



Treatment of a Failed Type V Acromioclavicular Separation Due to Coracoid Fracture: Revision of Acromioclavicular-Coracoclavicular Reconstruction and Coracoid Fixation

Petar Goliganin, M.B.A., Robert Waltz, M.D., C.D.R., M.C., U.S.N.,
Annalise M. Peebles, B.A., Connor Provencher, and
Matthew T. Provencher, M.D., CAPT., M.C., U.S.N.R.

Abstract: Acromioclavicular (AC) injuries are common, especially in the young and active population. AC joint dislocations account for 8% of all joint dislocations and are even more common in contact sports. These injuries are graded as type I through type VI on the basis of the Rockwood classification method. Types I and II are generally treated without surgery whereas types IV, V, and VI are best treated operatively. Type III dislocations remain controversial in terms of treatment, and many surgeons recommend nonoperative treatment first and operative treatment in case of continued symptoms such as pain, instability, or shoulder girdle dysfunction. The goal of operative treatment is to restore AC joint stability, which involves addressing both the coracoclavicular and coracoacromial ligaments to achieve a desirable patient outcome. The objective of this Technical Note is to describe our technique for management of a failed acromioclavicular stabilization, treated with a coracoclavicular and AC joint capsular reconstruction using tibialis anterior and semitendinosus allografts.

Acromioclavicular (AC) injuries are common in a young active population, especially in those who play contact sports with up to 80% of the injuries

From the Geisel School of Medicine at Dartmouth College (P.G.) and the Tuck School of Business at Dartmouth College (P.G.), Hanover, New Hampshire, the Steadman Clinic (R.W., M.T.P.) and The Steadman Philippon Research Institute (R.W., A.M.P., M.T.P.), Vail (C.P.), Colorado, U.S.A.

Research Performed at the Steadman Philippon Research Institute, Vail, CO
The authors report the following potential conflicts of interest or sources of funding: M.T.P. receives personal fees from Arthrex, personal fees from Joint Research Foundation (JRF), personal fees from SLACK Inc, personal fees from ArthroSurface, outside the submitted work; is an editorial or governing board member for Arthroscopy, Knee, Orthopedics, and SLACK Inc; and is a board or committee member for AANA, AAOS, AOSSM, ASES, ISAKOS, the San Diego Shoulder Institute, and the Society of Military Orthopaedic Surgeons. Full ICMJE author disclosure forms are available for this article online, as supplementary material.

Received August 23, 2020; accepted October 24, 2020.

Address correspondence to CAPT Matthew T. Provencher, M.D., M.C., U.S.N.R., The Steadman Clinic, The Steadman Philippon Research Institute, 181 W. Meadow Dr., Suite 400, Vail, CO 81657. E-mail: mprovencher@thesteadmanclinic.com

© 2021 Published by Elsevier on behalf of the Arthroscopy Association of North America. This is an open access article under the CC BY-NC-ND license (<http://creativecommons.org/licenses/by-nc-nd/4.0/>).

2212-6287/201455

<https://doi.org/10.1016/j.eats.2020.10.055>

occurring in a male population.¹ The AC injuries are often associated with disruption of surrounding structures such as the coracoacromial (CA) and coracoclavicular (CC) ligament and shoulder capsule injuries.^{2,3} Depending on the degree of the concomitant tissue injury, patients may experience significant shoulder pain and dysfunction.³ Rockwood's classification is used to classify these injuries, which extend from type I to type VI. Injury types I and II are treated almost universally without surgery, whereas types IV through VI are treated operatively because of significant soft-tissue disruption and shoulder dysfunction. The most controversial are type III injuries with no clear consensus on the optimal treatment algorithm.⁴ Most surgeons prefer to treat patients with type III injuries nonoperatively and in those cases that fail initial treatment the surgery is indicated.^{4,5}

Because of the prevalence of AC joint injuries, there are numerous studies that have described both the nonoperative and operative treatments.⁶⁻¹⁶ A systematic review by Beitzel and colleagues¹⁷ looked at 120 studies that collectively describe 162 different techniques for AC management. The study concluded that there is no consensus on a gold-standard procedure. Millett et al.⁵ reported complications in 7/31

(22.6%) patients at 2-year follow up, all who needed additional surgical procedures. These included clavicle fracture 2/31 (6.5%), distal clavicle hypertrophy 2/31 (6.5%), graft rupture or attenuation 2/31 (6.5%) and adhesive capsulitis 1/31 (3.2%). Another systemic review looked at 34 studies (939 patients) and found that all treatment modalities improved patient outcomes, but the highest complication rates were in cases that used hook plate/LK wires techniques (26.3%).⁴ Given the large number of different surgical techniques and consistent complication rates, treating patients who need revision surgery is even more complex. Thus it is essential to understand the reasons for failure to select the best option for revision surgery. The objective of this note is to describe our technique for AC-CC revision surgery with capsular reconstruction using two tibialis anterior allografts, cortical button (dog-bone button; Arthrex, Naples, FL) and high-strength suture (AC Tight Rope; Arthrex).

Preoperative Evaluation

Indications for either primary or revision AC-CC reconstruction are pain and shoulder dysfunction after failure of at least 3 months of nonoperative treatment in the setting of a Rockwood type III or above AC-CC injury. Preoperative work-up consists of a thorough history and shoulder examination with attention focused on deformity, symptomatic AC joint instability, and shoulder range of motion as well as evaluating for scapular dysfunction and strength deficits. Imaging studies should consist of AP, Axillary, and Scapular Y shoulder radiographs as well as bilateral AP radiographs of the AC joints to assess side to side differences in coracoclavicular distances and AC joint congruity. Computed tomography (CT) should also be obtained in the setting of failed previous AC-CC fixation to assess for coracoid fracture and to evaluate the prior bone

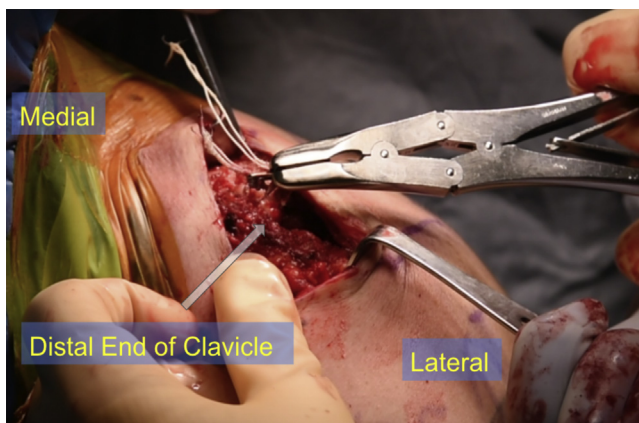


Fig 1. Left shoulder, beach-chair position. The distal clavicle was highly unstable. The prior button from the superior clavicle was removed and suture from the inferior clavicle was retrieved.

Table 1. Pearls and Pitfalls of Revision Acromioclavicular-Coracoclavicular Reconstruction with Coracoid Fracture Nonunion

Pearls

Prior bone tunnels should be carefully analyzed for size, position and presence of lysis. If the initial tunnel is poorly positioned or lysis is present, a new tunnel should be drilled. In cases where the size of the tunnel is too large, large screw fixation or “cuff links” should be used.

To restore native stability, it is important to pay attention to the position of bone tunnels. The medial tunnel (conoid), used for the tight rope grommet and should be 30 to 45 mm (in this case it was 35 mm) medial to the AC joint and on the posterior aspect of the clavicle. The second clavicular tunnel (trapezoid) should be positioned on the anterior one third on the clavicle 25 mm from the distal end and lateral to the conoid tunnel. These tunnels should be no more than 5 mm to match graft thickness.

The AC joint should be anatomically reduced superior-inferior and anterior-posterior.

Fluoroscopy should be used to confirm appropriate AC joint reduction.

Pitfalls

If the old tunnels are not usable, the surgeon must ensure adequate spacing of the new tunnel(s) to avoid convergence or fracture. This is particularly important when assessing the coracoid tunnel.

Care should be taken during dissection or retraction medial to the coracoid to protect the musculocutaneous nerve and prevent injury.

Drill plunging during coracoid or acromion drilling may result in injuries to neurovascular structures or rotator cuff, respectively. Thus it is highly recommended to use a retractor on the undersurfaces during drilling.

tunnels for position and widening for preoperative planning. The surgeon should also consider magnetic resonance imaging in a revision setting to further evaluate for intraarticular shoulder or rotator cuff pathology based on examination findings.

Surgical Technique

A narrated video with demonstration of the surgical technique described in the following may be reviewed ([Video 1](#)).

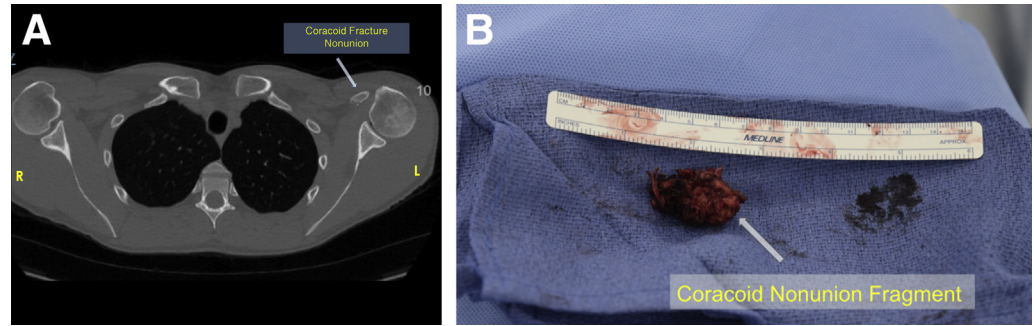
Patient Positioning and Anesthesia

The procedure is performed with the patient in the beach-chair position and under general anesthesia and supplemented by a regional interscalene block for postoperative analgesic purposes. The knees are placed in slight flexion with a soft pad under the popliteal fossa. Care should be taken to pad all bony prominences. The head and neck should be carefully positioned to achieve neutral position before the procedure. Examination with the patient under anesthesia is performed, and all relevant bony anatomy is identified through palpation and marked with a surgical pen.

Surgical Approach

The procedure begins by extending the incision scar from the prior procedure. All relevant bony structures

Fig 2. (A) On the preoperative imaging it was noted that there was a displaced coracoid fracture and nonunion on the patient's the left side. (B) Once the coracoid was exposed, the distal aspect was noted to be mobile and was resected.



are identified via palpation. The incision is approximately 5 cm in length 2 cm medial to the AC joint extending from posterior to anterior. Skin and subcutaneous tissue are incised and deltotrapezial fascia is visualized. Full-thickness flaps are created medially and laterally. Dissection of deltotrapezial fascia is done in line with the long axis of the clavicle by using a combination of Metzenbaum scissors and needle-tip Bovie (Bovie Medical, Purchase, NY). The fascia is preserved to facilitate layered closure. Soft tissues are then dissected down to the clavicle followed by subperiosteal dissection to visualize the anterior and posterior aspects of the clavicle and AC joint. The distal clavicle was highly unstable and partially subluxed from the AC joint. The prior button from the superior clavicle is removed and suture from the inferior clavicle is retrieved (Fig 1). The superior and inferior aspects of coracoid are also exposed using Metzenbaum scissors, followed by CC ligament debridement. This allows for provisional manual reduction of the AC joint (Table 1).

Graft Preparation

During the initial steps of the procedure, an assistant may prepare grafts as needed for the reconstruction. Options for grafts include anterior tibialis allograft or semitendinosus allograft or autograft. The desired diameter for each graft is 4 to 5 mm, and preparation includes whipstitching both ends.

Coracoid Preparation

On the preoperative imaging it was noted that there was a coracoid fracture with nonunion (Fig 2A). Once the coracoid was exposed the distal aspect was noted to be mobile and was resected to a wafer of bone that connected to the conjoint tendon (Fig 2B). The conjoint tendon origin was tagged with 3 FiberTape sutures and proximally exposed. The remnant nonunion section of coracoid was resected, and the allografts were then planned to be fixed at the base of coracoid with suture anchors placed in an intramedullary fashion into the remaining base of the coracoid. Preparation for a 5.5 mm SwiveLock anchor (PEEK, Arthrex) was then

performed by first drilling into the base of the remaining coracoid, then tapping to later attach the previously whipstitched conjoint tendon just posterior and superior to the anatomic placement of coracoid.

Tunnel Drilling

The remaining coracoid base is exposed and used to place a 3 mm cannulated guide pin from posterior to anterior at an angle of approximately 45°, and a passing suture is passed through the guide pin tunnel (Fig 3). This is for passage of the TightRope and dog-bone construct. Two tunnels were drilled in the clavicle. The first clavicular tunnel was drilled in the posterior one third of the clavicle approximately 35 mm from the AC joint (Table 1). This tunnel is used for conoid ligament reconstruction. The second clavicular tunnel is drilled on the anterior one third on the clavicle 25 mm medial to the distal end and is used for trapezoid ligament reconstruction. These tunnels should be approximately 4 to 5 mm in diameter to match graft thickness (Table 1). Passing sutures are passed through these tunnels. Extra care should be taken while drilling these tunnels by placing a retractor along the inferior aspect of the clavicle to prevent damage to the adjacent neurovascular structures (Table 1). One tunnel is then drilled in the acromion at midline, approximately

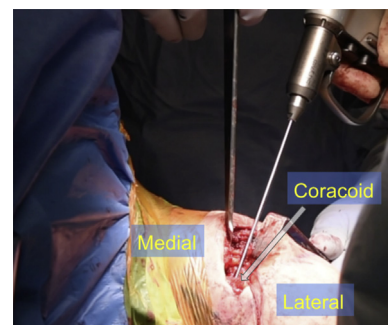


Fig 3. Left shoulder, beach-chair position. The remaining coracoid base was exposed and used to place a 3 mm cannulated guide pin from posterior to anterior at an angle of approximately 45°.

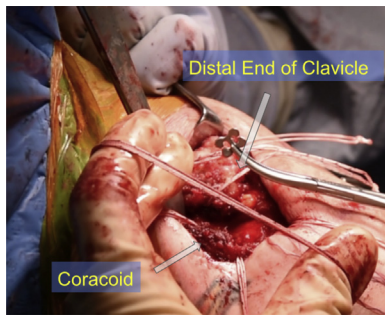


Fig 4. Left shoulder, beach-chair position. The tightrope is then passed through the base of the coracoid and a dog-bone button is placed on the suture loop, which is then tightened as the button is carefully guided to the base of the coracoid to secure the clavicle into anatomic position.

14 mm lateral to the AC joint followed by a passing suture for later graft passage.

Fixation

The tightrope suture for the dog-bone button construct is passed superiorly to inferiorly first through the clavicle tunnel and the gromet seated into the clavicle. The tightrope is then passed through the base of the coracoid and a dog-bone button is placed on the suture loop which is then tightened as the button is carefully guided to the base of the coracoid to secure the clavicle into an anatomic position (Fig 4). A 5.5 mm PEEK swivel lock anchor is placed into the previously drilled/tapped hole at the remaining coracoid loaded with fiber tape sutures to secure the graft and the conjoint tendon (Fig 5). The conjoint tendon is secured by whipstitching it with a single limb of the sliding suture within the swivel lock anchor and then tying the previously placed fiber tape sutures to the tension limb after securing it to the base of the remaining coracoid and superior glenoid neck (Fig 6).

One end of the graft is placed against the coracoid base and secured by suturing it with the fiber tape previously passed through the swivel lock anchor. One limb of the graft is passed from anterior to posterior inferior to the clavicle. Final tightening of the tightrope is performed, and the suture limbs are tied. The two ends of the graft are then tensioned over the superior clavicle and secured with fiber tape.

The posterior graft limb is crossed deep to the anterior limb and passed inferior to superior through the lateral/anterior clavicle tunnel and secured with a 5.5 × 8 mm biotenodesis screw (Fig 7). This limb is then passed from inferior to superior through the acromion tunnel and a second tenodesis screw is placed in the acromion to secure the graft. The two free graft limbs were again tensioned over the superior clavicle and sutured together with fiber tape, then cut.

The final construct creates basically a soft tissue hook plate through reconstruction of the AC joint capsule with the allograft. Range of motion of the arm is checked, and the stability of the reconstruction is confirmed. The wound is copiously irrigated and ready for closure.

Closure

The full-thickness deltotrapezoidal fascia flaps are closed with nonabsorbable suture in a pants-over-vest fashion for additional tension across the AC joint. The deep dermal layer and skin are closed with buried absorbable suture. A sterile dressing is applied, and the patient is placed in a padded abduction sling with elbow support.

Postoperative Rehabilitation

The patient is placed in a padded abduction sling with full elbow support for 6 weeks. During this period passive range of motion at the elbow and wrist is initiated. Passive shoulder motion is limited to below

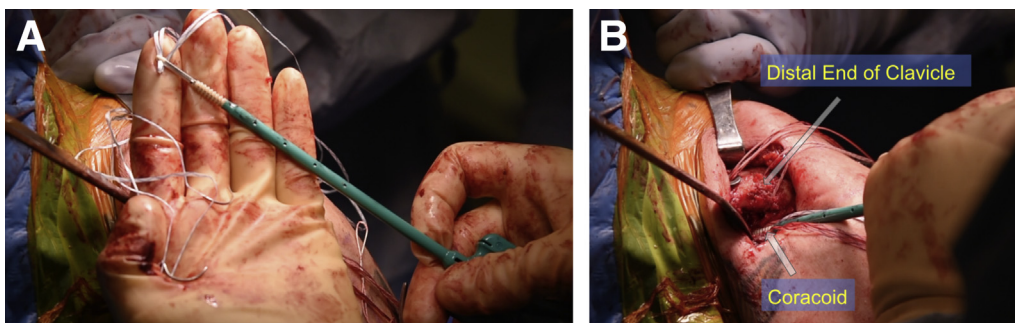


Fig 5. (A) Left shoulder, beach-chair position. A 5.5 mm PEEK SwiveLock anchor is placed into the previously drilled/tapped in the intramedullary canal of the remaining coracoid stump and is loaded with fiber tape sutures to secure the graft and the conjoint tendon. (B) Left shoulder, beach-chair position. The 4.75 mm PEEK SwiveLock is inserted into the base of the coracoid. The sutures will be used to secure and tie in the allograft (semitendinosus), which reconstructs the coracoclavicular ligaments.

the horizontal plane. Physical therapy begins immediately for guidance on passive range of motion and restrictions. Active assist range of motion begins at 6 weeks after surgery, and strengthening begins at 3 months after surgery. The patient resumes full activities at 6 months or earlier if cleared by the physician.

Discussion

This Technical Note describes revision AC joint reconstruction with coracoid fracture malunion using 2 tibialis anterior allografts with capsular reconstruction to restore AC joint stability. AC joint injuries are most common in younger individuals who participate in contact sports.¹⁸⁻²⁰ In those who undergo surgical treatment, up to 30% of patients will require reoperation.³ This demonstrates the complexity of AC joint stabilization procedures and the multitude of techniques that can be applied in different cases.

There are various reasons for complications after the AC joint stabilization, which include but are not limited to type of implant and method used, postoperative care, and infection.^{15,21-28} Thus it is prudent to understand the index procedure techniques, mechanics of the implants, and the mechanism of the initial injury. In their systematic review Moatshe et al.⁶ reported that the use of hook plates and K-wires in AC joint reconstruction resulted in highest rates of complications while the modified Weaver-Dunn procedure had high rate of unplanned reoperations. Weaver-Dunn includes distal clavicle resection and transfer of the CA ligament to the CC ligament although several modifications of this procedure involve the use of allograft passed inferior to the clavicle and wrapped around the clavicle. In general, failure of these procedures leave the coracoid intact, which makes our procedure ideal for revisions.^{28,29}

Conversely, techniques that use anatomic reconstruction with a combination of high-strength suture and button devices along with allograft require drill

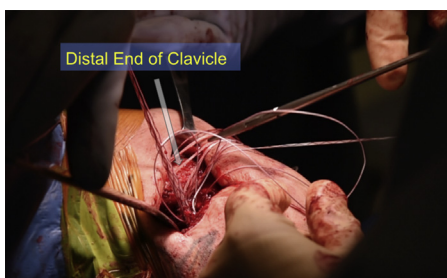

Fig 6. Left shoulder, beach-chair position. The conjoint tendon is secured by whipstitching it with a single limb of the sliding suture within the swivel lock anchor; thus both the semitendinosus allograft and the conjoint tendon are sutured via the SwiveLock anchor into the remaining base of the coracoid.

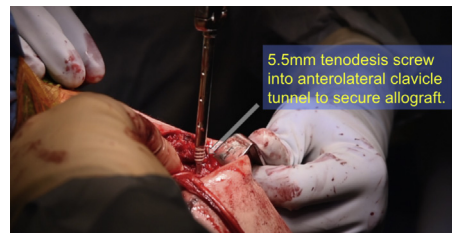


Fig 7. Left shoulder, beach-chair position. One of the allograft limbs is crossed deep to the other limb and passed inferior to superior through the anterolateral 5.0 mm clavicle tunnel and secured with a 5.5 × 8 mm biotenodesis screw.

holes through coracoid and clavicle, which provide a stress point of failure because of fracture or cutout.²⁹⁻³¹ In our case there was a coracoid fracture malunion from the initial injury and a tunnel drilled into the coracoid requiring the distal part of coracoid to be resected. It was imperative to place the bone tunnel away from the fracture/cutout area at the base of the coracoid using a minimal footprint to ensure strength for the reconstruction. The advantage of our procedure is that only one tunnel is required for the coracoid in order to use the dog-bone button and tightrope construct to augment fixation. It is important to mention that this is not the only technique for joint reduction in this procedure.

A key advantage of anatomic reconstruction is the restoration of the native biomechanics of the AC joint.³¹ Several studies show that this increases the strength of the joint and reduces the risk of future instability.³¹⁻³⁵ Additionally, we prefer to use biological over synthetic grafts since biological grafts have been reported to be superior in terms of radiographic and clinical outcomes.^{36,37} Although there are favorable short-term clinical outcomes in anatomic AC reconstruction procedures, further studies are needed to assess the long-term outcomes.

References

1. Rockwood CA Jr, YD. Disorders of the acromioclavicular joint. In: Rockwood Jr CA, Matsen FA, eds. *The Shoulder*. Ed 3. Philadelphia: WB Saunders, 1990;413-476.
2. Kennedy MI, Peebles LA, Provencher MT, LaPrade RF. Acromioclavicular and coracoclavicular ligament reconstruction for acromioclavicular joint instability. *JBJS Essent Surg Tech* 2019;9.
3. Frank RM, Cotter EJ, Leroux TS, Romeo AA. Acromioclavicular joint injuries: Evidence-based treatment. *J Am Acad Orthop Surg* 2019;27:e775-e788.
4. Tang G, Zhang Y, Liu Y, Qin X, Hu J, Li X. Comparison of surgical and conservative treatment of Rockwood type-III acromioclavicular dislocation: A meta-analysis. *Medicine (Baltimore)* 2018;97:e9690.

5. Millett PJ, Horan MP, Warth RJ. Two-year outcomes after primary anatomic coracoclavicular ligament reconstruction. *Arthroscopy* 2015;31:1962-1973.
6. Moatshe G, Kruckeberg BM, Chahla J, et al. Acromioclavicular and coracoclavicular ligament reconstruction for acromioclavicular joint instability: A systematic review of clinical and radiographic outcomes. *Arthroscopy* 2018;34:1979-1995.e1978.
7. Chahla J, Marchetti DC, Moatshe G, et al. Quantitative assessment of the coracoacromial and the coracoclavicular ligaments with 3-dimensional mapping of the coracoid process anatomy: A cadaveric study of surgically relevant structures. *Arthroscopy* 2018;34:1403-1411.
8. Haber DB, Golijanin P, Stone GL, et al. Primary acromioclavicular-coracoclavicular reconstruction using 2 allografts, tightrope, and stabilization to the acromion. *Arthrosc Tech* 2019;8:e147-e152.
9. Peebles LA, Dekker TJ, Akamefula RA, Golijanin P, Grantham WJ, Provencher MT. Distal Clavicular Augmentation with Acromioclavicular and Coracoclavicular Ligament Reconstruction in the Setting of Iatrogenic Induced Acromioclavicular Instability. *Arthrosc Tech* 2019;8:e1583-e1589.
10. Haber DB, Spang RC, Sanchez G, Sanchez A, Ferrari MB, Provencher MT. Revision acromioclavicular-coracoclavicular reconstruction: Use of precontoured button and 2 allografts. *Arthrosc Tech* 2017;6:e2283-e2288.
11. Bontempo NA, Mazzocca AD. Biomechanics and treatment of acromioclavicular and sternoclavicular joint injuries. *Br J Sports Med* 2010;44:361-369.
12. Krill MK, Rosas S, Kwon K, Dakkak A, Nwachukwu BU, McCormick F. A concise evidence-based physical examination for diagnosis of acromioclavicular joint pathology: A systematic review. *Phys Sportsmed* 2018;46:98-104.
13. Cisneros LN, Reiriz JS. Management of chronic unstable acromioclavicular joint injuries. *J Orthop Traumatol* 2017;18:305-318.
14. Lu D, Wang T, Hong JJ, Chen H, Sun LJ. Acute acromioclavicular joint dislocation treated with tightrope: Mini-open versus percutaneous stabilization. *Acta Orthop Belg* 2019;85:406-411.
15. Nolte PC, Lacheta L, Dekker TJ, Elrick BP, Millett PJ. Optimal management of acromioclavicular dislocation: Current perspectives. *Orthop Res Rev* 2020;12:27-44.
16. Erdle B, Izadpanah K, Jaeger M, et al. Comparative analysis of locking plate versus hook plate osteosynthesis of Neer type IIB lateral clavicle fractures. *Arch Orthop Trauma Surg* 2017;137:651-662.
17. Beitzel K, Cote MP, Apostolakis J, et al. Current concepts in the treatment of acromioclavicular joint dislocations. *Arthroscopy* 2013;29:387-397.
18. Deans CF, Gentile JM, Tao MA. Acromioclavicular joint injuries in overhead athletes: A concise review of injury mechanisms, treatment options, and outcomes. *Curr Rev Musculoskelet Med* 2019;12:80-86.
19. Müller D, Reinig Y, Hoffmann R, et al. Return to sport after acute acromioclavicular stabilization: A randomized control of double-suture-button system versus clavicular hook plate compared to uninjured shoulder sport athletes. *Knee Surg Sports Traumatol Arthrosc* 2018;26:3832-3847.
20. Kiel J, Kaiser K. Acromioclavicular Joint Injury. In: StatPearls. *Treasure Island (FL)*. StatPearls Publishing LLC., 2020. StatPearls Publishing Copyright © 2020.
21. Porschke F, Schnetzke M, Studier-Fischer S, Gruetzner PA, Guehring T. Return to work after acromioclavicular joint stabilization: A retrospective case control study. *J Orthop Surg Res* 2019;14:45.
22. Thangaraju S, Tauber M, Habermeyer P, Martetschläger F. Clavicle and coracoid process periprosthetic fractures as late post-operative complications in arthroscopically assisted acromioclavicular joint stabilization. *Knee Surg Sports Traumatol Arthrosc* 2019;27:3797-3802.
23. Jordan RW, Malik S, Bentick K, Saithna A. Acromioclavicular joint augmentation at the time of coracoclavicular ligament reconstruction fails to improve functional outcomes despite significantly improved horizontal stability. *Knee Surg Sports Traumatol Arthrosc* 2019;27:3747-3763.
24. Yeak RD, Daud H, Nizlan NM. Osteomyelitis post acromioclavicular joint reconstruction. *Chin J Traumatol* 2019;22:182-185.
25. Athar MS, Ashwood N, Arealis G, Hamlet M, Salt E. Acromioclavicular joint disruptions: A comparison of two surgical approaches "hook" and "rope.". *J Orthop Surg (Hong Kong)* 2018;26:2309499017749984.
26. Chernchujit B, Artha A. High grade acromioclavicular injury: Comparison of arthroscopic assisted acromioclavicular joint fixation and anatomic acromioclavicular joint reconstruction. *J Orthop* 2020;22:151-157.
27. Cook JB, Krul KP. Challenges in treating acromioclavicular separations: Current concepts. *J Am Acad Orthop Surg* 2018;26:669-677.
28. Rush LN, Lake N, Stiefel EC, et al. Comparison of short-term complications between 2 methods of coracoclavicular ligament reconstruction: A multicenter study. *Orthop J Sports Med* 2016;4:2325967116658419.
29. Spencer HT, Hsu L, Sodl J, Arianjam A, Yian EH. Radiographic failure and rates of re-operation after acromioclavicular joint reconstruction: a comparison of surgical techniques. *Bone Joint J* 2016;98-b:512-518.
30. Xue C, Zhang M, Zheng TS, et al. Clavicle and coracoid process drilling technique for truly anatomic coracoclavicular ligament reconstruction. *Injury* 2013;44:1314-1320.
31. Dyrna F, Berthold DP, Feucht MJ, et al. The importance of biomechanical properties in revision acromioclavicular joint stabilization: a scoping review. *Knee Surg Sports Traumatol Arthrosc* 2019;27:3844-3855.
32. Izadpanah K, Jaeger M, Ogon P, Südkamp NP, Maier D. Arthroscopically assisted reconstruction of acute acromioclavicular joint dislocations: Anatomic AC ligament reconstruction with protective internal bracing—The "AC-RecoBridge" technique. *Arthrosc Tech* 2015;4:e153-e161.
33. Lee S, Bedi A. Shoulder acromioclavicular joint reconstruction options and outcomes. *Curr Rev Musculoskelet Med* 2016;9:368-377.

34. Muench LN, Kia C, Jerliu A, et al. Functional and radiographic outcomes after anatomic coracoclavicular ligament reconstruction for type III/V acromioclavicular joint injuries. *Orthop J Sports Med* 2019;7:2325967119884539.
35. Beitzel K, Obopilwe E, Apostolakos J, et al. Rotational and translational stability of different methods for direct acromioclavicular ligament repair in anatomic acromioclavicular joint reconstruction. *Am J Sports Med* 2014;42:2141-2148.
36. Fauci F, Merolla G, Paladini P, Campi F, Porcellini G. Surgical treatment of chronic acromioclavicular dislocation with biologic graft vs synthetic ligament: a prospective randomized comparative study. *J Orthop Traumatol* 2013;14:283-290.
37. Phadke A, Bakti N, Bawale R, Singh B. Current concepts in management of ACJ injuries. *J Clin Orthop Trauma* 2019;10:480-485.