

# Rapidly Expanding Lateral Ventricular Meningioma Presenting with Intraventricular Hemorrhage following Remote Whole Brain Radiation and Stereotactic Radiosurgery

Joshua T. Prickett<sup>1,2,3,4,6</sup> Brendan J. Klein<sup>1,2,3,4,6</sup> Christopher M. Busch<sup>1,2,3,4,6</sup> Joshua A. Cuoco<sup>5</sup>  
Lisa S. Apfel<sup>1,2,3,4,6</sup> Eric A. Marvin<sup>1,2,3,4,6</sup>

<sup>1</sup>Division of Neurosurgery, Carilion Clinic, Roanoke, Virginia, United States

<sup>2</sup>Virginia Tech Carilion School of Medicine, Roanoke, Virginia, United States

<sup>3</sup>Virginia Tech School of Neuroscience, Roanoke, Virginia, United States

<sup>4</sup>Edward Via College of Osteopathic Medicine, Blacksburg, Virginia, United States

<sup>5</sup>New York Institute of Technology College of Osteopathic Medicine, Old Westbury, New York, United States

<sup>6</sup>Department of Surgery, Virginia Tech Carilion Clinic, Roanoke, Virginia, United States

Address for correspondence Eric A. Marvin, DO, Division of Neurosurgery, Carilion Clinic, 2331 Franklin Road, Roanoke, VA 24014, United States (e-mail: eamarvin@carilionclinic.org).

J Neurol Surg Rep 2018;79:e14–e18.

## Abstract

### Keywords

- ▶ meningioma
- ▶ ventricular system
- ▶ intraventricular hemorrhage
- ▶ whole brain radiation

Intraventricular meningiomas are uncommon intracranial tumors and infrequently present with hemorrhage. With only 10 reported cases in the literature, it is exceedingly rare for meningiomas of the ventricular system to present with hemorrhage. To our knowledge, this is the first report of a patient presenting with an acute intraventricular hemorrhage in relation to a ventricular meningioma suspected to be radiation induced. In addition, we review the current literature on hemorrhagic intraventricular meningiomas and review the natural history of radiation-induced meningiomas.

## Introduction

Meningiomas are typically benign tumors that represent ~20% of all primary intracranial neoplasms.<sup>1</sup> Intraventricular meningiomas are a rare subtype representing 0.5% to 3.0% of all meningiomas.<sup>2</sup> Meningiomas generally do not exhibit a hemorrhagic component as only 1.3% to 2.4% of cases are associated with hemorrhage.<sup>3</sup> Furthermore, hemorrhage associated with intraventricular meningiomas is extremely uncommon with only 10 reported cases in the literature since 1960.<sup>4–12</sup> Among these cases, none were associated with a previous history of radiation therapy.

We describe a 49-year-old female previously treated with both whole brain radiation and stereotactic radiosurgery (SRS) that presented with a newly discovered right lateral ventricular meningioma and intraventricular hemorrhage.

Her history included both prophylactic whole brain radiation in her early 20's for acute lymphoblastic leukemia (ALL) and SRS for treatment of symptomatic cavernous hemangiomas (cavernomas). In addition to this novel case, we will discuss the current literature regarding hemorrhagic intraventricular meningiomas as well as briefly review the natural history of radiation-induced meningiomas. We propose that both the development of this patient's meningioma and the acute hemorrhagic manifestations may potentially be consequential to her prior exposure to brain radiation.

## Case Report

A 49-year-old female presented to the hospital after a sudden onset of a severe headache associated with vision loss. Her past medical history consisted of ALL in her early 20s, which

received  
September 22, 2017  
accepted  
January 22, 2018

DOI <https://doi.org/10.1055/s-0038-1637006>  
ISSN 2193-6358.

© 2018 Georg Thieme Verlag KG  
Stuttgart · New York

License terms



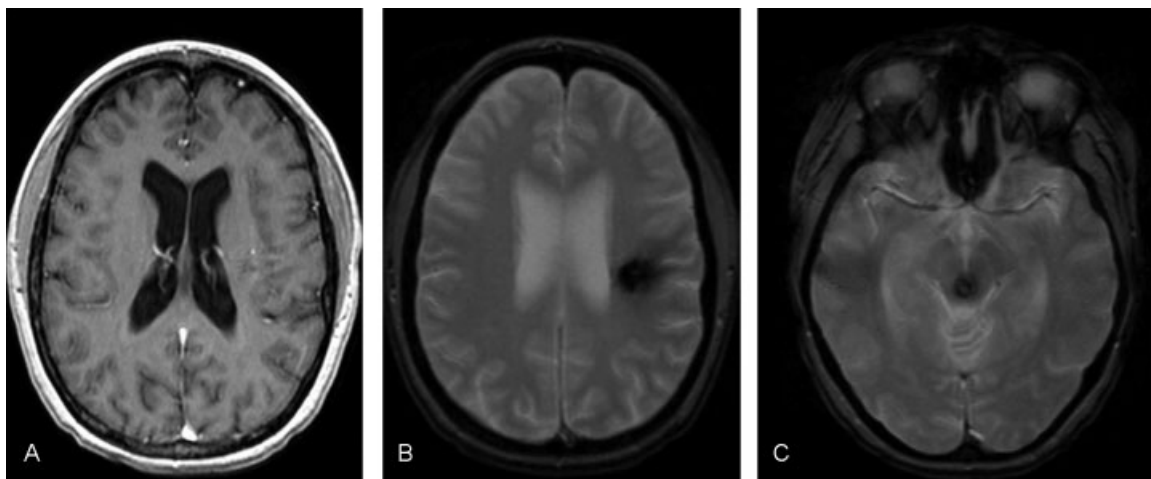
was treated with chemotherapy and prophylactic whole brain radiation. At 41 years old, her family reports that she was diagnosed with cavernous malformations in the midbrain and left corona radiata that were discovered after a hemorrhagic event, both of which were treated with Gamma Knife SRS at an outside institution. Interestingly, she had been seen in our department in 2009 for visual changes, where magnetic resonance imaging (MRI) demonstrated the suspected cavernous hemangiomas in the brain stem and left corona radiata, without any imaging evidence of a ventricular lesion (►Fig. 1). Upon arrival to the emergency department, her headache had diminished in intensity. Physical examination revealed decreased sensory perception on the left side of her body, a mild neglect, and an incongruent left-sided hemianopsia. Computed tomography imaging of the head demonstrated a well-circumscribed, homogeneous isodensity within and adjacent to the right lateral ventricle with hyperdense acute hemorrhage within the ventricular and intraparenchymal spaces (►Fig. 2). MRI demonstrated a mass with 4.2 cm craniocaudal, 3.2 cm anteroposteriorly, and 3.2 cm transverse dimensions that was T1 hypointense, T2 hyperintense, mildly diffusion-restricted, avidly enhancing, and well-circumscribed (►Fig. 3). MRI from 8 years prior demonstrated her previously known cavernomas without evidence of any ventricular mass. We felt that the differential diagnosis of this lesion included meningioma, metastasis, lymphoma, choroid plexus papilloma, and arteriovenous malformation or aneurysm. A metastatic workup was negative. Considering the mass effect, hemorrhagic nature, and need for tissue diagnosis, a craniotomy for tumor resection was recommended. A stereotactic-guided craniotomy was performed. We utilized a parietal trans-sulcal approach. The mass was well circumscribed with a firm capsule that extended into the atrium of the right ventricle. It derived its predominate blood supply from the choroidal

arteries. The deep feeding arterial supply was controlled and a gross total resection was achieved. Pathology was consistent with a grade I meningothelial meningioma with a  $K_i-67$  index of  $< 1\%$  (►Fig. 4). Postoperatively, the patient had no significant motor weakness or visual changes, but did experience worsening of her left-sided hemineglect. She was discharged on postoperative day 7 to an inpatient rehabilitation facility for continued therapy and resolution of her symptoms.

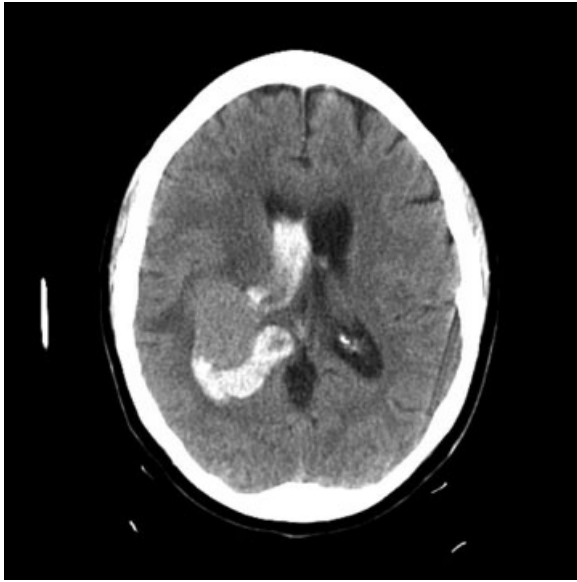
## Discussion

Intraventricular meningiomas are uncommon. These benign tumors are most commonly found within the lateral ventricles with ~90% located specifically within the trigone.<sup>13,14</sup> Clinical manifestations of these tumors can vary depending on the size as well as location within the ventricular system. A small-sized tumor of the lateral ventricle may remain clinically undetectable. However, large symptomatic intraventricular meningiomas often become clinically apparent due to symptoms related to increased intracranial pressure, visual field defects, and weakness or seizures. Acute onset of severe headaches related to hemorrhage is uncommon.

Hemorrhagic intraventricular meningiomas are exceedingly rare. In fact, our literature review identified 10 reported cases of hemorrhagic intraventricular meningiomas since 1960 (►Table 1).<sup>4-12</sup> Of the reported cases, age of onset ranged between 14 and 64 years old with an average age of onset of 45.2 years. Female predominance was observed with 7 out of 10 cases. Regarding histopathology, five cases (50%) were classified as fibroblastic, two (20%) were endotheliomatous, one (10%) was psammomatous, one (10%) was transitional, and one (10%) case did not report pathology. The case we present has similar epidemiological characteristics as previously reported cases including age of onset



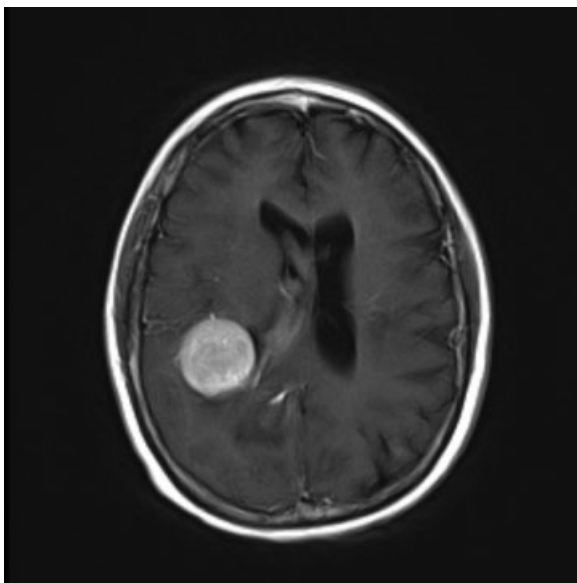
**Fig. 1** These images are from 8 years prior to presentation. (A) T1-weighted axial magnetic resonance imaging (MRI) with contrast showing the lateral ventricles normal in size and midline in position. (B) T2 fast low angle shot (FLASH) MRI demonstrating a 7 mm cavernous angioma within the upper left corona radiata. Considerable signal hypodensity is observed at the periphery of this lesion consistent with abundant hemosiderin deposition secondary to hemorrhage. (C) T2 FLASH MRI demonstrating a 9 mm cavernous angioma within the central portion of the midbrain, immediately anterior to the cerebral aqueduct. Considerably less extensive signal hypointensity is observed at the periphery of the midbrain lesion.



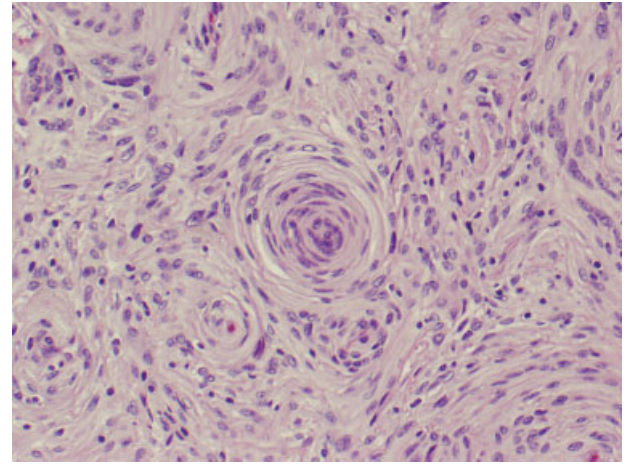
**Fig. 2** Axial computed tomography of the head demonstrating a round homogeneous isodensity within the right lateral ventricle. Hyperdense acute hemorrhage within the ventricular and intraparenchymal spaces was observed.

(49 years old versus a mean of 45.2 years old) and female predominance. This is the first reported case of a hemorrhagic ventricular meningioma of meningeothelial subtype. Interestingly, none of the prior 10 cases reported a history of radiation therapy, and to our knowledge, this is the first reported case of a hemorrhagic ventricular meningioma following brain radiation.

Due in part to their exceptionally low incidence rate, the causative factors for an intraventricular hemorrhage in asso-



**Fig. 3** T1-weighted axial magnetic resonance imaging demonstrating a T1 hypointense lesion measuring 4.2 cm craniocaudal, 3.2 cm anteroposteriorly, and 3.2 cm transverse in dimensions.



**Fig. 4** Histological examination showed a spindle/fibroblastic tumor. Ki67, performed to assess proliferative activity, was < 1%. This was consistent with a grade I meningioma, meningeothelial subtype.

ciation with a meningioma have yet to be fully elucidated; however, several hypotheses have been suggested to describe this phenomenon.<sup>15–18</sup> The most widely accepted hypothesis was proposed by Helle and Conley stating that compensatory expansion of meningeothelial vasculature can weaken arterial walls leading to rupture.<sup>15</sup> Bloomgarden et al suggested that meningeothelial arterial feeders can become more susceptible to variations in blood pressure due to arterial dilatation and tortuosity resulting in a loss of vascular resilience.<sup>16</sup> Jones and Blumbergs observed granulation tissue encompassing a necrotic area within the tumor bed attributing the cause of rupture to aberrant neovascularization.<sup>17</sup> Another hypothesis suggests that tumor necrosis can collapse the tumor bed.<sup>18</sup> Moreover, anticoagulation therapy, trauma, seizures, and blood dyscrasias may also contribute to meningioma hemorrhages.<sup>3</sup>

This case report details a patient previously treated with prophylactic whole brain radiation as well as SRS. Exposure to ionizing radiation has been associated as the strongest modifiable risk factor for the development of meningiomas.<sup>19,20</sup> An increased risk of meningioma development has also been established in those treated with cranial irradiation for ALL.<sup>19,20</sup> For example, a recent cohort study of 2,169 survivors of ALL demonstrated that 14% of individuals treated with prophylactic whole brain radiation developed meningiomas with a latency period of 20.6 years.<sup>19</sup> In addition, radiation treatment has also been associated with the development of cavernomas.<sup>21,22</sup> Radiation-related injury has been associated with proliferative vasculopathy, increased expression of vascular endothelial growth factor, neoangiogenesis, and deoxyribonucleic acid damage.<sup>23</sup> Radiation is thought to cause endothelial swelling, dilation of vessel lumens, hyalinization, and fibrosis.<sup>24</sup> Not surprisingly, reports have suggested that radiation-induced cavernomas may have an increased risk of hemorrhage compared with spontaneous cavernomas.<sup>21,25</sup> We propose that the same radiation-induced mechanisms that lead to the formation of angiographically occult vascular malformations

**Table 1** Reported cases of patients presenting with a hemorrhagic lateral ventricular meningioma

Author	Year	Age	Sex	Histology	Prior radiation	Reference
Askenasy	1960	34	F	Endotheliomatous	No	4
Askenasy	1960	38	M	Fibroblastic	No	4
Goran	1965	55	M	Endotheliomatous	No	5
Smith	1975	14	F	Fibroblastic	No	6
Lang	1995	64	M	Fibroblastic	No	7
Murai	1996	39	F	Fibroblastic	No	8
Lee	2001	43	F	Psammomatous	No	9
Romeike	2007	57	F	Fibroblastic	No	10
Fu	2011	46	F	Transitional	No	11
Das	2013	62	F	N/A	No	12
Present case	2017	49	F	Meningothelial	Yes	–

(e.g., capillary telangiectasia, cavernous malformations) may predispose radiation-induced meningiomas to a higher propensity for spontaneous hemorrhage.

## Conclusion

To our knowledge, this is the first case report describing a suspected radiation-induced lateral ventricular meningioma presenting with acute intraventricular hemorrhage. We suggest that the genesis of this patient's intraventricular meningioma, and potentially her hemorrhagic manifestation, may be a result of her extensive history of brain radiotherapy. Although hemorrhagic meningiomas of the ventricular system are exceedingly rare, we believe that early diagnosis and treatment are essential to avoid unnecessary morbidity and mortality.

### Conflict of Interest

None.

## References

- Saraf S, McCarthy BJ, Villano JL. Update on meningiomas. *Oncologist* 2011;16(11):1604–1613
- Nakamura M, Roser F, Bundschuh O, Vorkapic P, Samii M. Intraventricular meningiomas: a review of 16 cases with reference to the literature. *Surg Neurol* 2003;59(06):491–503, discussion 503–504
- Bosnjak R, Derham C, Popović M, Ravnik J. Spontaneous intracranial meningioma bleeding: clinicopathological features and outcome. *J Neurosurg* 2005;103(03):473–484
- Askenasy HM, Behmoaram AD. Subarachnoid hemorrhage in meningiomas of the lateral ventricle. *Neurology* 1960;10:484–489
- Goran A, Cimenello VJ, Fisher RG. Hemorrhage into meningiomas. *Arch Neurol* 1965;13:65–69
- Smith VR, Stein PS, MacCarty CS. Subarachnoid hemorrhage due to lateral ventricular meningiomas. *Surg Neurol* 1975;4(02):241–243
- Lang I, Jackson A, Strang FA. Intraventricular hemorrhage caused by intraventricular meningioma: CT appearance. *AJNR Am J Neuroradiol* 1995;16(06):1378–1381
- Murai Y, Yoshida D, Ikeda Y, Teramoto A, Kojima T, Ikakura K. Spontaneous intraventricular hemorrhage caused by lateral ventricular meningioma—case report. *Neurol Med Chir (Tokyo)* 1996;36(08):586–589
- Lee EJ, Choi KH, Kang SW, Lee IW. Intraventricular hemorrhage caused by lateral ventricular meningioma: a case report. *Korean J Radiol* 2001;2(02):105–107
- Romeike BF, Joellenbeck B, Skalej M, Scherlach C, Kirches E, Mawrin C. Intraventricular meningioma with fatal haemorrhage: clinical and autopsy findings. *Clin Neurol Neurosurg* 2007;109(10):884–887
- Fu Z, Xu K, Xu B, Qu L, Yu J. Lateral ventricular meningioma presenting with intraventricular hemorrhage: a case report and literature review. *Int J Med Sci* 2011;8(08):711–716
- Das D, Singh V. A sphenoid wing meningioma presenting with intraparenchymal and intraventricular hemorrhage treated with endovascular embolization alone: case report and radiologic follow-up. *J Neurointerv Surg* 2012;4(06):e36
- Lyngdoh BT, Giri PJ, Behari S, Banerji D, Chhabra DK, Jain VK. Intraventricular meningiomas: a surgical challenge. *J Clin Neurosci* 2007;14(05):442–448
- Delfini R, Acqui M, Oppido PA, Capone R, Santoro A, Ferrante L. Tumors of the lateral ventricles. *Neurosurg Rev* 1991;14(02):127–133
- Helle TL, Conley FK. Haemorrhage associated with meningioma: a case report and review of the literature. *J Neurol Neurosurg Psychiatry* 1980;43(08):725–729
- Bloomgarden GM, Byrne TN, Spencer DD, Heafner MD. Meningioma associated with aneurysm and subarachnoid hemorrhage: case report and review of the literature. *Neurosurgery* 1987;20(01):24–26
- Jones NR, Blumbergs PC. Intracranial haemorrhage from meningiomas: a report of five cases. *Br J Neurosurg* 1989;3(06):691–698
- Gruszkiewicz J, Doron Y, Gellei B, Peyser E. Massive intracerebral bleeding due to supratentorial meningioma. *Neurochirurgia (Stuttg)* 1969;12(03):107–111
- Hijjiya N, Hudson MM, Lensing S, et al. Cumulative incidence of secondary neoplasms as a first event after childhood acute lymphoblastic leukemia. *JAMA* 2007;297(11):1207–1215
- Yamanaka R, Hayano A, Kanayama T. Radiation-induced meningiomas: an exhaustive review of the literature. *World Neurosurg* 2017;97:635–644.e8
- Keezer MR, Del Maestro R. Radiation-induced cavernous hemangiomas: case report and literature review. *Can J Neurol Sci* 2009;36(03):303–310
- Chourmouzi D, Papadopoulou E, Kontopoulos A, Drevelegas A. Radiation-induced intracranial meningioma and multiple cavernomas. *BMJ Case Rep* 2013;2013:bcr2013010041

- 23 Jain R, Robertson PL, Gandhi D, Gujar SK, Muraszko KM, Gebarski S. Radiation-induced cavernomas of the brain. *AJNR Am J Neuroradiol* 2005;26(05):1158–1162
- 24 Walch J, Tettenborn B, Weber J, Hundsberger T. Radiation-induced cavernoma after total body irradiation and haematopoietic stem cell transplantation in an adult patient suffering from acute myeloid leukaemia. *Case Rep Neurol* 2013;5(01):91–97
- 25 Larson JJ, Ball WS, Bove KE, Crone KR, Tew JM Jr. Formation of intracerebral cavernous malformations after radiation treatment for central nervous system neoplasia in children. *J Neurosurg* 1998;88(01):51–56