

Blowout Fracture after Descemet's Stripping Automated Endothelial Keratoplasty

Eri Tachibana Shizuka Koh Naoyuki Maeda Kohji Nishida

Department of Ophthalmology, Osaka University Graduate School of Medicine,
Suita, Japan

Key Words

Descemet's stripping automated endothelial keratoplasty · Corneal transplantation · Blowout fracture

Abstract

We present the case of an 86-year-old woman who developed a blowout fracture after Descemet's stripping automated endothelial keratoplasty (DSAEK). Sixteen months after DSAEK, she suffered a blow to her left eye caused by a fall. Computed tomography confirmed the presence of a blowout fracture of the inferior wall of the left orbit with soft tissue prolapsing into the orbit. The patient complained of no abnormal symptoms, and her operated cornea was intact and clear. There was no abnormal finding in both the anterior and posterior segments. This case highlights that the DSAEK technique provides adequate tectonic stability of the globe throughout the traumatic event in contrast to penetrating keratoplasty, which can lead to devastating vision damage after trauma. © 2014 S. Karger AG, Basel

Introduction

Descemet's stripping automated endothelial keratoplasty (DSAEK) is the most popular procedure in endothelial keratoplasty for patients suffering only from corneal endothelial dysfunction. The advantages of DSAEK over penetrating keratoplasty (PK), such as less postoperative astigmatism, faster visual rehabilitation, and avoidance of wound dehiscence or wound infections, can be attributed to a minimally invasive sutureless corneal transplantation technique, which provides better structural integrity for the recipient [1, 2]. Wound dehiscences have been noted to occur secondary to suture removal or trauma [3]. Ocular trauma after PK is one of the postoperative complications which may cause PK graft

Shizuka Koh, MD
Department of Ophthalmology
Osaka University Graduate School of Medicine
Room E7, 2-2 Yamadaoka, Suita, Osaka 565-0871 (Japan)
E-Mail skoh@ophthal.med.osaka-u.ac.jp

dislocation or PK wound dehiscence, possibly leading to serious complications. Ocular trauma after PK has been reported in many previous studies; however, we are unaware of any previous reports of trauma caused by a blow after DSAEK. Here, we describe a case of a blowout fracture in a patient after DSAEK whose cornea survived the injury undamaged.

Case Report

An 86-year-old woman presenting pseudophakic bullous keratopathy in her left eye was referred to our clinic. She had undergone laser iridotomy in both eyes 10 years prior to cataract surgery. The best-corrected visual acuity (BCVA) of her left eye was 20/1,000. A slit-lamp examination of that eye showed diffuse corneal edema with increased corneal thickness (0.629 mm). She underwent uncomplicated DSAEK of her left eye. Sutures were used only to close the sclerocorneal incisions. The postoperative BCVA of her left eye improved to 20/20, and she had an uncomplicated postoperative course. Sixteen months after DSAEK, the patient suffered a blow to her left eye caused by a fall. An urgent head computed tomography scan revealed a blowout fracture of the inferior wall of the left orbit with soft tissue prolapsing into the orbit. Accumulated hemorrhage in the maxillary sinus was also observed (fig. 1). She complained of no symptoms except for a dull pain in her left eye. BCVA of that eye was 20/20, and neither diplopia nor eye movement disorder was observed. On slit-lamp examination, her operated cornea was intact and clear, and there was no abnormal finding in both the anterior and posterior segments (fig. 2a). Imaging with anterior segment optical coherence tomography showed no graft dislocation or detachment of the graft (fig. 2b).

Discussion

A classic blowout fracture involves a sudden, forced increase in intraorbital pressure, which, in turn, causes decompression through an orbital wall fracture. A classic blowout fracture usually saves the eye globe and vision; however, in eyes with surgical wounds, wound dehiscence may easily occur.

Traumatic wound dehiscence after PK is not a rare occurrence and may result in a sight-threatening situation. Many cases of traumatic globe rupture after PK have been previously reported. In a previous literature review [4], the incidence of traumatic dehiscence after keratoplasty was 1.28–5.8%, and the average duration between initial keratoplasty and traumatic globe rupture was 61 ± 50.0 months. Damage to an eye caused by a blow due to a fall after PK frequently occurs in elderly patients and results in poor visual outcome [3, 4]. In the present case, our elderly patient suffered a blunt trauma caused by a fall 16 months after keratoplasty, and in her case this was accompanied by an inferior-blowout fracture.

A previous paper reported that traumatic globe rupture involves the graft-host junction and occurs regardless of the presence of sutures [4]. If our patient had undergone PK instead of DSAEK, wound dehiscence might have occurred, possibly resulting in traumatic PK graft dislocation and globe rupture. However, she underwent DSAEK, a closed-eye surgery which includes smaller wound size and provides more tectonic stability for the eye compared with PK. As a benefit of surgery, her postoperative cornea survived the injury and remained undamaged and intact.

The finding of our case confirms the tectonic stability of the globe after DSAEK, although long-term postoperative data for trauma after DSAEK are lacking because of the limited

history of this procedure. Graft dislocation is the most frequent complication in DSAEK; further complications can be graft failure, rejection, pupillary block, and retinal detachment [2, 5, 6]. Thus, although wound dehiscence-related complications caused by trauma are rare, slight trauma may cause DSAEK graft dislocation during the early postoperative period. However, this does not usually require emergency correction to preserve vision as in a PK case [2]. Careful observation of the graft location is also important after DSAEK.

Disclosure Statement

No author has a financial or proprietary interest in any materials or methods mentioned.

References

- 1 Price FW Jr, Price MO: Descemet's stripping with endothelial keratoplasty in 50 eyes: a refractive neutral corneal transplant. *J Refract Surg* 2005;21:339–345.
- 2 Lee WB, Jacobs DS, Musch DC, Kaufman SC, Reinhart WJ, Shtein RM: Descemet's stripping endothelial keratoplasty: safety and outcomes: a report by the American Academy of Ophthalmology. *Ophthalmology* 2009;116:1818–1830.
- 3 Nagra PK, Hammersmith KM, Rapuano CJ, Laibson PR, Cohen EJ: Wound dehiscence after penetrating keratoplasty. *Cornea* 2006;25:132–135.
- 4 Kawashima M, Kawakita T, Shimmura S, Tsubota K, Shimazaki J: Characteristics of traumatic globe rupture after keratoplasty. *Ophthalmology* 2009;116:2072–2076.
- 5 Price FW Jr, Price MO: Descemet's stripping with endothelial keratoplasty in 200 eyes: early challenges and techniques to enhance donor adherence. *J Cataract Refract Surg* 2006;32:411–418.
- 6 Villarrubia A, Palacin E, Aranguez C, Solana J, Garcia-Alonso CR: Complications after endothelial keratoplasty: three years of experience (in Spanish). *Arch Soc Esp Oftalmol* 2011;86:180–186.

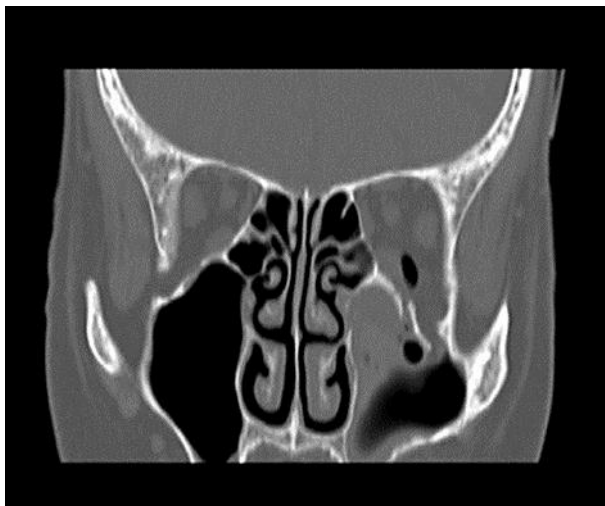

Fig. 1. Head computed tomography image immediately after injury. A blowout fracture of the inferior wall of the left orbit accompanied by soft tissue prolapsing into the orbit is presented. Accumulated hemorrhage in the maxillary sinus is also observed.

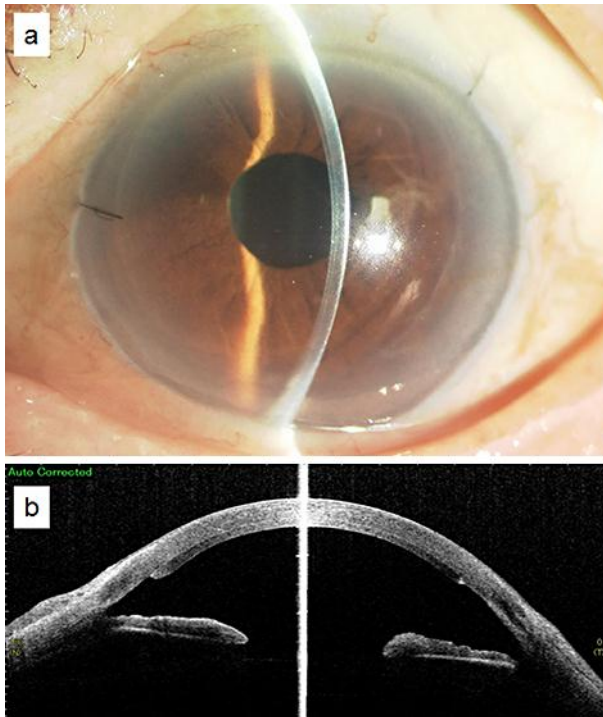


Fig. 2. Slit-lamp image of the left eye after injury. **a** The cornea was intact and clear. No abnormal findings were detected in the ocular surface and anterior segments. **b** An anterior segment optical coherence tomography image shows no graft dislocation or detachment. The sclerocorneal incisions were intact.