

# Endoscopic Laser Surgery for Subglottic Stenosis in Wegener's Granulomatosis

Jacob Shvero,<sup>1</sup> David Shitrit,<sup>2</sup> Rumelia Koren,<sup>3</sup> Dekel Shalomi,<sup>2</sup> and Mordechai Reuven Kramer<sup>2</sup>

<sup>1</sup>Department of Otorhinolaryngology Head & Neck Surgery, <sup>2</sup>Pulmonary Institute and <sup>3</sup>Department of Pathology, Rabin Medical Center, Petah Tikva, and Sackler Faculty of Medicine, Tel Aviv University, Tel Aviv, Israel.

**Purpose:** Wegener's granulomatosis (WG) is a rare multisystem inflammatory disease, which infrequently involves the subglottic area and trachea. Treatment usually involves the use of immunosuppressive agents with corticosteroids. Some patients, however, continue to have symptoms of airway obstruction after clinical remission following the standard therapeutic regimen. **Objective:** To investigate laser treatment for subglottic stenosis in five patients suffering from WG. **Materials and Methods:** We endoscopically treated 5 patients with subglottic stenosis due to WG and airway obstruction by Nd:YAG and CO<sub>2</sub> lasers. One of the patients had preoperative tracheostomy and after treatment was decannulated and could not breathe without dyspnea. Another patient required stenting of the subglottic area. **Results:** All five patients were able to breathe without dyspnea after the treatment. Three patients were treated with an Nd:YAG laser but needed repeated laser treatment every four to six months, whenever they complained of dyspnea. The other two patients were treated with a CO<sub>2</sub> laser; one of these patients had preoperative tracheostomy and was treated twice by CO<sub>2</sub> laser and decannulated, with no further difficulty in breathing. The follow-up period was 1-5 years. **Conclusions:** Nd:YAG and CO<sub>2</sub> lasers are recommended in the treatment of subglottic stenosis (SS) due to WG, particularly when the stenosis is in continuity or close proximity to the vocal cords.

**Key Words:** Subglottic, stenosis, Wegener's granulomatosis, laser, endoscopy

## INTRODUCTION

Wegener's granulomatosis (WG) is a rare multi-

system inflammatory disease of unknown origin, characterized by necrotizing granulomatous inflammation and necrotizing vasculitis of the upper and lower respiratory tract, glomerulonephritis and a variable degree of small vessel vasculitis. Nasal and oral ulceration, epistaxis, sinusitis, or otitis is found in more than 90% of the cases.<sup>1</sup> Ulcers in the larynx and trachea were seen in about a quarter of the cases of WG.<sup>2,3</sup> Subglottic stenosis (SS) is considered to be less common.<sup>3,4</sup> This rare form of the disease (SS due to WG) often responds to medical treatment of cyclophosphamide with or without corticosteroids,<sup>5,6</sup> but when patients continue to complain of respiratory difficulty due to SS, surgical treatment is necessary.<sup>7,8</sup>

There are a wide variety of possible surgical interventions including dilatation, stents, or major open operations, such as laryngofissure with or without skin or mucosal grafts and segmental resection of the stenotic area.<sup>6,9,10</sup>

Research has concentrated on the use of a CO<sub>2</sub> laser for the treatment of SS.<sup>2,11-13</sup>

In this study we report on a series of five patients with subglottic stenosis related to WG, who were treated by endoscopic laser surgery: three with an Nd:YAG laser and two with a CO<sub>2</sub> laser. We also review the literature concerning tracheal reconstruction options for cases of SS due to WG.

## MATERIALS AND METHODS

### Patients

We treated 5 patients (4 female, 1 male) with SS

Received February 13, 2006  
Accepted January 15, 2007

Reprint address: requests to Dr. Jacob Shvero, Department of Otorhinolaryngology Head and Neck Surgery, Rabin Medical Center, Petah Tikva, Israel. Tel: 03-9376451, Fax: 03-5322890, E-mail: asaf890@bezeqint.net

due to WG by laser. The patients' ages ranged between 21 and 83 years, with a mean age of 35.8 years. All patients were positive for complement antineutrophil cytoplasm antibody (c-ANCA) according to blood tests.

The patients were evaluated by CT scan, chest x-ray, and pulmonary function studies. Preoperative fiber optic laryngoscopy and bronchoscopy provided valuable information regarding vocal cord mobility, the extent of the stenosis, and the distance from the vocal cords.

The stenoses were firm, with a granulomatous rim, and extended below the vocal cord 0.5 to 1.5 cm, with an average thickness of 1.7 cm. Computer tomography showed circumferential stenosis causing narrowing of the lumen in the subglottic area in three patients. One patient had a preoperative tracheostomy (Table 1).

All patients were treated by the immunosuppressive agent, cyclophosphamide, with corticosteroids, but they continued to suffer from dyspnea on exertion and stridor. Pulmonary function testing revealed a flattening of the flow-volume loop with inspiration, consistent with an extra-thoracic airway obstruction (Fig. 1).

### Surgical procedure

Direct microlaryngoscopy was performed under general anesthesia in two patients (one required an endotracheal tube and one was anesthetized via a prior tracheostomy). A Storz laser laryngoscope was used to expose the glottic and the subglottic areas. A Zeiss microscope with a 400-mm

objective lens coupled to a CO<sub>2</sub> laser was used in both cases. The laser setting was 10 W in a continuous mode. Moistened neurosurgical pledgets were placed in the subglottic space to protect the trachea and endotracheal tube during excision of the stenotic area in order to reduce the lateral thermal damage of the CO<sub>2</sub> laser.

Three patients underwent bronchoscopy under local anesthesia and an Nd:YAG laser was used with Olympus fiber-optic bronchoscopy.

The laser energies ranged from 2500 to 6000 Joules, applied in a 50 W continuous mode. In one patient, we placed a 12/30 mm wall stent. The

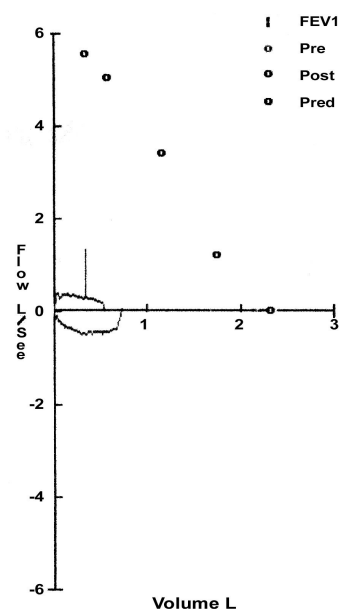


Fig. 1. Preoperative pulmonary function testing.

**Table 1.** Clinical Data of Five Patients with Subglottic Stenosis

No.	Age (yrs)	Sex (M/F)	Nose/Sinus	Tracheostomy		Stenosis		
				Preop.	Postop.	Thickness/cm	Diameter/mm	Distance/cm*
1	29	F	Saddle nose Chronic sinusitis	Yes	No	1	Total	1
2	20	M	Saddle nose Septal perforation	No	No	2	5, circular	1.5
3	25	F	Saddle nose	No	No	3	4, circular	1
4	83	F	-	No	No	1	6, anterior	0.5
5	25	F	-	No	No	1.5	6, anterior	0.5

\*Distance of the stenosis from the vocal cord (cm).

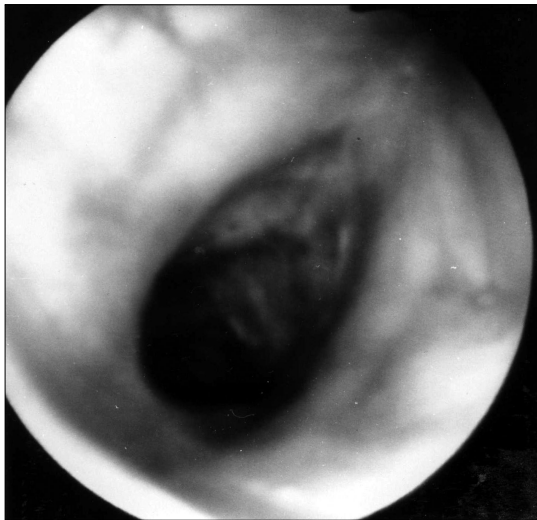

Fig. 2. Tracheoscopic image of preoperative subglottic stenosis.

preoperative SS is shown in Fig. 2. Both the CO<sub>2</sub> and Nd: YAG laser procedures took no longer than 20 minutes.

**RESULTS**

We treated two patients by CO<sub>2</sub> laser because the SS was in close proximity to the vocal cords (within 0.5 - 1 cm). One patient, who had undergone a preoperative tracheostomy, also underwent two interventions with dilatation and the other patient underwent four additional interventions. These patients were in the hospital for only 24 hours after CO<sub>2</sub> laser treatment.

The other three patients were treated by an Nd: YAG laser and underwent 5 - 18 interventions (the SS was between 1 - 1.5 cm below the vocal

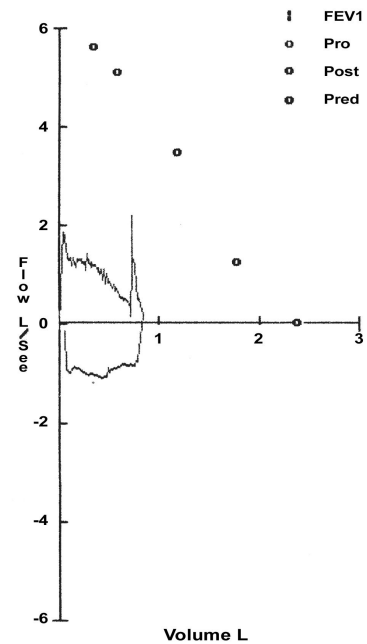


Fig. 3. Postoperative pulmonary function testing.

cords), and these patients were discharged one hour after the procedure. None of the five patients needed emergency tracheostomy. The follow-up period for all of our patients ranged from 1 to 5 years (Table 2).

The resolution of dyspnea on exertion or decannulation was the criteria for success.

Four patients had no dyspnea during the follow-up period. The fifth patient needed repeated intervention after two and three months because of episodes of dyspnea on exertion, and this patient ultimately required an SS stent. The SS in this patient had an opening diameter of 4 mm. The stenotic segment was short and had soft

Table 2. Laser Treatment and Follow-up

No.	CO <sub>2</sub> laser	Nd: YAG laser	Interventions (n)	Outcome	Follow-up/months
1	Yes + dilatation	-	2	Decannulated	12
2	-	Yes	10	Favorable	60
3	-	Yes	18	Favorable	6
4	-	Yes	5	Favorable	24
5	Yes	-	4*	Favorable	6

\*stent.

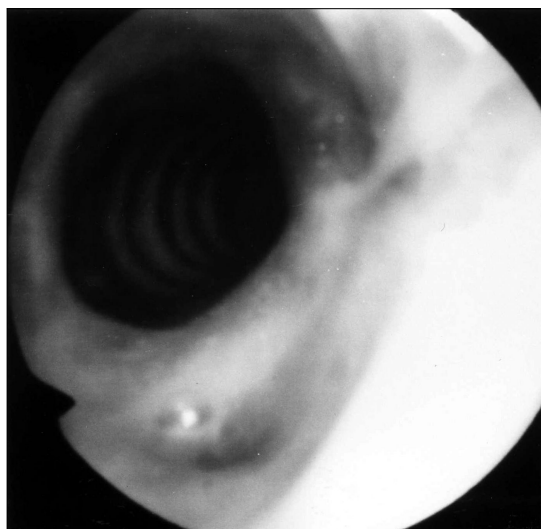

Fig. 4. Tracheoscopic image of postoperative subglottic stenosis.

tissue. Another patient who had preoperative tracheostomy was decannulated after two interventions by CO<sub>2</sub> laser.

There was no voice disturbance after treatment in our patients. Postoperative pulmonary function testing showed an improvement (Fig. 3). Fig. 4 shows the postoperative results after laser treatment.

### Histological examination

All specimens were fixed in 10% buffered formalin, embedded in paraffin, and stained with haematoxylin and eosin. The biopsies demonstrated focal acute necrosis surrounded by a zone of fibroblastic proliferation with giant cells and leukocytic infiltrate. The vasculitis affected small arteries and veins. These granulomatous inflammatory changes were consistent with the diagnosis of WG.

### DISCUSSION

SS occurs in nearly 16 to 23% of patients with WG.<sup>1,4,14</sup> Significant SS is defined as the presence of symptomatic airway compromise, usually consisting of dyspnea, voice changes, or cough. For unknown reasons, SS is more common in young

patients. The clinical course of SS generally runs independently of systemic WG activity.<sup>14</sup> Patients with WG are at great risk for severe airway obstruction, which can rapidly run a fatal course if not treated.<sup>15</sup> In the absence of other features of acute WG, isolated SS is optimally managed with intratracheal laser treatment and does not require systemic therapy; this is the best approach in cases, such as our patients, where SS is in close proximity to or in continuity with the vocal cords.

A CO<sub>2</sub> laser emits an invisible beam of light at 10.6  $\mu\text{m}$ , which is selectively absorbed by water. The CO<sub>2</sub> laser has distinct advantages over conventional steel knives. It seals blood vessels less than 0.5 mm in diameter, resulting in superior haemostasis, and it can be used in ablation mode for vaporizing tissue and for incisions. Therefore, this method is frequently used for micro-laryngeal surgery. However, a major disadvantage of the CO<sub>2</sub> laser is that fiber-optic transmission is not possible. The ultra spot micromanipulator delivery system allows a spot size of 200  $\mu\text{m}$ , at a 400-mm focal distance.

The Nd:YAG laser, which is an excellent photo coagulator and can be transmitted through fiber-optic cables, emits a beam of light at 1.06  $\mu\text{m}$ . The Nd:YAG laser utilizes a 220-V energizer and needs an exterior cooling device, is less precise, having a 20 to 40% scatter, and its beam of light penetrates deeply and is absorbed by water. The Nd:YAG laser can also cause edema and scarring. Because of its excellent ability to evaporate and coagulate, it is used as surgical intervention for obstructive lesions in the tracheobronchial area.<sup>6</sup>

In 1984, Dedo et al.<sup>2</sup> described a new technique for the treatment of posterior glottic, subglottic, and tracheal stenosis with a CO<sub>2</sub> laser and microtrapdoor mucosal flap. Nine of the ten patients in their study were given an adequate airway and good voice. In 1979, Strong et al.<sup>13</sup> presented a study involving 18 patients with glottic or subglottic partial or total stenosis. Using a laser, they successfully treated 4/7 and 8/11 SS cases. Six of the latter also had temporary placement of Silastic<sup>®</sup> roll stents. Lebovics et al.<sup>12</sup> described 8 out of 25 cases of CO<sub>2</sub> laser Treatment, and they reported that subglottic scarring recurred rapidly and was more extensive after each laser procedure. All 8 of their patients

ultimately required other therapies to adequately manage the stenosis.

In 2003, Gluth et al.<sup>14</sup> described their experience in repairing SS in WG and recommended minimizing the airway manipulation during episodes of systemic disease activity. Once the disease process is under control, consideration can then be given to either an endoscopic or an open approach based on the extent of stenosis. Either laryngotracheal reconstruction or CO<sub>2</sub> laser resection and dilation can be safely used to produce a favorable outcome.

Alternative approaches that minimize the frequency of episodes of recurrent disease, such as trimethoprim-sulfamethoxazole therapy, are currently under investigation.<sup>14,16</sup>

SS at the level of the cricoids cartilage and/or upper tracheal rings present a management dilemma<sup>12</sup> as the stenosis is in close proximity to the vocal cords. In these cases, laser treatment should be used to preserve the quality of the voice as any other open surgery might damage the vocal cords. In patients, especially young patients, with SS in close proximity or in continuity with the vocal cords, if the patient complains of dyspnea, repeated laser intervention is preferred over permanent tracheostomy or laryngotracheal resection.

Our patients were diagnosed with WG by a positive c-ANCA blood test and by histological examination. For treatment, we used CO<sub>2</sub> laser for two patients with SS close to the vocal cords (0.5-1 cm) since the Nd:YAG laser can penetrate deeply, causing edema and scarring that would affect the quality of the voice. The Nd:YAG laser was used in the other three patients with SS located far from the vocal cords (1 - 1.5 cm). The Nd:Yag laser is preferred over the CO<sub>2</sub> laser when the SS is near the upper trachea and because it can be done under local anesthesia and allows for multiple interventions.

As a result of our study, we recommend laser treatment for treatment of SS for the following reasons: it requires a short surgical intervention (no longer than 20 minutes) and short hospitalization; there is no bleeding and no scarification of the recurrent nerve; laser treatment can be done without tracheostomy; it does not produce cosmetic defects in the neck skin; it is suitable for

high risk patients; it can be performed if the SS is in close proximity or in continuity with the vocal cords; and it produces favorable results. In cases where endoscopic treatment by laser has failed, we suggest performing laryngotracheal resection with reconstruction.

## REFERENCES

- O'Devaney K, Ferlito A, Hunter BC, Devaney SL, Rinaldo A. Wegener's granulomatosis of the head and neck. *Ann Otol Rhinol Laryngol* 1998;107:439-45.
- Dedo HH, Sooy CD. Endoscopic laser repair of posterior glottic, subglottic and tracheal stenosis by division or micro-trapdoor flap. *Laryngoscope* 1984;94:445-50.
- Walton EW. Giant-cell granuloma of the respiratory tract (Wegener's granulomatosis). *Br Med J* 1958;34:265-70.
- DeRemee RA, McDonald TJ, Harrison EG, Coles DT. Wegener's granulomatosis. Anatomic correlates, a proposed classification. *Mayo Clin Proc* 1976;51:777-81.
- Arauz JC, Fonseca R. Wegener's granulomatosis appearing initially in the trachea. *Ann Otol Rhinol Laryngol* 1982;91:593-6.
- McDonald TJ, Neel HB 3rd, DeRemee RA. Wegener's granulomatosis of the subglottis and the upper portion of the trachea. *Ann Otol Rhinol Laryngol* 1982;91:588-92.
- Alaani A, Hogg RP, Drake Lee AB. Wegener's granulomatosis and subglottic stenosis: management of the airway. *J Laryngol Otol* 2004;118:786-90.
- Nishiike S, Kato T, Nagai M, Konishi M, Sakata Y. Management and follow-up of localized Wegener's granulomatosis: a review of five cases. *Acta Otolaryngol* 2004;124:1103-8.
- Eliachar I, Chan J, Akst L. New approaches to the management of subglottic stenosis in Wegener's granulomatosis. *Cleve Clin J Med* 2002;69 Suppl 2:SII149-51.
- Herridge MS, Pearson FG, Downey GP. Subglottic stenosis complicating Wegener's granulomatosis: surgical repair as a viable treatment option. *J Thorac Cardiovasc Surg* 1996;111:961-6.
- Crockett DM, Reynolds BN. Laryngeal laser surgery. *Otolaryngol Clin North Am* 1990;23:49-66.
- Lebovics RS, Hoffman GS, Leavitt RY, Kerr GS, Travis WD, Kammerer W, et al. The management of subglottic stenosis in patients with Wegener's granulomatosis. *Laryngoscope* 1992;102:1341-5.
- Strong MS, Healy GB, Vaughan CW, Fried MP, Shapshay S. Endoscopic management of laryngeal stenosis. *Otolaryngol Clin North Am* 1979;12:797-805.
- Gluth MB, Shinnars PA, Kasperbauer JL. Subglottic stenosis associated with Wegener's granulomatosis. *Laryngoscope* 2003;113:1304-7.

15. Utzig MJ, Warzelhan J, Wertz H, Berwanger I, Hasse J. Role of thoracic surgery and interventional bronchoscopy in Wegener's granulomatosis. *Ann Thorac Surg* 2002;74:1948-52.
16. Stegeman CA, Tervaert JW, de Jong PE, Kallenberg CG. Trimethoprim-sulfamethoxazole (co-trimoxazole) for the prevention of relapses of Wegener's granulomatosis. Dutch Co-Trimoxazole Wegener Study Group. *N Engl J Med* 1996;335:16-20.