

Handheld Retinal Oximetry in Healthy Young Adults

Wouter Vehmeijer¹, Sveinn Hakon Hardarson², Kelly Jonkman⁴, Leon Aarts⁴, Albert Dahan⁴, Einar Stefánsson³, and Nicoline Schalij-Delfos¹

¹ Department of Ophthalmology, Leiden University Medical Center, Leiden, The Netherlands

² Department of Physiology, University of Iceland, Reykjavik, Iceland

³ Department of Ophthalmology, Landspítali, Reykjavik, Iceland

⁴ Department of Anesthesiology, Leiden University Medical Center, Leiden, The Netherlands

Correspondence: Nicoline Schalij-Delfos, Albinusdreef 2, 2300 RC Leiden, The Netherlands. e-mail: n.e.schalij-delfos@lumc.nl

Received: 18 December 2017

Accepted: 19 June 2018

Published: 27 August 2018

Keywords: retinal oximetry; handheld oximetry; dual-wavelength oximetry

Citation: Vehmeijer W, Hardarson SH, Jonkman K, Aarts L, Dahan A, Stefánsson E, Schalij-Delfos N. Handheld retinal oximetry in healthy young adults. *Trans Vis Sci Tech.* 2018;7(4):19. <https://doi.org/10.1167/tvst.7.4.19>
Copyright 2018 The Authors

Purpose: The objective of this study was to measure the relative retinal oxygen saturation with a prototype, mobile handheld oximeter in upright and supine position and to compare these measurements to the gold standard Oxymap T1 retinal oximeter in upright position. A handheld oximeter is needed for measurements of infants with retinopathy of prematurity as well as acutely injured and bedridden adults.

Methods: Healthy volunteers (age 18–35) were recruited at the Leiden University Medical Center. Retinal images were acquired with the handheld oximeter and the Oxymap T1. Both cameras are dual-wavelength oximeters and acquire images with wavelengths of 570 and 600 nm. Retinal oxygen saturation values were determined for both the handheld camera and the Oxymap T1.

Results: Twenty-one subjects (age 25 ± 2 years) were included. In upright position, the oxygen saturation for the arterioles was $92.2\% \pm 4.9\%$ vs. $95.5\% \pm 4.2\%$ and for the venules $57.9\% \pm 10.2\%$ vs. $57.7\% \pm 6.4\%$ for the handheld camera and Oxymap T1, respectively. The oxygen saturation was higher in the arterioles than the venules for both cameras ($P < 0.05$). In supine position, measured with the handheld oximeter, the oxygen saturation in the arterioles was $92.3\% \pm 5.8\%$ and $59.2\% \pm 6.1\%$ in the venules.

Conclusions: Performance of the prototype, mobile handheld oximeter Corimap camera compares well with the Oxymap T1, with a slightly larger standard deviation in oxygen saturation measurements, both in upright and supine patients.

Translation Relevance: To date, to our knowledge, no oximeters are available for handheld use and for measurement in supine position in infants and bedridden adults. Here we tested such an oximeter and show that its performance compares well with that of the gold standard Oxymap T1 in healthy adults.

Introduction

Oxygen plays a pivotal role in the pathogenesis of various retinal diseases, especially in retinal disease with ischemic pathophysiology. Retinal ischemia may cause neovascularization and edema, resulting in decreased vision or even blindness. Better understanding of retinal oxygen metabolism could be crucial for management of retinal ischemic disease.

In 1959 Hickam et al.¹ were the first to develop a technique for the measurement of relative oxygen saturation of the retinal vessels. The development of

this retinal oximetry technique has been extensively described by Beach.² Retinal oximeters measure the relative oxygen saturation in the retinal vessels by using the difference of light absorbance of oxyhemoglobin and deoxyhemoglobin. Currently, two retinal oximeters are commercially available, the Imedos oximeter (Imedos Systems UG, Jena, Germany) and the Oxymap T1 (Oxymap ehf., Reykjavik, Iceland). Both are conventional fundus camera–based systems and acquire two fundus images simultaneously with two wavelengths of light. One wavelength is sensitive to the changes in oxygen saturation of the retinal

vessels, while the second wavelength (isosbestic) is not. The Oxymap T1 has been used in many studies to increase knowledge of oxygen metabolism in various retinal diseases such as diabetic retinopathy,³ age-related macular degeneration,⁴ central retinal vein occlusion,⁵ retinitis pigmentosa,⁶ and glaucoma.⁷⁻⁹

Until now, retinal oximetry has been applicable to patients who can be positioned at a fundus camera in an upright position with their head in a chinrest. Hence, it cannot be used in young children nor in bedridden patients. However, retinal oximetry could be useful in the pediatric population. Premature infants born before 32 weeks gestational age are at risk of developing vision-threatening retinopathy of prematurity (ROP). Oxygen plays a pivotal role in the pathophysiology of ROP. However, the retinal images provided by the currently available mobile handheld cameras do not give insight in oxygen levels of metabolism of the developing retina and the distribution of oxygen in ROP. Oxygen saturation measurements in the retina can be beneficial for monitoring and management of ROP.

The applicability of oximetry in young infants was first demonstrated by Vehmeijer et al.¹⁰ using a scanning laser ophthalmoscope (SLO) (Optomap 200Tx; Optos, Dunfermline, Scotland, UK) and modified Oxymap Analyzer software (version 2.5.1; Oxymap ehf.).¹⁰ An SLO had previously been used for widefield imaging of the premature infants with ROP.¹¹ However, the SLO is not practical for bedside use in the neonatology department. A handheld mobile camera would be preferred for imaging a pediatric population. Beyond infants and newborns, such a camera would broaden the applicability of retinal oximetry to supine patients, such as trauma patients.

The Compact Retina Mapper (Corimap) camera (Demcon Focal B.V., Enschede, The Netherlands) was developed according to the dual-wavelength principle, similar to the Oxymap T1.¹² This study describes the setup of the handheld Corimap camera. The objective of this study was the validation of the Corimap camera and its comparison to the gold standard Oxymap T1 regarding oxygen saturation measurement in a healthy adult population. In addition, a comparison is made with the Corimap camera in both upright and supine position.

Methods

The study was approved by the Medical Ethical Review Committee of the Leiden University Medical

Center, The Netherlands, and adhered to the tenets of the Declaration of Helsinki. All subjects of the study provided written informed consent before participation in the study.

Healthy subjects aged between 18 and 35 years were recruited at the Leiden University Medical Center. The exclusion criteria were any ocular opacity; refraction error larger than ± 6 diopters or a cylindrical error of >1.5 diopters; a history of ocular disease; a history of systemic disease, which could affect the eye or oxygen levels; and familial history of glaucoma. Participants underwent an ophthalmological examination, and one eye was randomly selected for the study. The pupil was dilated to investigate the eye before final inclusion in this study.

The study population consisted of 21 healthy Caucasian participants (14 female) with a mean age of 25 ± 2 years (mean \pm SD) and a median Snellen visual acuity of 1.2 (range 1.0–1.2) with a spherical equivalent for the right eye -0.86 ± 1.72 and for the left eye -1.17 ± 1.83 . The mean intraocular pressure of the participants was for the right eye 13.6 ± 2.5 mm Hg and for the left eye 14.7 ± 2.7 mm Hg (Full Auto Tonometer TX-F; Canon, Tokyo, Japan).

For this study, a comparison was made between the Oxymap T1 and the Corimap camera (Demcon Focal B.V.). Both cameras use a dual-wavelength principle for retinal oximetry, which is based on the difference of light absorbance of oxyhemoglobin and deoxyhemoglobin. Therefore, two images are simultaneously captured in two different wavelengths of light (570 and 600 nm).

The current Oxymap T1 is composed of two digital cameras, a custom optical adapter, 1600×1200 square pixels (Insight IN1800; Diagnostic Instruments Inc., Sterling Heights, MI) and an image splitter as an addition to a fundus camera (Topcon TRC-50DX; Topcon Corp., Tokyo, Japan). The custom-built Corimap camera (Fig. 1) is composed of two digital cameras (Camelion 3; Point Grey Research, Richmond, BC, Canada) with a mono charge-coupled device sensor, resolution 1928×1448 (Sony ICX818; Sony Corp., Tokyo, Japan) for the simultaneous capturing of two images in both wavelengths. For the alignment of the retina, the Corimap camera uses near-infrared light. According to the dual-wavelength principle, the Corimap camera uses two xenon flashes separated for both wavelengths. To filter the correct wavelengths, the Corimap camera utilizes filters for 570 and 600 nm with a half maximum bandwidth of 6 nm (Chroma Technology Corp., Bellows Falls,

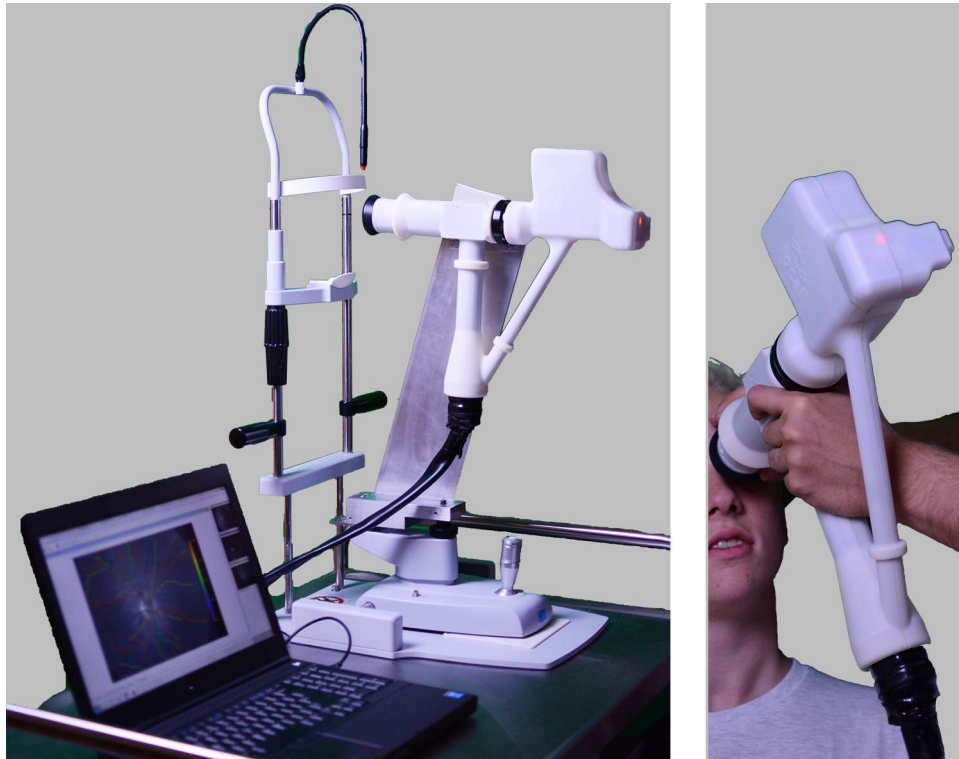


Figure 1. (Left) The Corimap camera setup mounted to the chinrest and a mobile cart for transportation within the hospital. (Right) The Corimap camera in the handheld mode.

Vermont). The three light sources (two xenon flashes and the near-infrared light sources) are built into the light box. The camera unit is connected through 12 glass fiber cables (POF, CK-60; Mitsubishi Rayon Co., Ltd., Tokyo, Japan) to the lightbox. The glass fibers are positioned in a ring formation and separated for the three light sources. The Corimap camera is a noncontact camera and can be used mounted to a chinrest or in handheld mode.

Study Procedure

Images of the retina with the optic disk in the center of the frame were obtained with both cameras, in random order, while the subjects were in an upright position. Images, which were out of focus or off center, were discarded, and additional images were obtained. This procedure was repeated with the handheld Corimap camera while the subjects were in supine position.

All images were analyzed with a modified version of the Oxymap Analyzer software. Measurements were taken in a predefined, standardized area between two circles, the first circle being 3 times and the second circle being 1.5 times the size of the optic disc.

For each of the participants, the three best images per camera per condition (three images for the Oxymap T1, three for the Corimap camera in upright position, and three images for the Corimap camera in supine position) were selected, based on the image-grading tool within the Oxymap Analysis software and the expertise of the researcher.

Image Analysis

The optical density ratio (ODR) was obtained through the standardized Oxymap T1 analysis protocol for images from both cameras.¹³ Two comparisons were made, that is, comparison of average retinal ODR and comparison of the main superotemporal vessel pair.¹³ Figure 2 shows images acquired from one subject with both cameras. The relative oxygen saturation can be calculated with the equation

$$SatO_2 = (a \cdot ODR + b) \cdot 100\%.$$

In order to obtain the calibration factors for the Corimap camera, the mean ODR of the images of the included subjects with the highest quality was matched to oxygen saturation values found in a separate study by Schweitzer et al.¹⁴

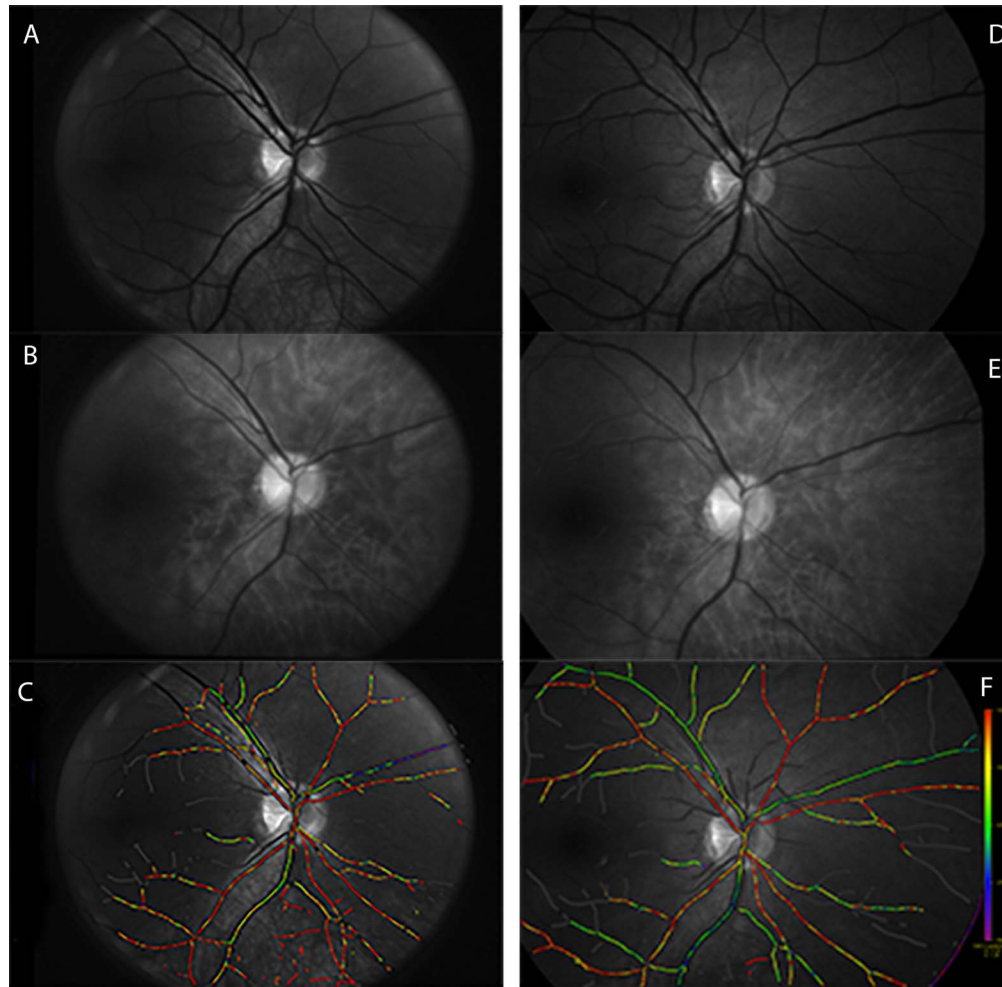


Figure 2. Oximetry fundus images from one subject from the Corimap camera (A–C) and the Oxymap T1 (D–E). A + D show images at wavelength 570 nm. B + E show similar images for the 600-nm wavelength. C + F show the 570-nm images with the relative oxygen saturation calculated by the Oxymap Analyzer software.

Statistical Analysis

Statistical analysis was performed using software (SPSS Statistics release 23.0.0.0; IBM Corp., Armonk, NY). A P value < 0.05 was considered statistically significant. A paired t -test was used for determining statistical difference for ODR and oxygen saturation between arterioles and venules within subjects. For the repeatability of measurements, ANOVA was used to separate variability between subjects and variability between repeated measurements of the same eye. The performance of the Corimap camera was compared to performance of the Oxymap T1 while the subjects were in upright position, since the Oxymap T1 is the current standard of retinal oximetry. The level of agreement between both cameras was determined by a Bland-Altman plots. Additionally, the measurements of the Corimap

camera in upright position were also compared to the supine position. In supine position, the Corimap camera was used in handheld mode.

Results

The retinal images for analysis were selected out of the total set of images taken of the subjects for each camera and position. For the Oxymap T1, a mean of 9 ± 2 images were captured, and for the Corimap camera in upright position, 13 ± 4 images, and in supine position, 15 ± 5 images were captured.

For the first part of the ODR analysis, the standardized protocol of Oxymap was used to analyze the vessel segments in proximity to the optic disk in all four quadrants, resulting in a mean value for all major retinal vessels. In the second analysis, a single vessel

Table 1. ODR and Retinal Saturation, Mean \pm Standard Deviation

	Corimap Camera, Upright		Oxymap T1		Corimap Camera, Supine	
	Arterioles	Venules	Arterioles	Venules	Arterioles	Venules
ODR						
Mean retinal analysis	0.205 \pm 0.044	0.515 \pm 0.092	0.213 \pm 0.037	0.516 \pm 0.051	0.204 \pm 0.053	0.487 \pm 0.101
Single segment analysis	0.311 \pm 0.075	0.562 \pm 0.096	0.254 \pm 0.042	0.543 \pm 0.060	0.297 \pm 0.077	0.553 \pm 0.099
Saturation						
Mean retinal analysis	92.2% \pm 4.9%	57.9% \pm 10.2%	95.5% \pm 4.2%	59.2% \pm 6.1%	92.3% \pm 5.8%	61.0% \pm 11.2%
Single segment analysis	80.5% \pm 8.3%	52.7% \pm 10.6%	91.4% \pm 4.8%	57.7% \pm 6.4%	82.0% \pm 8.5%	53.7% \pm 11.0%

* Superotemporal pair ($n=19$), two subjects were excluded due to intertwined vessel.

** All paired t -tests between arterioles and venules had a P value < 0.0001 .

segment (superotemporal vessel pair) was selected.¹³ The results of ODR measurements are reported in Table 1. A significant difference between the arterioles and the venules of $P < 0.001$ was found with both cameras and with both analyses (i.e., for mean ODR and single vessel pair). There is no significant difference in ODR measurements between both cameras. The Bland-Altman plots in Figure 3 shows the level of agreement between the Oxymap T1 and the Corimap camera.

Calibration

Using a calibrated device, Schweitzer et al.¹⁴ found a saturation of 97.2% in the arterioles and a saturation of 57.9% for venules in a healthy population. The ODR measurements with the Corimap of the arterioles and venules in the upright position were matched to the saturation values found in the study by Schweitzer et al.,¹⁴ allowing for the calculation of the calibration factor for the Corimap camera.

$$SatO_2 = (a \cdot ODR + b) \cdot 100\%. \quad (1)$$

$$92.2\% = (a \cdot 0.205 + b) \cdot 100\%. \quad (2)$$

$$57.9\% = (a \cdot 0.515 + b) \cdot 100\%. \quad (3)$$

Based on these equations, the calibration factors for the Corimap camera are $a = -1.1065$, and $b = 1.1488$. For the Oxymap T1, the calibration factors

used were the same as those recommended by the manufacturer, $a = -1.28$ and $b = 1.24$. After calibration, Equation 1 can be used to calculate relative oxygen saturation values. The mean retinal saturation values for the Oxymap T1 were 95.5% \pm 4.2% for arterioles and 59.2% \pm 6.1% for venules. For the Corimap camera in upright position, the saturation for the arterioles was 92.2% \pm 4.8% and for venules 57.9% \pm 10.2% (means set to 92.2% and 57.9% with calibration). Corresponding values for the supine position were 92.3% \pm 5.8% for arterioles and 61.0% \pm 11.2% for the venules. Detailed information on the ODR and calculated oxygen saturation are presented in Table 1.

Repeatability

The selected three retinal images per subject were analyzed for repeatability. Results are displayed in Table 2. For both the mean retinal as well as the single vessel pair segment analysis, the repeated measurements show no significant difference ($P > 0.05$) between cameras and position.

Discussion

The handheld mobile prototype oximeter compares well with the Oxymap T1 oximeter. It provides repeatable and reliable oxygen saturation measurements in retinal vessels in upright and supine

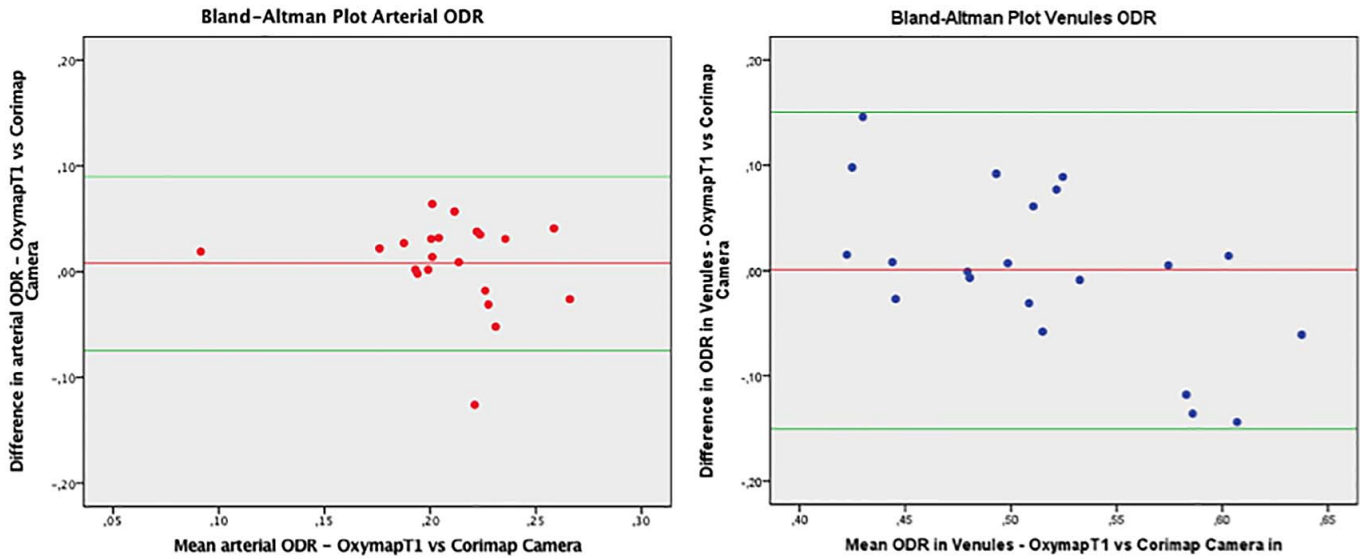


Figure 3. Bland-Altman plot for ODR measured for the Oxymap T1 and the Corimap camera.

positions. This prototype has been developed for use in a pediatric population as well as for bedridden adults.

The handheld oximeter measures a significant difference in oxygen saturation between retinal arterioles and venules. The measurements of the Corimap are comparable to the Oxymap T1 camera, both in the mounted and the handheld mode. The prototype can reliably measure the retinal oxygenation, thereby expanding the scope of retinal oximetry to supine and pediatric patient populations, which could add to the knowledge of retinal diseases such as ROP.¹⁵

The standard deviation of the repeated measurements of the mean retinal oxygen saturation is currently slightly worse in the handheld Corimap camera compared to the Oxymap T1. The measurement of the single superotemporal vessel pair shows a larger variability in both cameras. These results are shown in Table 2. In the early development of a prototype of the Oxymap T1 oximeter, Hardarson et al.¹⁶ reported a standard deviation between repeated saturation measurements of single vessels of 3.7% for the arterioles and 5.3% for the venules. Subsequently,

Palsson et al.¹³ reported standard deviations between repeated measurements of mean saturation with the Oxymap T1 of 0.8% for the arterioles and 1.3% for the venules. For the Imedos camera, the standard deviations of the repeated measurements for vessel segments were reported by Hammer et al.¹⁷ to be 2.5% for the arterioles and 3.25% for venules. The standard deviations found in this study are comparable to those found in earlier prototypes of Oxymap T1, thus implicating that these deviations are acceptable at this stage. Good repeatability of the Oxymap T1 means that it can be used to detect small differences (e.g., two to four percentage points) between relatively small groups of subjects (e.g., 20 subjects per group, depends on several factors). Slightly worse repeatability of the Corimap camera means that it has less chance than the Oxymap T1 of detecting a difference between groups.

The Corimap camera also required a higher number of attempts to obtain three good-quality images. This is to be expected, since a handheld camera is likely to be more difficult to operate than a full-size fundus camera. Improvements of ergonomics in the Corimap could be made to address this issue.

Table 2. Standard Deviation Between Repeated Images (Saturation Percentages)

	Corimap Camera, Upright		Oxymap T1		Corimap Camera, Supine	
	Arterioles	Venules	Arterioles	Venules	Arterioles	Venules
Mean retinal analysis	1.9%	3.8%	1.6%	2.9%	2.6%	4.1%
Single vessel segment analysis*	3.0%	5.8%	3.4%	5.3%	5.3%	8.9%

* Superotemporal pair ($n = 19$), two subjects were excluded due to intertwined vessel.

The measured repeatability for the Oxymap T1 was worse in this experiment than in the experiment by Palsson et al.¹³ The reason for this is unclear. Other researchers have found good repeatability with the Oxymap T1, although the different statistical approach does not allow direct comparison with the current study.^{18,19}

An explanation for the difference between the handheld Corimap camera and the Oxymap T1 is the light used to focus and align the camera with the retina. The Oxymap T1 uses continuous white light, whereas the Corimap camera uses near-infrared light. This results in a limited amount of light exposure to the retina with the Corimap. Furthermore, the light distribution at the retina differs from the Oxymap T1 due to the glass fiber configuration for the handheld purpose of the Corimap camera. The illumination of the retina works through a ring of 12 glass fibers separated for the three light sources of the Corimap camera. This may influence the homogeneous illumination of the retina, which might interfere with some measurements and be reflected in the single vessel segment analysis of the Corimap camera.

Additionally, a contributing factor to the larger standard deviations of the Corimap camera might be that the saturation values for the Oxymap T1 are corrected by the Oxymap Analyzer software for vessel diameter, whereas those for the Corimap camera are derived directly from the ODR values.¹² Software modifications can improve the measurements of the Corimap camera, similar to adaptation previously performed in the precursors of the Oxymap T1. Finally, the Corimap camera uses polarized light to capture the retinal images, thereby minimizing the central light reflection of the vessels in contrast to the conventional fundus photography. This can also affect the measurements of the ODR for the Corimap camera in comparison to the Oxymap T1. The Corimap camera has been proven to be a reliable system for the measurements of oxygen saturation. However, refinements, such as improved ergonomics and software optimization, can be accomplished for even better performance in the future.

A retinal oximeter suitable for supine use in pediatric and neonatal ophthalmological care is warranted because oxygen plays a pivotal role in several serious retinal diseases, such as ROP. It may be beneficial to closely monitor the saturation levels within the retinal vessels, as changes in oxygen saturation may be a predictor for the development and progression of disease. This current prototype camera is also able to adequately measure the relative

oxygen saturation in the retinal vessels in adults in a supine position. Due to the foreseen use in a pediatric population, especially in preterm neonates, an advantage of the Corimap camera compared to conventional cameras is that the Corimap camera is a noncontact camera. Furthermore, the use of near-infrared alignment and two short simultaneous flashes instead of continuous white light exposure might be less of a burden for the children than conventional retinal photography. In addition, the use of infrared alignment and minimal light exposure can be of value for imaging of ocular diseases in which severe photophobia plays an important role, such as certain rod-cone dystrophies or in patients with *ABCA4*-associated mutations.

In conclusion, to our knowledge, this is the first mobile, retinal oximeter that can be used in a handheld mode, providing many opportunities for future research. This Corimap camera has been proven reliable for the measurement of retinal oxygenation and is comparable to the current standard Oxymap T1 retinal oximeter. The Corimap camera has been validated in both mounted and handheld mode for use in upright and supine patient positions. This, in addition to the mobility of the Corimap camera, broadens the applicability of retinal oximetry.

Acknowledgments

This study was supported by the ODAS Foundation (nonprofit), The Netherlands.

Disclosure: **W. Vehmeijer**, None; **S.H. Hardarson**, Oxymap ehf. (C,I,P); **K. Jonkman**, None; **L. Aarts**, None; **A. Dahan**, None; **E. Stefánsson**, Oxymap ehf. (I,S,P); **N. Schalijs-Delfos**, None

References

1. Hickam JB, Sieker HO, Frayser R. Studies of retinal circulation and A-V oxygen difference in man. *Trans Am Clin Climatol Assoc.* 1959;71:34–44.
2. Beach J. Pathway to retinal oximetry. *Trans Vis Sci Tech.* 2014;3:2.
3. Hardarson SH, Stefánsson E. Retinal oxygen saturation is altered in diabetic retinopathy. *Br J Ophthalmol.* 2012;96:560–563.

4. Geirsdottir A, Hardarson SH, Olafsdottir OB, Stefansson E. Retinal oxygen metabolism in exudative age-related macular degeneration. *Acta Ophthalmol.* 2014;92:27–33.
5. Hardarson SH, Stefansson E. Oxygen saturation in central retinal vein occlusion. *Am J Ophthalmol.* 2010;150:871–875.
6. Eysteinnsson T, Hardarson SH, Bragason D, Stefansson E. Retinal vessel oxygen saturation and vessel diameter in retinitis pigmentosa. *Acta Ophthalmol.* 2014;92:449–453.
7. Vandewalle E, Abegao Pinto L, Olafsdottir OB, et al. Oximetry in glaucoma: correlation of metabolic change with structural and functional damage. *Acta Ophthalmol.* 2014;92:105–110.
8. Olafsdottir OB, Hardarson SH, Gottfredsdottir MS, Harris A, Stefansson E. Retinal oximetry in primary open-angle glaucoma. *Invest Ophthalmol Vis Sci.* 2011;52:6409–6413.
9. Olafsdottir OB, Vandewalle E, Abegao Pinto L, et al. Retinal oxygen metabolism in healthy subjects and glaucoma patients. *Br J Ophthalmol.* 2014;98:329–333.
10. Vehmeijer WB, Magnusdottir V, Eliasdottir TS, Hardarson SH, Schalijs-Delfos NE, Stefansson E. Retinal oximetry with scanning laser ophthalmoscope in infants. *PloS One.* 2016;11:e0148077.
11. Patel CK, Fung TH, Muqit MM, et al. Non-contact ultra-widefield imaging of retinopathy of prematurity using the Optos dual wavelength scanning laser ophthalmoscope. *Eye (Lond).* 2013;27:589–596.
12. Geirsdottir A, Palsson O, Hardarson SH, Olafsdottir OB, Kristjansdottir JV, Stefansson E. Retinal vessel oxygen saturation in healthy individuals. *Invest Ophthalmol Vis Sci.* 2012;53:5433–5442.
13. Palsson O, Geirsdottir A, Hardarson SH, Olafsdottir OB, Kristjansdottir JV, Stefansson E. Retinal oximetry images must be standardized: a methodological analysis. *Invest Ophthalmol Vis Sci.* 2012;53:1729–1733.
14. Schweitzer D, Hammer M, Kraft J, Thamm E, Konigsdorffer E, Strobel J. In vivo measurement of the oxygen saturation of retinal vessels in healthy volunteers. *IEEE Trans Biomed Eng.* 1999;46:1454–1465.
15. Stefansson E. How to prevent retinopathy of prematurity. *Acta Ophthalmol.* 2011;89:3–4.
16. Hardarson SH, Harris A, Karlsson RA, et al. Automatic retinal oximetry. *Invest Ophthalmol Vis Sci.* 2006;47:5011–5016.
17. Hammer M, Vilser W, Riemer T, Schweitzer D. Retinal vessel oximetry-calibration, compensation for vessel diameter and fundus pigmentation, and reproducibility. *J Biomed Opt.* 2008;13:054015.
18. Yip W, Siantar R, Perera SA, et al. Reliability and determinants of retinal vessel oximetry measurements in healthy eyes. *Invest Ophthalmol Vis Sci.* 2014;55:7104–7110.
19. Goharian I, Iverson SM, Ruiz RC, Kishor K, Greenfield DS, Sehi M. Reproducibility of retinal oxygen saturation in normal and treated glaucomatous eyes. *Br J Ophthalmol.* 2015;99:318–322.