

Retrieval of a transcatheter pacemaker in sheep after a mid-term implantation time



Maria Grazia Bongiorni, MD,^{*} Luca Segreti, MD,^{*} Andrea Di Cori, MD,^{*} Matthew Bonner, PhD,[†] Michael Eggen, PhD,[†] Pamela Omdahl, PhD[‡]

From the ^{*}Second Division of Cardiovascular Diseases, Cardiac-Thoracic and Vascular Department, Cisanello Hospital, University of Pisa, Italy, [†]Medtronic Cardiac Rhythm and Heart Failure Research, Mounds View, Minnesota, and [‡]Cardiac Rhythm and Heart Failure Procedure Development, Mounds View, Minnesota.

Introduction

The Medtronic Micra transcatheter pacing system (TPS) is a miniaturized VVIR pacemaker that is less than one-tenth the volume of a typical pacemaker, or 0.8 cc (6.7 mm diameter by 26 mm long). The TPS is small enough to place directly within the right ventricle (RV) at the site of pacing, and uses 4 nitinol tines for fixation. Implanting the pacemaker entirely within the heart eliminates the need for both a device pocket and a lead. The pocket and lead contributed to 75% and 88% of the complications in 2 different reports.^{1,2} Additionally, with placement of the pacemaker within the heart, patients are no longer reminded of their medical condition by either an incision or a device felt under the skin.

The longevity of the TPS is estimated to be between 7 and 12 years, depending on patient pacing needs and pacing output. At end of service the TPS is designed to be turned off and left within the heart, and cannot automatically power on again. A new TPS may be implanted adjacent to the original device, and the telemetry is designed allow the user to choose with which device to communicate. Because of this design, it is expected that retrieval of the TPS will be a rare event. However, it is anticipated that there may be some circumstances in which the TPS may need to be retrieved, for example high thresholds shortly after implant.

To facilitate retrieval, the TPS is designed with a feature on the proximal end of the device to allow a snare to capture the device around the waist (Figure 1A). A button with a smaller diameter than the TPS, and a waist between the

button and the TPS body, allows the TPS to be snared and then pulled back into the delivery tool or introducer.

This case study describes the first in vivo retrieval procedure of a TPS implanted in the right ventricular apex of a sheep for 28 months, using a custom sheath combined with market-released tools.

Case report

The implanted device used in this study was externally identical to the clinical TPS, but the implanted device contained no battery chemicals or circuitry. The TPS delivery tool contained the TPS at the distal end. The delivery tool was directed through a 24F introducer that was placed in the jugular vein of a sheep via a surgical cut-down. The TPS was delivered to the apex of the RV and the device was fixed to the heart with 4 flexible nitinol tines. These atraumatic tines were embedded into the heart wall first by housing them inside a device cup to keep them straight, then by pressing this device cup against the heart wall, and finally by retracting the device cup to expose the tines and allow them to self-expand and engage the tissue (Figure 1B). Because of the elastic properties of nitinol, the tines return to their preformed shape after they are deployed into the tissue.

Once the tines were attached to the heart wall, a fixation test was performed confirming that at least 2 of the 4 tines were engaged in the tissue. Once the TPS was implanted, the sheep was turned out to pasture for 28 months.

The retrieval was performed with a custom sheath that consisted of an Arctic Front FlexCath Steerable Sheath (Medtronic, Minneapolis, Minnesota) to which a TPS device cup had been attached (AF sheath). A 7F Marinr (single-curve) ablation catheter (Medtronic) and a 90° Lasso snare (Osypka AG, Rheinfelden-Herten, Germany) were placed through the AF sheath (Figure 1C). The loop of the snare was placed over the distal end of the ablation catheter before the ablation catheter and the snare were loaded into the AF sheath.

The first step in the retrieval procedure was to visualize the capsule using intracardiac echocardiography. From these

KEYWORDS Pacemaker; Transcatheter pacing system; Miniaturization; Delivery catheter; Leadless pacemaker

ABBREVIATIONS RV = right ventricle; TPS = transcatheter pacing system (Heart Rhythm Case Reports 2016;2:43–46)

Maria Grazia Bongiorni reports honoraria relevant to this topic from Medtronic and Biosense Webster and serves as a consultant/advisory board member of Boston Scientific and Spectranetics. Matthew Bonner, Michael Eggen, and Pamela Omdahl are employees of Medtronic. **Address reprint requests and correspondence:** Maria Grazia Bongiorni, Second Division of Cardiovascular Diseases, Cardiac-Thoracic and Vascular Department, Cisanello Hospital, University of Pisa, Via Paradisa 2, 56124 Pisa, Italy. E-mail address: m.g.bongiorni@med.unipi.it.

KEY TEACHING POINTS

- The Medtronic Micra transcatheter pacing system (TPS) is a miniaturized VVIR pacemaker that eliminates the need for both a device pocket and a lead.
- Although the TPS is designed to be turned off and left within the heart, there may be some circumstances in which the TPS may need to be acutely retrieved.
- This case study describes the first in vivo retrieval procedure of a TPS chronically implanted in the right ventricular apex of a sheep, using a custom sheath combined with market-released tools.

images the proximal end of the capsule was determined to be clearly free of fibrous tissue (Figure 2A). Once it was determined that the proximal end of the TPS was free of tissue, the ablation catheter was guided to the TPS until the catheter tip was touching the proximal end of the device in both lateral and dorsal ventral views. The snare was then guided down over the ablation catheter and onto the waist of the device retrieval feature (Figure 2B).

The ablation catheter was then removed from the AF sheath. The snare was tensioned like a rail, and the AF sheath was advanced down over the snare until the cup was adjacent to the device (Figure 2C). Then, using tension on the snare and counter-traction on the AF sheath, the TPS device was slowly pulled into the cup at the end of the AF sheath (Figure 2D). Only a small amount of tension was required to pull the device into the delivery cup. The AF sheath containing the TPS was then removed from the body. The entire procedure lasted approximately 40 minutes, with less than 10 minutes between the catheter insertion and removal of the device.

After removal, TPS and heart gross anatomy were analyzed. The TPS appeared substantially intact, without evident distortion of the tines. Regarding the RV endocardial surface, we observed a thin white tissue near the apex of the heart (Figure 3), which in other studies has been shown to be a fibrous response to the presence of the TPS.³ In the center of this white tissue was a small void the same diameter as the distal TPS. This was likely the tissue capsule around the distal end of the TPS. There was no injury to the tissue surrounding this void or to any other structures in the RV.

Discussion

The TPS is designed to be turned off at the end of service and left in the heart, allowing another TPS to be placed adjacent to the original one. It is expected that with an average implant age of 75 years, and an average longevity of 10 years, the implantation of 2 and potentially 3 TPS will provide most patients with a lifetime of pacing therapy without requiring retrieval or extraction. However, in some

rare situations, the TPS may need to be removed. Although the TPS and delivery system were designed for acute TPS recovery and repositioning, to date no technical recommendations are available to approach chronically implanted devices.

Some may argue that the most common time for retrieval/extraction would be at end of service. However, for the TPS this may not be the case. With an average implant age of 75 for pacemaker patients and the average longevity of the TPS estimated at 10 years, most patients will not survive past 3 TPS devices. The RV and trabeculation will likely accommodate at least 3 devices. Therefore, for the average patient extraction at end of service may not be required. The primary anticipated reasons for retrieval would be high thresholds, infections, and dislodgment. In the first 140 patients we have seen no infections, no dislodgments, and no high thresholds requiring retrieval.⁴ While it is still very early in the development of this device, it looks promising. In addition, once the TPS device is encapsulated, it will not participate in infections, and it will not dislodge. So if indeed the TPS lasts for 10 years and the average heart can accommodate at least 3 devices, then extraction at end of service will likely be a rare event.

In this sheep study we demonstrated that it is possible to retrieve the TPS in a reasonable time, using a custom sheath combined with market-released tools. The lack of encapsulation seen around the retrieval feature of the device in the intracardiac echocardiograph⁵ allowed the retrieval feature on the TPS to be snared without complication. In contrast, it is very likely that the distal end was well encapsulated, because the implant location in the heart of this subject had a mature fibrous structure consistent with the fibrous capsules observed in previous TPS studies.³ Despite this, the TPS was removed with no damage to the endocardial surface.

In the extraction literature a differentiation is made between retrieval and extraction.⁶ Retrieval is considered to be the removal of a lead before it is encapsulated, generally involving only traction. In contrast, extraction typically requires special tools such as locking stylets and cutting sheaths to remove the lead after encapsulation. Retrieval is considered likely if the lead has been implanted

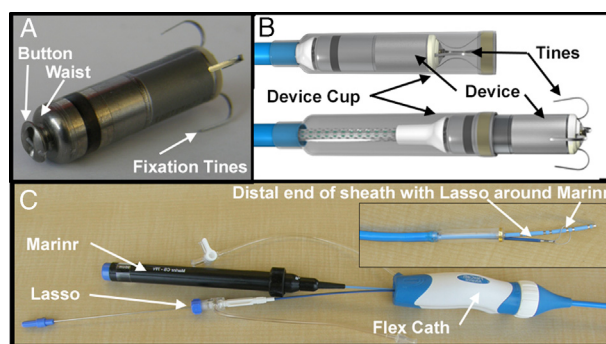


Figure 1 A: Transcatheter pacing system (TPS) device highlighting the proximal retrieval feature. B: TPS held in device cup with tines straightened and with device cup pulled back to allow tines to engage tissue. C: Assembly including the Arctic Front FlexCath Steerable Sheath (AF sheath) into which the Mariner catheter and Lasso snare were placed. The inset shows the distal end of the AF sheath with the TPS device cup attached and the Mariner catheter and Lasso snare projecting beyond the distal end of the cup.

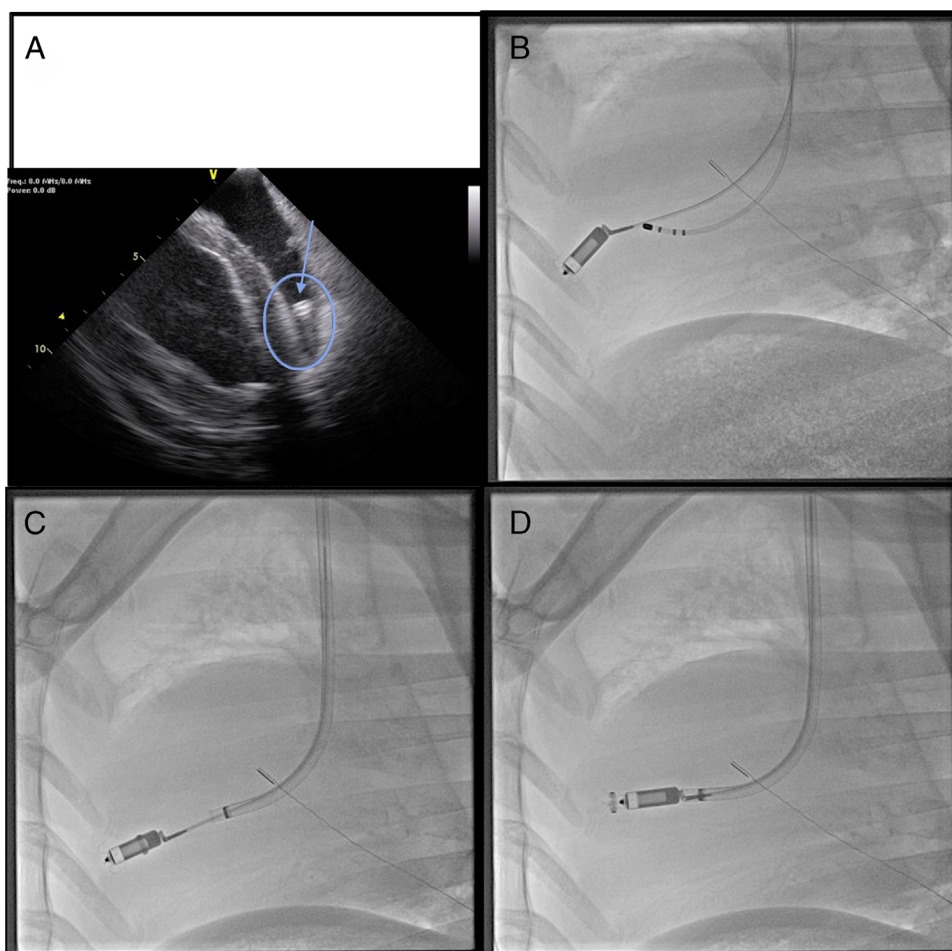


Figure 2 Steps in capturing the transcatheter pacing system (TPS). **A:** Intracardiac echo image of the TPS in the apex of the right ventricle with the retrieval feature shown at the top (*arrow*). **B:** The TPS with lasso snare around the waist of the retrieval feature. The ablation catheter used to steer the snare to the device can also be seen in the picture. **C:** The TPS being pulled into the Arctic Front FlexCath Steerable Sheath (AF sheath) that was guided to the TPS using the snare as a rail. **D:** The TPS pulled into the cup on the AF sheath ready for removal from the body.

less than a year; extraction is considered likely if the lead has been implanted more than a year.⁷

The same differentiation should apply to the TPS. Some-time after implantation the device will be fully encapsulated and removal will require extraction tools and methods.⁸ Prior

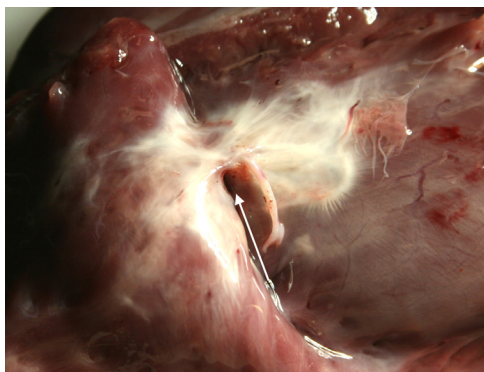


Figure 3 Endocardial surface after extraction. The white tissue is likely the fibrous response to the presence of the transcatheter pacing system (TPS). The void in the middle of the white tissue (*arrow*) is where the TPS was implanted, with the thicker encapsulation tissue surrounding the distal end of the TPS.

to encapsulation at an as yet undetermined time (potentially years), the retrieval feature on the device can be used to pull the device into a delivery tool for removal from the body.

While a traditional pacemaker system must be extracted if it becomes infected, it is not clear if the same recommendation applies to the TPS.⁹ Occasionally, a lead fragment (up to a few centimeters) is left in the heart after an incomplete lead extraction owing to infection, and over 90% of these patients fully recover with no infection relapse.^{10–12} In the presence of infection with the TPS device it is of note that the TPS is similar in size to many of the lead fragments left in the heart after a partial extraction (<4 cm). Therefore, treatment of infection with a course of antibiotics prior to initiating retrieval or extraction may be warranted. In addition, the possibility that the TPS could be participating in a late infection will be reduced once the TPS is fully encapsulated.

The tines used to attach the device to the heart wall have a unique feature. The nitinol tines should remain flexible for the lifetime of the device, and should back out of the fibrous capsule in which they are covered, with little or no adhesion to the surrounding tissue. This design concept was reflected in the ease of removal of the TPS in this study 28 months after implantation.

The use of an over-the-catheter approach, even if not essential, may help to guide snare manipulation in the RV. However, the described approach may fail in the case of complete device encapsulation; in fact, the technique depends on the proximal end of the device being free of fibrous tissue in order to advance the snare. The manufacturer has designed the delivery tool to accommodate a small off-the-shelf snare that can be used for retrieval. In addition, the manufacturer has designed the TPS with a snareable feature on the back of the TPS to allow retrieval with other off-the-shelf retrieval tools. Lastly, the TPS fixation is designed in such a way that the tines can be withdrawn from the cardiac tissue without counter-traction or a cup and the tines will not tear the tissue.

Some limitations have to be considered. The primary limitation of this case is that this research was performed in sheep and sheep hearts have no trabeculae. The human heart can be highly trabeculated, complicating retrieval of the TPS. A second limitation is that this technique requires the proximal retrieval feature to be free of tissue and therefore only applies to devices that are not fully encapsulated. An additional limitation was the jugular approach used in this study for device implantation, primarily owing to the difficulty of access to the cardiac apex from the femoral approach in sheep. Therefore, the orientation of the device in this sheep's heart was directed toward a jugular approach. While in humans the TPS is implanted from the femoral approach, both the femoral and the jugular approach are used for lead extraction, with the jugular approach offering many advantages in removal of difficult or intravascular leads.^{13–16} Therefore, for the TPS, depending on the orientation of the device one approach or the other may be the best. At present, long-term data of TPS are pending in humans. Device follow-up will clarify the long-term TPS performance, the related necessity of transvenous removal, and the clinical impact of the present case.

References

1. Udo EO, Zuihoff NP, van Hemel NM, de Cock CC, Hendriks T, Doevedans PA, Moons KG. Incidence and predictors of short- and long-term complications in pacemaker therapy: The FOLLOWPACE study. *Heart Rhythm* 2012;9:728–735.
2. Wiegand UK, Bode F, Bonnemeier H, Eberhard F, Schlei M, Peters W. Long-term complication rates in ventricular, single lead VDD, and dual chamber pacing. *Pacing Clin Electrophysiol* 2003;26:1961–1969.
3. Bonner MD, Eggen MD. Chronic animal study of leadless pacer design. *Heart Rhythm Society Annual Conference* 2011, San Francisco, CA.
4. Ritter P, Duray GZ, Stienwender C, et al. Early performance of a miniaturized leadless cardiac pacemaker: the Micra Transcatheter Pacing Study. *Eur Heart J* 2015;36(37):2510–2519.
5. Bongiorni MG, Di Cori A, Soldati E, Zucchelli G, Arena G, Segreti L, De Lucia R, Marzilli M. Intracardiac echocardiography in patients with pacing and defibrillating leads: a feasibility study. *Echocardiography* 2008;25(6):632–638.
6. Wilkoff BL, Love CJ, Byrd CL, Bongiorni MG, Carrillo RG, Crossley GH 3rd, Epstein LM, Friedman RA, Kennergren CE, Mitkowski P, Schaerf RH, Wazni OM. Transvenous lead extraction: Heart Rhythm Society expert consensus on facilities, training, indications, and patient management. *Heart Rhythm* 2009;6(7):1085–1104.
7. Deharo JC, Bongiorni MG, Rozkovec A, Bracke F, Defaye P, Fernandez-Lozano I, Golzio PG, Hansky B, Kennergren C, Manolis AS, Mitkowski P, Platou ES. Pathways for training and accreditation for transvenous lead extraction: a European Heart Rhythm Association position paper. *Europace* 2012;14:124–134.
8. Segreti L, Di Cori A, Soldati E, Zucchelli G, Viani S, Paperini L, De Lucia R, Coluccia G, Valsecchi S, Bongiorni MG. Major predictors of fibrous adhesions in transvenous implantable cardioverter-defibrillator lead extraction. *Heart Rhythm* 2014;11(12):2196–2201.
9. Bongiorni MG, Dagues N, Estner H, Pison L, Todd D, Blomstrom-Lundqvist C. Management of malfunctioning and recalled pacemaker and defibrillator leads: results of the European Heart Rhythm Association survey. *Europace* 2014;16:1674–1678.
10. Rusanov A, Spotnitz H. A 15-year experience with permanent pacemaker and defibrillator lead and patch extractions. *Ann Thorac Surg* 2010;89:44–50.
11. Smith HJ, Fearnot NE, Byrd CL, Wilkoff BL, Love CJ, Sellers TD. Five-years experience with intravascular lead extraction. *Pacing Clin Electrophysiol* 1994;17(Pt II):2016–2020.
12. Chua JD, Wilkoff BL, Lee I, Jurati N, Longworth DL, Gordon SM. Diagnosis and management of infections involving implantable electrophysiologic cardiac capsules. *Ann Intern Med* 2000;133:604–608.
13. Bongiorni MG, Soldati E, Zucchelli G, Di Cori A, Segreti L, De Lucia R, Solarino G, Balbarini A, Marzilli M, Mariani M. Transvenous removal of pacing and implantable cardiac defibrillating leads using single sheath mechanical dilatation and multiple venous approaches: high success rate and safety in more than 2000 leads. *Eur Heart J* 2008;29(23):2886–2893.
14. Bongiorni MG, ed. *Transvenous Lead Extraction: From Simple Traction to the Internal Transjugular Approach*, 1st edition. Milan, Italy: Springer Verlag; 2011: 1–180.
15. Bongiorni MG, Segreti L, Di Cori A, Zucchelli G, Viani S, Paperini L, De Lucia R, Boem A, Levorato D, Soldati E. Safety and efficacy of internal transjugular approach for transvenous extraction of implantable cardioverter defibrillator leads. *Europace* 2014;16(9):1356–1362.
16. Bongiorni MG, Di Cori A, Segreti L, Zucchelli G, Viani S, Paperini L, De Lucia R, Levorato D, Boem A, Soldati E. Transvenous extraction profile of Riata leads: procedural outcomes and technical complexity of mechanical removal. *Heart Rhythm* 2015;12(3):580–587.