

CASE REPORT

Acute stroke from paradoxical embolism of dense fibrous tissue following pacemaker lead extraction: salvation by mechanical thrombectomy

Nicolas B. Dayal¹, Ana Paula Narata² & Haran Burri¹

¹Cardiology Service, University Hospital of Geneva, Geneva, Switzerland

²Radiology Service, University Hospital of Geneva, Geneva, Switzerland

Correspondence

Haran Burri, Electrophysiology Unit, Cardiology Service, University Hospital of Geneva, Rue Gabrielle Perret Gentil 4, 1211 Geneva 14, Switzerland. Tel: +41 22 372 72 00; Fax: +41 22 372 72 29; E-mail: haran.burri@hcuge.ch

Funding Information

No sources of funding were declared for this study.

Received: 1 August 2015; Revised: 17 September 2015; Accepted: 29 October 2015

Clinical Case Reports 2016; 4(2): 158–161

doi: 10.1002/ccr3.461

Case Report

A 57-year-old woman who had initially been implanted with a double chamber pacemaker for complete atrioventricular block was upgraded to CRT-P at another center after a year due to left ventricular dysfunction and dyspnea. She was referred to us 3 months after the upgrade due to wound infection by *Pseudomonas sp* caused by gossybyoma (retained compress). Preoperative transthoracic (TTE) and transesophageal (TOE) echocardiography did not reveal any signs of endocarditis, and the patient was afebrile with negative blood cultures. A patent foramen ovale (PFO) with a small left to right shunt was found on color Doppler imaging (Fig. 1). Under general anesthesia, traction with locking stylets allowed complete extraction of the active-fixation right atrial and right ventricular leads, and the coronary sinus lead was explanted by simple traction. There were no additional findings on the perioperative TOE. The following morning she developed sudden dysarthria and left facial palsy, and emergent cerebral angiography revealed an occlusion of the right

Key Clinical Message

Systemic embolization is a dreaded complication of transvenous lead extraction (TLE), even without visible vegetations. Preoperative patent foramen ovale evaluation is important, justifying neurological surveillance or consideration of surgical extraction in selected cases. In case of stroke after TLE, mechanical thrombectomy is a successful therapy, and should be readily available.

Keywords

Embolic stroke, lead extraction, pacemaker, patent foramen ovale, thrombectomy.

frontal branch of the middle cerebral artery (Fig. 2A and B). Mechanical thrombectomy with a Solitaire™ FR revascularization device (Covidien, Plymouth, MN, USA) retrieved a thrombus attached to dense fibrinous tissue (Fig. 3), presumably originating from debris surrounding the extracted leads. Normal vessel flow was recovered (Fig. 2C and D), and neurological recovery was complete within 60 min of symptom onset. The patient underwent CRT-P reimplantation on the right side the next day. Oral antibiotics were continued for a further 2 weeks, and follow-up at 6 months was uneventful.

Case Discussion

Herein, we describe the case of a patient suffering acute ischemic stroke due to paradoxical embolization of dense fibrous material through a PFO following transvenous lead extraction (TLE). Endocardial pacemaker leads cause fibrin deposits on their surface which may form sheaths in over 85% of patients [1] or adhere with the vessel walls, tricuspid valves, and endocardium. Thrombi can be

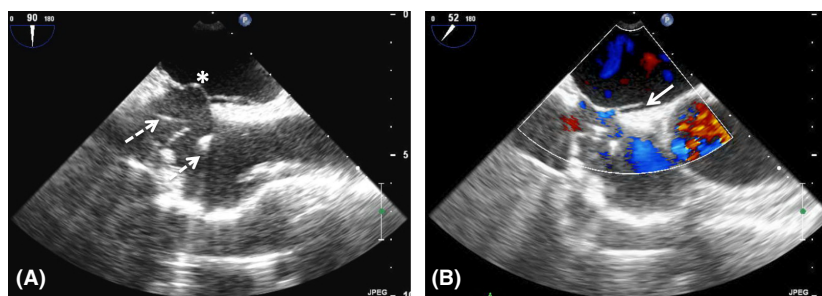


Figure 1. Transesophageal echocardiography of the bicaval view in 2 dimensions (A) and using color doppler (B), showing a mobile interatrial septum (asterisk) with a patent foramen ovale (solid arrow). Pacemaker leads are shown with dashed arrows.

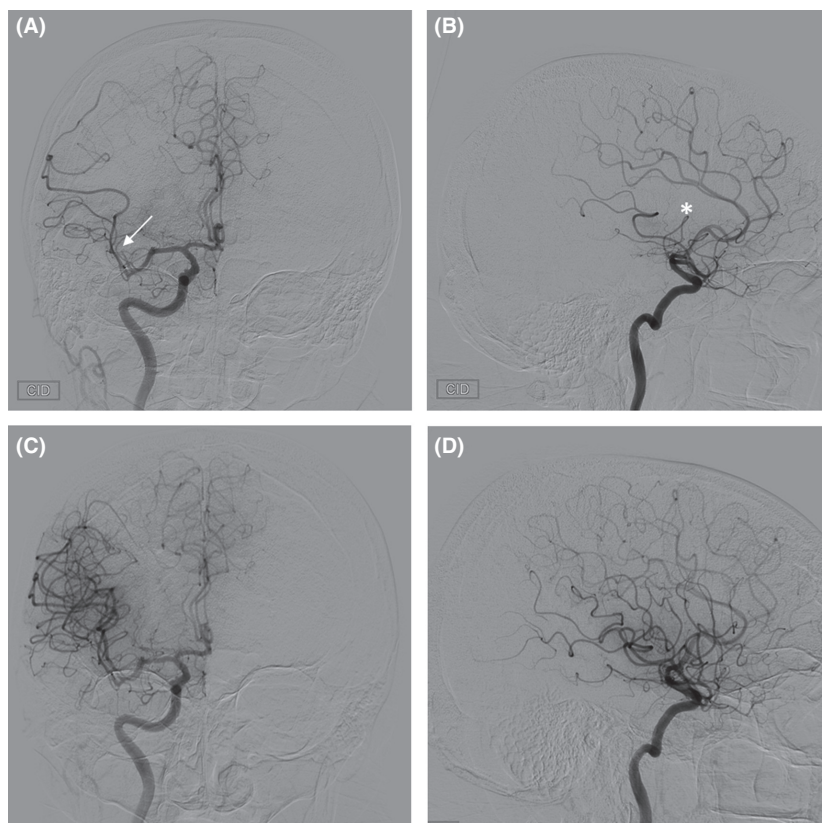


Figure 2. Cerebral angiography in frontal and sagittal views. (A and B) occlusion of frontal branch of right middle cerebral artery (arrow) with hypoperfusion of a large territory (asterisk). (C and D) restored flow after mechanical thrombectomy.

detected on the leads in around 30% of patients by TOE and intracardiac ultrasound [2, 3], and findings of asymptomatic pulmonary emboli in up to 15% of patients as well as increased pulmonary pressure point toward a high rate of subclinical embolism in patients with cardiovascular implantable electronic devices (CIEDs) [1, 3, 4]. One particular concern is the risk of systemic thromboembolism in patients with intracardiac shunts and CIEDs; in all shunts other than PFOs, the risk of systemic thromboembolism is doubled [5] and such conditions are

present considered a contraindication for endocardial lead placement [6]. In the case of PFOs, the risk is less well documented, but retrospective data points toward a hazard ratio of >3 for stroke [7], although study bias may have exaggerated this figure.

TLE is a valuable technique for management of device infection and lead failure, and its safety has improved thanks to technological advances and increasing experience. Preliminary data from the ELECTRa registry [8], the only prospective European registry of TLE, show a




Figure 3. (A) The Solitaire™ FR revascularization device (Covidien) used for mechanical thrombectomy. (B) Fibrous material retrieved after thrombectomy.

relatively low rate of major complications (2.5–3.9% depending on the procedural volume of centers). One complication of particular concern when extracting leads is the risk of systemic embolism. Indeed, residual fibrous deposits persisting after TLE have been described [9], sometimes large enough as to be described as “ghosts” of the extracted leads. Our case illustrates that these residual deposits may not always be visible with TOE, probably because they may be confined to the vessels (e.g., innominate or subclavian vein) but may embolize later. Although the rate of stroke seems to be low (0.1%) during TLE, our case highlights the potentially dramatic consequences of systemic embolization, even in the absence of visible vegetations on the leads. Moreover, current guidelines offer no clear recommendations to help lower the risk of embolization during TLE [10]. Routine anticoagulation, used by some centers mainly to lower the rate of venous occlusion, is probably of little use due to the fibrinous nature of the tissue. The use of distal embolization protection devices during TLE in patients with vegetations has been reported in several cases, whether in the pulmonary [11] or systemic circulation [12]. However, the efficacy of these devices seems limited by the risk of delayed embolism as demonstrated in our case, and because residual dense fibrinous tissue probably persists for several days or weeks.

Based on our case and these considerations, we believe paradoxical embolism causing stroke is a real concern in patients with PFOs undergoing TLE. Although its incidence seems to be low, the consequences can be catastrophic and the costs linked with the morbidity of stroke are important. We recommend preoperative evaluation for PFOs in all patients undergoing TLE. Although this may raise the concern of additional cost, most patients undergoing TLE have a preoperative echocardiographic examination, either TTE or TOE, in order to evaluate preoperative tricuspid valve regurgitation or presence of vegetations. The additional cost and time linked to evaluate for a PFO is negligible. In case of PFOs with large

shunts, we suggest considering percutaneous PFO-closure before extraction in noninfected patients or surgical extraction and PFO-closure in patients with endocarditis. In cases with small PFOs, we recommend strict avoidance of manoeuvres increasing right-to-left shunting (e.g., coughing, valsalva) and 24–48 h neurological surveillance. The effectiveness of mechanical thrombectomy in cases of embolization after lead extraction is also highlighted in this case. Because of the dense fibrous nature of embolus (or in cases where the embolus is of foreign body material), pharmacological thrombolysis is likely to be ineffective, as well as increasing the bleeding risk considerably in the postoperative period. Therefore, we strongly suggest performing TLE in centers with neuro-radiological standby, as rapid action may prevent irreversible sequelae.

Conflicts of interest

None.

Funding

None.

References

- Novak, M., Dvorak P., Kamaryt P., Slana B., Lipoldova J., et al. 2009. Autopsy and clinical context in deceased patients with implanted pacemakers and defibrillators: intracardiac findings near their leads and electrodes. *Europace* 11:1510–1516.
- Alizadeh, A., M. Maleki, H. Bassiri, M. Alasti, Z. Emkanjoo, M. Haghjoo, et al. 2006. Evaluation of atrial thrombus formation and atrial appendage function in patients with pacemaker by transesophageal echocardiography. *Pacing Clin. Electrophysiol.* 29:1251–1254.
- Supple, G. E., J. F. Ren, E. S. Zado, and F. E. Marchlinski. 2011. Mobile thrombus on device leads in patients

- undergoing ablation: identification, incidence, location, and association with increased pulmonary artery systolic pressure. *Circulation* 124:772–778.
4. Seeger, W., and K. Scherer. 1986. Asymptomatic pulmonary embolism following pacemaker implantation. *Pacing Clin. Electrophysiol.* 9:196–199.
 5. Khairy, P., M. J. Landzberg, M. A. Gatzoulis, L. A. Mercier, S. M. Fernandes, J. M. Côté, et al. 2006. Transvenous pacing leads and systemic thromboemboli in patients with intracardiac shunts: a multicenter study. *Circulation* 113:2391–2397.
 6. Brignole, M., A. Auricchio, G. Baron-Esquivias, P. Bordachar, G. Boriani, O. A. Breithardt, et al. 2013. 2013 ESC Guidelines on cardiac pacing and cardiac resynchronization therapy. *Eur. Heart J.* 34:2281–2329.
 7. DeSimone, C. V., P. A. Friedman, A. Noheria, N. A. Patel, D. C. DeSimone, S. Bdeir, et al. 2013. Stroke or transient ischemic attack in patients with transvenous pacemaker or defibrillator and echocardiographically detected patent foramen ovale. *Circulation* 128:1433–1441.
 8. ELECTRa registry status report, presented at ESC congress 2014, Barcelona
 9. Rizzello, V., Dello Russo, A., Casella, M., Biddau, R. 2008. Residual fibrous tissue floating in the right atrium after percutaneous pacemaker lead extraction: an unusual complication early detected by intracardiac echocardiography. *Int. J. Cardiol.* 127:e67–e68.
 10. Wilkoff, B. L., C. J. Love, C. L. Byrd, M. G. Bongiorno, R. G. Carrillo, G. H. 3rd Crossley, et al. 2009. Transvenous lead extraction: Heart Rhythm Society expert consensus on facilities, training, indications, and patient management. *Heart Rhythm* 6:1085–1104.
 11. Dello Russo, A., C. Di Stasi, G. Pelargonio, M. Casella, S. Bartoletti, M. L. Narducci, et al. 2013. Intracardiac echocardiogram-guided use of a Dormia basket to prevent major vegetation embolism during transvenous lead extraction. *Can. J. Cardiol.* 29:1532.e11–1532.e13.
 12. Thompson, J. J., K. M. McDonnell, J. F. Reavey-Cantwell, K. A. Ellenbogen, and J. N. Koneru. 2014. Paradoxical septic emboli secondary to pacemaker endocarditis: transvenous lead extraction with distal embolization protection. *Circ. Arrhythm. Electrophysiol.* 7:1271–1272.