

Evaluation and comparison of the effect of honey, milk and combination of honey–milk on experimental induced second-degree burns of Rabbit

Seyed Mehdi Hosseini¹, Reza Fekrazad², Hamid Malekzadeh¹,
Parviz Farzadinia³, Mohammadreza Hajiani³

¹Department of Oral and Maxillofacial Surgery, Dental School, AJA University of Medical Science, ²Department of Periodontology, Dental School, AJA University of Medical Science, ³Department of Biology and Anatomical Science, Faculty of Medicine, Bushehr University of Medical Science, Bushehr, Iran

ABSTRACT

Introduction: Burn can happen in any area and causes dominant changes in the quality of normal tissues. The aim of present article is evaluation and comparison the effect of milk, natural honey, and combination of honey–milk on healing of burnt wound. **Method and Material:** A 4-week trial study was carried out on 10 Albino New Zealand rabbits. All dry burned wound was created on the back of the scapula by a 1 * 1 cm metal block. First group received honey dressing, second group milk dressing, third group honey–milk dressing, and the fourth group 5% sulfadiazine dressing. Sampling was performed at days 1, 10, and 20. Measurement of wound size was done in days 1, 7, 14, 21, 28. The obtained data and information were analyzed by two-way ANOVA and Duncan tests using SPSS. **Results:** Result show that combination of milk-honey dressing had most significant effect on the improvement of wound healing in the recipient rabbits after a 4-week study. The size of burn wound in four different group was: Honey milk combination 0.428 cm², honey 0.547 cm², milk 0.579 cm² and sulfadiazine 0.873 cm². **Conclusion:** All dressing can accelerate wound healing and have promotive effect on wound healing but the combination of honey–milk had the greatest effect. Honey, milk, and sulfadiazine had next grade of effectiveness.

Keywords: Honey, milk, wound dressing, wound healing

Introduction

One of the most common physical and mental damages that can hurt a person is burning damages. Burn can happen in any area such as the site of a car accident or in war field. Burn trauma causes dominant changes in quality and regeneration ability of soft tissues. These change in soft tissue delayed soft and hard tissues' regeneration after burning damage.^[1] We should notice

the point that more damage in soft and hard tissue occurs before transferring the patient to the treatment center.^[2] So, if the quality of the soft tissue can be maintained before transferring to hospital regeneration and treatment can be done better. Burn can be caused by heat, electricity, and chemicals. The thermal burns include 90% and electricity and chemicals only include 10% of total types of burns.^[3] Burning damages classified in three different types: grades 1, 2, and 3.^[4] Treatment of burn wounds is one of the important medical issue that researchers try to find a substance that accelerate healing of these wounds with least side effects. Burn wounds have different complications but the most common one is infection. The best treatment of

Address for correspondence: Dr. Hamid Malekzadeh, Department of Oral and Maxillofacial Surgery, Dental School, AJA University of Medical Science, Tehran, Iran. E-mail: pmn.hsn30067@gmail.com

Received: 20-09-2019

Revised: 27-12-2019

Accepted: 06-01-2020

Published: 28-02-2020

Access this article online

Quick Response Code:



Website:
www.jfmpc.com

DOI:
10.4103/jfmpc.jfmpc_801_19

This is an open access journal, and articles are distributed under the terms of the Creative Commons Attribution-NonCommercial-ShareAlike 4.0 License, which allows others to remix, tweak, and build upon the work non-commercially, as long as appropriate credit is given and the new creations are licensed under the identical terms.

For reprints contact: reprints@medknow.com

How to cite this article: Hosseini SM, Fekrazad R, Malekzadeh H, Farzadinia P, Hajiani M. Evaluation and comparison of the effect of honey, milk and combination of honey–milk on experimental induced second-degree burns of Rabbit. J Family Med Prim Care 2020;9:915-20.

burn wounds is to remove the infection^[5] and the most common antimicrobial drug for burn wound is silver sulfadiazine ointment. Silver sulfadiazin has not dominant effects in acceleration of wound healing. Besides it has side effects such as delayed wound healing, nephrotoxicity, leukopenia, allergic reactions, and medical resistance.^[5] As silversulfadiazin other synthetic drugs are expensive and has side effects such as allergic reactions and drug resistance, researchers look for alternative dressing material for wounds, especially burn wounds. Since ancient ages, mankind has tried to treat burns by new materials. In traditional medicine there have been various attempts to find a drug that accelerate wound healing and skin lesions. Among all of different traditional materials honey and milk were used widely in different part of ancient world.^[6] Honey has antimicrobial and regenerative effects that help wound healing.^[7] Milk as another ancient dressing material has feature of good maintainer substance for cells such as similar PH and osmolarity.^[8] The aim of this investigation is evaluation and comparison of the effect of milk, natural honey and combination of honey milk dressing on burning wounds of rabbit.

Material and Methods

Model selection and grouping

A 4-week trial study was carried out on 10 Albino New Zealand rabbits, with an average weight of 2000 g, under the same conditions (room temperature: 24°C, humidity: 70–80%, 12-hour regular cycle of light and dark, necessary care, and enough food and water). The research accepted in Aja ethical committee in animal laboratory examination and received ethical code (IR. AJAUMS.REC.1397.110). All burned wounds were created on the back of animal at the interscapula area. first Group of wounds were treated with pure honey (from Golestan Company-Iran). The second group was treated with high-fat (3% fat) milk-pasteurized (which is produced in Mihan company in Iran). The third group was treated with mixture of milk and honey and the fourth group was treated with sulfadiazine 5% (Iran Najo company-Iran) as control group. During the experiment, all environmental and physical conditions of the animal, including weight, disease, ulcers, and infection were examined and, if any abnormal alteration of the animal, was removed from the work.

Preparation of animals and method of ulceration

Before ulceration (wound), hair of shoulder region of all rabbits was shaved. The next day, rabbits were transferred to surgery room. For general anesthesia, 50 mg per kg of body weight of 3:1 mixture of ketamine and xylazine was intramuscularly (IM) administered to rabbits.

To create a dry burn wound, scapula region was burned (1 * 1) dimensions by the burn treatment unit (Manufactured by Anatomical Sciences of Bushehr University of medical science). In this method 10 second touch of 140 centigrad degree-plate makes second-degree dry burn wound [Figures 1-3].

Treatments

According to grouping, the rabbits were treated twice a day with an interval of 12 hours in the first week, once a day in the second week, and every 2 days in the third week. Honey, combination of honey–milk and sulfadiazin were spatulated by finger on the wound. Milk was maintained on wound by moisturizing steril gau. All of the procedure was done by expert technician in blind condition.

Biopsy and tissue preparation

Sampling was performed at days 1, 10, and 20. For sampling, rabbits were firstly anesthetized by the intramuscular administration of 50 mg/kg of body weight of 3:1 mixture of ketamine and xylazin. The scapula area on the border between healthy and repaired tissue was sampled using sterile surgical set. Samples were fixed in 10% formalin and sent to a histopathology laboratory for performing sample preparation steps based on routine and standard method. For study under light microscope, samples were fixed with formalin 10% and dehydration with alcohol and embedded with paraffin, and then 3-micron sections were prepared. The prepared sections were normally stained using routine staining (H and E) for detecting better collagen density and arrangement. For detecting better collagen density and arrangement and more accurate investigation of dermal tissue repair, Masson's Trichrome stain against collagen fibers was used.

Histological studies

After preparing microscopic slides of tissue sections and quantitative measurement such as fibroblast cell count, blood vessels, area of wound surface and necrotic tissue, epidermis thickness, and wound healing speed, the status of morphological changes of wounds in all groups was studied.

Clinical evaluation of wound

Qualitative (morphology) studies were conducted directly using observations and preparation of a standard checklist (www. bradenscale.com, Barbara Braden, 2001). This information includes the status of wound's morphological size changes in different days. This checklist is a tool for assessment of the status of wounds repair over time which has the ability to monitor wounds over time and differentiate the healing wound. All check list has been filled by expert technician in blind condition out of any bias. Ease of use and high accuracy and sensitivity are of features of this check list. Based on consultation with statistical specialist obtained data and information were analyzed by two-way ANOVA and Duncan tests using SPSS (ver 18, and Excel).

Results

This interventional case-control study was performed on 10 laboratory rabbits all living in similar conditions. The rabbits were received general anesthesia using ketamine and xylazine, and their hairs were shaved at interscapular area. Their back was then disinfected with polyvinylpyrrolidone iodine and then

burned by a 1 cm² aluminum plaque at a temperature of 250-300 degrees Celsius to create grade 2 burn wound. For each rabbit, right wound toward the tail (caudal) was covered with natural honey, right wound toward the head (cephalic) with wet milky gauze, left side to head with the combination of milk and honey and left toward the tail with silver sulfadiazine ointment. In order to evaluate wound healing, the wound size was measured on the first day and then weekly to day 28 using a transparent sheet and a digital caliper. The result is as below:

Kamolmogorov-Smirnov and Shapiro-Wilk were used to evaluate the normal distribution of study data. Also, Levin test was used to evaluate the homogeneity of variance of the research variables. Result of these tests [Tables 1 and 2] showed normal distribution and homogeneity of data which can be used for other analysis.

After that two way Anova test was done for each dressing group to evaluate affectivity of each materials. Results showed that in each group of dressing wound size decreased from day 1 to day 28. It means that all dressings accelerate wound healing. The rate of wound size decreasing is faster in group of honey milk combination (0.547 mm² in day 28) in comparison to other groups. Honey, milk and silver sulfadiazine are at the next level of healing acceleration. Result of Anova test for each group showed in Tables 3-5.

Figure 4 shows wound size of different dressing group in different days as blue columns and mean wound's sizes of control group (silversulfadiazin) as red column. According to the below chart, it is clear that the mean wound size of first day was 1, day 7 was 0.963, 0.848 for day 14, day 21 was 0.722, day 28 was 0.579 for milk group dressing and in the control groups was 0.873. These measurement for honey dressing wound showed 1 in day 1, 0.963 in day 7, 0.848 in day 14, 0.722 in day 21, and 0.579 in day 28. In the same manner measurement of wound size for honey–milk combination dressing showed that mean of first day was 1, day 7 was 0.839, day 14 was 0.682, day 21 was 0.552, day 28 was 0.428. Therefore, it was concluded that milk, honey, and combination of honey–milk dressing had the most effect on the rate of wound healing in the recipient rabbits. Honey, milk, and silversulfadiazin are at the next level of effectivity, respectively.

As mentioned in statistical analysis, it seems that all three compounds are effective in acceleration of wound healing

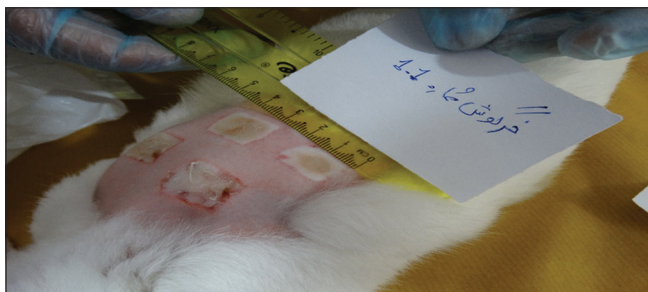


Figure 1: Preparation of second degree dry burn wound on back of rabbit

in rabbits because wound size decrease from first to 28th day continuously in all groups of dressing. The following charts show the size of wounds in groups with different dressings in day 28:

Table 1: Kolmogorov Smirnov test and Shapiro Wilk test for different dressing

Variability	Shapiro-Wilk test	Variability	Kamolmogorov-Smirnov Test	Dressing
0.508	0.920	0.210*	0.137	Milk
0.274	0.881	0.234*	0.162	Honey
0.117	0.921	0.189*	0.125	Honey-milk

Table 2: Levin test result for different dressing

Levin test	Variability	Dressing
0.257	0.616	Milk
0.155	0.697	Honey
0.437	0.513	Honey-milk

Table 3: One-way ANOVA Results for milk group dressing

Day	Average	Standard deviation	%95		F	Valuability
			Min	Max		
0	1.00000	0.000000	1.00000	1.00000	35.230	0.000
7	0.96310	0.033238	0.93932	0.98688		
14	0.84890	0.037403	0.82214	0.87566		
21	0.72280	0.035835	0.69716	0.74844		
28	0.57900	0.021700	0.56348	0.59452		
Control	0.87328	0.114510	0.84074	0.90582		
Sum	0.84802	0.140586	0.82012	0.87592		

Table 4: One-way ANOVA Results for honey group dressing

Day	Average	Standard deviation	%95		F	Valuability
			Min	Max		
0	1.00000	0.000000	1.00000	1.00000	39.858	0.000
7	0.87820	0.064249	0.83224	0.92416		
14	0.74280	0.042632	0.71230	0.77330		
21	0.66120	0.041747	0.63134	0.69106		
28	0.54740	0.048990	0.51235	0.58245		
Control	0.87328	0.114510	0.84074	0.90582		
Sum	0.81960	0.152023	0.78944	0.84976		

Table 5: One-way ANOVA Results for combination of hone- milk group dressing

Day	Average	Standard deviation	% 95		F	Valuability
			Min	Max		
0	1.00000	0.000000	1.00000	1.00000	74.792	0.000
7	0.83940	0.049072	0.80430	0.87450		
14	0.68240	0.039503	0.65414	0.71066		
21	0.55230	0.039503	0.52404	0.58056		
28	0.42860	0.035072	0.40351	0.45369		
Control	0.87328	0.114510	0.84074	0.90582		
Sum	0.78691	0.188065	0.74959	0.82423		

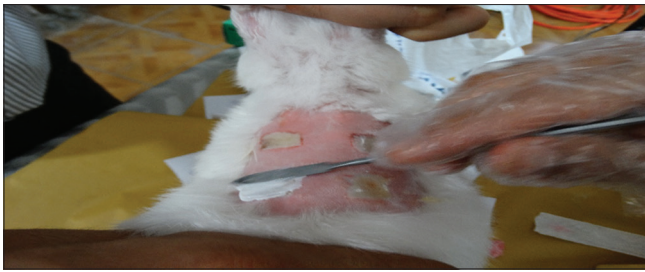

Figure 2: Spatulation of dressing on dry burn wounds




Figure 3: Clinical evaluation and wound size measurement in day 14,21,28

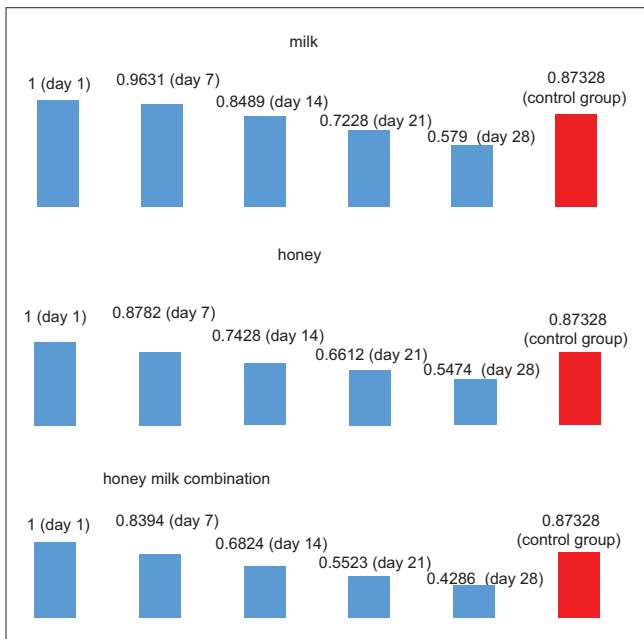


Figure 4: Mean dressed wound size in different (0,7,14,21,28) days in different group of dressing(milk,honey,combination of honey-milk) in recipient rabbits

The diagram shows that in day 28, the lowest size (0.371 mm²) of the wounds was for the wounds that were dressed with the combination of milk and honey. After that the lowest size of the wounds was related to honey (0.496 mm²), milk (0.533 mm²),

and silver sulfadiazine (0.63 mm²) ointments, respectively. This indicates that the greatest improvement is achieved when the wounds are covered with a mixture of milk and honey. Honey, milk, and silver sulfadiazine ointments are at the next level. All of these resulted were gained in *P* value 0.05%.

Microscopic examination at day 10 showed normal healing of connective tissue and epithelium in honey–milk combination but in other groups skin lacks notable epithelium at surface and connective tissue in depth. The same results existed in samples of day 20 [Figure 5].

Discussion

This case-control study was performed on 10 rabbits. Four grade 2 burn wound were created, on the back of each rabbit. The wounds were covered with dressings of honey, milk, honey–milk, and silversulfadiazin (as control group). The results showed that the wounds which were covered by the honey–milk dressing had smaller size after 4 weeks. The wounds of the honey dressing and the milk dressing were at the next level of healing speed. In other words, milk–honey dressed wound had higher rate of healing than honey, milk, and Silver Sulfadiazine control group. The use of dressings on wounds refer to ancient civilizations when it was suggested in 2200 BC that natural and traditional herbal materials were washed and then tightly inserted in damaged area.^[9,10] In general, dressing can accelerate wound healing even if it does not contain any disinfectant which was proved by Lionely *et al.* in 2003.^[11] In their research, they showed that dressing can accelerate wound healing by blocking the wound, preventing trauma to tissue, reducing wound edema, and creating a humid environment for epithelial cells to move. In addition, in 2007, Seyed al-Shohadee’s research on second-degree burn wounds showed that wound healing in wet environments is better than in dry environments.^[12] This showed that dressings create a higher wound healing and epithelial mobility by creating a wet environment.^[13] The most important discovery in dressing examination as a factor of wound healing accelerator returns to 2015. Dhivya *et al.* (2015) evaluate extracellular matrix in wounds dressing. They showed that dressings accelerate the formation of extracellular matrix and thereby accelerate wound healing.^[14] Although their studies were an initiating point for evaluation of dressing effect on wound healing, they did not evaluate specific dressing. In other words, they proved that all dressing accelerate wound healing but did not investigate the type of dressings and materials used in them.

Various materials have been used in wound dressing during the time. Honey is a material which was used in traditional medicine as a dressing.^[15] Honey accelerates wound healing by two important features: First, due to its antibacterial properties, it creates an infection-free environment that can help wound healing. This was explored in Gupta’s study in 2011 which showed the antibacterial effect of honey by H₂O₂ and phenolic acid, which are found in natural honey.^[16] In addition honey has high acidity levels that destroy bacterial cell wall.^[17] The second property of honey that accelerates wound healing is the effect of honey on the stimulation

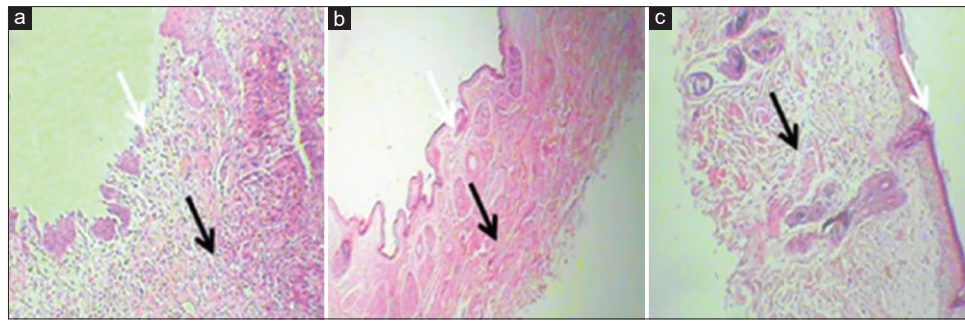


Figure 5: The micrograph of skin section in different group of dressing in day10. a: Milk, b: Honey, c: Honey-milk combination

of host cells to heal wounds. Honey stimulates the production of cytokines by monocytes.^[18] In addition, honey increases proliferation of B and T lymphocytes which can produce more Antibodies and increase foreign cell phagocytosis.^[19] So honey directly destroys microorganisms with its antibacterial and antiseptic properties and indirectly strengthens the host's immune system. In this condition regenerative and repair system can do their work better.

Milk is another substance which is suitable environment for the maintenance of tissues avulsed from the body, such as Avulse teeth. The ability of milk to maintain the proliferative cells of the body returns to its intrinsic properties. PH of milk is similar to body cells.^[20] This allows the milk to remain same osmotic pressure as long as being in the vicinity of the cells of the body and to survive in a safe environment. On the other hand, milk is a rich source of amino acids, carbohydrates and vitamins that provide the cells with nutrients in the early hours of the body's inadequate nutrient supply and extend their lives.^[21] Another important ingredient of milk is calcium. Research by Hemmati *et al.* showed that milk had a faster healing effect on the wound's initial contraction, and this effect was due to the calcium in the milk.^[21] Milk affects the proliferation of fibroblasts and keratinocytes in addition to causing wound's initial contraction and improves the early healing.^[22] So milk can be used as a preservative and nutritional substance in wound dressing.

The important point of this investigation is that if milk and honey have regenerative properties they can be used in combination to increase regenerative properties of damaged tissue. Combination of honey and milk has more effect in acceleration of wound healing because of the feature which mention for each of these materials former. All of the feature that mentioned former can assumed in combination of honey–milk dressing and improved wound healing.

Conclusion

The results showed that milk-honey combination as dressing had the most effect on wound healing improvement. Honey is more effective than milk if each ingredient is used alone. The control group, which was silver sulfadiazine, had the least effect. In area which has access to these material combination of honey milk can be used as dressing in burn wound. It seems that more research should be done to evaluate other dressings, especially

traditional materials, in order to reveal the effectiveness of these materials in wound healing.

Financial support and sponsorship

Nil.

Conflicts of interest

There are no conflicts of interest.

References

1. Abhyankar SV, Vartak AM. Impact of ulinastatin on outcomes in acute burns patients. *J Burn Care Res* 2018;39:109-16.
2. Vivó C, Galeiras R, del Caz MD. Initial evaluation and management of the critical burn patient. *Med Intensiva* 2016;40:49-59.
3. Smolle C, Cambiaso-Daniel J, Forbes AA, Wurzer P, Hundeshagen G, Branski LK, *et al.* Recent trends in burn epidemiology worldwide: A systematic review. *Burns* 2017;43:249-57.
4. Vaughn L, Beckel N. Severe burn injury, burn shock, and smoke inhalation injury in small animals. Part 1: Burn classification and pathophysiology. *J Vet Emerg Crit Care (San Antonio)* 2012;22:179-86.
5. Güldoğan CE, Kendirci M, Tikici D, Gündoğdu E, Yastı AÇ. Clinical infection in burn patients and its consequences. *Ulus Travma Acil Cerrahi Derg* 2017;23:466-471.
6. Molan P, Rhodes T. Honey: A biologic wound dressing. *Wounds* 2015;27:141-51.
7. Winter GF. Medical-grade honey dressing use in developing countries. *Adv Skin Wound Care* 2017;30:1-3.
8. Souza BDM, Alves AMH, Ribeiro DM, Santos LGPD, Simões CMO, Felipe WT, *et al.* Effect of milk renewal on cell viability *In Vitro* at different time frames. *Braz Dent J* 2017;28:435-9.
9. Peć anac M, Janjić Z, Komarcević A, Pajić M, Dobanovacki D, Misković SS. Burns treatment in ancient times. *Med Pregl* 2013;66:263-7.
10. Kim SW, Kim JH, Kim JT, Kim YH. A simple and fast dressing for skin grafts: Comparison with traditional techniques. *J Wound Care* 2018;27:417-20.
11. Lionely C, Ning C, Gawaziuk JP, Liu S, Logsetty S. *In vitro* measurements of burn dressing adherence and the effect of interventions on reducing adherence. *Burns* 2017;43:1002-10.
12. Al-Shoahadaee S. [Influence of different inner dressings in negative-pressure wound therapy on escharectomy wound of full-thickness burn rabbits]. *Zhonghua Shao Shang Za Zhi*

- 2007;33:431-6.
13. Monsuur HN, Boink MA, Weijers EM, Roffel S, Breetveld M, Gefen A, *et al.* Methods to study differences in cell mobility during skin wound healing *in vitro*. *J Biomech* 2016;49:1381-7.
 14. Dhivya S, Padma VV, Santhini E. Wound dressings-A review. *Biomedicine (Taipei)* 2015;5:22.
 15. Maver T, Gradišnik L, Kurešič M, Hribernik S, Smrke DM, Maver U, *et al.* Layering of different materials to achieve optimal conditions for treatment of painful wounds. *Int J Pharm* 2017;529:576-88.
 16. Gupta SS, Singh O, Bhagel PS, Moses S, Shukla S, Mathur RK. Honey dressing versus silver sulfadiazene dressing for wound healing in burn patients: A retrospective study. *J Cutan Aesthet Surg* 2011;4:183-7.
 17. Piotrowski M, Karpiński P, Pituch H, van Belkum A, Obuch-Woszczyński P. Antimicrobial effects of manuka honey on *in vitro* biofilm formation by *clostridium difficile*. *Eur J Clin Microbiol Infect Dis* 2017;36:1661-4.
 18. Lourenço AP, Martins JR, Torres FAS, Mackert A, Aguiar LR, Hartfelder K, *et al.* Immunosenescence in honey bees (*Apis mellifera* L.) is caused by intrinsic senescence and behavioral physiology. *Exp Gerontol* 2019;119:174-83.
 19. Gasparrini M, Afrin S, Forbes-Hernández TY, Cianciosi D, Reboredo-Rodríguez P, Amici A, *et al.* Protective effects of Manuka honey on LPS-treated RAW 264.7 macrophages. Part 2: Control of oxidative stress induced damage, increase of antioxidant enzyme activities and attenuation of inflammation. *Food Chem Toxicol* 2018;120:578-87.
 20. Hasan MR, Takebe H, Shalehin N, Obara N, Saito T, Irie K. Effects of tooth storage media on periodontal ligament preservation. *Dent Traumatol* 2017;33:383-92.
 21. Hemmati AA, Larki-Harchegani A, Shabib S, Jalali A, Rezaei A, Housmand G. Wound healing property of milk in full thickness wound model of rabbit. *Int J Surg* 2018;54:133-40.
 22. Souza BDM, Alves AMH, Ribeiro DM, Santos LGPD, Simões CMO, Felipe WT, *et al.* Effect of milk renewal on cell viability *In Vitro* at different time frames. *Braz Dent J* 2017;28:435-9.