

Upgrade of cardiac resynchronization therapy by utilizing additional His-bundle pacing in a patient with lamin A/C cardiomyopathy: an autopsy case report

Our previous case series showed that an upgrade from conventional cardiac

resynchronization therapy (CRT) to CRT combining para-His-bundle pacing (HBP) and left ventricular pacing (LVP) significantly improved the heart failure (HF) status in patients with advanced cardiomyopathy.¹ To continue that report, we provide the autopsy findings and histological examinations of patient No. 1 with lamin A/C gene (LMNA) cardiomyopathy.

A year after the upgrade, he developed renal failure and died from hyperkalaemia resistant to dialysis. An autopsy revealed an enlarged and

dilated heart, weighing 560 g (Figure 1A). Microscopic examination with Masson trichrome staining of the LVP site showed a partially scarred region (blue cytoplasm) (Figure 1B), whereas extensive scarring was present in the region of the right ventricular (RV) apex pacing lead (Figure 1C). The alternative pacing lead was located below the septal tricuspid leaflet and 4 mm from the lower edge of the membranous septum (Figure 1D). Microscopic examination showed diffuse interstitial fibrosis

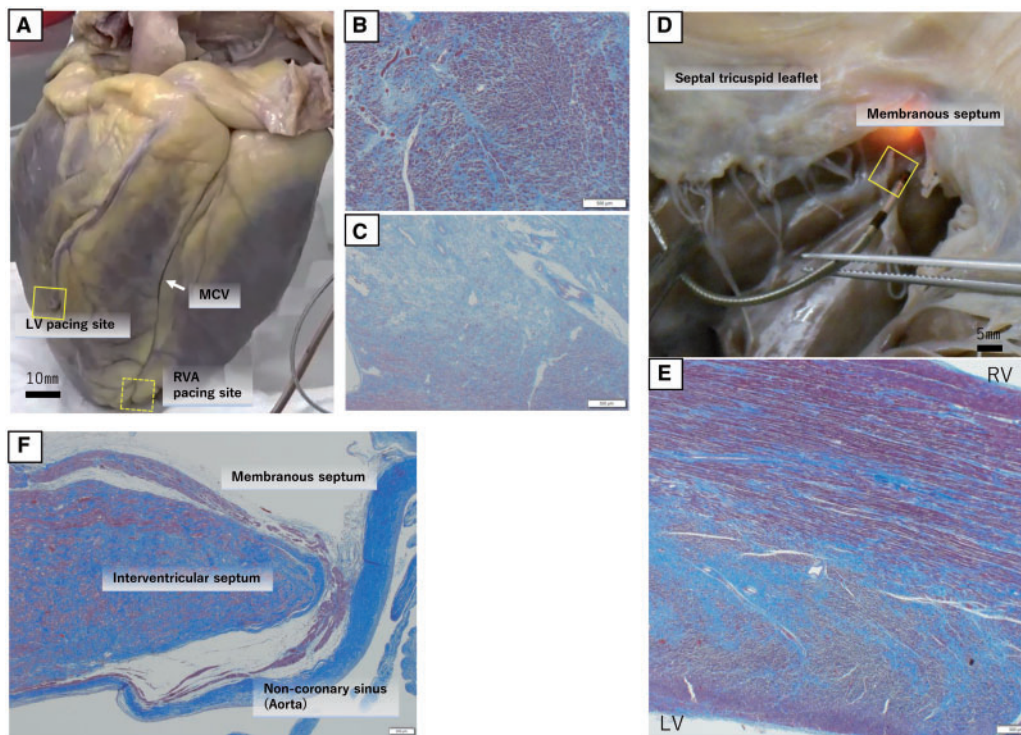


Figure 1 (A) The heart was enlarged and dilated. (B) Histological examination with Masson trichrome staining at the left ventricle pacing region showed extensive interstitial fibrosis with a partial scar region (blue cytoplasm). (C) Histological examination at the right ventricle apex pacing region. Myocytes were present over an extensive region of scarring. (D) Close-up view of the alternative pacing lead, located below the septal tricuspid leaflet and 4 mm away from the lower edge of the membranous septum transilluminated from the left ventricle. (E) Microscopic examination showed interstitial fibrosis diffusely present throughout the myocardium with a scar in the mid-layer. However, some more viable myocardium (red cytoplasm) was present within the right ventricle septal endocardium compared to that in the right ventricle apex pacing region. Although the right bundle branch was assumed to run superficially in this region, it was difficult to identify distinct conduction systems microscopically. (F) Histological section at the level of the interventricular component of the membranous septum, being attached inferior to the crest to the muscular IVS. This region was extensively scarred. The bundle of His, left bundle branch, and RBB could not be identified. IVS, interventricular septum; LV, left ventricle; MCV, mid-cardiac vein; RVA, right ventricle apex; RV, right ventricle; RBB, right bundle branch.

Handling Editor : Christian Fielder Camm

© The Author(s) 2021. Published by Oxford University Press on behalf of the European Society of Cardiology.

This is an Open Access article distributed under the terms of the Creative Commons Attribution-NonCommercial License (<https://creativecommons.org/licenses/by-nc/4.0/>), which permits non-commercial re-use, distribution, and reproduction in any medium, provided the original work is properly cited. For commercial re-use, please contact journals.permissions@oup.com

and a scarred region within the middle layer. However, viable myocardium (red cytoplasm) was present within the RV endocardium (Figure 1E). Although this region was presumably where the right bundle branch (RBB) ran superficially, it was difficult to identify a distinct conduction system microscopically.

The histological sections at the level of the interventricular component of the membranous septum, which was attached inferiorly to the crest to the muscular interventricular septum (IVS), showed extensive scarring. A conduction system, i.e., His-bundle, left bundle branch, and RBB, could not be identified (Figure 1F).

The European Society of Cardiology statements consider HBP to be safe as an alternative technique to CRT.² However, HBP may not provide adequate resynchronization for patients with advanced cardiomyopathy due to coexisting scarred myocardium or intraventricular conduction defect.³ The most advanced cardiomyopathy is accompanied by extensive fibrosis and is associated with adverse clinical outcomes.⁴ Avoiding scarred areas pacing is critical since nonviable tissue can no longer be resynchronized.⁵ In the present case, scar formation was evident around the left ventricle and right ventricle apex pacing sites. No studies have so far evaluated the importance of myocardial substrate and remodelling for RV lead placement. This autopsy study focused on whether the alternative pacing lead had actually captured the conduction system. We had speculated that the upgraded CRT improved the patient's HF status because it successfully captured the conduction system with the alternative pacing lead. However, we did not recognize any distinct conduction system in the para-

HBP region. This suggested that para-HBP would actually fail to recruit, directly or partially, the intrinsic conduction system for resynchronization. Extensive scarring in the basal IVS is known to be a characteristic of LMNA cardiomyopathy.^{6,7} Aiming for selective HBP may not always be an appropriate choice when performing CRT in patients with advanced cardiomyopathy with IVS scarring and a damaged His-Purkinje system. We hope that these autopsy findings can help solve another puzzle in understanding the non-response to CRT. Further studies should be encouraged to evaluate RV myocardial substrate in advanced cardiomyopathy patients requiring CRT.

Consent

The authors confirm that written consent for submission and publication of this case series including images and associated text has been obtained from the patients in line with COPE guidance.

Funding

This work did not receive any specific grant from funding agencies in the public, commercial, or not-for-profit sectors.

References

1. Baba M, Yoshida K, Hanaki Y, Yamamoto M, Shinoda Y, Takeyasu N et al. Upgrade of cardiac resynchronization therapy by utilizing additional His-bundle pacing in patients with inotrope-dependent end-stage heart failure: a case series. *Eur Heart J Case Rep* 2020;**4**:1–9.
2. Mullens W, Auricchio A, Martens P, Witte K, Cowie MR, Delgado V et al. Optimized Implementation of cardiac resynchronization therapy - a call for action

for referral and optimization of care. *Europace* 2021;**23**:1324–1342.

3. Vijayaraman P, Herweg B, Ellenbogen KA, Gajek J. His-optimized cardiac resynchronization therapy to maximize electrical resynchronization: a feasibility study. *Circ Arrhythm Electrophysiol* 2019;**12**:e006934.
4. Eijgenraam TR, Sillje HHW, de Boer RA. Current understanding of fibrosis in genetic cardiomyopathies. *Trends Cardiovasc Med* 2020;**30**:353–361.
5. Harb SC, Toro S, Bullen JA, Obuchowski NA, Xu B, Trulock KM et al. Scar burden is an independent and incremental predictor of cardiac resynchronization therapy response. *Open Heart* 2019;**6**:e001067.
6. Graber HL, Unverferth DV, Baker PB, Ryan JM, Baba N, Wooley CF. Evolution of a hereditary cardiac conduction and muscle disorder: a study involving a family with six generations affected. *Circulation* 1986;**74**:21–35.
7. Arbustini E, Pilotto A, Repetto A, Grasso M, Negri A, Diegoli M et al. Autosomal dominant dilated cardiomyopathy with atrioventricular block: a lamin A/C defect-related disease. *J Am Coll Cardiol* 2002;**39**:981–990.

Masako Baba^{1,2}, Kentaro Yoshida^{1,2,*}, Osamu Igawa³, Masayoshi Yamamoto², Akihiko Nogami², Noriyuki Takeyasu¹, and Hitoaki Saitoh⁴

¹Department of Cardiology, Ibaraki Prefectural Central Hospital, Kasama, Japan; ²Department of Cardiology, Faculty of Medicine, University of Tsukuba, 1-1-1 Tennodai, Tsukuba 305-8575, Japan; ³Department of Cardiology, Nippon Medical School Hospital, Tokyo, Japan; and ⁴Department of Pathology, Ibaraki Prefectural Central Hospital, Kasama, Japan

* Corresponding author. Tel: +81(296)77-1121
Fax: +81(296)77-2886, Email: kentaroyo@nifty.com