Clinical Case Report

Medicine®

OPEN

Renal and pulmonary thrombotic microangiopathy triggered by proteasome-inhibitor therapy in patient with smoldering myeloma

A renal biopsy and autopsy case report

Clarissa A. Cassol, MD[a,*], Michael P.A. Williams, MD[b], Tiffany N. Caza, MD, PhD[c], Sophia Rodriguez, MD[d]

Abstract

Rationale: Thrombotic microangiopathy (TMA) is a group of clinical syndromes characterized by excessive platelet activation and endothelial injury that leads to acute or chronic microvascular obliteration by intimal mucoid and fibrous thickening, with or without associated thrombi. It frequently involves the kidney but may involve any organ or system at variable frequencies depending on the underlying etiology. Among its numerous causes, drug toxicities and complement regulation abnormalities stand out as some of the most common. A more recently described association is with monoclonal gammopathy. Lung involvement by TMA is infrequent, but has been described in Cobalamin C deficiency and post stem-cell transplantation TMA.

Patient concerns: This is the case of a patient with smoldering myeloma who received proteasome-inhibitor therapy due to retinopathy and developed acute renal failure within one week of therapy initiation.

Diagnoses: A renal biopsy showed thrombotic microangiopathy. At the time, mild pulmonary hypertension was also noted and presumed to be idiopathic.

Interventions: Given the known association of proteasome-inhibitor therapy with thrombotic microangiopathy, Bortezomib was discontinued and dialysis was initiated.

Outcomes: Drug withdrawal failed to prevent disease progression and development of end-stage renal disease, as well as severe pulmonary hypertension that eventually lead to the patient's death.

Lessons: To our knowledge, this is the first reported case of pulmonary involvement by TMA associated with monoclonal gammopathy which appears to have been triggered by proteasome-inhibitor therapy. Clinicians should be aware of this possibility to allow for more prompt recognition of pulmonary hypertension as a potential manifestation of monoclonal gammopathy-associated TMA, especially in patients also receiving proteasome-inhibitors, so that treatment aiming to slow disease progression can be instituted.

Abbreviations: ADAMTS13 = a disintegrin-like and metalloproteinase with thrombospondin type 1 motif, member 13, BMI = body mass index, C3 = complement C3, C4 = complement C4, ESRD = end-stage renal disease, FLC = free light chains, HF = heart failure, HUS = hemolytic uremic syndrome, ICU = intensive care unit, IgG = immunoglobulin G, IkK = IκB kinase, NF-kB = nuclear factor kappa-light-chain-enhancer of activated B cells, PASP = pulmonary artery systolic pressure, PI = proteasome inhibitor, POEMS syndrome = polyneuropathy, organomegaly, endocrinopathy, monoclonal gammopathy, and skin changes, TMA = thrombotic microangiopathy, VEGF = vascular endothelial growth factor.

Keywords: monoclonal gammopathy, proteasome-inhibitor, pulmonary hypertension, smoldering myeloma, thrombotic microangiopathy

Editor: N/A.

The authors of this case report have no conflicts of interest to disclose.

[a] Department of Pathology, The Ohio State University, Columbus, [b] Department of Pathology, SUNY Upstate Medical University, Oneida, [c] Arkana Laboratories, Little Rock, AR 72211, [d] Queens Office of the Chief Medical Examiner of the City of New York, New York.

[*] Correspondence: Clarissa A. Cassol, The Ohio State University, Department of Pathology, Renal Pathology Division, 320W, 10th Avenue M018 Starling Loving Hall, Columbus, OH 43210 (e-mail: Clarissa.Cassol@osumc.edu).

Copyright © 2019 the Author(s). Published by Wolters Kluwer Health, Inc.
This is an open access article distributed under the terms of the Creative Commons Attribution-Non Commercial-No Derivatives License 4.0 (CCBY-NC-ND), where it is permissible to download and share the work provided it is properly cited. The work cannot be changed in any way or used commercially without permission from the journal.

How to cite this article: Cassol CA, Williams MPA, Caza TN, Rodriguez S. Renal and pulmonary thrombotic microangiopathy triggered by proteasome-inhibitor therapy in patient with smoldering myeloma. Medicine 2019;98:39(e17148).

Received: 4 February 2019 / Received in final form: 18 July 2019 / Accepted: 20 August 2019

http://dx.doi.org/10.1097/MD.0000000000017148

1. Introduction

Thrombotic microangiopathies are clinical syndromes characterized by excessive platelet activation and endothelial injury that result in acute and chronic microvascular occlusion.[1] Among its many causes are Shiga-toxin producing bacterial infections, ADAMTS13 deficiency or autoantibodies, complement alternative pathway regulation abnormalities, drug reactions, malignancies, bone marrow transplantation, Cobalamin C deficiency, viral, and bacterial infections.[2] The kidney is often involved; however, any organ or system may be affected. The frequency of extrarenal manifestations may vary according to the underlying etiology, with central nervous system involvement being common in ADAMTS13 deficiency, and renal involvement often seen in complement-mediated TMA. Lung involvement, clinically manifested by pulmonary hypertension, is rare in Complement-mediated TMA but can be seen in TMA secondary to Cobalamin C deficiency[3,4] and stem-cell transplantation.[5] To our knowledge, lung involvement has not been reported in TMA associated with monoclonal gammopathy, nor with proteasome-inhibitor therapy.[1,6]

1.1. Case presentation

The patient was a 53 year-old female who originally presented to an ophthalmologist for blurred vision and was found to have retinal ischemia, cotton wool spots and macular edema, initially attributed to hypertensive retinopathy. Worsening retinal findings eventually led to more extensive workup that revealed a 1.5 g/dL monoclonal protein, immunoglobulin G (IgG) kappa type. She had a negative hypercoagulable panel, normal blood cell counts, elevated erythrocyte sedimentation rate and lactate dehydrogenase, and slightly elevated creatinine (1.1 mg/dL). Total immunoglobulin G was 1176 mg/dL (reference range 700–1600 mg/dL), free light chains (FLC) ratio was abnormal at 28.12 with high free kappa (274 mg/L; reference range 3.3–19.4 mg/L). There was no monoclonal protein in a 24-hour urine collection and no significant proteinuria. Skeletal survey showed no lytic lesions and a bone marrow aspiration and biopsy showed 10%–15% plasma cells. She was diagnosed with smoldering myeloma and plasma cell directed therapy was recommended due to significant vision impairment. One week after starting triple therapy with bortezomib, lenalidomide, and dexamethasone, she presented with acute renal failure (rise in Creatinine from 1.4 to 6.9 mg/dL). Urinalysis showed 1+ protein and greater than five red blood cells per high power field, no casts were seen. Serum albumin was 3.1 g/dL. Hepatitis serologies were negative. Renal ultrasound showed normal-sized kidneys and no evidence of obstruction. A renal biopsy was indicated.

1.2. Renal biopsy

The biopsy contained 11 glomeruli, one of which was globally sclerosed. The remaining glomeruli were shrunken with a bloodless appearance and diffusely wrinkled capillary walls (Figure 1). There was no endocapillary hypercellularity and no glomerular thrombi. Diffuse interstitial edema with focal mild interstitial inflammation were present, along with evidence of acute tubular injury and rare granular casts. No atypical, fractured crystalline eosinophilic casts were seen. Interstitial fibrosis and tubular atrophy were estimated as mild. At least four arterioles were present, all of which showed endothelial swelling, intimal edema and concentric fibroplasia with entrapped red blood cells leading to complete or near-complete luminal obliteration. There were no definite thrombi or fibrinoid necrosis. Congo Red stain for amyloid was negative. Immunofluorescence showed no light chain restriction within casts or in the tubulo-interstitium. Electron microscopy confirmed the absence of amyloid fibrils and showed evidence of endothelial damage and ischemia in the form of subendothelial lucent widening and diffusely wrinkled glomerular basement membranes. Tubules showed intracytoplasmic vacuoles and loss of microvilli consistent with acute tubular injury and no crystals or abnormal lysosomes.

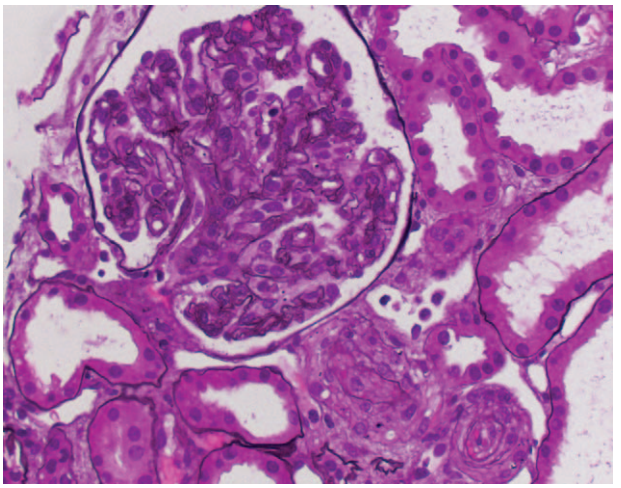

Figure 1. Renal biopsy one week after initiation of bortezomib therapy showing complete arteriolar luminal obliteration by endothelial swelling, fibrous and mucoid intimal thickening, and an ischemic glomerulus with a bloodless appearance. (Jones Silver stain, 400×).

A diagnosis of acute thrombotic microangiopathy was made.

1.3. Follow-up

Given the recent initiation of myeloma therapy including Bortezomib and the known association of proteasome-inhibitor therapy with thrombotic microangiopathy,[1] Bortezomib was discontinued. The patient however did not recover renal function and remained dialysis-dependent ever since. She also experienced progressive decline of vision, with no response to intravitreal anti-VEGF and only partial response to steroids.

She eventually presented to an outside hospital 9 months later with shock that was presumed to be septic in origin. By then, she also had a history of recurrent pericardial effusions, attributed to chronic renal failure, and congestive heart failure with an ejection fraction of 25%. She had severe left ventricular systolic dysfunction and moderate pulmonary hypertension. In retrospect, pulmonary hypertension had been detected at an echocardiogram performed two days after her renal biopsy, at which point she had a normal ejection fraction and had received a diagnosis of primary pulmonary hypertension.

Shortly after presentation, she suffered a cardiac arrest and was successfully resuscitated. At that point, she was transferred to our institution where she was admitted to ICU and broad antibiotic therapy was started even though no clear infection source was identified. Echocardiogram showed moderate pericardial effusion and an enlarged right atrium and right ventricle with

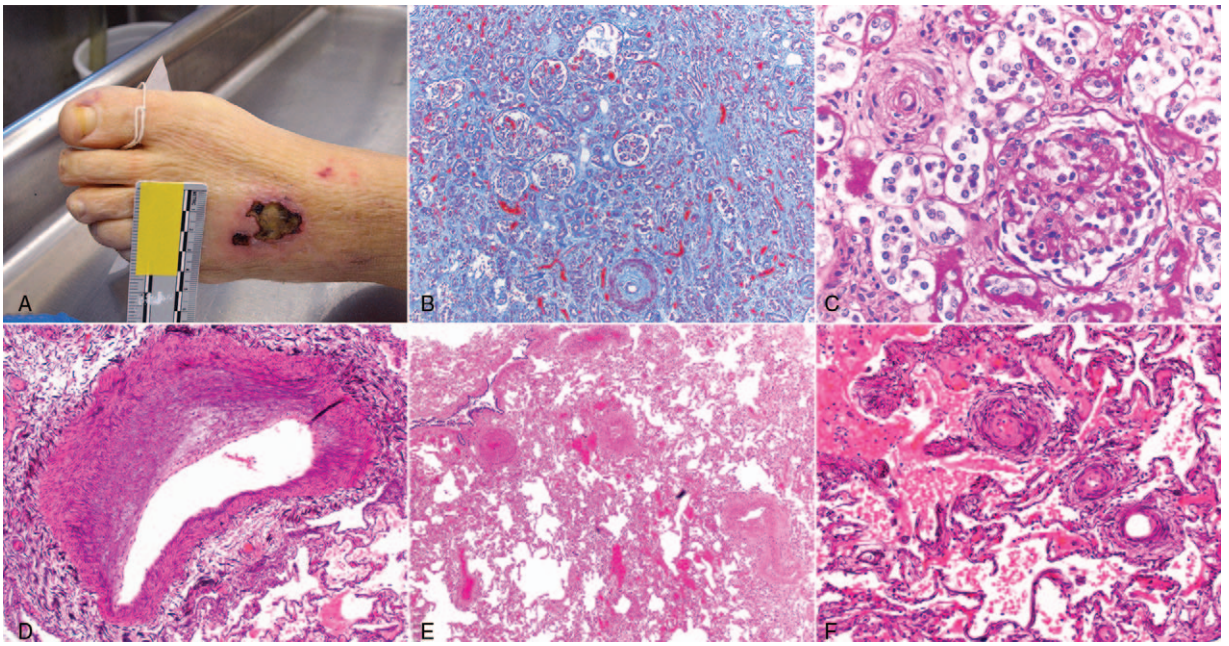

Figure 2. (A) Ulcer with fat layer exposure on the foot dorsum, similar to reported in skin involvement in atypical hemolytic uremic syndrome.[7](B) Renal parenchyma at autopsy showing severe interstitial fibrosis and tubular atrophy; prominent arterial fibrous intimal thickening (B, Trichrome stain, 100×); arterioles with "onion-skin" changes and ischemic glomeruli (C, PAS stain, 400×). Lung parenchyma at autopsy showing severe fibrous intimal thickening of a large caliber pulmonary artery (D, Jones Silver stain, 200×), medial hypertrophy in medium and small caliber arteries (E, Hematoxylin and eosin, 100×) and prominent obliterative changes in small arterioles (F, Jones Silver stain, 400×).

tricuspid regurgitation but no evidence of tamponade. Pulmonary artery systolic pressure (PASP) was very high (85.28 mmHg) compared with a previous echocardiogram done 2 months earlier that showed a PASP of 52 mmHg. Left ventricular ejection fraction was estimated at 60%–65%. Pericardiocentesis was arranged and 325 mL of serous fluid were drained; cytopathology and fluid cultures including acid-fast bacilli and fungi were negative.

Given her history of smoldering myeloma, hematology-oncology was consulted. Serum protein electrophoresis showed a 0.66 g/dL monoclonal band in the gamma region, characterized as IgG on serum immunofixation. IgG was 1226 mg/dL (reference range 700–1600 mg/dL). Serum kappa FLC was 340.8 mg/L (reference range 0.33–1.94) with kappa/lambda FLC ratio of 16.15. Skeletal survey showed no lytic lesions. An abdominal fat pad biopsy was negative for amyloid.

Rheumatology was also consulted and as part of the workup, she was found to have low C3 levels (54 mg/dL; reference range 90–180 mg/dL) with normal C4 (19 mg/dL; reference range 10–40 mg/dL). Complement Factor I was normal at 32.9 mcg/mL (reference range 29.3–58.5 mcg/mL) as were Factor H (B1H) levels (176 mcg/mL, reference range 160–412 mcg/mL). ADAMTS13 activity was 17%, ADAMTS13 inhibitor screen was negative. Antiphospholipid antibody panel was negative. Because of peripheral neuropathy, plasma VEGF and anti-myelin associated glycoprotein antibodies were ordered to rule out POEMS syndrome but returned negative.

Over the following days, the patient experienced multiple episodes of lactic acidosis requiring repeated intubations and severe right heart failure due to pulmonary hypertension for which she was initiated on treprostinil. Thirteen days after admission, she suffered another cardiac arrest refractory to resuscitative efforts and a partial (chest-abdomen) autopsy was requested.

Patient's family has provided informed consent. Ethical board review was waived because as a single case study, it did not qualify as human subjects research.

1.4. Autopsy

External examination was unremarkable except for a 2 cm ulcer with fat layer exposure on the dorsal aspect of the left foot (Figure 2). Bilateral serous pleural effusions were present (left 400 mL, right 900 mL). The pericardial sac contained 200 mL of serous fluid and was free of adhesions. The heart weighted 440 g (normal range for females: 148–296 g[8]). Serial sections of the coronary arteries showed no significant atherosclerosis and no thrombi. Concentric left ventricular hypertrophy was noted. The right ventricle was dilated with a wall thickness of 0.5 cm. Lungs were congested weighting each 710 g (normal range for normal BMI women 142–719 g for right lung and 143–518 g for left[9]). The spleen weighted 100 g and showed multiple subcapsular wedge-shaped infarcts. No enlarged lymph nodes were found within the thorax or abdomen. The kidneys were bilaterally atrophic weighting 50 g (right; normal range for normal BMI women 67–261 g[9]) and 60 g (left; normal range for normal BMI women 55–274 g[9]). The liver weighted 1330 g (normal range for normal BMI women 775–1946[9]) and had a nutmeg appearance.

Microscopic examination confirmed severe renal interstitial fibrosis with mostly shrunken glomeruli and concentric fibrointimal thickening of both small and large caliber arteries (Figure 2B and C). Similar changes were also seen within splenic and pulmonary arteries and arterioles, while large caliber pulmonary arteries showed atherosclerotic changes

Table 1

Previous case reports or case series of adverse events associated with proteasome-inhibitor therapy.

Author	Drug	Number of patients	Organs/systems involved	Outcome
Chan et al[10]	Bortezomib	01	Neurologic (acute disorientation and agitation, negative imaging exams), gastrointestinal (ischemic colitis), kidney (acute kidney injury)	Resolved upon discontinuation of therapy
Atallah-Yunes and Soe[11]	Ixazomib	01	Kidney (acute kidney injury with TMA)	Improved upon discontinuation of therapy
Jhaveri et al[12]	Carfilzomib	01	Kidney (acute kidney injury)	Improved upon discontinuation of therapy
Lodhi et al[13]	Carfilzomib	01	Kidney (acute kidney injury with TMA)	Improved upon discontinuation of therapy
Mehta et al[14]	Bortezomib	01	Kidney (acute kidney injury, TTP)	Resolved upon discontinuation of therapy and plasmapheresis
Wanchoo et al[15]	Carfilzomib	01	Kidney (acute kidney injury)	Improved upon discontinuation of therapy; N-acetyl cysteine reduced AKI on rechallenge
Qaqish et al[16]	Carfilzomib	02	Kidney (acute kidney injury with TMA); hematologic	Improved upon discontinuation of therapy; did not respond to plasmapheresis alone
Salmenniemi and Remes[17]	Bortezomib	01	Kidney (acute kidney injury with TMA); hematologic	Improved upon discontinuation of therapy and plasmapheresis
Sullivan et al[18]	Carfilzomib	01	Kidney (acute kidney injury with TMA)	Improved upon discontinuation of therapy and plasmapheresis
Morita et al[19]	Bortezomib	01	Kidney (mild acute kidney injury); hematologic	Improved upon discontinuation of therapy and plasma transfusions
Yui et al[5]	Bortezomib (n = 3); Carfilzomib (n = 8)	11	Hematologic (all); kidney (9 patients, acute kidney injury with TMA); gastrointestinal (6 patients); neurologic (3 patients)	Resolved upon discontinuation of therapy in 9 of 11; persistent TMA in 2 of 11
Moore et al[20]	Bortezomib	01	Kidney (acute kidney injury with TTP); hematologic	Resolved upon discontinuation of therapy; did not recur upon drug rechallenge
Hobeika et al[21]	Carfilzomib	01	Kidney (acute kidney injury with TMA)	Proteinuria and hypertension improved upon discontinuation of therapy
Honton et al[22]	Bortezomib	23	Heart (heart failure)	Improved upon discontinuation of therapy in index case, no detailed follow-up on additional 22 cases identified through registry analysis
Enrico et al[23]	Bortezomib	08	Heart (heart failure—4 patients; arrhythmia—5 patients)	No follow-up available
Dasanu[24]	Bortezomib	01	Kidney; heart (complete AV block)	Improved upon discontinuation of therapy and pacemaker placement
Gupta et al[25]	Bortezomib	01	Heart (congestive heart failure)	Improved upon discontinuation of therapy

AV = atrioventricular, CNS = central nervous system, MA = thrombotic microangiopathy, TTP = thrombotic thrombocytopenic purpura.

(Figure 2D–F). The heart showed myocyte hypertrophy, minimal fibrosis and no evidence of amyloid deposition. Liver parenchyma had centrolobular congestion and necrosis, consistent with right-sided heart failure.

2. Discussion

Here, we report the case of a patient with smoldering myeloma for which plasma-cell directed therapy including a proteasome inhibitor (PI) was indicated due to progressively worsening retinopathy. She developed acute renal failure and biopsy-proven renal thrombotic microangiopathy within a week of starting treatment; at which point, in retrospect, pulmonary hypertension was also noted and presumed to represent idiopathic pulmonary hypertension. Bortezomib was discontinued; however the patient did not recover renal function, experienced progressive retinopathy and pulmonary hypertension leading to congestive heart failure and ultimately death.

While both monoclonal gammopathy[6] as well as proteasome inhibitor therapy[1] have been associated with microangiopathic hemolytic anemia and renal thrombotic microangiopathy; to our knowledge, this is the first case of lung involvement in TMA triggered by Bortezomib therapy for monoclonal gammopathy (Table 1). TMA associated with monoclonal gammopathy has been more recently described, and so far, pulmonary involvement has not been reported (Table 2).[6]

It is postulated that monoclonal paraprotein may lead to TMA through Complement alternative pathway dysregulation, however the exact mechanism is not known. It is possible that dimeric light chains may act as an autoantibody against complement Factor H thus interfering with its inhibitory properties. Alternatively, monoclonal immunoglobulins could increase the half-life of alternative pathway C3 convertase by acting as autoantibodies to complement Factor B, akin to a C3 nephritic factor.[6,33,34]

In the case of TMA associated with PI therapy, given the presence of podocytopathy in a few cases (mostly associated with Carfilzomib use),[35] a postulated mechanism of endothelial injury is through decreased VEGF production secondary to decreased NF-kB transcription due to decreased ubiquitination of NF-kB inhibitor IkK because of proteasome inhibition therapy.[13] Finally, direct endothelial damage by the drug has also been invoked.[1]

In our patient, TMA was initially correctly presumed to be secondary to Bortezomib given the temporal association of PI therapy and TMA presentation. However, given the lack of response to drug withdrawal and progressive unremitting TMA, we postulate that Bortezomib may have been only the trigger for

Table 2

Previous case reports or case series of TMA associated with monoclonal gammopathy.

Author	Monoclonal gammopathy	Number of patients; TMA type	Organs/systems involved	Outcome
Riksen et al[26]	MGUS, IgG lambda	01; TTP	Hematologic; eyes (bilateral serous retinal detachment)	TTP resolved with plasmapheresis; laboratory studies showed M-protein didn't bind or inhibit activity of ADAMTS13 suggesting that the MGUS and TTP arose distinctly
Cheah et al[27]	Multiple myeloma, IgG lambda	01; TTP	Hematologic; kidney; cardiovascular (elevated troponin level)	TTP resolved with plasmapheresis; laboratory studies showed no ADAMTS13 inhibitor
Alpay et al[28]	Multiple myeloma, IgG kappa	01;TTP	Hematologic; neurologic (altered mental status with negative imaging exams)	TTP treated with plasmapheresis, died one week after initiation of therapy
Koga et al[29]	MGUS, IgM	01; TTP	Hematologic (anemia, thrombocytopenia); kidney	TTP treated with plasmapheresis, resolved; laboratory studies showed low ADAMTS13 level without ADAMTS13 autoantibodies suggesting the paraprotein may serve as the inhibitor
Yao et al[30]	Multiple myeloma, IgG kappa	01; TTP	Hematologic; kidney; neurologic (headaches and hallucinations, imaging exams and temporal artery biopsy negative)	TTP treated with plasmapheresis; renal failure did not resolve at follow-up
Xiao et al[31]	Multiple myeloma, IgG lambda	01; TTP	Hematologic; kidney; neurologic (delirium without focal neurologic deficits)	TTP resolved with plasmapheresis and steroids, but recurred with recurrence of the patient's myeloma
Cheungpasitporn et al[32]	MGUS; IgG kappa	01; atypical HUS	Hematologic (anemia); kidney; pulmonary (dyspnea)	a-HUS responded to treatment of the MGUS with bortezomib, lenalidomide, and dexamethasone
Ravindran et al[9]	MGUS (n=15); T-LGL (n=1); MM (n=2); POEMS (n=2)	20 (2 TTP; 9 a-HUS; 9 unclassified TMA)	Hematologic (anemia, thrombocytopenia); kidney	9 of 20 developed ESRD (on dialysis or post-transplant at follow-up)

ESRD=end-stage renal disease, HUS=hemolytic uremic syndrome, MGUS=monoclonal gammopathy of unknown significance, MM=multiple myeloma, POEMS=polyneuropathy, organomegaly, endocrinopathy, monoclonal protein, skin changes, T-LGL=T-cell large granular lymphoma, TMA=thrombotic microangiopathy, TTP=thrombotic thrombocytopenic purpura.

activation of Complement alternative pathway dysregulation related to her monoclonal gammopathy, which then remained unchecked. This is supported by the low C3 levels measured 8 months after discontinuation of Bortezomib; and the progressive end-organ-damage due to TMA in spite to prompt discontinuation, which is in strike contrast to most reports of proteasome-inhibitor associated TMA, in which the majority of cases resolved after drug withdrawal[1] (Table 1). The overall outcome of TMA associated with monoclonal gammopathy seems to be worse than that of PI-associated TMA, with up to 50% of patients progressing to end-stage renal disease (ESRD) (Table 2),[6] as was the case with our patient.

Skin lesions can also be a manifestation of Complement-mediated thrombotic microangiopathy, including ulcers with well-delimitated borders, most commonly seen in the lower limbs, similar to those seen in this patient (Figure 2A).[7]

Pulmonary involvement in thrombotic microangiopathy has been reported in adult and pediatric patients with TMA secondary to Cobalamin C deficiency,[3,4] in pediatric patients with TMA post stem cell transplantation.[5] Pulmonary hypertension due to pulmonary artery stenosis was also described in a case of pediatric atypical hemolytic uremic syndrome due to Complement Factor B mutation.[36] Complement-mediated TMA predominantly affects the renal microvasculature; however, extrarenal manifestations including central nervous system, cardiovascular, skin, pulmonary, gastrointestinal, and skeletal muscle involvement can be seen in up to 20% of patients.[37] Importantly, they have been described to occur not only during the disease acute phase but even after renal function is lost, as in our case, likely as a result of chronic over activation/dysregulation of the complement system.[37,38] Cardiovascular complications of PI therapy, including bortezomib-induced heart failure (HF),[22,25] ischemic heart disease and complete heart block[24] have also been reported (Table 1) and appear to be due to a toxic mechanism, as symptoms in most cases occurred only after high cumulative doses.[24,25] This is in contrast to our patient, who only received one cycle of bortezomib-containing chemotherapy and developed HF many months later after drug discontinuation, indicating that her HF was likely secondary to pulmonary hypertension due to chronic complement over activation as opposed to bortezomib toxicity.

Retinal involvement in multiple myeloma can occur in the form of flame-shaped, white hemorrhages, nerve fiber layer infarcts,[39] and macular edema[40] and may be an indication for plasma-cell targeted therapy. The retina can also rarely be involved in systemic TMA, where it can present as cotton wool exudates or multiple retinal detachments.[41–43] In retrospect, it is possible that this patient's retinal manifestations could in at least in part already be a manifestation of monoclonal paraprotein associated Complement dysregulation leading to microvascular injury. Because autopsy was restricted to the thorax and abdomen, histopathological examination of the retina could not be performed to confirm or rule out the presence of TMA.

Cardiac tamponade leading to death has been reported in a patient with HUS and was considered as a possibility in our case.[44] In that regard, she had been assessed multiple times by cardiology, had frequent pericardiocentesis with drainage of up to 325 mL, and in all those occasions, the possibility of tamponade had been ruled out. At postmortem examination, 200 mL of serous fluid were noted in the pericardial space, which were attributed to this patient's chronic pericardial effusions and deemed unlikely to represent cardiac tamponade in her case.

Although no anatomical cause of death was identified, patient's death was likely a result of severe pulmonary hypertension leading to cardiogenic shock. This is supported clinically by the very high PASP in the days preceding her death and morphologically by prominent cardiomegaly and right ventricular hypertrophy, and severe pulmonary microvascular obliterative changes (Figure 2D–F).

Our report has limitations that should be acknowledged. First of all, patient care took place at multiple institutions in different states; she only came to our institution during final admission and her diagnosis remained unclear until postmortem examination was completed. Therefore an alternative Complement pathway dysregulation was not thought of as a possible cause for her symptoms and more extensive testing, including functional assays, measurement of Complement activation markers and search for autoantibodies were not performed.[45] Still, we believe our findings are relevant because they show that severe lung involvement eventually leading to death can occur in TMA associated with monoclonal gammopathy, which in our case appears to have been triggered or worsened by proteasome-inhibitor therapy. Clinicians should be aware of this possibility to allow for more prompt recognition of pulmonary hypertension as a potential manifestation of monoclonal gammopathy-associated TMA.

Author contributions

Conceptualization: Clarissa A. Cassol.
Data curation: Clarissa A. Cassol, Michael P.A. Williams, Sophia Rodriguez.
Investigation: Sophia Rodriguez.
Supervision: Clarissa A. Cassol.
Writing – original draft: Clarissa A. Cassol.
Writing – review & editing: Clarissa A. Cassol, Tiffany N. Caza.
Clarissa A. Cassol: 0000-0001-7536-6806.

References

[1] Goodship TH, Cook HT, Fakhouri F, et al. Atypical hemolytic uremic syndrome and C3 glomerulopathy: conclusions from a "Kidney Disease: Improving Global Outcomes" (KDIGO) Controversies Conference. Kidney Int 2017;91:539–51.
[2] Grangé S, Bekri S, Artaud-Macari E, et al. Adult-onset renal thrombotic microangiopathy and pulmonary arterial hypertension in cobalamin C deficiency. Lancet 2015;386:1011–2.
[3] Komhoff M, Roofthooft MT, Westra D, et al. Combined pulmonary hypertension and renal thrombotic microangiopathy in cobalamin C deficiency. Pediatrics 2013;132:e540–4.
[4] Jodele S, Hirsch R, Laskin B, et al. Pulmonary arterial hypertension in pediatric patients with hematopoietic stem cell transplant-associated thrombotic microangiopathy. Biol Blood Marrow Transplant 2013;19:202–7.
[5] Yui JC, Van Keer J, Weiss BM, et al. Proteasome inhibitor associated thrombotic microangiopathy. Am J Hematol 2016;91:E348–52.
[6] Molina DK, DiMaio VJ. Normal organ weights in women: Part I-the heart. Am J Forensic Med Pathol 2015;36:176–81.
[7] Ardissino G, Tel F, Testa S, et al. Skin involvement in atypical hemolytic uremic syndrome. Am J Kidney Dis 2014;63:652–5.
[8] Molina DK, DiMaio VJ. Normal organ weights in women: Part II-the brain, lungs, liver, spleen, and kidneys. Am J Forensic Med Pathol 2015;36:182–7.
[9] Ravindran A, Go RS, Fervenza FC, Sethi S. Thrombotic microangiopathy associated with monoclonal gammopathy. Kidney Int 2017;91:691–8.
[10] Chan KL, Filshie R, Nandurkar H, Quach H. Thrombotic microangiopathy complicating bortezomib-based therapy for multiple myeloma. Leuk Lymphoma 2015;56:2185–6.
[11] Atallah-Yunes SA, Soe MH. Drug-induced thrombotic microangiopathy due to cumulative toxicity of ixazomib. Case Rep Hematol 2018;2018:7063145.
[12] Jhaveri KD, Chidella S, Varghese J, et al. Carfilzomib-related acute kidney injury. Clin Adv Hematol Oncol 2013;11:604–5.
[13] Lodhi A, Kumar A, Saqlain MU, Suneja M. Thrombotic microangiopathy associated with proteasome inhibitors. Clin Kidney J 2015;8:632–6.
[14] Mehta N, Saxena A, Niesvizky R. Bortezomib-induced thrombotic thrombocytopaenic purpura. BMJ Case Rep 2012;2012:
[15] Wanchoo R, Khan S, Kolitz JE, Jhaveri KD. Carfilzomib-related acute kidney injury may be prevented by N-acetyl-L-cysteine. J Oncol Pharm Pract 2015;21:313–6.
[16] Qaqish I, Schlam IM, Chakkera HA, et al. Carfilzomib: a cause of drug associated thrombotic microangiopathy. Transfus Apher Sci 2016;54:401–4.
[17] Salmenniemi U, Remes K. Thrombotic microangiopathy associated with bortezomib treatment in a patient with relapsed multiple myeloma. Hematol Rep 2012;4:e13.
[18] Sullivan MR, Danilov AV, Lansigan F, Dunbar NM. Carfilzomib associated thrombotic microangiopathy initially treated with therapeutic plasma exchange. J Clin Apher 2015;30:308–10.
[19] Morita R, Hashino S, Shirai S, et al. Thrombotic microangiopathy after treatment with bortezomib and dexamethasone in a patient with multiple myeloma. Int J Hematol 2008;88:248–50.
[20] Moore H, Romeril K. Multiple myeloma presenting with a fever of unknown origin and development of thrombotic thrombocytopenic purpura post-bortezomib. Intern Med J 2011;41:348–50.
[21] Hobeika L, Self SE, Velez JC. Renal thrombotic microangiopathy and podocytopathy associated with the use of carfilzomib in a patient with multiple myeloma. BMC Nephrol 2014;15:156.
[22] Honton B, Despas F, Dumonteil N, et al. Bortezomib and heart failure: case-report and review of the French Pharmacovigilance database. Fundam Clin Pharmacol 2014;28:349–52.
[23] Enrico O, Gabriele B, Nadia C, et al. Unexpected cardiotoxicity in haematological bortezomib treated patients. Br J Haematol 2007;138:396–7.
[24] Dasanu CA. Complete heart block secondary to bortezomib use in multiple myeloma. J Oncol Pharm Pract 2011;17:282–4.
[25] Gupta A, Pandey A, Sethi S. Bortezomib-induced congestive cardiac failure in a patient with multiple myeloma. Cardiovasc Toxicol 2012;12:184–7.
[26] Riksen NP, Luken BM, Klasen IS, et al. Antibodies against the CUB1-2 domains of ADAMTS13 in a patient with benign monoclonal gammopathy: no causal relationship. Haematologica 2007;92:e74–6.
[27] Cheah CY, Orlowski RZ, Manasanch EE, Oo TH. Thrombotic thrombocytopenic purpura in a patient with lenalidomide-responsive multiple myeloma. Ann Hematol 2015;94:1605–7.
[28] Alpay N, Uzun S, Bahat G, et al. Thrombotic thrombocytopenic purpura associated with multiple myeloma. Blood Coagul Fibrinolysis 2008;19:439–41.
[29] Koga T, Yamasaki S, Nakamura H, et al. Renal thrombotic microangiopathies/thrombotic thrombocytopenic purpura in a patient with primary Sjogren's syndrome complicated with IgM monoclonal gammopathy of undetermined significance. Rheumatol Int 2013;33:227–30.
[30] Yao H, Monge M, Renou M, et al. Thrombotic thrombocytopenic purpura due to anti-ADAMTS13 antibodies in multiple myeloma. Clin Nephrol 2014;81:210–5.
[31] Xiao X, Zhong HY, Zhang GS, Deng MY. Thrombotic thrombocytopenic purpura as initial and major presentation of multiple myeloma. J Thromb Thrombolysis 2013;36:422–3.
[32] Cheungpasitporn W, Leung N, Sethi S, et al. Refractory atypical hemolytic uremic syndrome with monoclonal gammopathy responsive to bortezomib-based therapy. Clin Nephrol 2015;83:363–9.
[33] Jokiranta TS, Solomon A, Pangburn MK, et al. Nephritogenic λ light chain dimer: a unique human miniautoantibody against complement factor H. J Immunol 1999;163:4590–6.
[34] Meri S. Activation of the alternative pathway of complement by monoclonal lambda light chains in membranoproliferative glomerulonephritis. J Exp Med 1992;175:939–50.
[35] Hobeika L, Self SE, Velez JCQJBn. Renal thrombotic microangiopathy and podocytopathy associated with the use of carfilzomib in a patient with multiple myeloma. BMC Nephrol 2014;15:156.

[36] Azukaitis K, Loirat C, Malina M, et al. Macrovascular involvement in a child with atypical hemolytic uremic syndrome. Pediatr Nephrol 2014;29:1273–7.
[37] Hofer J, Rosales A, Fischer C, Giner T. Extra-renal manifestations of complement-mediated thrombotic microangiopathies. Front Pediatr 2014;2:97.
[38] Noris M, Remuzzi G. Cardiovascular complications in atypical haemolytic uraemic syndrome. Nat Rev Nephrol 2014;10:174–80.
[39] Knapp AJ, Gartner S, Henkind P. Multiple myeloma and its ocular manifestations. Surv Ophthalmol 1987;31:343–51.
[40] Bernard A. [Macular manifestations of monoclonal dysgammaglobulinemias. Apropos of 3 cases]. J Fr Ophtalmol 1986;9:805–10.
[41] Benson DO, Fitzgibbons JF, Goodnight SH. The visual system in thrombotic thrombocytopenic purpura. Ann Ophthalmol 1980;12:413–7.
[42] Mohsin N, Nooyi C, Jha A, et al. Retinal injury as an early manifestation of posttransplant thrombotic microangiopathy: recovery with plasma exchanges and conversion to sirolimus–case report and review of the literature. Transplant Proc 2007;39:1272–5.
[43] Randhawa S, Sharma M. Multifocal serous detachments as the presenting sign of thrombotic thrombocytopenic purpura. Retin Cases Brief Rep 2014;8:295–9.
[44] Birk PE, Chakrabarti S, Lacson AG, Ogborn MR. Cardiac tamponade as a terminal event in the hemolytic uremic syndrome in childhood. Pediatr Nephrol 1994;8:754–5.
[45] Angioi A, Fervenza FC, Sethi S, et al. Diagnosis of complement alternative pathway disorders. Kidney Int 2016;89:278–88.