

CASE REPORT

Multidetector CT of multicentric solid pseudopapillary tumor of the pancreas: a case report and review of the literature

Shudong Hu, Xiaozhu Lin, Qi Song and Kemin Chen

Department of Radiology, Ruijin Hospital, Shanghai Jiao tong University, School of Medicine, No. 197, Ruijin Er Road, Shanghai, 200025 China

Corresponding address: Kemin Chen, MD, PhD; Department of Radiology, Ruijin Hospital, Shanghai Jiao tong University, School of Medicine, No. 197, Ruijin Er Road, Shanghai, 200025 China.
Email: keminchénrj@yahoo.cn

Date accepted for publication 13 September 2011

Abstract

Solid pseudopapillary tumor of the pancreas (SPTP) is a rare pancreatic tumor. Rarely does the tumor have a multicentric location. We report this unusual case of a 24-year-old woman who had 2 large synchronous SPTPs detected incidentally by routine physical examination. There was a 4.0×5.0 cm mass in the pancreatic head and a 7.0×8.0 cm mass in the pancreatic tail. To the best of our knowledge, 3 cases of multicentric SPTP have been reported, but none have been described in the radiology literature. We report a case and describe the CT imaging features of multicentric SPTP with a review of the literature.

Keywords: *Multicentric lesions; pancreas; solid pseudopapillary neoplasm; CT.*

Introduction

Solid pseudopapillary tumor of the pancreas (SPTP) is a rare neoplasm and is considered to have low-grade malignant potential. It primarily affects young women in their 2nd or 3rd decades of life^[1–3]. It is characterized by a well-demarcated or encapsulated mass, indolent behavior and favorable prognosis. Almost all SPTPs are solitary lesions. This case report describes the fourth reported case of a multicentric SPTP in the English literature thus far^[4–6]. We describe the multiple-phase multidetector computed tomography (CT) findings of SPTP in a 24-year-old woman who had 2 separate tumors in the head and in the tail of the pancreas, which will add evidence for accurate diagnosis and management.

Case report

A 24-year-old healthy woman was admitted to our hospital in February 2009 for further evaluation and treatment of 2 pancreatic masses detected by local hospital abdominal ultrasonography (US) at a routine physical

examination. Ultrasonography of the abdomen demonstrated multicentric masses composed of both cystic and solid components located on the head and tail of the pancreas (Fig. 1). The patient was asymptomatic with no physical signs or abnormalities. Her laboratory examinations including serum tumor markers serum carcinoembryonic antigen, CA 19-9 were within normal limits. She consumed neither tobacco nor alcohol and her past medical and family histories were negative.

Multidetector row CT of the abdomen was performed on our 64-row multidetector CT scanner (LightSpeed VCT, GE Medical Systems, Milwaukee, WI, USA). Unenhanced scan and dual phase (arterial and portal phase) were used. Coronal and sagittal multiplanar images can also be reconstructed from the axial CT dataset for reviewing. The major scanning parameters were: 120 kV, 250 mA s, a 1.0 pitch, and 0.625 mm collimation, slice thickness and slice intervals of 4 mm.

An unenhanced CT scan revealed 2 well-circumscribed heterogeneous lesions: one mass with small cystic areas arising from the head of the pancreas and the other mass with prominent degenerative cystic areas in the

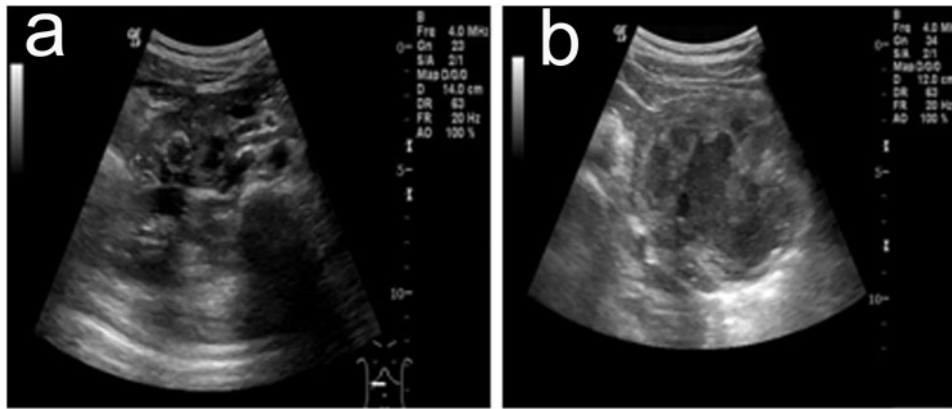


Figure 1 Preoperative abdominal US shows 2 well-defined heterogeneous masses with both solid and cystic components, located (a) in the head and (b) in the tail of the pancreas.

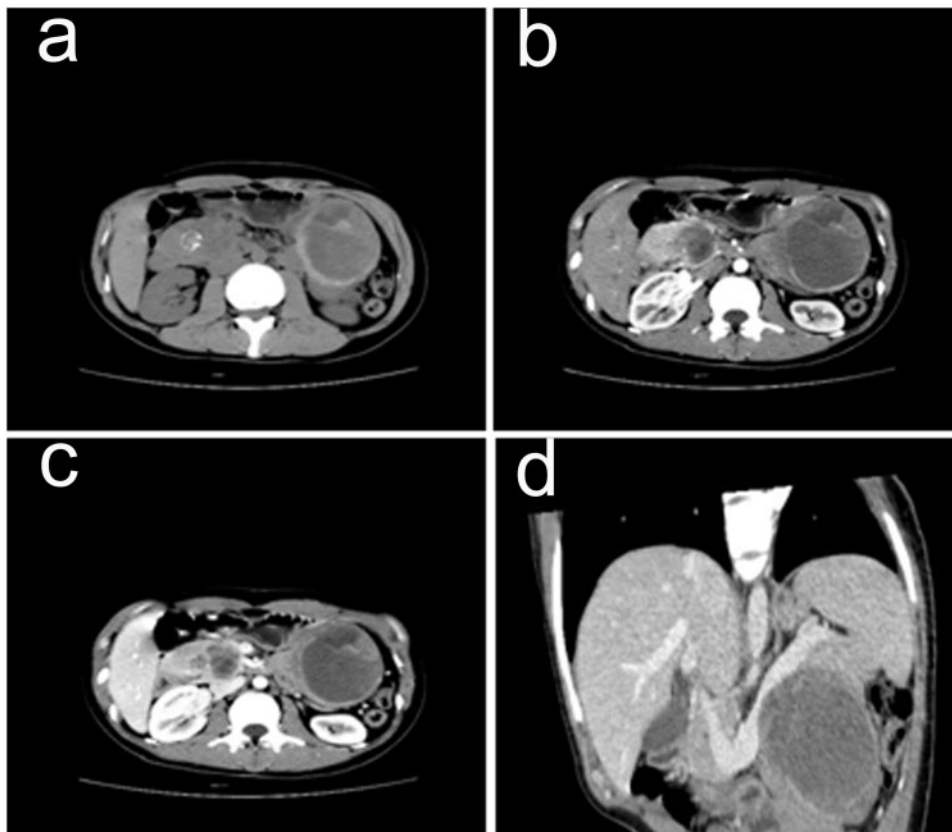


Figure 2 Preoperative abdominal CT images. (a) Unenhanced CT scan shows 2 well-circumscribed heterogeneous lesions: one mass with small cystic areas arising from the head of the pancreas and the other mass with prominent degenerative cystic areas in the pancreatic tail. The typical internal calcification was present in the pancreatic head tumor. (b,c) Solid components of the lesions appeared initially moderately enhanced and a progressive fill-in enhanced pattern during the arterial, portal phase. (d) Multiplanar reformed images demonstrated that the neoplasm in the tail of the pancreas compressed the splenic vein with a smooth border.

pancreatic tail (Fig. 2a). The 2 ovoid masses measured 4.0×5.0 cm and 7.0×8.0 cm in the head and tail of the pancreas respectively. The tumors showed complete and smooth encapsulation on the images. The 2 lesions

showed a fibrous pseudocapsule with slight hyperattenuation on unenhanced images and obviously delayed enhancement at dynamic examination. The CT scan indicated calcification in the pancreatic head. During the

arterial phase, solid components of 2 lesions appeared moderately enhanced initially and a progressive fill-in enhanced pattern (Fig. 2b,c) during the portal phase, whereas the cystic part remained unenhanced. Multiplanar reformed images can be helpful in the evaluation of the surrounding the splenic vein displacement (Fig. 2d).

A diagnosis of SPTP was considered, but was not definite, because it seemed very unusual for SPTP to be multiple. The patient underwent surgical resection for the tumor. Distal pancreatectomy without splenic preservation and pylorus-preserving pancreatoduodenectomy was performed. The patient's postoperative course was uneventful. There was no surgical morbidity after surgery.

Macroscopic examination demonstrated a 5.0-cm mass in the pancreatic head and an 8.0-cm lesion in the tail. Gross examination revealed that the 2 lesions were typically well circumscribed, with a pseudocapsule of compressed pancreatic and fibrous tissue. The cut surface showed central areas of hemorrhage and necrosis. The histologic features of the 2 tumors were similar. Microscopically, the 2 lesions revealed small cells with uniform spherical nuclei with narrow eosinophilic cytoplasm and tumoral cells forming glandular structures. Both margins were negative for the neoplasm with no perineural or vascular invasion. The tumors were separate from each other both macroscopically and microscopically. On immunohistochemical staining, the 2 lesions were positive for vimentin, α -1 antitrypsin, S-100, Cyclin D1, Nestin, and progesterone receptor, whereas they were negative for neuron-specific enolase (NSE), synaptophysin, chromogranin, CK 7, and estrogen receptor. The results of these special stains were all consistent with SPTP. Based on these findings, the pathologic diagnosis was SPTP arising synchronously and independently at 2 sites.

The patient has remained well after a 2-year follow-up with no evidence of recurrence on repeated abdominal CT scan.

Discussion

Frantz is credited as the first to describe this lesion as a distinctive neoplasm in 1959, the World Health Organization renamed it as a solid pseudopapillary tumor in 1996^[7] and it now accounts for an estimated 2–3% of primary pancreatic tumors^[8]. SPTPs can occur in every part of the pancreas. Most SPTPs originate from the pancreas. SPTP rarely develops in extrapancreatic tissues. SPTP is often detected when patients present with abdominal pain or an abdominal mass. Some patients are asymptomatic with no physical signs or abnormalities and are diagnosed at abdominal imaging, physical examination, or laparotomy performed for other reasons, including health screening, abdominal trauma, and pregnancy.

Despite a recent increase in recognition, the pathogenesis and natural history of SPTP remains unclear and the cellular derivation is yet to be determined.

Familiarity with the characteristic CT appearance and the clinical characteristics of SPTPs will help radiologists make a more confident diagnosis. Typical radiologic features of SPTPs show a large well-circumscribed tumor with a pseudocapsule composed of pancreatic tissue and fibrous change; they frequently show extensive hemorrhage and cystic changes that result in the inhomogeneous texture; calcification and enhanced solid areas are also present at the periphery of the mass^[9]. Our case was typical in all these aspects and was similar to other reported cases.

Most reported cases of SPTPs are known to be benign; however, malignant behavior does occur in 9–15% of cases^[1]. The criterion for malignant SPTP has not been firmly established yet. Pathologically, SPTP was defined as malignant if it demonstrated deep pancreatic invasion, perineural invasion, and vascular invasion according to the WHO classification. SPTPs infrequently invade the capsule and surrounding structures, mainly the spleen, portal vein, and duodenum. Goh et al.^[10] suggest that the malignant potential of SPTP cannot be predicted before surgery by age, sex, or tumor size. There are no well-known tumor markers for aggressive behavior.

Surgery is the main therapeutic modality for this low-grade malignant tumor. A good prognosis is expected after surgical resection of the primary tumor; even patients with distant metastasis have a good prognosis as long as the metastatic lesions are resected completely^[1]. A parenchyma-sparing pancreatectomy should be considered in order to avoid a total pancreatectomy, even if multicentre neoplasms involve all segments of the pancreas.

Multiple pancreatic neoplasms occur occasionally. Multiple pancreatic masses have been reported as follows: metastatic pancreatic tumor such as renal cell carcinoma, pancreatic endocrine tumor with multiple endocrine neoplasia type 1 (MEN1), von Hippel–Lindau (VHL) disease, autoimmune pancreatitis, and intraductal pancreatic mucinous neoplasm^[11–15]. To date, only 3 cases of multicentric SPTP have been reported previously in the English literature^[4–6], so our case is thought to be the fourth case. In 1991, in the first reported case, Orlando et al.^[4] described 2 synchronous lesions found on gross pathologic examination in a young black pregnant woman. She presented to the hospital in her first trimester of pregnancy with the chief complaint of sharp right upper quadrant abdominal pain that radiated to the right shoulder. She underwent total pancreatectomy and the resected pancreas included 2 separate well-circumscribed SPTPs. The larger tumor was found within the head of the pancreas and consisted of solid and cystic components; the other tumor was located within the tail and was predominantly solid tissue with focal cystic areas. In 1998, Kobayashi et al.^[5] reported the second case of multicentric SPTP in a 17-year-old girl. She had suffered from intermittent abdominal pain for 5 years. The young Japanese girl underwent surgical

resection for the tumor. Body and tail pancreatectomy without splenic preservation was performed. The larger tumor was located in the pancreas body and was predominantly solid; the smaller lesion (3×3 cm) in the tail was mostly hemorrhagic and a smaller solid component. In 2003, Lloyd and Kang^[6] described 2 synchronous lesions in a 31-year-old African American woman who presented with a 7-month history of a palpable left upper quadrant abdominal mass. The mass compressed the superior mesenteric vein and nearly encased the portal vein circumferentially. A distal pancreatectomy with splenectomy and pylorus-sparing pancreaticoduodenectomy was performed. Pathology demonstrated a 19.3-cm mass in the pancreatic tail and a histologically identical 8.5-cm lesion in the head.

The 2 lesions were different in the same patient in our present case. At the time of diagnosis, the mass in the head was smaller than that in the tail of the pancreas. The fractions of cystic versus solid material in the 2 lesions were different; the mass in the pancreatic tail had prominent degenerative cystic areas. Calcification was presented in the tumor in the pancreatic head, but was not present in the tumor in the pancreatic tail. In order to establish a definite disease entity, the origin and natural history should be clarified based on the accumulation of many, at present, atypical, cases.

Conclusion

A case is presented of a 24-year-old woman who had 2 large synchronous SPTPs involving the pancreatic head and tail that were detected incidentally by US scanning. The masses manifested typical radiologic patterns on CT. Radical surgery was carried out. The patient is free of disease after her operation at 24-month follow-up.

References

- [1] Papavramidis T, Papavramidis S. Solid pseudopapillary tumors of the pancreas: review of 718 patients reported in English

- literature. *J Am Coll Surg* 2005; 200: 965–72. doi:10.1016/j.jamcollsurg.2005.02.011.
- [2] Lin MY, Stabile BE. Solid pseudopapillary neoplasm of the pancreas: a rare and atypically aggressive disease among male patients. *Am Surg* 2010; 76: 1075–8.
- [3] Lam KY, Lo CY, Fan ST. Pancreatic Solid-cystic-papillary tumor: clinicopathologic features in eight patients from Hong Kong and review of the Literature. *World J Surg* 1999; 23: 1045–50. doi:10.1007/s002689900621.
- [4] Orlando CA, Bowman RL, Loose JH. Multicentric papillary-cystic neoplasm of the pancreas. *Arch Pathol Lab Med* 1991; 115: 958–60.
- [5] Kobayashi T, Kimura T, Takabayashi N, Sugimura H. Two synchronous solid and cystic tumors of the pancreas. *J Gastroenterol* 1998; 33: 439–42. doi:10.1007/s005350050110.
- [6] Lloyd FP, Jr, Kang J. Multifocal papillary-cystic neoplasm of the pancreas. *J Natl Med Assoc* 2003; 95: 1204–7.
- [7] Coleman KM, Doherty MC, Bigler SA. Solid-pseudopapillary tumor of the pancreas. *Radiographics* 2003; 23: 1644–8. doi:10.1148/rg.236035006.
- [8] Machado MC, Machado MA, Bacchella T, et al. Solid pseudopapillary neoplasm of the pancreas: distinct patterns of onset, diagnosis, and prognosis for male versus female patients. *Surgery* 2008; 143: 29–34. doi:10.1016/j.surg.2007.07.030.
- [9] Buetow PC, Buck JL, Pantongrag-Brown L, et al. Solid and papillary epithelial neoplasm of the pancreas: imaging-pathologic correlation on 56 cases. *Radiology* 1996; 199: 707–11.
- [10] Goh BK, Tan YM, Cheow PC, et al. Solid pseudopapillary neoplasms of the pancreas: an updated experience. *J Surg Oncol* 2007; 95: 640–4. doi:10.1002/jso.20735.
- [11] Sellner F, Tykalsky N, De Santis M, et al. Solitary and multiple isolated metastases of clear cell renal carcinoma to the pancreas. *Ann Surg Oncol* 2006; 13: 78–85.
- [12] Klöppel G, Willemer S, Stamm B, et al. Pancreatic lesions and hormonal profile of pancreatic tumors in multiple endocrine neoplasia type I. An immunocytochemical study of nine patients. *Cancer* 1986; 57: 1824–32.
- [13] Hammel PR, Vilgrain V, Terris B, et al. Pancreatic involvement in von Hippel–Lindau disease. *Gastroenterology* 2000; 119: 1087–95. doi:10.1053/gast.2000.18143.
- [14] Inoue D, Gabata T, Matsui O, et al. Autoimmune pancreatitis with multifocal mass lesions. *Radiat Med* 2006; 24: 587–91. doi:10.1007/s11604-006-0071-9.
- [15] Salvia R, Crippa S, Falconi M, et al. Branch-duct intraductal papillary mucinous neoplasms of the pancreas: to operate or not to operate? *Gut* 2007; 56: 1086–90. doi:10.1136/gut.2006.100628.