

Mediastinal Abscess Formation after EUS-Guided Sampling in a Young Patient with Sarcoidosis: Be Aware of the Increased Risk!

Miguel Bispo^a Susana Marques^a Sara Teles de Campos^a Ricardo Rio-Tinto^a
Paulo Fidalgo^a Jacques Devière^{a, b}

^aDepartment of Gastroenterology and Digestive Endoscopy, Champalimaud Foundation, Lisbon, Portugal;

^bDepartment of Gastroenterology, Hepatopancreatology, and Digestive Oncology, Erasme University Hospital – Université Libre de Bruxelles, Brussels, Belgium

Keywords

Endoscopic ultrasound-guided sampling · Mediastinal abscess · Mediastinitis · Sarcoidosis

Abstract

International guidelines establish EUS-guided sampling as safe and accurate for the evaluation of mediastinal solid lesions, such as lymphadenopathies of unknown origin, and point out an increased risk of severe infectious complications induced by needle puncture in mediastinal cystic lesions. A retrospective case series and a systematic review documented an increased risk of mediastinal abscess formation after EUS-guided lymph nodes sampling in patients with sarcoidosis. The authors describe a case of a 38-year-old male patient with a final diagnosis of sarcoidosis, who developed a large mediastinal abscess after EUS-guided fine-needle biopsy of mediastinal lymphadenopathies. Endoscopists should be aware of the potential increased risk of severe infectious complications when sampling mediastinal lymph nodes in suspected sarcoidosis, and a strategy to minimize such risk should be pursued.

© 2022 The Author(s)

Published by S. Karger AG, Basel

Abcesso mediastínico após biopsia guiada por ecoendoscopia num doente jovem com sarcoidose: atenção ao risco acrescido!

Palavras Chave

Abcesso mediastínico · Biopsia guiada por ecoendoscopia · Mediastinite · Sarcoidose

Resumo

As normas de consenso internacionais estabelecem a biopsia guiada por ecoendoscopia como segura e precisa no diagnóstico de lesões sólidas do mediastino, tais como adenopatias de origem indeterminada, e sublinham o risco significativo de complicações infecciosas graves associado à punção de lesões mediastínicas quísticas. Uma série retrospectiva e uma revisão sistemática apontaram para um risco aumentado de abcesso mediastínico após punção guiada por ecoendoscopia de gânglios linfáticos em doentes com sarcoidose. Os autores descrevem o caso clínico de um jovem de 38 anos, com o diagnóstico final de sarcoidose, que desenvolveu um volumoso abcesso mediastínico após biopsia guiada por ecoendoscopia de adenopatias mediastínicas. Os endoscopistas deverão reconhecer o risco aumentado de complicações infecciosas graves aquando da punção de adenopatias mediastínicas na suspeita de sarcoidose e procurar definir uma estratégia preventiva para minimizar o referido risco.

© 2022 The Author(s).

Published by S. Karger AG, Basel

Introduction

Endoscopic ultrasound (EUS)-guided sampling is regarded as a safe and accurate diagnostic tool for the evaluation of mediastinal lymphadenopathies and masses of unknown origin [1]. The overall incidence of adverse events associated to EUS-guided puncture is very low, and the most common adverse event is infection (pooled infection rate, 0.4–1.7%), which is significantly higher for cystic lesions compared to solid ones [2, 3]. Limited evidence is available regarding patient-related risk factors of adverse events associated to EUS-guided sampling [2]. Awareness of such risk factors is crucial in the decision-making process of sampling (when and how to puncture), in the definition of preventive strategies, and in the optimization of the informed consent process. The only well-established risk factor for infection associated to EUS-guided sampling is the puncture of cystic lesions (specifically, pancreatic cysts or mediastinal cysts) [2]. Data from a large retrospective series, including 252 patients with sarcoidosis, documented an increased risk for mediastinal abscess formation and mediastinitis after EUS-guided sampling in patients with sarcoidosis (30-fold higher than for other indications for EUS-guided nodal sampling in the mediastinum) [4]. The authors describe a case of a young patient with a final diagnosis of sarcoidosis, who developed a large mediastinal abscess after EUS-guided fine-needle biopsy (FNB) and discuss potential preventive measures to avoid such severe complication.

Case Report

A 38-year-old man with a past history of a surgically removed duodenal GIST (AJCC stage 1, R0) was referred for EUS-guided sampling for characterization of several enlarged mediastinal lymph nodes, documented on computed tomography (CT). The patient was asymptomatic and had no lung lesions or abdominal lymphadenopathies on CT. EUS documented several coalescent, crescent-shaped lymph nodes in the posterior mediastinum, with a hypoechoic homogeneous pattern, the largest with 35 × 17 mm in the subcarinal station (Fig. 1). FNB was performed using a 22-gauge fork-tip needle (SharkCore; Medtronic, Sunnyvale, CA), with three dedicated passes (until obtaining a macroscopic visible whitish core), using the fanning and stylet retraction techniques. Polymerase chain reaction for *Mycobacterium tuberculosis* and assessment of clonal B cell populations by flow cytometry were negative, and noncaseating granulomas with multinucleated giant cells, compatible with sarcoidosis, were documented on pathology (Fig. 2). Two weeks after EUS-FNB, the patient was admitted due to increasing retrosternal pain, fever (39°C), and progressive dysphagia. Serum inflammatory markers were elevated, and chest CT revealed a large subcarinal mass (54 × 45 mm) with heterogeneous liquefactive areas, consistent with a mediastinal abscess, in continuity with a thickened esophageal wall (Fig. 3). The patient was treated with intravenous

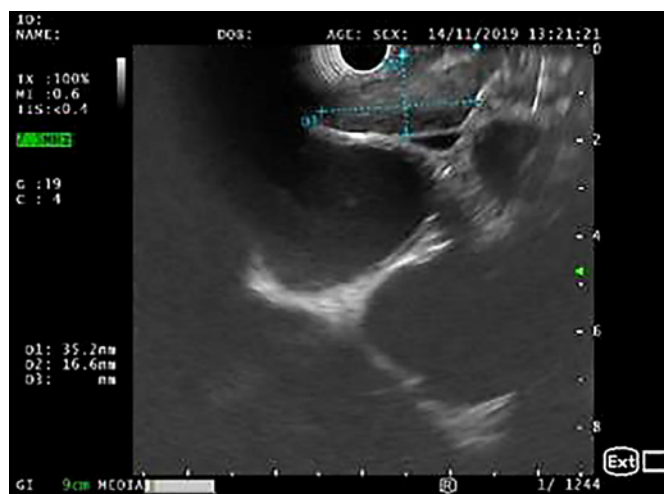

Fig. 1. EUS (linear array, transesophageal view – station 7): crescent-shaped lymph node, with 35 × 17 mm and a hypoechoic homogeneous echo pattern.

meropenem for 7 days, followed by prolonged (4 week) oral treatment with ciprofloxacin (750 mg b.i.d.) and metronidazole (500 mg t.i.d.), with progressive clinical improvement and recovering completely. Treatment duration was based on previously reported cases, where noninvasively treated patients required prolonged (at least 4-week course) antibiotic therapy [4, 5].

Discussion

Current guidelines point out a higher risk of infection after EUS-guided sampling of mediastinal cystic lesions rather than of solid lesions [1–3]. As mediastinal abscess and mediastinitis are associated to high morbidity and potential mortality, EUS-guided sampling of mediastinal cysts is globally discouraged and should be restricted to carefully selected cases [1–3]. In patients undergoing EUS-guided sampling of any cystic lesion, prophylactic antibiotic administration is recommended [1–3]. Although infection prophylaxis is not advocated for EUS-guided sampling of solid lesions (as the pooled infection rate is very low) [1–3], a retrospective case series [4] and a systematic review [5] documented an increased risk of infection, with mediastinal abscess formation, after EUS-guided puncture of lymph nodes in patients with sarcoidosis.

Sarcoidosis is a granulomatous disease affecting mostly young adults and presenting with mediastinal or hilar lymphadenopathies in 85% of cases [4]. In suspected sarcoidosis, EUS-guided sampling of mediastinal nodes is increasingly being used as it demonstrated to have higher diagnostic yield when compared to con-

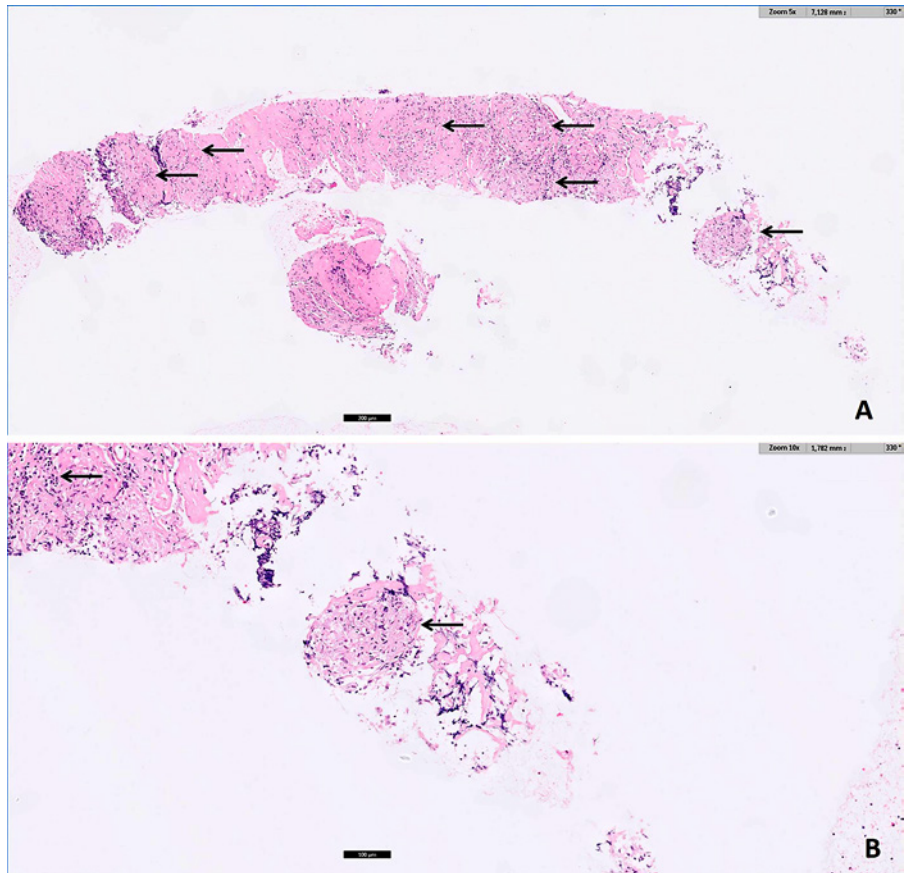


Fig. 2. Pathology (**A** H&E, $\times 5$; **B** H&E, $\times 10$): noncaseating epithelioid granulomas (arrows) with multinucleated giant cells, in a fibrotic stroma, compatible with sarcoidosis.

ventional bronchoscopy with transbronchial and endobronchial biopsies in the so-called Granuloma trial [6] and a similar diagnostic yield when compared to endobronchial ultrasound-guided sampling in the multicenter International Sarcoidosis Assessment (ISA) trial [7] (even though only first- and second-generation FNB needles were used in the EUS arm [7]). In a large series of 252 patients with the final diagnosis of sarcoidosis undergoing EUS-guided sampling, 5 patients developed mediastinal abscesses and 4 of those patients required surgical drainage [4]. This corresponded to a 30-fold higher incidence of nodal infection after EUS-guided puncture in patients with sarcoidosis compared to patients submitted to mediastinal node sampling for other indications (mostly for lung cancer staging) in the same institution [4]. An increased risk for infection after lymph node puncture in patients with sarcoidosis (caused by iatrogenic inoculation of commensal flora by the needle) may be related to the distribution of regulatory T-cells at the periphery of sarcoid granulomas, which may account for the state of anergy (poor re-

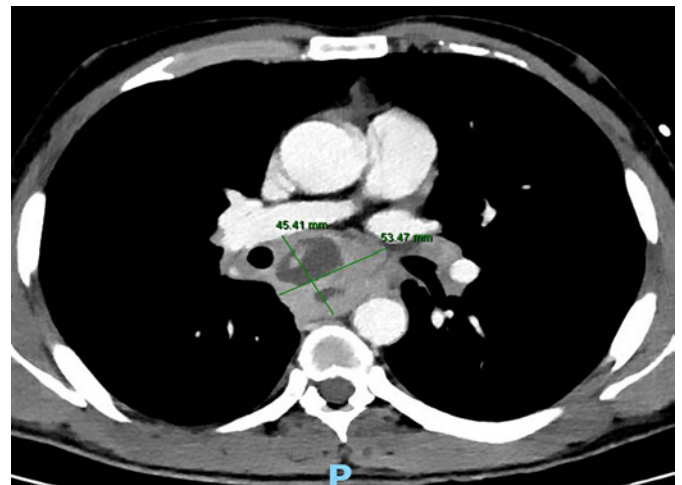


Fig. 3. Axial contrast-enhanced CT (mediastinal window): large subcarinal mass (54 \times 45 mm) with heterogeneous liquefactive areas in continuity with a thickened esophageal wall.

sponse to antigens in vitro and in vivo) that characterizes sarcoidosis [8]. Endoscopists should be aware of the potentially increased risk of infection when sampling mediastinal lymph nodes in suspected sarcoidosis and a strategy to minimize such risk should be followed, although current guidelines do not yet consider this issue. An easy strategy to minimize the infection risk may be reducing the number of needle passes, by selecting a third-generation (frontal cutting) FNB needle (with a higher diagnostic yield per pass), and using on-site evaluation to confirm sample adequacy and the presence of granulomas, thus dismissing additional passes [9–11]. The use of prophylactic antibiotics for EUS-guided mediastinal lymph node puncture in suspected sarcoidosis should also be considered, and this approach is presently followed by the authors, using an antibiotic regimen similar to the one recommended for cystic lesions puncture [2, 3]. The low frequency of infection after lymph node sampling in the suspicion of sarcoidosis (~2% [4]) would require large numbers in trials to achieve adequate statistical power, and prospective studies validating the potential benefit of antibiotic prophylaxis in this setting are unlikely to be undertaken. Since endobronchial ultrasound-guided sampling seems to have a negligible risk of infection in sarcoidosis, which may be related to a lower contamination rate of commensal flora by the needle through the respiratory tract, this sampling route may be considered in this setting [5, 7].

References

- 1 Dumonceau JM, Deprez PH, Jenssen C, Iglesias-Garcia J, Larghi A, Vanbiervliet G, et al. Indications, results, and clinical impact of endoscopic ultrasound (EUS)-guided sampling in gastroenterology: European Society of Gastrointestinal Endoscopy (ESGE) clinical guideline – updated January 2017. *Endoscopy*. 2017;49(7):695–714.
- 2 ASGE Standards of Practice Committee, Forbes N, Coelho-Prabhu N, Al-Haddad MA, Kwon RS, Amateau SK, et al. Adverse events associated with EUS and EUS-guided procedures. *Gastrointest Endosc*. 2022;95(1):16–26.e2.
- 3 ASGE Standards of Practice Committee, Khashab MA, Chithadi KV, Acosta RD, Bruining DH, Chandrasekhara V, et al. Antibiotic prophylaxis for GI endoscopy. *Gastrointest Endosc*. 2015;81(1):81–9.
- 4 von Bartheld M, van der Heijden E, Annema J. Mediastinal abscess formation after EUS-guided FNA: are patients with sarcoidosis at increased risk? *Gastrointest Endosc*. 2012; 75(5):1104–7.
- 5 von Bartheld MB, van Breda A, Annema JT. Complication rate of endosonography (endobronchial and endoscopic ultrasound): a systematic review. *Respiration*. 2014;87(4):343–51.
- 6 von Bartheld MB, Dekkers OM, Szlubowski A, Eberhardt R, Herth FJ, 't Veen JCCM, et al. Endosonography vs conventional bronchoscopy for the diagnosis of sarcoidosis: the GRANULOMA randomized clinical trial. *JAMA*. 2013;309(23):2457–64.
- 7 Crombag LMM, Mooij-Kalverda K, Szlubowski A, Gnass M, Tournoy KG, Sun J, et al. EBUS versus EUS-B for diagnosing sarcoidosis: the International Sarcoidosis Assessment (ISA) randomized clinical trial. *Respirology*. 2022;27(2):152–60.
- 8 Miyara M, Amoura Z, Parizot C, Badoual C, Dorgham K, Trad S, et al. The immune paradox of sarcoidosis and regulatory T cells. *J Exp Med*. 2006;203(2):359–70.
- 9 Bang JY, Kirtane S, Krall K, Navaneethan U, Hasan M, Hawes R, et al. In memoriam: fine-needle aspiration, birth – fine-needle biopsy – the changing trend in endoscopic ultrasound-guided tissue acquisition. *Dig Endosc*. 2019;31(2):197–202.
- 10 Tanisaka Y, Mizuide M, Fujita A, Ogawa T, Araki R, Suzuki M, et al. Comparison of endoscopic ultrasound-guided fine-needle aspiration and biopsy device for lymphadenopathy. *Gastroenterol Res Pract*. 2021;2021: 6640862.
- 11 Chen YI, Chatterjee A, Berger R, Kanber Y, Wyse J, Lam E, et al. Endoscopic ultrasound (EUS)-guided fine needle biopsy alone vs. EUS-guided fine needle aspiration with rapid onsite evaluation in pancreatic lesions: a multicenter randomized trial. *Endoscopy*. 2022; 54(1):4–12.

Acknowledgment

The authors would like to thank Dr. António Galzerano for providing histopathological images of this clinical case.

Statement of Ethics

Written informed consent was obtained from the patient for publication of this case report (including publication of images).

Conflict of Interest Statement

The authors have no conflicts of interest to declare.

Funding Sources

The authors did not receive funding support for this work.

Author Contributions

Drafting of the manuscript: M.B. Literature review, critical revision of the manuscript, and approval of the final version to be published: all listed authors.

Data Availability Statement

All data analyzed during this study are included in the article. Further inquiries can be directed to the corresponding author.