



ELSEVIER

Contents lists available at ScienceDirect

## Journal of Cardiology Cases

journal homepage: [www.elsevier.com/locate/jccase](http://www.elsevier.com/locate/jccase)

## Case Report

## Recurrent Kounis syndrome – a life-threatening event after COVID-19 vaccine administration



Inês Fialho (MD)<sup>a,\*</sup>, Carolina Mateus (MD)<sup>a</sup>, Gonçalo Martins-dos-Santos (MD)<sup>b</sup>,  
Joana Pita (MD)<sup>b</sup>, Nuno Cabanelas (MD)<sup>a</sup>, Sérgio Bravo Baptista (MD, PhD)<sup>a,c</sup>,  
David Roque (MD)<sup>a</sup>

<sup>a</sup> Cardiology Department, Fernando Fonseca Hospital, Amadora 2700-000, Portugal

<sup>b</sup> Allergy and Clinical Immunology Department, Central Lisbon University Hospital Centre, Lisbon, Portugal

<sup>c</sup> University Clinic of Cardiology - Faculty of Medicine at University of Lisbon, Lisbon, Portugal

## ARTICLE INFO

## Article history:

Received 3 September 2021

Revised 2 January 2022

Accepted 11 January 2022

## Keywords:

Kounis Syndrome

Drug hypersensitivity

Acute coronary syndrome

Coronavirus disease 2019 vaccine

## ABSTRACT

Kounis syndrome is an acute coronary syndrome occurring in the setting of a hypersensitivity reaction. It occurs as a consequence of mast-cell activation and degranulation causing coronary artery spasm, atherosclerotic plaque erosion, or stent thrombosis.

We report the case of a man who presented to the emergency department with typical angina that started 20 minutes after coronavirus disease 2019 (COVID-19) vaccine administration. Electrocardiogram showed inferior ST-elevation myocardial infarction, and coronary angiography confirmed right coronary artery stent thrombosis. Five months before, he had an acute coronary syndrome after influenza vaccine administration. Both vaccines share a common excipient, polysorbate 80. Considering the reproducibility of the reaction and the temporal association between vaccine administration and coronary events, a hypersensitivity reaction to polysorbate 80 was admitted and the patient was instructed to further avoid drugs containing it.

To our knowledge, this constitutes the first reported case of type 3 Kounis syndrome after COVID-19 vaccine administration. Kounis syndrome is an uncommon disease, often undiagnosed. Its recognition and proper management are crucial to prevent future events.

**<Learning objective:** Kounis syndrome is an acute coronary syndrome occurring in the setting of a hypersensitivity reaction and is a potential life-threatening adverse effect of multiple drugs, including vaccines. It is an uncommon disease often undiagnosed. A correct diagnosis and prompt referring for drug hypersensitivity investigation are essential to prevent future events.>

© 2022 Japanese College of Cardiology. Published by Elsevier Ltd. All rights reserved.

## Introduction

Kounis Syndrome (KS) is an acute coronary syndrome (ACS) occurring in the setting of a hypersensitivity reaction. It occurs as a consequence of mast-cell degranulation and platelet cell activation [1]. There are three variants: coronary spasm without coronary artery disease (CAD) (type I), acute myocardial infarction in patients with pre-existing CAD (type II), and coronary artery stent thrombosis (ST) (type III) [1]. Type I is the most common (72.6%) and type III the least frequent (5.1%) [2].

KS is poorly recognized in clinical practice. KS is more frequent in men and middle-aged people [2]. The most common triggers are antibiotics, non-steroidal anti-inflammatory drugs, and hy-

menoptera venom [2], although other drugs, food, or latex have also been reported as precipitating events [1]. Right coronary artery (RCA) is the most common affected artery [2].

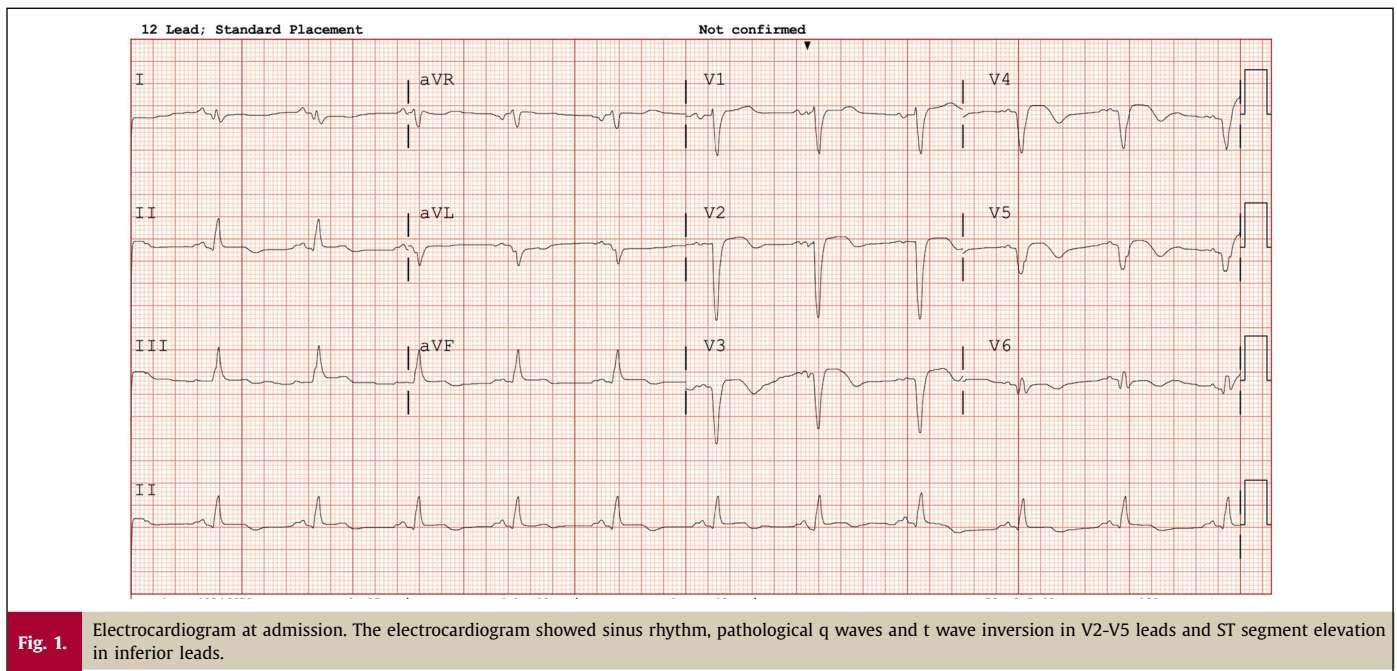
## Case report

A 59-year-old man presented to the emergency department with typical precordial pain starting 20 minutes after the ChAdOx1 severe acute respiratory syndrome coronavirus 2 (SARS-CoV2) vaccine (AstraZeneca, Cambridge, UK) administration. He was pale, sweaty, and had a discrete micropapular rash on his chest. He denied exanthema, pruritus, dyspnea, wheezing, diarrhea, or abdominal pain.

The patient had past medical history of rheumatoid arthritis, atrial fibrillation and he was a former smoker. He was not medicated with any immunosuppressive therapy. Four months before,

\* Corresponding author.

E-mail address: [ines.fialho@hff.min-saude.pt](mailto:ines.fialho@hff.min-saude.pt) (I. Fialho).



**Fig. 1.** Electrocardiogram at admission. The electrocardiogram showed sinus rhythm, pathological q waves and t wave inversion in V2-V5 leads and ST segment elevation in inferior leads.

he was admitted with a non-ST myocardial infarction presented with acute heart failure. Echocardiogram showed severe left ventricular dysfunction and invasive coronary angiography confirmed 2 vessel CAD: an occlusion of the left anterior descending (LAD) coronary artery (at the time considered chronic) and a proximal stenosis of the RCA. The RCA stenosis was treated with one drug-eluting stent (DES). After the procedure, he was started on dual antiplatelet therapy and oral anticoagulation for one month, and afterwards with clopidogrel 75 mg and rivaroxaban 20 mg, with good compliance.

At admission, the patient presented with blood pressure of 80/50 mmHg, heart rate of 65 bpm, and oxygen peripheral saturation of 96%. The arterial blood gas test showed pH 7.39, partial pressure of carbon dioxide (PaCO<sub>2</sub>) 35 mmHg, partial pressure of oxygen (PaO<sub>2</sub>) 97 mmHg, bicarbonate 21 mEq/L, and lactate 1.52 mg/dL. The electrocardiogram (Fig. 1) showed sinus rhythm, pathological q waves and t wave inversion in V2-V5 leads and ST segment elevation in II, III, and aVF leads. A ST-elevation myocardial infarction (STEMI) was admitted, and the patient underwent emergent coronary angiography with evidence of RCA ST (Fig. 2). A large occluding thrombus was aspirated. Coronary optical coherence tomography (OCT) revealed stent underexpansion. A balloon dilatation was performed, and a new DES was implanted in the proximal margin of the previous one. Blood tests at admission showed a high-sensitivity troponin T of 60 ng/L (upper limit 14 ng/mL), a creatine kinase of 32 U/L (upper limit 308 U/L), N-terminal pro-hormone of B-type natriuretic peptide of 4,455 pg/mL (upper limit 210 pg/mL), normal eosinophil count ( $0.1 \times 10^9/L$ ), and normal platelet count ( $294 \times 10^9/L$ ). The peak high-sensitivity troponin T value was 7,795 ng/L and peak creatine kinase value was 1,271 ng/L 12 hours after admission.

The temporal association between the vaccine administration and STEMI occurrence was suggestive of a causal relationship. During hospitalization, he did not have precordial pain recurrence, arrhythmias, or heart failure symptoms. Eosinophil count showed an increase-decrease pattern (Fig. 3), with a peak value of  $1.9 \times 10^9/L$  three days after ACS which returned to normal values seven days after ACS. Activated partial thromboplastin time and prothrombin time were normal. Anticardiolipin, anti $\beta$ 2microglobulin, and lu-

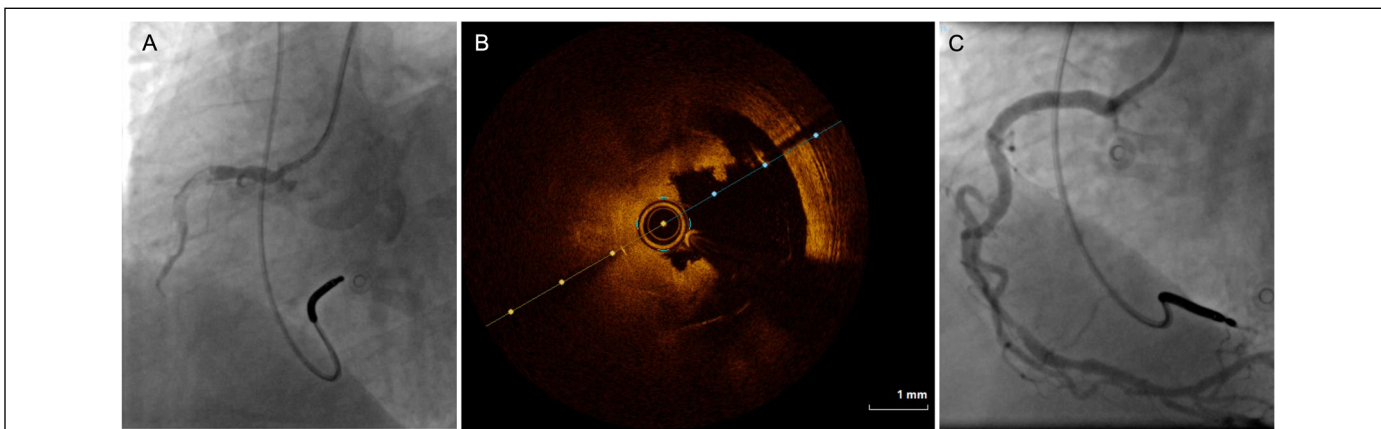
pus anticoagulant antibodies were negative. C and S protein, antithrombin III, and prothrombin deficiencies were excluded.

A more detailed medical history revealed that in the first ACS the patient had also presented typical precordial pain, dyspnea, and sweating that started 12 hours after the influenza vaccine administration (Influvac Tetra®, Abbott Biologicals B.V, Netherland). However, the patient did not recognize his symptoms as an ACS, and only presented to hospital seven days later with heart failure symptoms due to acute left ventricular dysfunction. As such, the LAD occlusion interpreted as being chronic may have been the culprit lesion of that event. In the first ACS event, the eosinophil count was normal at admission ( $0.1 \times 10^9/L$ ) and during hospitalization (peak value  $0.3 \times 10^9/L$  three days after admission).

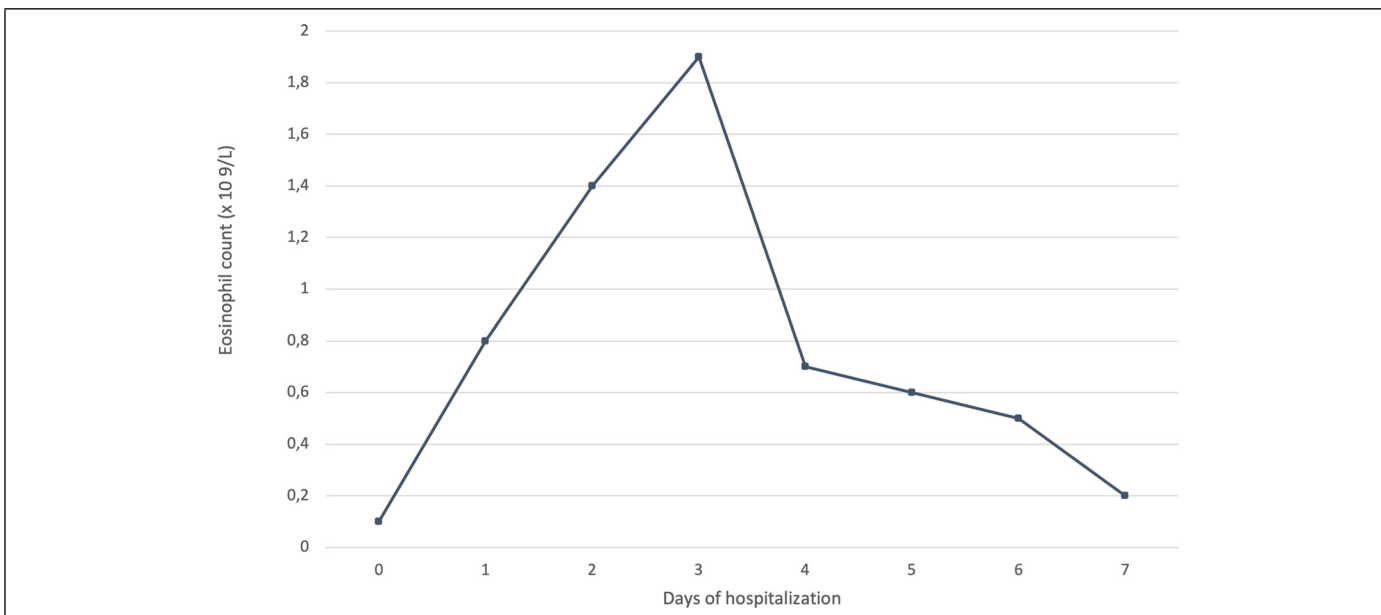
These two vaccines shared a common excipient, polysorbate-80 (PS80), admitted as the potential trigger of both events. A careful review of previous medication did not find exposure to PS80-containing drugs between influenza and COVID-19 vaccine administration. The clinical data suggested the diagnosis of KS, so the patient was referred for drug hypersensitivity diagnostic evaluation. Skin tests with intravenous amiodarone, that contains PS80, were negative. An anaphylactoid reaction (non-IgE mediated) to PS80 was admitted and the patient was advised to avoid all PS80 containing drugs, including the second dose of the ChAdOx1 SARS-CoV2 vaccine.

## Discussion

KS diagnosis is clinical, based on simultaneous symptoms of acute hypersensitivity reaction and ACS [1]. The most important finding for KS diagnosis is the time association between the triggering event and ACS, suggesting a cause-effect relationship. In our case, the reproducibility of the reaction and the temporal association between vaccines administration and coronary events suggested an adverse effect by a shared component of both vaccines. PS80 is the only common component among these vaccines, and a hypersensitivity reaction to PS80 was admitted as the most probable diagnosis. Systemic symptoms of hypersensitivity reaction did not occur in our patient. However, previous reports of KS referred the presence of skin rash and hives in only 25% of patients and



**Fig. 2.** Coronary angiography and optical coherence tomography (OCT). (A) The coronary angiography showed a thrombus settled in the right coronary artery stent previously implanted. (B) OCT images confirmed the presence of a thrombus protruding in the right coronary artery lumen. (C) Final result with a thrombolysis in myocardial infarction 3 flow after primary angioplasty.



**Fig. 3.** Eosinophil count evolution during hospitalization. The graph shows the increase-decrease pattern of the eosinophil count.

respiratory symptoms in only 15%, suggesting that the absence of systemic hypersensitivity manifestations does not exclude KS [2].

Although there is no pathognomonic test to confirm KS, some markers of drug hypersensitivity can be useful to make the diagnosis. Serum tryptase is the most useful marker and should be measured at 2 (peak level) and 24 hours or later (baseline sample) after the onset of symptoms [3]. The increase-decrease pattern of eosinophil count seen in our patient is also compatible with KS [1,2].

The definitive diagnosis of type III KS is made by documentation of eosinophils and mast cell infiltration in the coronary artery thrombus [1]. Unfortunately, the histological examination was not performed since the medical team was not aware of the possible KS diagnosis.

Immediate hypersensitivity reactions to vaccines can be explained by multiple mechanisms. The most frequent and well-understood is IgE-mediated reactions, which consists of mast cell activation via direct interaction between specific IgE against a vaccine component and the FcεR1 receptor on mast cell surface [4,5].

This reaction occurs within minutes (up to 4-6 hours) after exposure to the culprit antigen and is confirmed by specific IgE detection and increased levels of serum tryptase [4,5]. Hypersensitivity reactions can also be non-IgE-mediated, occurring through the activation of complement system and generation of anaphylatoxins, or through direct activation of mast cells by the Mas-related G protein-coupled receptor X2 [4,5].

For evaluation of IgE-mediated PS80 reaction, our patient underwent skin tests which were negative. However, negative results do not exclude PS80 non-IgE mediated hypersensitivity reactions [4]. Although drug provocation test is the gold standard for the diagnosis of drug hypersensitivity, in this case it is not recommended due to the risk of a new life-threatening reaction [3].

Other causes for coronary ST were also excluded. ST is classified as early (first 30 days after stent implantation), late (>30 days), or very late (>12 months) [6]. Procedural factors, such as stent underexpansion, malapposition, edge dissection or fracture, may act as predisposing factors for ST [6]. Stent underexpansion seems to be more frequently responsible for early ST, unlike late

and very late ST that are usually associated with stent malapposition and neoatherosclerosis [7]. However, the stent underexpansion does not seem to be the most probable cause for the ST in this case, especially in a patient compliant with antithrombotic therapy. Systemic hypercoagulable states can also contribute to ST [6], but they were excluded.

Based on the reproducibility of the reaction and the temporal association between vaccines administration and ACS, and after exclusion of other causes of ST, a non-IgE mediated hypersensitivity reaction to PS80 was considered.

### Conclusion

To our knowledge, this is the first case of type III KS after a COVID-19 vaccine administration. KS is an uncommon disease, often undiagnosed. After the acute event, the patient should be referred for hypersensitivity investigation to correctly identify the trigger, prevent further expositions, and avoid future life-threatening reactions.

### Declaration of Competing Interest

Dr Baptista reports receiving investigational grants from AstraZeneca.

### References

- [1] Kounis NG. Kounis syndrome: an update on epidemiology, pathogenesis, diagnosis and therapeutic management. *Clin Chem Lab Med* 2016;54:1545–59.
- [2] Abdelghany M, Subedi R, Shah S, Kozman H. Kounis syndrome: a review article on epidemiology, diagnostic findings, management and complications of allergic acute coronary syndrome. *Int J Cardiol* 2017;232:1–4.
- [3] Mirakian R, Ewan PW, Durham SR, Youlten LJF, Dugué P, Friedmann PS, English JS, Huber PAJ, Nasser SM. BSACI guidelines for the management of drug allergy. *Clin Exp Allergy* 2009;39:43–61.
- [4] Banerji A, Wickner PG, Saff R, Stone CA, Robinson LB, Long AA, Wolfson AR, Williams P, Khan DA, Phillips E, Blumenthal KG. mRNA vaccines to prevent COVID-19 disease and reported allergic reactions: current evidence and suggested approach. *J Allergy Clin Immunol Pract* 2021;9:1423–37.
- [5] Kounis NG, Koniari I, de Gregorio C, Velissaris D, Petalas K, Brinia A, Assimakopoulos SF, Gogos C, Kouni SN, Kounis GN, Calogiuri G, Hung M-Y. Allergic reactions to current available COVID-19 vaccinations: pathophysiology, causality, and therapeutic considerations. *Vaccines* 2021;9:221.
- [6] Claessen BE, Henriques JPS, Jaffer FA, Mehran R, Piek JJ, Dangas GD. Stent thrombosis. *JACC Cardiovasc Interv* 2014;7:1081–92.
- [7] Adriaenssens T, Joner M, Godschalk TC, Malik N, Alfonso F, Xhepa E, De Cock D, Komukai K, Tada T, Cuesta J, Sirbu V, Feldman LJ, Neumann F-J, Goodall AH, Heestermaans T, et al. Optical coherence tomography findings in patients with coronary stent thrombosis: a report of the PRESTIGE consortium (prevention of late stent thrombosis by an interdisciplinary global European effort). *Circulation* 2017;136:1007–21.