

This article is licensed under the Creative Commons Attribution-NonCommercial 4.0 International License (CC BY-NC) (<http://www.karger.com/Services/OpenAccessLicense>). Usage and distribution for commercial purposes requires written permission.

Single Case

Ascending Colon Cancer Associated with Dermatomyositis Which Was Cured after Colon Resection

Hirohiko Kamiyama^a Koichiro Niwa^a Shun Ishiyama^a
Makoto Takahashi^a Yutaka Kojima^a Michitoshi Goto^a Yuichi Tomiki^a
Yoshie Higashihara^b Kazuhiro Sakamoto^a

^aDepartment of Coloproctological Surgery, Juntendo University Faculty of Medicine, Tokyo, Japan; ^bDepartment of Gastroenterology, Juntendo University Faculty of Medicine, Tokyo, Japan

Keywords

Colon cancer · Dermatomyositis · Polymyositis · Paraneoplastic syndrome

Abstract

A 76-year-old woman with muscle ache, weakness of the extremities, and skin rash was diagnosed with dermatomyositis (DM). Upon the diagnosis of DM, a systemic survey of malignancy revealed an advanced carcinoma of the ascending colon. The patient underwent right hemicolectomy approximately 2 months after the onset of DM. The symptoms and signs of DM disappeared after the surgery without additional therapy. DM is an idiopathic systemic inflammatory disease characterized by muscle ache, muscle weakness, and skin rash. In some cases, DM develops as paraneoplastic syndrome, and it is assumed that 30% of DM patients have cancer. Symptoms and signs of DM can be attenuated by treatment of the malignancy, and they reappear if the malignancy recurs. It is essential to perform a systemic survey of malignancy in DM patients, and treatment of the malignancy has to precede treatment of DM.

© 2016 The Author(s)
Published by S. Karger AG, Basel

Introduction

Dermatomyositis (DM) is an idiopathic inflammatory myositis characterized by muscle ache, muscle weakness, and skin rash [1]. Activation and deposition of complements cause lysis of endomysial capillaries, which leads to muscle ischemia described as microangiopathy affecting the skin and muscles [1]. There is an association with malignant disease in DM [2]. In the clinical course of DM, 30% of the patients develop cancer [3]. The incidence of cancer in DM patients aged over 50 years is as high as 50% [3]. The associated cancers include cancers of the ovary, lung, breast, pancreas, stomach, colon, and prostate as well as non-Hodgkin lymphomas and others [3]. DM is regarded as a part of paraneoplastic syndrome, which is mediated by cancer-associated secretions and antibodies. Paraneoplastic syndromes are generally associated with particular cancer types, such as Lambert-Eaton myasthenic syndrome which is associated with small-cell carcinoma of the lung; thus, DM can also be associated with various types of cancer.

Here, we report a case of colon cancer found upon the diagnosis of DM. The symptoms and signs of DM in the patient disappeared after surgery. The serum creatinine kinase (CK) level of the patient was highest at the peak of muscle weakness and returned to normal within 3 weeks after surgery. The patient was free of symptoms from both diseases after surgery.

Case Report

A 76-year-old Japanese woman with muscle ache, weakness of the upper and lower extremities, and skin rash was referred to a rheumatologist at our hospital. She had first noticed a skin rash on her right elbow approximately 1 month previously. She had a past medical history of hypertension, diabetes mellitus, chronic bronchitis, angina pectoris, and cerebral lacunar infarctions. Her operative history included resection of the ovary and the uterus for ovarian cysts and uterine myoma at the age of 44 years.

On physical examination, she had a marked periorbital swelling on her face. Her neck was supple without jugular venous distensions, bruits, or lymphadenopathy. Her heart had a regular rate and rhythm without murmur. The lungs were clear to auscultation without wheezing or rales. Her abdomen was soft and flat with a normal bowel sound. She had a purple rash on her arms, chest, lumbar back, and hip. In summary, she had a heliotrope eruption (a blue-purple discoloration on the upper eyelids; fig. 1a), Gottron's sign (a raised violaceous rash or papules on the knuckles prominent in the metacarpophalangeal and interphalangeal joints), a skin eruption on the extensor surfaces of the extremities, and a shawl sign/V-sign skin rash around the neck (fig. 1b).

Blood examination showed elevated levels of CK (447 IU/l), lactate dehydrogenase (270 IU/l), complement C3 (174 mg/l), and C-reactive protein (2.6 mg/dl). The antibody against tRNA synthetases (anti-Jo-1 antibody) was negative. Electromyogram showed myogenic changes, and a muscle biopsy from the upper arm revealed myositis. Her presentations and the results of the examinations were consistent with a diagnosis of DM. There was no sign of interstitial pneumonia (IP) of the lung. Tumor markers were elevated, including carcinoembryonic antigen (18.6 ng/ml) and CA 19-9 (103 U/ml), and a fecal occult blood test was positive. A systemic survey of malignancy, including esophagogastroduodenoscopy, colonoscopy, and whole-body computed tomography (CT), was conducted and led to the diagnosis of advanced carcinoma of the ascending colon (fig. 2). No metastatic disease was found on the CT.

She underwent right hemicolectomy approximately 2 months after the onset of DM. The drastic improvement of the redness of the skin lesions was observed on the first postoperative day (POD). Muscle ache and muscle weakness disappeared gradually in the weeks after surgery. CK also decreased to normal levels within 3 weeks after surgery (fig. 3). During the postoperative course, she encountered mild respiratory dysfunction and mild heart failure on POD 18, which required strict control of infusion. She also had a candida infection, supposedly related to the central vein catheter placed in her right internal jugular vein on the day of the surgery. She had recovered from the surgery and was discharged on POD 53.

Histologically, the tumor of the ascending colon was a mucinous adenocarcinoma which had invaded the subserosa without vein and lymph ductal invasion. There was no metastasis in twelve harvested lymph nodes. The patient has been free from both diseases for 2 years under watchful observation without any adjuvant therapy.

Discussion

DM is an idiopathic inflammatory myositis with characteristic cutaneous manifestations, whereas cases without cutaneous manifestations are diagnosed as polymyositis (PM) [1]. The incidence of DM is 60 per million in Japan, which is much higher than 5–10 per million in the United States [4]. It is three times more common in females than in males. There is a major peak of onset of DM at the age of 40–60 years and a minor peak at 5–15 years [4].

There is an association between DM and cancer. The organs commonly affected by cancer in Japanese DM patients are the stomach, lung, and breast [4]. Cancer patients with DM have a higher mortality rate than those without DM [5]. Most of the malignancies in DM patients are diagnosed within 1 year before and after the diagnosis of DM [2]. There is a higher incidence of cancer in DM than in PM, and the severity of the cutaneous presentations could be related to the malignancy [3]. For example, vesicle forms in the skin lesions are related to a higher incidence of concomitant malignancy in DM [6]. DM/PM patients who are anti-Jo-1 antigen positive are more likely to develop polyarthritis and IP. DM patients who are anti-Jo-1 antigen negative are more prone to have cancer than those who are anti-Jo-1 antigen positive [7]. Clinical symptoms and signs of DM are attenuated by treatment of the malignancy and reappear if the malignancy recurs. One third of the DM/PM patients with cancer are cured by successful treatment of cancer such as resection of the tumor [5]. Thirty percent of DM/PM patients present with IP, and IP related to DM/PM also disappears after successful treatment of cancer [8].

The peak of the serum CK level in the present patient was paralleled by the peak of muscle weakness (fig. 3). Although she had not begun any treatment for DM, the CK level began to decrease before surgery. The reason for this early decrease in the CK level is unknown. Considering the short half-life of CK (3–15 h, varying in isozymes), the myositis might have reached a plateau for some reasons, and the CK started draining away. Eventually, the CK returned to normal ranges after surgery. The pulmonary dysfunction and acute heart failure in the postoperative course might be due to DM or surgical stress. DM rarely involves myocardial muscle fibers; however, cardiac involvement such as congestive heart failure is well described. Hypoventilation due to a weakness of the respiratory muscles could cause pulmonary dysfunction even in DM without IP.

Finally, it is essential to perform a systemic survey of malignancy in DM patients, since there is a high incidence of cancer in DM. Therapy of the malignancy has to precede therapy of DM, because DM will possibly be cured by a successful treatment of the malignancy.

Acknowledgement

The authors would like to thank Dr. Kurisu Tada, Dr. Michihiro Ogasawara, Dr. Hiroshi Morichika, and Prof. Sumio Watanabe.

Statement of Ethics

The authors have no ethical conflicts to disclose.

Disclosure Statement

The authors declare that they have no conflicts of interest.

References

- 1 Dalakas MC, Hohlfeld R: Polymyositis and dermatomyositis. *Lancet* 2003;362:971–982.
- 2 Sigurgeirsson B, Lindelof B, Edhag O, Allander E: Risk of cancer in patients with dermatomyositis or polymyositis. A population-based study. *N Engl J Med* 1992;326:363–367.
- 3 Hill CL, Zhang Y, Sigurgeirsson B, Pukkala E, Mellemkjaer L, Airio A, Evans SR, Felson DT: Frequency of specific cancer types in dermatomyositis and polymyositis: a population-based study. *Lancet* 2001;357:96–100.
- 4 Japan Intractable Disease Information Center. www.nanbyou.or.jp.
- 5 Andras C, Ponyi A, Constantin T, Csiki Z, Szekanecz E, Szodoray P, Danko K: Dermatomyositis and polymyositis associated with malignancy: a 21-year retrospective study. *J Rheumatol* 2008;35:438–444.
- 6 Kubo M, Sato S, Kitahara H, Tsuchida T, Tamaki K: Vesicle formation in dermatomyositis associated with gynecologic malignancies. *J Am Acad Dermatol* 1996;34(2 Pt 2):391–394.
- 7 Chinoy H, Fertig N, Oddis CV, Ollier WE, Cooper RG: The diagnostic utility of myositis autoantibody testing for predicting the risk of cancer-associated myositis. *Ann Rheum Dis* 2007;66:1345–1349.
- 8 Ponyi A, Constantin T, Garami M, Andras C, Tallai B, Vancsa A, Gergely L, Danko K: Cancer-associated myositis: clinical features and prognostic signs. *Ann NY Acad Sci* 2005;1051:64–71.

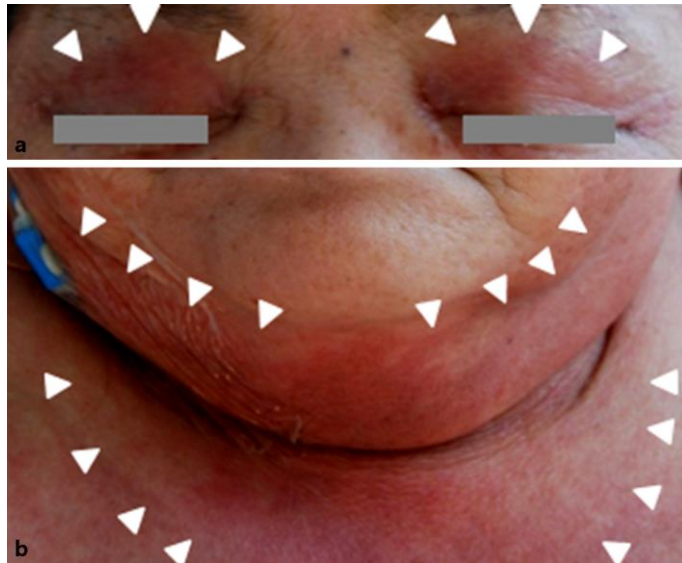


Fig. 1. **a** Heliotrope eruption: a blue-purple discoloration on the upper eyelids can be observed. **b** Shawl sign/V-sign skin rash around the neck.

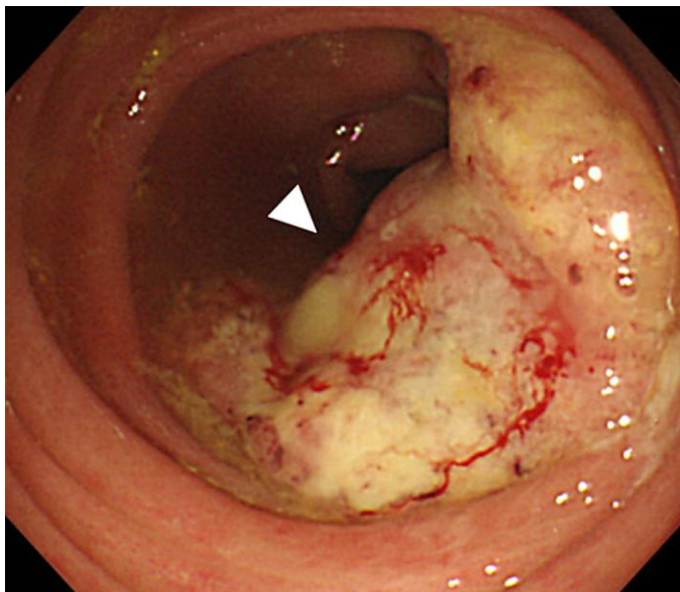


Fig. 2. Colonoscopy revealed advanced cancer in the ascending colon.

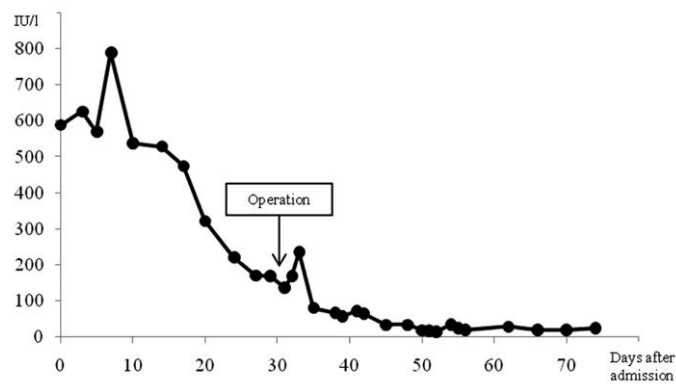


Fig. 3. Transition of serum CK in the patient.