

CASE REPORT

Successful treatment of suspect *Babesia*-induced ARDS in a dog using lung-protective positive-pressure ventilation and neuromuscular blockade

Ian M. DeStefano¹  | Annie S. Wayne²  | Sarah E. Cudney³  | Elizabeth A. Rozanski¹ 

¹Department of Clinical Sciences, Cummings School of Veterinary Medicine, Tufts University, North Grafton, Massachusetts, USA

²Department of Emergency and Critical Care, Massachusetts Veterinary Referral Hospital, Ethos Veterinary Health, Woburn, Massachusetts, United States

³Department of Emergency and Critical Care, ACCESS Specialty Animal Hospitals, Los Angeles, California, USA

Correspondence

Ian M. DeStefano, Cummings School of Veterinary Medicine, Tufts University, 55 Willard Street, North Grafton, MA 01536, USA.
Email: ian.destefano@tufts.edu

Abstract

A mixed breed dog was treated for severe hemolytic anemia secondary to *Babesia canis* infection. Within 14 hours of hospitalization, the dog developed respiratory distress and hypoxemia. The patient improved with lung-protective mechanical ventilation and neuromuscular blockade. The dog survived to discharge and was reportedly healthy at three-month follow-up.

KEYWORDS

babesiosis, critical care medicine, infectious disease, respiratory medicine

1 | INTRODUCTION

Babesiosis is a tick-borne infection caused by several parasitic hematoprotzoal organisms belonging to the *Babesia* genus. Several pathogenic species have been documented in dogs, but in the United States, *B. canis* and *B. gibsoni* are most common.^{1–3} Transmission occurs through a variety of mechanisms, such as the bite of an infected *Rhipicephalus sanguineus* tick, transplacental and direct blood–blood contact, dog bites, and contaminated blood transfusion.¹ A variety of clinical syndromes in dogs and people with babesiosis have been described, and the hallmark is hemolytic anemia or “uncomplicated babesiosis.”¹ Immune-mediated hemolysis, increased erythrocyte osmotic fragility, direct cellular injury by piroplasms,

and oxidative injury have all been proposed as causes of hemolysis.¹

In addition to anemia, other severe clinical syndromes have been described in people and dogs.^{4–7} Sequelae of babesiosis unrelated to hemolysis are termed “complicated babesiosis” and are associated with worse prognosis.⁴ There are no consensus definitions of complicated vs. uncomplicated babesiosis in veterinary medicine, but complicated infections may include sequelae such as pancreatitis, acute kidney injury, cerebral babesiosis, or hepatopathy.

Babesia-induced acute respiratory distress syndrome (ARDS) is a late and rare complication of human babesiosis cases, first reported in 1984 as a single case report⁵ and not again until 1994.⁶ The incidence of *Babesia*-induced

ARDS in dogs is unknown, partially because case reports documenting respiratory distress in this population do not report diagnostic information to evaluate for ARDS criteria. However, several studies have shown poor outcome in dogs with complicated babesiosis that include respiratory signs, as well as histologic evidence of ARDS in a dog with cerebral babesiosis.^{4,8,9} The successful management of severe respiratory failure and suspected ARDS in a dog with naturally occurring babesiosis has not previously been described.

2 | CASE REPORT

2.1 | Clinical history

An approximately 11-week-old intact male mixed breed dog was presented to the emergency service as a referral for severe anemia and suspected babesiosis. The dog had a history of being transported from Texas 3 weeks prior. One week after transport, the dog was evaluated by his primary veterinarian for acute onset of lethargy, where he was febrile (40.4°C) with an otherwise normal physical exam. An in-house complete blood cell count (CBC) showed a severe microcytic (MCV 61 fL, reference interval [RI] 61.6–73.5 fL), normochromic (MCHC 347 g/L, RI 320–379 g/L), non-regenerative (reticulocyte count $6.3 \times 10^9/L$, RI 10.0–110.0 $\times 10^9/L$) anemia (HCT 0.147 L/L, RI 0.373–0.617 L/L), a normal leukocyte ($6.29 \times 10^9/L$, RI 5.05–16.76 $\times 10^9/L$) and neutrophil count ($4.57 \times 10^9/L$, RI 2.95–11.84 $\times 10^9/L$), and severe thrombocytopenia (platelet count $23 \times 10^9/L$, RI 148–484 $\times 10^9/L$). The dog was treated with 15 ml/kg of packed red blood cells (pRBC) over 4 h. He was discharged home having also received 150 ml of subcutaneous fluids (unknown type) and prescribed omeprazole (10 mg PO q 24 h), sucralfate (1 gram PO q 8 h), and amoxicillin/clavulanate (10 mg/kg PO q 12 h; Clavamox, Zoetis). The fever had improved (39.4°C) before discharge. The following day he was returned to the referring hospital for recheck, where the packed cell volume (PCV) was 23%. Eight days later, the dog re-presented to his primary veterinarian due to lethargy, and the PCV was 15%. An in-house blood smear evaluation was suspicious for *Babesia*, so polymerase chain reaction (PCR) testing was submitted to a reference laboratory. The dog was discharged home with clindamycin (75 mg PO q 12 h). The next day, the owner reported that the dog was too weak to stand, prompting referral.

2.2 | Examination and treatment

On presentation, the dog was quiet and non-ambulatory. Physical examination indicated pallor with mild icterus

and splenomegaly on abdominal palpation. The dog weighed 5.75 kilograms and was normothermic (38.2°C). He was tachycardic (150 beats/minute) and tachypneic (60 breaths/minute) with normal bronchovesicular and heart sounds on auscultation. Point-of-care bloodwork showed severe anemia (PCV 14%) and low refractometric serum total protein (TP, 5.4 g/dL). A venous blood gas/electrolyte panel (NOVA Stat Profile, Nova Biomedical, Waltham, Massachusetts, USA) was consistent with compensated metabolic acidosis with elevated lactate (5.2 mmol/L). Point-of-care ultrasound evaluation of the heart and lungs showed subjective volume contraction, and no effusions or pulmonary B-lines were noted. Abdominal point-of-care ultrasound was unremarkable other than subjective splenomegaly. The dog was blood typed (DEA 1.1 positive) and major cross-matched and then admitted to the ICU. He was initially treated with 1 mg/kg IV maropitant (Cerenia, Zoetis,) and then was transfused with 14 ml/kg of pRBCs.

CBC and chemistry analysis were performed (see [Tables 1 and 2](#)), and cytologic evaluation of a blood smear by a boarded clinical pathologist showed intrerythrocytic piroplasms morphologically consistent with *Babesia canis*. The dog was treated with 6.6 mg/kg IM imidocarb (Imizol, Merck,) and was started on IV fluids (Lactated Ringer's solution, Baxter, Deerfield,) at 75 ml/kg/day. After completion of the blood transfusion, PCV/TP showed no improvement of his anemia (PCV 13%, TP 5.0) and progressive hyperlactatemia (8.2 mmol/L). The dog was noted to be more alert and was ambulatory and eupneic (36 breaths/min) but febrile (39.4°C). He was given 2.2 mg/kg diphenhydramine IM (West-Ward, Eatontow) due to concern for a transfusion reaction, and an additional 13 ml/kg pRBC were administered over 6 h. Fourteen hours after admission, the dog became tachypneic (RR >100 breaths/min) and was transferred to an oxygen chamber to provide approximately 40% fractional inspired oxygen (FiO₂). An hour later, he developed diarrhea and hypersalivation, so he was given 0.02 mg/kg atropine IV due to concern for parasympathetic signs as an adverse effect of imidocarb. Over the next hour, his tachypnea worsened, necessitating emergent endotracheal intubation using IV propofol (Abbot Animal Health, Chicago,).

During intubation, a large volume of serosanguineous/icteric fluid was produced through the endotracheal tube. Initial manual ventilation using an anesthetic machine and 100% FiO₂ yielded SpO₂ values 88%–92%. He was then switched to mechanical ventilation (MV) using a commercial ventilator (Puritan Bennett 840, Medtronic,). Initial ventilator settings are listed in [Table 3](#) (hour 0). Sedation was maintained with titrated continuous rate infusions (CRIs) of fentanyl (Hospira Inc.,) at 5–10 mcg/kg/

TABLE 1 Serial CBC values at hospital admission (day 0), during hospitalization (day 2), and at follow-up (day 14)

Complete Blood Cell Count					
Parameter (units)	Day 0	Day 2	Day 4	Day 14	Reference Interval
WBC count (x10 ⁹ /L)	19.89	39.73	22.23	11.81	4.4–15.1
HCT (L/L)	0.14	0.21	0.21	0.32	0.39–0.55
MCV (fL)	69.8	71.6	72.9	70.5	64.5–77.5
MCHC (g/L)	3.09	3.41	3.04	3.06	3.19–3.43
RDW (L/L)	0.161	0.159	0.229	0.163	0.119–0.152
Platelet count (x10 ⁹ /L)	70	99	252	314	173–486
Mean platelet volume (fL)	23.6	20.3	15	11.3	8.29–13.2
Reticulocytes (x10 ⁹ /L)	181.5	262.1	394.2	121.1	14.7–113.7
Neutrophils (x10 ⁹ /L)	14.8	31.6	13.42	6.84	2.8–11.5
Lymphocytes (x10 ⁹ /L)	4.4	6.4	6.6	3.72	1–4.8
Monocytes (x10 ⁹ /L)	0.8	1.6	1.98	0.36	0.1–1.5
Band neutrophils (x10 ⁹ /L)	0	0.4	0	0	0–0.3
nRBC (/100 WBC)	1	5	2	2	0–1
Parasites	<i>B. canis</i>	None	None	None	None

Abbreviations: HCT, hematocrit; MCV, mean corpuscular volume; MCHC, mean corpuscular hemoglobin concentration; nRBC, nucleated red blood cells; RDW, red cell distribution width; WBC, white blood cell count.

hr, midazolam (West-Ward) at 0.1–1 mg/kg/hr, and dexmedetomidine (Dexdomitor, Zoetis) at 1 mcg/kg/hr. An indwelling urinary catheter was placed, and urine output was adequate (2.3 ml/kg/hr over 12 h).

Initially, the dog's pulmonary static compliance was poor (0.7 ml/cm H₂O/kg, normal range 1–1.6 ml/cm H₂O/kg), and normoxemia measured by pulse oximetry (SpO₂) was achieved only with aggressive ventilator settings (see Table 3) and high FiO₂ (80%). Arterial catheterization/blood gas samples were not obtained due to the dog's thrombocytopenia and coagulopathy noted on point-of-care coagulation parameters (prothrombin time 20 s, RI 12–17 s; activated partial thromboplastin time > 300 s, RI 72–102 s). Blood titers were submitted to a reference laboratory to evaluate for co-infection with *Borrelia*, ehrlichiosis, anaplasmosis, and *Rickettsia rickettsii*. A 6 French, 90-cm nasogastric tube (Mila, Florence,) was placed, and the dog was started on enteral doxycycline (10 mg/kg q 24 h; PuraCap, Laurelton,). Repeat point-of-care lung ultrasound showed confluent B-lines bilaterally with no evidence of left atrial enlargement as determined by the LA:Ao ratio.

The dog's PCV improved and remained stable throughout the day (23%–24%), although he developed marked jaundice. He remained normothermic and normotensive but was dyssynchronous with the ventilator and was assessed to be in a relatively light plane of sedation. Additional sedation was added with a CRI of ketamine (Hospira Inc.) at 0.5 mg/kg/hr and propofol at 0.1–0.5 mg/kg/min titrated to effect. Adequate sedation/synchrony

was achieved, and ketamine was discontinued within a few hours.

After 10 h on MV, the dog developed progressive hypercapnia (ETCO₂ 55 mmHg). While troubleshooting, his endotracheal tube was sterilely suctioned and produced a large amount of icteric/serosanguineous fluid, which was cytologically consistent with a neutrophilic exudate and rare intracellular bacteria. Hand-held refractometry of the fluid showed a TP of 4.8 g/dL (peripheral TP was 5.6 g/dL). A sample of the fluid was submitted for aerobic culture, and piperacillin/tazobactam (50 mg/kg IV q 6 h; Auromedics, East Windsor, New Jersey, USA) was started. The dog then developed hypotension (mean arterial pressure [MAP] 65 mmHg) which was initially responsive to a fluid challenge (10 ml/kg Lactated Ringer's solution). At 12 h on MV, hypotension recurred (MAP 44 mmHg) coupled with relative oliguria (urine output 1.5 ml/kg/hr). There was no improvement with another fluid challenge (5 ml/kg), so a norepinephrine (Clarix Lifesciences, North Brunswick, New Jersey, USA) CRI was started at 0.2–0.6 mcg/kg/minute titrated to achieve a MAP of >70 mmHg and systolic blood pressure > 100 mmHg.

At 13 hours on MV, the dog developed poor oxygen saturation (SpO₂ 89%, FiO₂ 60%) and frequent tachypnea despite adequate sedation (no response to physical/auditory stimuli). An arterial blood gas showed severe hypoxemia and hypercapnia (Table 3). Ventilator settings were adjusted using a modified version of the ARDSnet protocol (see Table 4) and were titrated to meet a minimum SpO₂ > 92%. He was also given 0.1 mg/kg dexamethasone

TABLE 2 Serial serum chemistry values

Chemistry Profile					
Parameter (units)	Day 0	Day 2	Day 4	Day 14	Reference Interval
Glucose (mmol/L)	4.6	6.3	7.2		3.7–7.5
Urea nitrogen (mmol/L)	10.35	11.07	1.07		2.86–10.71
Creatinine (μ mol/L)	26.52	17.68	26.52		53.04–176.80
Phosphorus (mmol/L)	2.93	1.29	1.97		0.84–2.33
Calcium (mmol/L)	2.6	2.4	2.4		2.35–2.83
Magnesium (mmol/L)	1.0	0.95	0.8		0.9–1.5
Total protein (g/L)	48	36	40		55–78
Albumin (g/L)	22	12	16		28–40
Globulin (g/L)	26	24	24		23–42
Sodium (mmol/L)	148	146	144		140–150
Chloride (mmol/L)	110	114	109		106–116
Potassium (mmol/L)	5.2	3.2	4.9		3.7–5.4
Anion gap (mmol/L)	21	12	10		8–19
Total bilirubin (μ mol/L)	5.13	107.73	20.52		1.71–5.13
ALP (U/L)	131	234	523		12–127
GGT (U/L)	<1	3	2		0–10
ALT (U/L)	37	259	118		14–86
AST (U/L)	114	83	31		9–54
Creatine kinase (U/L)	535	856	318		22–422
Cholesterol (mmol/L)	3.83	6.06	5.31		2.12–9.19
Triglycerides (mmol/L)	0.63	22.49	1.00		0.34–3.82

ALP, alkaline phosphatase; ALT, alanine aminotransferase; AST, aspartate aminotransferase; GGT, gamma-glutamyltransferase.

(Dexaject SP, Henry Schein,) IV once. The dog's SpO₂ mildly improved initially, but he continued to have significant tachypnea despite adjusting ventilator settings to address dyssynchrony. A propofol bolus IV was given to effect to induce complete apnea, after which his oxygen saturation substantially improved (SpO₂ 98%); the decision was made to induce neuromuscular blockade with atracurium (Sagent, Schaumberg) 0.3 mg/kg IV, followed by a CRI (6–9 mcg/kg/min) which rapidly improved his ventilator synchrony. Persistent hypercapnia occurred after neuromuscular blockade was started (ETCO₂ 60–65 mmHg) but maintained adequate oxygenation.

At 24h on MV, ventilator settings had been gradually weaned while maintaining SpO₂>93%. Portable thoracic radiographs (Figure 1) showed a bilateral mixed pulmonary interstitial and alveolar lung pattern which was worse in the left lung lobes (attributed to atelectasis per a board-certified veterinary radiologist). Diagnostic considerations included ARDS or transfusion-related acute lung injury (TRALI).

At 48 hours on MV, the dog was on minimal ventilator settings (Table 3). Atracurium was discontinued, and nor-epinephrine was weaned/discontinued. Within hours, the other sedative infusions were also discontinued (fentanyl/midazolam/propofol), and his dexmedetomidine was

lowered to 0.5 mcg/kg/hour. He was extubated and left to fully recover from sedation in an oxygen cage with 30% FiO₂. Several hours later, oxygen supplementation was discontinued. The results of the pending infectious disease titers showed ehrlichiosis co-infection. His urinary catheter was removed, and he walked with mild support.

2.3 | Outcome and follow-up

On day 4 of hospitalization, the nasogastric tube was removed and the dog was discharged with amoxicillin/clavulanate (14 mg/kg PO q 12h; Clavamox, Zoetis), maropitant (1 mg/kg PO q 24h; Cerenia, Zoetis), and doxycycline (5 mg/kg PO q 12h). The airway culture was positive for low numbers of oropharyngeal contaminants (quantitatively reported as “few”), so amoxicillin/clavulanate was continued for a total of 7 days. The *Babesia* PCR testing was positive for *Babesia canis vogeli*. Fourteen days after the initial imidocarb injection, the dog was represented for recheck and was clinically well. A CBC showed improved regenerative anemia, resolved thrombocytopenia and leukocytosis, and no *Babesia* organisms (see Table 1). A second dose of imidocarb (6.6 mg/kg IM) was given

TABLE 3 Ventilator settings and patient vitals over the course of mechanical ventilation. A volume-control mode in SIMV with pressure support was used throughout the course of treatment

Time (hours)	0	2	13*	14	16	18	24	28	36	42	50**
F _{set} (breaths/min)	15	15	25	25	25	25	25	25	25	25	1
F _{tot} (breaths/min)	103	102	25	25	25	25	54	34	25	25	24
V _t (mL)	60	50	55	55	55	55	55	55	55	55	40
PS (cmH ₂ O)	10	10	8	8	8	8	8	2	2	2	2
PEEP (cmH ₂ O)	8	6	10	10	10	10	8	8	5	5	3
PIP (cmH ₂ O)	15	17	22	24	18	16	20	14	14	16	7
P _{mean} (cmH ₂ O)	9.9	9.8	15	14	11	9.3	12	10	9	8	-
C (mL/cmH ₂ O)	3.6	3.9	2.5	3.8	4.8	7.2	6	8.1	6.7	5.0	-
C _{wr} (mL/cmH ₂ O/kg)	0.7	0.75	0.48	0.73	0.92	1.38	1.15	1.56	1.29	0.96	-
I:E ratio	1:1.1	1:1.3	1:1.9	1:1.9	1:1.8	1:1.9	1:1.2	1:1.9	1:1.9	1:1.9	-
FiO ₂	1.0	0.6	0.6	0.6	0.6	0.6	0.5	0.4	0.4	0.4	0.3
SpO ₂ (%)	96	93	89	92	95	94	94	93	93	93	95
ETCO ₂ (mmHg)	49	39	71	74	57	51	35	35	60	65	-
PvCO ₂ (mmHg)	50	-	-	-	-	-	-	-	-	55	-
PaCO ₂ (mmHg)	-	-	60	-	-	-	-	-	-	-	-
PaO ₂ (mmHg)	-	-	84	-	-	-	-	-	-	-	-
P:F ratio	-	-	140	-	-	-	-	-	-	-	-

Time intervals presented in units of hours from presentation. Abbreviations: HR, heart rate (beats/minute); F_{set}, mandatory respiratory rate (breaths/minute); F_{tot}, total respiratory rate (breaths/minute); V_t, tidal volume; PS, pressure support applied to spontaneous breaths; PEEP, positive end-expiratory pressure; PIP, peak inspiratory pressure; C, static compliance; C_{wr}, static compliance indexed for body weight in kilograms; I:E ratio, inspiratory to expiratory ratio; FiO₂, fractional inspired oxygen concentration; SpO₂, pulse oximetry; ETCO₂, end-tidal carbon dioxide; PvCO₂, venous carbon dioxide tension; PaCO₂, arterial carbon dioxide tension; PaO₂, arterial oxygen tension; P:F ratio, PaO₂:FiO₂ ratio

* = prior to adopting ARDSnet settings; ** = immediately prior to extubation.

TABLE 4 Positive end-expiratory pressure and fractional inspired oxygen settings used, adapted from the ARDSnet trial¹⁰

FiO ₂	0.3	0.4	0.4	0.5	0.5	0.6	0.7	0.7	0.7	0.8	0.9	0.9	0.9	1.0
PEEP (cmH ₂ O)	5	5	8	8	10	10	10	12	14	14	14	16	18	18–24

FiO₂, fractional inspired oxygen concentration; PEEP, positive end-expiratory pressure.

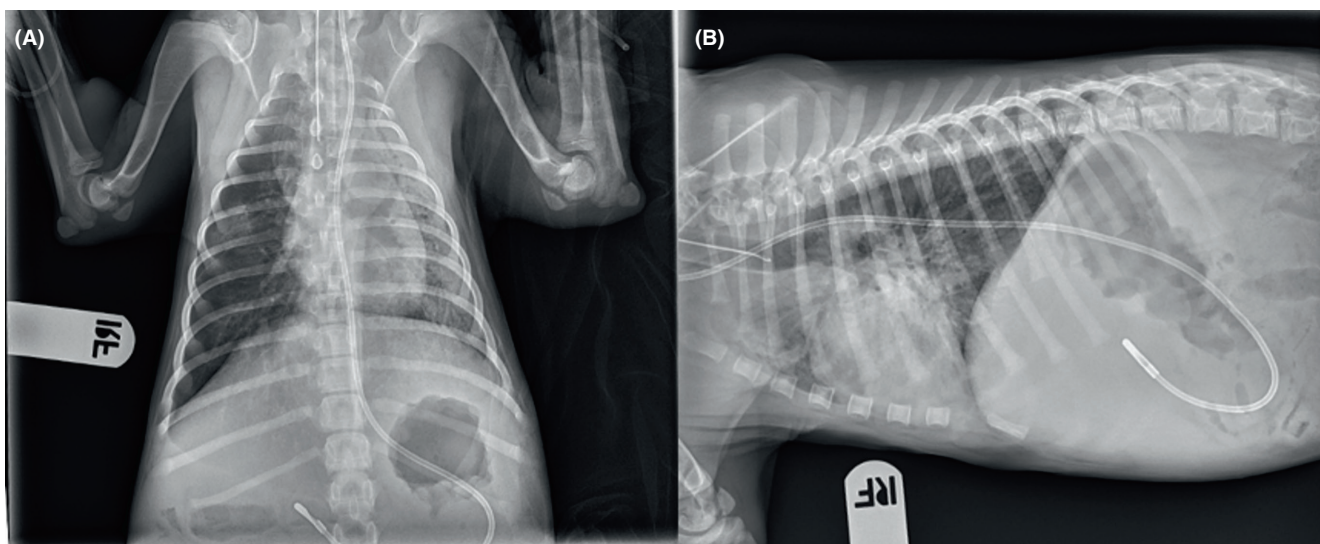


FIGURE 1 Thoracic radiographs taken 24 h after intubation. Dorsoventral (A) and right lateral views (B)

without any adverse events. The dog had complete resolution of disease and was still doing well 3 months later.

3 | DISCUSSION

To the authors' knowledge, this report details the successful management of hypoxemic respiratory failure in a dog with complicated babesiosis. While definitive evidence of ARDS was not obtained with histopathology, it remains a likely differential diagnosis. Reports of management of suspected ARDS are scarce in the veterinary literature, and this report provides clinical guidance for such patients.

Acute respiratory distress syndrome (ARDS) describes the complex clinical syndrome of lung injury, leading to downstream consequences of activation of cell-mediated immune pathways, endothelial injury, and alveolar flooding with protein-rich edema.^{10,11} This initial "exudative" phase of lung injury can be initiated secondary to several pulmonary and extra-pulmonary risk factors but ultimately leads to increased vascular permeability, pulmonary edema, atelectasis, impaired gas exchange/hypoxemia, and respiratory fatigue often requiring positive-pressure ventilation. Consensus definitions of acute lung injury and ARDS have been proposed previously for small animals.¹² Based on these criteria, the authors propose that the dog described here fulfilled VetARDS criteria based on the following: (1) acute onset (<72 h) tachypnea, (2) known risk

factors (infection/sepsis, multiple transfusions), (3) and pulmonary capillary leak as evidenced by bilateral lung infiltrates on thoracic radiographs, proteinaceous fluid within the conducting airways, and no echocardiographic evidence supporting cardiogenic pulmonary edema. The fourth criterion, evidence of inefficient gas exchange, was not directly documented at the time of respiratory decline, but arterial blood gases sampled after 12 hours of MV showed a profound hypoxemia and coupled with the findings of poor oxygen saturation immediately after intubation, prior to MV inefficient gas exchange was undoubtedly present.

The case presented here did have growth of oropharyngeal contaminant microbes on airway culture, but concurrent aspiration pneumonia cannot be completely ruled out. Several other factors make bacterial pneumonia less likely: The radiographic pulmonary changes were not classic for aspiration pneumonia, and the patient presented afebrile and had normal lung sounds, and the tachypnea at presentation resolved after initial pRBC transfusion.

Respiratory failure in people with babesiosis that meet ARDS criteria is unique from other forms of ARDS because of its delayed onset and relatively rapid resolution when compared to more typical causes. One patient who survived severe hypoxemic respiratory failure with initiation of MV was extubated on the 10th day of treatment and discharged on day 20.⁴ Another describes a babesiosis-associated ARDS patient who was extubated on day 4 of

hospitalization.⁶ The dog described here was on MV for approximately 2 days, with discharge on day 5 of hospitalization and developed suspect ARDS several weeks into his disease course. Respiratory compromise possibly attributable to ARDS has been documented in 6% of dogs with complicated babesiosis in one study, and only one dog was reported to recover, representing 3.2% (1/31) of complicated infections and 1.6% (1/63) of all infections.⁹ While the relative severity of respiratory compromise was not specified in the manuscript, all dogs were treated with oxygen supplementation.⁹ In one retrospective canine study of complicated babesiosis, 38% (32/84) of dogs died, of which 56% (18/32) had respiratory failure as the listed cause of death.⁴ Another report of respiratory distress and mental obtundation in a dog with babesiosis had histopathology changes consistent with ARDS on necropsy.⁹ Interestingly, previous reports noted that *B. canis vogeli* is associated with less severe disease except in the subpopulation of very young dogs,³ which fits the scenario presented here.

In people, ARDS historically carried a mortality rate of 40–50%, but trials in the last 20 years have shown improved outcomes with “lung-protective” ventilation strategies that include high PEEP and low tidal volumes to avoid alveolar overdistention and atelectrauma,¹³ prone positioning,¹⁴ neuromuscular blockade,¹⁵ and early use of corticosteroids¹⁶ in certain subgroups of patients. There are no studies specifically evaluating ventilation strategies of ARDS and their impact on outcome in dogs. The dog in the present report was managed with ventilation settings adapted from the human ARDSnet trial.¹³ In this case, use of PEEP titrated to FiO₂ requirements combined with neuromuscular blockade resulted in rapidly improved hypoxemia and pulmonary compliance. For the majority of the patients' MV, a slightly higher tidal volume (55 ml, ~9.6 ml/kg) was used than the lung-protective tidal volumes from ARDSnet. It is unknown whether the same tidal volumes used in people with ARDS should be applied to dogs as the proportion of lung:body weight may differ. The tidal volume in this patient was not reduced further due to hypercapnia.

At the time of initiation of neuromuscular blockade, the dog was considered heavily sedated. It is standard of care in people to meet certain criteria of sedation prior to using paralytic agents for MV, such as the Richmond agitation-sedation score [RASS].¹⁷ Ensuring a RASS of –4 to –5 (deep or unarousable sedation, respectively) helps avoid inadvertent awake paralysis in ventilated patients, which may cause ICU delirium and post-traumatic stress disorder from intensive care.¹⁶ While human sedation criteria applied to dogs have not been evaluated, we would have scored the dog a RASS of –5 despite being tachypneic/dyssynchronous with the

ventilator. The amount of sedation provided was not changed while the dog was paralyzed to avoid awake paralysis, but an optimal strategy to determine proper sedation prior to neuromuscular blockade remains unclear for dogs.

The present case report has several important limitations. Histopathologic confirmation of ARDS and full echocardiography by a cardiologist were not performed. Given that the dog responded with the therapy described and tolerated IV fluid administration, the authors feel that cardiovascular fluid overload is unlikely. Transfusion-related acute lung injury cannot be ruled out, although a blood type and crossmatch were performed prior to transfusion. In people, this complication is more commonly associated with products containing soluble antibodies such as fresh frozen plasma, but activation of primed resident pulmonary leukocytes by other blood products secondary to severe systemic inflammation is another proposed mechanism.¹⁸ While we suspect that respiratory failure was already developing prior to blood transfusion, this cannot be proven. Regardless, receiving multiple transfusions is listed as a risk factor for ARDS in people as well as the veterinary consensus definition.¹²

4 | CONCLUSION

We present here a case of suspected ARDS associated with *Babesia canis vogeli* infection in a young dog with successful application of some ARDSnet lung-protective strategies in MV and favorable outcome. While this dog made a full recovery, veterinary clinicians should be vigilant of this potential complication of babesiosis and know that while successful treatment is possible, more data are necessary to comment on the prognosis and applications of lung-protective MV in dogs with suspected ARDS.

AUTHOR CONTRIBUTIONS

Ian M DeStefano: contributed to acquisition and evaluation of case material as well as drafting, revision, and final approval of the manuscript. Annie S Wayne: contributed to revision and final approval of the manuscript. Sarah E Cudney: contributed to revision and final approval of the manuscript. Elizabeth A Rozanski: contributed to revision and final approval of the manuscript.

ACKNOWLEDGMENT

None.

FUNDING INFORMATION

No funding was obtained in conjunction with this manuscript.

CONFLICT OF INTEREST

The authors declare no conflicts of interest.

DATA AVAILABILITY STATEMENT

Data sharing is not applicable to this article.

ETHICAL APPROVAL

This case report and the patient care described therein conform to institutional ethical guidelines. Permission was granted by the owner of the dog described for publication of this case report.

CONSENT


Written informed consent was obtained from the patient's owner to publish this report in accordance with the journal's patient consent policy.

ORCID

Ian M. DeStefano  <https://orcid.org/0000-0002-3634-9971>

Annie S. Wayne  <https://orcid.org/0000-0002-8910-4724>

Sarah E. Cudney  <https://orcid.org/0000-0002-4202-7952>

Elizabeth A. Rozanski  <https://orcid.org/0000-0003-3233-8930>

REFERENCES

- Birkenheuer AJ. Babesiosis. In: Sykes JE, ed. *Canine and Feline Infectious Diseases*. 1st ed. Elsevier Saunders; 2014:727-738.
- Boozer LA, Macintire DK. Canine babesiosis. *Vet Clin Small Anim*. 2003;33:885-904.
- Zahler M, Schein E, Rinder H, Gothe R. Characteristic genotypes discriminate between *Babesia canis* isolates of differing vector specificity and pathogenicity to dogs. *Parasitol Res*. 1998;84:544-548.
- Welzl C, Leisewitz AL, Jacobson LS, Vaughan-Scott T, Myburgh E. Systemic inflammatory response syndrome and multiple-organ damage/dysfunction in complicated canine babesiosis. *J South Afr Vet Assoc*. 2001;72:158-162.
- Gordon S, Cordon RA, Mazdzer EJ, Valigorsky JM, Blagg NA, Barnes SJ. Adult respiratory distress syndrome in babesiosis. *Chest*. 1984;86:633-634.
- Horowitz ML, Coletta F, Fein AM. Delayed onset adult respiratory distress syndrome in babesiosis. *Chest*. 1994;106(4):1299-1301.
- Panduranga V, Kumar A. Severe babesiosis presenting as acute respiratory distress syndrome in an immunocompetent patient. *Crit Care Med*. 2012;40(12-S1):1-328.
- Máthé Á, Vörös K, Papp L, Reiczigel J. Clinical manifestations of canine babesiosis in Hungary (63 cases). *Acta Vet Hung*. 2006;54(3):367-385.
- Daste T, Lucas M, Aumann M. Cerebral babesiosis and acute respiratory distress syndrome in a dog. *J Vet Emerg Crit Care*. 2013;23(6):615-623.
- Taylor TB, Chambers RC, Liu KD. Acute respiratory distress syndrome. *N Engl J Med*. 2017;377(6):562-572.
- Ranieri VM, Rubenfield GD, Thompson BT, et al. Acute respiratory distress syndrome: the Berlin definition. *Jama*. 2012;307(23):2526-2533.
- Wilkins PA, Otto CM, Baumgardner JE, et al. Acute lung injury and acute respiratory distress syndromes in veterinary medicine: consensus definitions: the Dorothy Russell Havemeyer working group on ALI and ARDS in veterinary medicine. *J Vet Emerg Crit Care*. 2007;17(4):333-339.
- Brower RG, Matthay MA, Morris A, et al. Ventilation with lower tidal volumes as compared with traditional tidal volumes for acute lung injury and the acute respiratory distress syndrome. *N Engl J Med*. 2000;342(18):1301-1308.
- Guérin C, Reignier J, Richard J-C, et al. Prone positioning in severe acute respiratory distress syndrome. *N Engl J Med*. 2013;368:2159-2168.
- Papazian L, Forel J-M, Gacouin A, et al. Neuromuscular blockers in early acute respiratory distress syndrome. *N Engl J Med*. 2010;363:1107-1116.
- The National Heart, Lung, and Blood Institute acute respiratory distress syndrome (ARDS) clinical trials network. Efficacy and safety of corticosteroids for persistent acute respiratory distress syndrome. *N Engl J Med*. 2006;354:1671-1684.
- Sessler CN, Gosnell MS, Grap MJ, et al. The Richmond agitation-sedation scale: validity and reliability in adult intensive care unit patients. *Am J Respir Crit Care Med*. 2002;166(10):1338-1344.
- Marik PE, Corwin HL. Acute lung injury following blood transfusion: expanding the definition. *Crit Care Med*. 2008;36(11):3080-3084.

How to cite this article: DeStefano IM, Wayne AS, Cudney SE, Rozanski EA. Successful treatment of suspect *Babesia*-induced ARDS in a dog using lung-protective positive-pressure ventilation and neuromuscular blockade. *Clin Case Rep*. 2022;10:e06234. doi: [10.1002/ccr3.6234](https://doi.org/10.1002/ccr3.6234)