

## CASE REPORT

# Appendico ilial knotting: a rare cause of small bowel obstruction

Anteneh Tadesse Kifle<sup>1,\*</sup> and Samuel Tesfaye<sup>2</sup><sup>1</sup>Department of Surgery, Hawassa University College of Medical and Health Sciences, Hawassa, Ethiopia and<sup>2</sup>Head of Department of General Surgery, Department of Surgery, Hawassa University College of Medical and Health Sciences, Hawassa, Ethiopia

\*Corresponding author: General Surgery Resident, Department of Surgery, Hawassa University College of Medical and Health Sciences, Hawassa, Ethiopia. Tel: +251968657195; E-mail: antyeneh@gmail.com

## Abstract

Small bowel obstruction (SBO) is one of the most common acute surgical conditions that needs immediate innervation to prevent the morbidity and mortality associated with it. The common causes of SBO are different in developed and developing nations. Well-versed knowledge of the rare causes of SBO including its option of management is necessary. In this article, we present a case of an acute SBO secondary to Appendico-ileal knotting. The diagnostic difficulty and the options of management are discussed

## INTRODUCTION

Small bowel obstruction (SBO) is one of the common acute abdomen with different causes. Management of SBO needs through knowledge of the pathophysiology and causes of obstruction. The commonest causes include Adhesive SBO, Hernia, volvulus and malignancies [1–3] appendix as a cause of mechanical SBO has been well known since 1901 [4]. this has been described in literatures with different names; appendico-ileal knotting, appendicular tourniquet, appendicular knot and appendiceal tie syndrome [4–7]. It is difficult to make the diagnosis preoperatively as the patients present as SBO. The subsequent management is dictated by the intra operative finding.

## CASE REPORT

A 46-year-old-female patient presented with crampy abdominal pain of a week duration. Associated with vomiting of ingested matter which latter become bilious matter. She does not pass faeces but passes flatus. She has abdominal distention

for last 4 months which increased since the onset of cramp. On physical examination, she was tachycardia to the level of 110 beats per minute, BP 110/70 and she was maintaining her saturation on atmospheric oxygen-97%. Her temperature 37.2°C, her abdomen was distended with hyperactive bowel sound, hyper tympanic to percussion and no tenderness. On digital rectal examination, normal anal tone with empty rectum and no blood on examining finger. On investigation, she has WBC count of 10 600 with neutrophil 86%, She was referred from private setup with abdominal ultrasound which shows significant dilation of bowel loops with increased peristaltic activity and right lower quadrant blind ending tubular structure with diameter of 18 mm with hypoechoic content. On plain abdominal X-ray shows dilated small bowel loops with multiple air fluid level. (Fig. 1)

With the diagnosis SBO secondary to adhesion band, the patient was taken to the operation room after and the finding was dilated small bowel loops with closed loop obstruction at distal 8 cm of ilium by appendicular knot. At the tip of the appendix there is 4×2 cm cystic mass with no solid component.

Received: March 27, 2018. Accepted: April 18, 2018

Published by Oxford University Press and JSCR Publishing Ltd. All rights reserved. © The Author(s) 2018.

This is an Open Access article distributed under the terms of the Creative Commons Attribution Non-Commercial License (<http://creativecommons.org/licenses/by-nc/4.0/>), which permits non-commercial re-use, distribution, and reproduction in any medium, provided the original work is properly cited. For commercial re-use, please contact [journals.permissions@oup.com](mailto:journals.permissions@oup.com)

Retrograde appendectomy including mesoappendix done (Fig. 2). The biopsy result is mucous cyst adenoma with no extension in the surrounding mesoappendix and the base of the appendix. (Fig. 3) There was a pressure mark exactly at the ileocecal junction and 8 cm away from it. Post-operatively, the patient started sips on second day discharged on fifth day with post-operative diagnosis of SBO secondary to appendico-ileal knotting with appendicular mucocele.

## DISCUSSION

Acute SBO is one of the most common surgical clinical problems. It can be classified based on many factors: functional or mechanical, the small bowel (SBO) or large bowel (LBO)

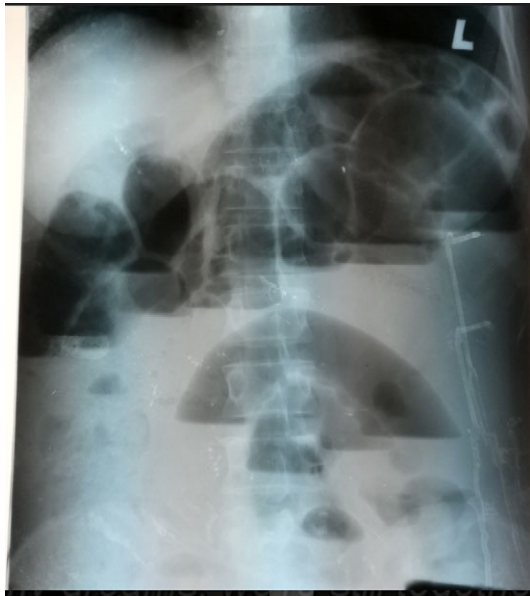


Figure 1: Erect abdominal X-ray showing multiple air fluid level with dilated small bowel loops.

obstruction, partial or complete, simple, or complicated [2]. Mechanical SBO has many etiologies, post-op adhesion being top in the developed countries. Soressa *et al.*'s study [1] in Ethiopia post-op adhesion and groyne hernia are the commonest cause of SBO. Other common etiologies include post-op adhesion and small bowel malignancies [1, 3].

Appendicitis as a cause of SBO has been known in the literature since 1901 when Lucius Hotchkiss reported three successful surgeries for intestinal obstruction due to appendicitis [4]. Bhandari *et al.* has reviewed the literature and proposed four categories on the pathology of appendicitis causing obstruction; adynamic, mechanical (without strangulation), strangulation of intestine and intestinal obstruction due to mesenteric ischaemia [8].

Strangulation can be due to the appendix wrapping around the base of a bowel loop, or when inflamed appendix adheres to caecum, small intestine or posterior peritoneum and a part of the bowel herniates through the gap. This is described with appendicular KNOT, appendicular tourniquet, appendiceal tie syndrome and appendico-ileal knotting [6, 7, 9, 10]. In our opinion, appendico-ileal knotting is the preferred name because it describes the pathologies of both appendix and ileum.

Diagnosis of SBO is made based on history and physical examination. The four cardinal signs and symptoms are colicky abdominal pain, vomiting, absolute constipation, and abdominal distension [6]. As depicted in the table, most of the patients with appendico-ileal knotting presented with abdominal pain, vomiting and constipation [4–10]. Chatterjee suggests that a period of acute appendicitis precedes the mechanical obstruction. CT scan of abdomen can suggest the diagnosis preoperatively. But as the patients are having acute abdomen, emergent exploratory laparotomy is indicated and it will confirm the diagnosis.

The management depends on the extent of the strangulation and part of bowel involved. It ranges from appendectomy to right hemicolectomy. In our case, the appendix was gangrenous with viable distal ileum so appendectomy was done. The mucocele associated with our case can be ascribed to chronic retention mucus.

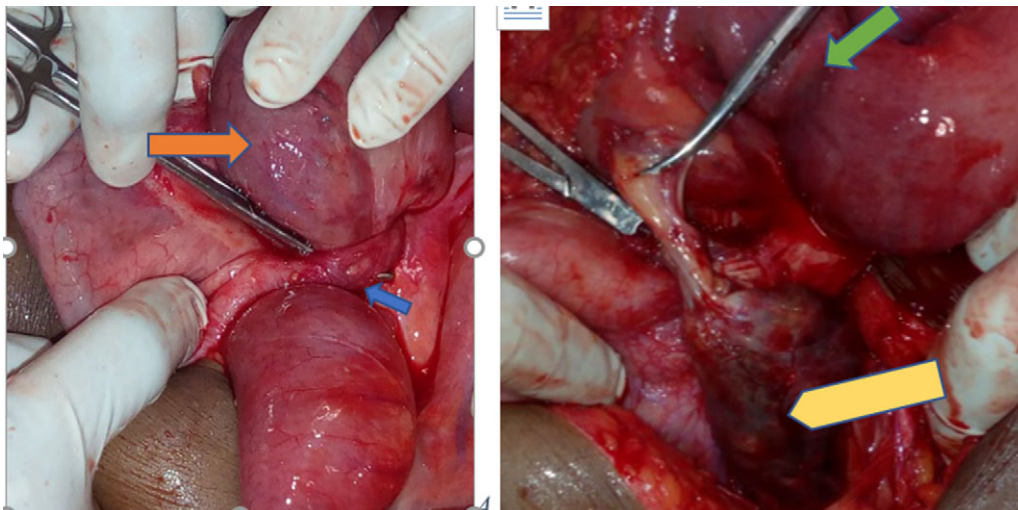


Figure 2: Appendix with mucocele entangling distal ileum forming closed loop obstruction (blue arrow—appendicular knot, orange—entangled distal ileum, green—the pressure mark on the distal ileum and yellow—gangrenous appendicular mucocele).

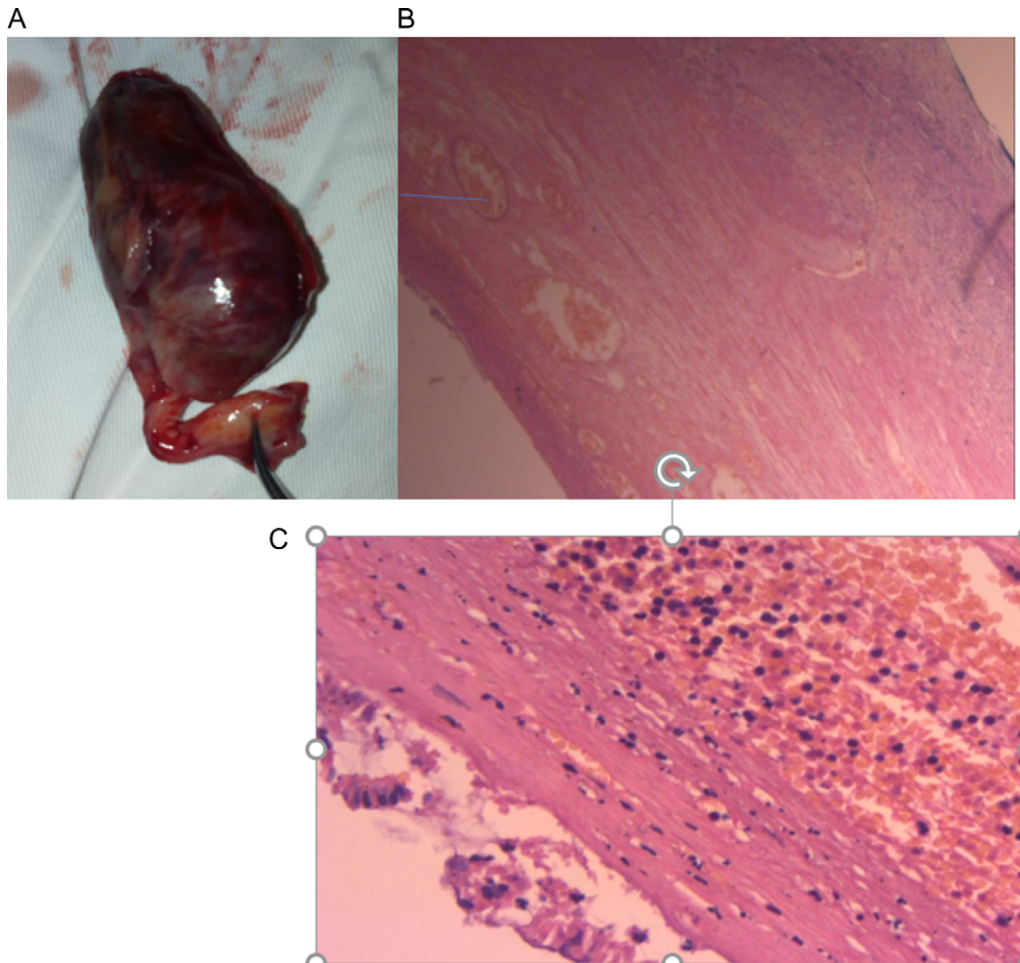


Figure 3: (A) Post-appendectomy gangrenous appendix with mucocele, (B) and (C). Histologic specimen per low power and high power field microscopy showing appendicular mucocele with some haemorrhagic infarcts with thinned out mucosa and no extension beyond the submucosa.

## CONCLUSION

Appendico ilial knotting is a rare cause of mechanical SBO. As a surgeon dealing with acute abdomen in day to day practise, knowledge about the diagnosis and management of this rare diagnosis is very helpful.

## CONFLICT OF INTEREST STATEMENT

None declared.

## REFERENCES

1. Soressa U, Mamo A, Hiko D, Fentahun N. Prevalence, causes and management outcome of intestinal obstruction in Adama Hospital, Ethiopia. *BMC Surg* 2016;**16**:38.
2. Holzheimer RG, Mannick JA. *Surgical Treatment: Evidence-Based and Problem-Oriented*. Munich: Zuckschwerdt, 2001.
3. Tsegaye S, Osman M, Bekele A. Surgically treated acute abdomen at Gondar University Hospital, Ethiopia. *East Cent Afr J Surg* 2006;**12**:53–7.
4. Hotchkiss Lucius W. Acute intestinal obstruction following appendicitis. A report of three cases successfully operated upon. *Ann Surg* 1901;**34**:660–77.
5. O'Donnell ME, Sharif MA, O'Kane A, Spence RA. Small bowel obstruction secondary to an appendiceal tourniquet. *Ir J Med Sci* 2009;**178**:101–05.
6. Ranjan A, Kumari K, Jha S. Acute small bowel obstruction as a result of an appendicular knot encircling the terminal ileum: an exceptionally rare case report. *Int J Med Sci Public Health* 2015;**4**:426–9.
7. Awale L, Joshi BR, Rajbanshi S, Adhikary S. Appendiceal tie syndrome: a very rare complication of a common disease. *World J Gastrointest Surg*, 27 2015;**7**:67–70.
8. Mohandas PG, Bhandari L. Appendicitis as a cause of intestinal strangulation: a case report and review. *World J Emerg Surg* 2009;**4**:34.
9. Yang AD, Lee C-H. Appendico-ileal knotting resulting in closed-loop obstruction in a child. *Pediatr Radiol* 2002;**32**: 879–81.
10. Chowdary PB, Shivashankar SC, Gangapp RB, Varghese EV. Appendicular tourniquet: a cause of intestinal obstruction. *J Clin Diagn Res* 2016;**10**:9–11.