

Internal jugular vein thrombosis due to heterozygote methylene tetrahydrofolate reductase (MTHFR) 1298C and Factor V G1691A mutations after a minor trauma

Department of Otolaryngology and Head and Neck Surgery, The Ministry of Health, Izmir Tepecik Training and Research Hospital, Izmir, Turkey

Murat Gumussoy, Ilker B. Arslan, Ibrahim Cukurova, Sinan Uluyol

ABSTRACT

Internal jugular vein thrombosis usually appears in central venous catheterization, distant malignancies, hypercoagulation, infections, or secondary to ovarian hyperstimulation syndrome. A 44-year-old female patient presented to us with sore throat, and pain and swelling on the right side of her neck. She had a history of simple neck trauma 10 days ago. Ultrasonography and computed tomography showed bilateral multiple lymphadenopathies and right internal jugular vein thrombosis. Patient was put on parenteral antibiotherapy and oral anticoagulant treatment. Genomic DNA tests for hypercoagulation revealed methylene tetrahydrofolate reductase 1298C heterozygote mutation and Factor V G1691A (Leiden) mutation. Patient has been under clinical control for 1 year and does not have any complaints. In this article, diagnosis, treatment, and the etiology of internal jugular vein thrombosis, which is a rare and potentially fatal condition, have been discussed through this case.

Address for correspondence:
Dr. Murat Gumussoy,
227 Sokak No. 15, A Block,
Bayrakli - 35070, Izmir, Turkey.
E-mail: mgumussoy@hotmail.com

Key words: Factor V, internal jugular vein thrombosis, methylene tetrahydrofolate reductase 1298C, thrombophilia

INTRODUCTION

Even though neck swelling and sore throat are very common in patients who present to ear, nose and throat (ENT) clinics, internal jugular vein thrombosis (IJVT) is rarely the cause of these complaints. Lateral sinus thrombophlebitis after a middle ear infection and turning into IJVT by caudal development of the infection is relatively a more common situation that is encountered in ENT.^[1] IJVT may appear spontaneously or

secondarily to trauma, intravenous (i.v.) catheterization, recurrent i.v. injections, polycythemia, neck dissection, radiotherapy, drug usage, hypercoagulability by paraneoplastic syndrome, ovarian overstimulation syndrome, deep neck infections, and oropharyngeal infections. The importance of diagnosing and treating IJVT lies in the fact that if not diagnosed, it can cause potentially fatal complications such as sepsis and pulmonary embolism.^[2,3]

CASE REPORT

A single, 44-year-old female patient presented to the clinic with the complaints of fever, sore throat, pain when swallowing, and swelling and pain on the right side of her neck. Patient stated that these complaints had started 3 days ago. She had a history of simple neck trauma, a slap stroke, nearly 10 days ago. She was not admitted to

Access this article online	
Quick Response Code: 	Website: www.njms.in
	DOI: 10.4103/0975-5950.154824

any health clinic or emergency service for this and had no complaints until 3 days before presentation. There was no history of regular drug use, smoking, malignancy, catheterization, or oropharyngeal infection.

On physical examination, the oral cavity and oropharynx were found to be normal. Endoscopic examination of the nasal cavity, nasopharynx, and larynx was normal. Her neck examination showed an approximately 3 × 4 cm sized swelling that caused minimal temperature rise above the skin, but did not cause hyperemia, and it was found on the carotid triangle of the right side of the neck. The palpation and sensitivity were also felt along the internal jugular vein region [Figure 1]. In addition to these, multiple palpable lymphadenopathies (LAPs) were present in the upper right and middle jugular sections.

Laboratory findings were as follows: Hemoglobin (Hb): 13.9 g/dl, leukocyte: 11,300/mm³, neutrophils: 71.2%, lymphocytes: 18.2%, prothrombin time (PT): 22.2 sec, activated partial thromboplastin time (aPTT): 51.1 sec, International Normalized Ratio (INR): 1.87, erythrocyte sedimentation rate: 40 mm/h, alanine transaminase (ALT): 12 U/l, aspartate transaminase (AST): 23 U/l, blood urea nitrogen (BUN): 23 mg/dl, and creatinine: 0.8 mg/dl; urine analysis and chest X-ray radiography were normal.

Neck ultrasonography (USG) revealed lamellar-type dense thrombosis in the right jugular vein, and bilaterally at 2, 3, 4, and 5, multiple lymph nodes were observed. On Doppler USG, it appeared to be of lamellar type and was 17 × 26 mm in diameter, compatible with hyperechoic and avascular thrombus that was observed in the right jugular vein [Figure 2].

Computerized tomography (CT) of the neck showed multiple lymph nodes at 2A, 2B, 3, 4, and 5A levels, the largest of which was bilaterally on the right, at 2B level. Three-dimensional (3D)-CT angiography revealed total occlusion findings related to acute thrombosis from the sigmoid sinus level to the subclavian vein level [Figure 3]. Neck magnetic resonance (MR) image showed thrombosis in the right jugular vein, distinct edematous and inflammatory changes on jugular region around the right vascular pack, and small bilateral multiple jugular LAPs.

Patient was hospitalized; blood and throat culture samples were taken. Afterward, the patient was started on i.v. ampicillin-sulbactam 4 × 2 g/day and ornidazole 2 × 500 mg/day. After consulting the cardiovascular department, the patient was put on oral anticoagulant treatment with an INR level of 2.

- We excluded possible malignancies with normal thorax and abdominal CT scans. Oncological markers

suggested by the internal diseases department were found to be negative. All viral serology tests including those for *Brucella*, HIV, syphilis, and *Toxoplasma* were found to be negative. After immunological consultation and tests, the following results were obtained: Anti-nuclear anticore, cytoplasmic

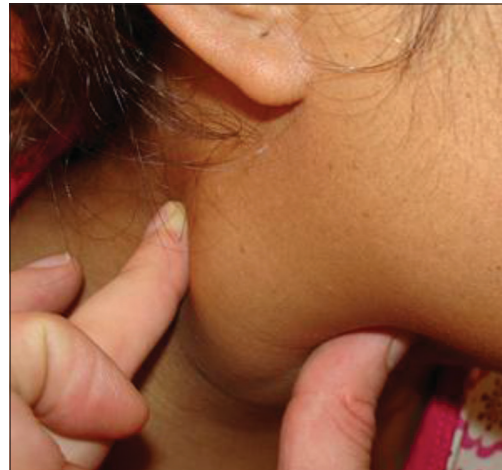

Figure 1: Sensitivity along the internal jugular vein region

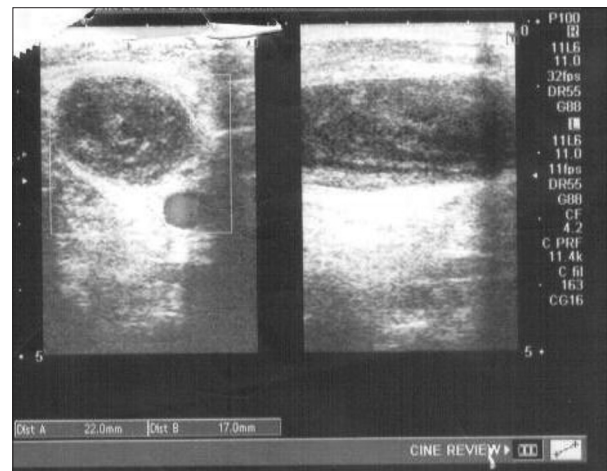


Figure 2: Thrombosis on the right jugular vein

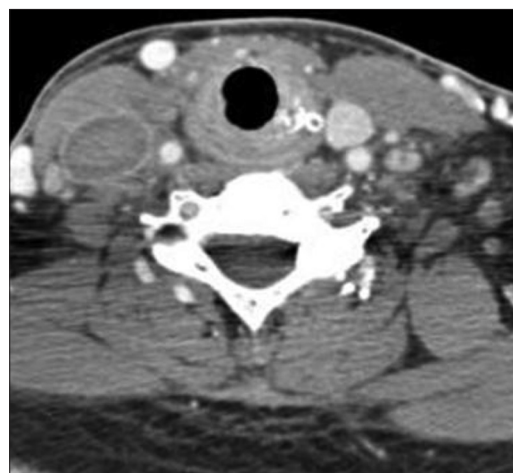


Figure 3: Computerized tomography angio image

antineutrophil cytoplasmic antibodies (c-ANCA), and perinuclear antineutrophil cytoplasmic antibodies (p-ANCA) were found to be negative, and antiphospholipid and anticardiolipin anticores were found to be at a normal level. No reproduction was seen in blood and throat cultures. Fine-needle aspiration biopsy (FNAB) was used for the evaluation of LAP, whose result was normal. Protein C level determined, as recommended by the hematology department, was 69 IU/dL (the normal protein C level in a healthy adult is approximately 85-135 IU/dL) and protein S was 13.1 U/dL, (the normal protein S level in a healthy adult Females is greater than 63 U/dL) which was lower than normal. In genomic DNA tests, methylene tetrahydrofolate reductase (MTHFR) 1298C heterozygote mutation and Factor V G1691A (Leiden) heterozygote mutation were detected.

No additional treatment was recommended by the hematology department. Beginning on the 3rd day of treatment, significant decrease in the neck and throat pain was reported by the patient. On the 15th day of treatment, swelling on the neck almost completely vanished. No difference in jugular vein thrombosis was seen in control Doppler USG, but a significant decrease in LAP was reported. Thereon, the patient was discharged but put on oral anticoagulant treatment for 6 months. There has been no problem in 2 years of follow-up.

DISCUSSION

The most common cause of a painful swelling on the neck is cervical lymphadenitis. The most common reason of a mass on the neck, especially in children, is local or systemic viral or bacterial reactive adenopathy and inflammation with a diagnosis of lymphadenitis. In differential diagnosis, neck cellulitis, deep neck infections, and abscess should be considered. The most commonly seen clinical symptoms of IJVT are fever, leukocytosis, cervical pain, and mass or swelling on the neck.^[4-6] Our patient had all these symptoms as well, and was diagnosed after radiological monitoring with the suspicion of IJVT and put on the correct treatment.

Pathophysiology of venous thrombosis is described by the Virchow's triad of vascular thrombosis, which includes the following: Endothelial damage (intimal), blood flow changes (stasis), and hypercoagulability. Even in the localized diseases, head and neck veins are more sensitive to thrombosis than the extremities and internal organs. The structure and position of the head and neck veins, especially lack of valve in them make them less prone to stasis.^[6,7]

IJVT is generally diagnosed after specific radiological assessments. IJVT diagnosis can be made with CT,

USG, and Doppler USG involving contrast agent. Through CT findings, diagnosis of neck abscess and retraction from lymph node with central necrosis should be made. MR is commonly used in IJVT diagnosis due to its advantages, which are superiority in soft tissue resolution, being a noninvasive technique, and avoidance of radiation exposure. Previously, contrast venography was considered to be the golden standard for venous occlusion, but it is not recommended any more due to its side effects such as vein perforation and displacement of the thrombus.^[8,9] In our case, IJVT diagnosis was made using USG, Doppler USG, and jugular vein CT angio, recommended by the radiology department.

IJVT is a rare and potentially life-threatening disease. In adenocarcinoma (malignancy) and hypercoagulability syndromes, patients should be subjected to a more detailed examination and monitoring due to the possibility of this disease.^[10] In our case, we have performed radiological and oncological examinations for a possible malignancy, but did not encounter any. For the possibility of IJVT developing secondarily to malignancy, FNAB was performed on LAPs and they were reported as normal. After the patient was put on antibiotic treatment, patient's clinical symptoms healed and LAPs in the USG shrank, and this led us away from diagnosis of lymphoma.

In the differential diagnosis, detailed examinations were conducted to find congenital deficiencies or hereditary thrombophilia caused by natural anticoagulant protein (antithrombin III, protein C, and factor XII) deficiency.^[11] Thrombophilia is a term used for defining the clinical presentation that cause the tendency of thrombosis. Development of thrombosis is multifactorial. Various acquired or hereditary factors are known to cause thrombosis with different mechanisms. More than 60% of the tendency is thought to be based on the hereditary components. The most commonly seen factor is active protein C resistance caused by Factor V Leiden mutation. Factor V Leiden heterozygote mutation frequency increased between 3 and 8 times in carriers and venous thrombosis risk was identified. Even though homozygote Factor V Leiden is seen in 0.02% in the society, it increased by 80 times and venous thromboembolic risk was present. Genetic mutations that control MTHFR, a necessary enzyme for homocysteine metabolism, can cause hyperhomocysteinemia. Hyperhomocysteinemia was proven to be a risk factor for venous thromboembolism, cerebrovascular diseases, coronary artery diseases, and peripheral artery diseases.^[12,13] In our patient, protein C and S values were detected to be low. The results of genomic DNA tests conducted on the recommendation of the hematology department showed that both MTHFR 1298C heterozygote mutation and Factor V

G1691A (Leiden) heterozygote mutation were present, and no additional treatment was given with the oral anticoagulant treatment that the patient was already on. We came to the result that a minor trauma caused IJVT in our patient who has a tendency to thrombosis due to genetic mutation.

Lemierre syndrome, or postanginal sepsis, rarely causes IJVT. IJVT caused by an oropharyngeal infection and septic thrombosis bacterium are the criteria for diagnosis. This syndrome is very rare, which could be due to the frequent usage of antibiotics.^[3] In our patient, Lemierre syndrome was not considered as there were no septicemia findings and blood culture results were negative.

IJVT treatment typically involves anticoagulants and antibiotics for distant vein thrombosis. Conventional treatment includes administration of heparin and anticoagulation. If it is thought to be secondary to an infection source, i.v. antibiotic treatment is recommended. Heparin of lower molecular weight can be used as well and Warfarin can be included to avoid thromboembolic situations. Fibrinolytics are rarely indicated, and a surgery such as the partial resection of the vein or thrombectomy is very rare unless it is related to a neoplasm. Every case is unique and should be followed according to the patient's requirements.^[14,15] In our patient, there was no evidence of a thromboembolic disease, and for the 15 days that the patient was in our hospital, i.v. antibiotics and oral anticoagulant treatment were given based on the recommendation of cardiothoracic surgery department. When the case was discharged from the hospital, we recommended oral antibiotics for 7 days and oral anticoagulant treatment at least for 6 months. This is not a standard approach for a sterilized IJVT treatment. Patient has been under our clinical control for 1 year and has no complaints.

CONCLUSIONS

IJVT is very rarely encountered in ENT practice, and early diagnosis and treatment is crucial due to the risk of high morbidity and mortality. If no significant etiologic factor has been identified for the presence of IJVT, as in our case, hereditary thrombophilia has to be kept in mind and investigated.

REFERENCES

1. Chlumský J, Havlín J. Spontaneous jugular vein thrombosis. *Acta Cardiol* 2009;64:689-91.
2. Unsal EE, Karaca C, Ensari S. Spontaneous internal jugular vein thrombosis associated with distant malignancies. *Eur Arch Otorhinolaryngol* 2003;260:39-41.
3. Gormus N, Durgut K, Ozergin U, Odev K, Solak H. Lemierre's syndrome associated with septic pulmonary embolism: A case report. *Ann Vasc Surg* 2004;18:243-5.
4. Cohen JP, Persky MS, Reede DL. Internal jugular vein thrombosis. *Laryngoscope* 1985;95:1478-82.
5. Turkington JR, Paterson A, Sweeney LE, Thornbury GD. Neck masses in children. *Br J Radiol* 2005;78:75-85.
6. Duffey DC, Billings KR, Eichel BS, Sercarz JA. Internal jugular vein thrombosis. *Ann Otol Rhinol Laryngol* 1995;104:899-904.
7. Sengupta S, Kalkonde Y, Khot R, Paithankar M, Salkar R, Salkar H. Idiopathic bilateral external jugular vein thrombosis:-A case report. *Angiology* 2001;52:69-71.
8. Merhar GL, Colley DP, Clark RA, Herwig SR. Computed tomographic demonstration of cervical abscess and jugular vein thrombosis. A complication of intravenous drug abuse in the neck. *Arch Otolaryngol* 1981;107:313-5.
9. Danaci M, Akpolat T, Koyuncu M, Unal R, Belet U. The advantages of MRI and MRA for diagnosing Behçet's disease and internal jugular vein thrombosis. *Comput Med Imaging Graph* 2000;24:121-4.
10. Langlieb AM, Dunton CJ, Carlson JA Jr. Spontaneous internal jugular vein thrombosis associated with leiomyosarcoma of the omentum. *Gynecol Oncol* 1992;47:125-6.
11. Nicolaides AN, Breddin HK, Carpenter P, Coccheri S, Conard J, De Stefano V, *et al.* European Genetics Foundation; Cardiovascular Disease Educational and Research Trust; International Union of Angiology; Mediterranean League on Thromboembolism Thrombophilia and venous thromboembolism. International Consensus Statement. Guidelines according to scientific evidence. *Int Angiol* 2005;24:1-26.
12. Cattaneo M, Chantarangkul V, Taioli E, Santos JH, Tagliabue L. The G20210A mutation of the prothrombin gene in patients with previous first episodes of deep-vein thrombosis: Prevalence and association with Factor V G1691A, methylenetetrahydrofolate reductase C677T and plasma prothrombin levels. *Thromb Res* 1999;93:1-8.
13. Frosst P, Blom HJ, Milos R, Goyette P, Sheppard CA, Matthews RG, *et al.* A candidate genetic risk factor for vascular disease: A common mutation in methylenetetrahydrofolate reductase. *Nat Genet* 1995;10:111-3.
14. Tovi F. Septic thrombophlebitis of the internal jugular vein. *Isr J Med Sci* 1992;28:250-3.
15. De Casso C, Ghosh S, Timms M, Morar P. Superior mediastinal and internal jugular venous thrombosis presenting to the otolaryngologist. *J Laryngol Otol* 2005;119:40-5.

How to cite this article: Gumussoy M, Arslan IB, Cukurova I, Uluyol S. Internal jugular vein thrombosis due to heterozygote methylene tetrahydrofolate reductase (MTHFR) 1298C and Factor V G1691A mutations after a minor trauma. *Natl J Maxillofac Surg* 2014;5:180-3.

Source of Support: Nil. **Conflict of Interest:** None declared.