



## NOTE

Pathology

# Systemic *Staphylococcus pseudintermedius* infection in an arctic fox (*Vulpes lagopus*) with severe multifocal suppurative meningoencephalitis and nephritis

Kei IWATA<sup>1)##</sup>, Kazufumi KASUYA<sup>2)#</sup>, Kou TAKAYAMA<sup>2)</sup>, Yusuke NAKAHARA<sup>3)</sup>, Yoshifumi KOBAYASHI<sup>1)</sup>, Asako KATO<sup>1)</sup>, Hironobu SENBA<sup>1)</sup>, Masae YANAGISAWA<sup>1)</sup> and Tomoyuki SHIBAHARA<sup>4,5)#</sup>

<sup>1)</sup>Pathological and Physicochemical Examination Division, Laboratory Department, Animal Quarantine Service, MAFF, 11-1 Haramachi, Isogo, Yokohama, Kanagawa 235-0008, Japan

<sup>2)</sup>Moji Branch Shinmoji Detention Facility, Animal Quarantine Service, MAFF, 3-1-2 Shinmojikita, Moji, Kitakyushu, Fukuoka 800-0113, Japan

<sup>3)</sup>Animal Inspection Division, Quarantine Department, Animal Quarantine Service, MAFF, 11-1 Haramachi, Isogo, Yokohama, Kanagawa 235-0008, Japan

<sup>4)</sup>Division of Pathology and Pathophysiology, National Institute of Animal Health, National Agricultural and Food Research Organization (NARO), 3-1-5 Kannondai, Tsukuba, Ibaraki 305-0856, Japan

<sup>5)</sup>Department of Veterinary Science, Graduate School of Life and Environmental Sciences, Osaka Prefecture University, 1-58 Rinku-oraikita, Izumisano, Osaka 598-8531, Japan

**ABSTRACT.** A 2-year-female arctic fox (*Vulpes lagopus*) developed anorexia, dehydration, and emaciation during the quarantine period for importation from Norway, and died 17 days later. At necropsy, a fistula was observed on the left gluteal region, and the left eye, left brain, and kidneys were discolored. Histologically, severe diffuse suppurative meningoencephalitis and renal abscesses were detected. Numerous Gram-positive cocci were detected in these lesions. Multidrug-susceptible *Staphylococcus pseudintermedius* were isolated from the lesions. These results suggest that *S. pseudintermedius* can cause severe multifocal suppurative meningoencephalitis and nephritis in foxes. This is the first report of multidrug-susceptible *S. pseudintermedius* meningoencephalitis and nephritis in a fox.

**KEY WORDS:** arctic fox, meningoencephalitis and nephritis, multidrug-susceptible *Staphylococcus pseudintermedius*

*J. Vet. Med. Sci.*

80(8): 1219–1222, 2018

doi: 10.1292/jvms.18-0061

Received: 6 February 2018

Accepted: 1 June 2018

Published online in J-STAGE:

11 June 2018

*Staphylococcus pseudintermedius* is a Gram-positive, facultative anaerobic coccus; its colonies are medium-sized, raised, and unpigmented, and display large incomplete  $\beta$ - and small complete  $\delta$ -hemolysis either alone or in combination (double hemolysis) on sheep or bovine blood agar [3]. In the past, *S. aureus* and *S. hyicus* have been recognized as principal pathogenic staphylococci in veterinary medicine. *S. intermedius* was first described by Hajek in 1976, based on isolates from pigeons, dogs, minks and horses [9]. For over 30 years, *S. intermedius* had been considered a common cause of skin and soft tissue infections in dogs [1, 2, 11].

Recent work has shown that isolates phenotypically identified as *S. intermedius* are indeed differentiated into three distinct species: *S. intermedius*, *S. delphini*, and *S. pseudintermedius*, which are together referred to as the *Staphylococcus intermedius* group (SIG) [4, 6, 14]. The newly described *S. pseudintermedius* species, and not *S. intermedius*, is a common cause of canine cutaneous infections [4, 14] and occasionally causes infection in cats [10] and humans [12]. The natural hosts of *S. delphini* were recognized as Mustelidae such as minks, ferrets, and badgers [7], and those of *S. pseudintermedius* were not only dogs, but also foxes [7]. *S. pseudintermedius* infection has been sporadically reported in other hosts, such as horses, including cases of fatal infection [8]. Moreover, the incidence of methicillin-resistant *S. pseudintermedius* (MRSP) has been increasing in dogs, and is primarily associated with skin, surgical site, and wound infections [13]. However, information regarding *S. pseudintermedius* infection in foxes is still limited [7]. There are no previous reports of fatal *S. pseudintermedius* infection in foxes.

\*Correspondence to: Iwata, K.: kei\_iwata380@maff.go.jp

#These authors contributed equally to this work.

©2018 The Japanese Society of Veterinary Science



This is an open-access article distributed under the terms of the Creative Commons Attribution Non-Commercial No Derivatives (by-nc-nd) License. (CC-BY-NC-ND 4.0: <https://creativecommons.org/licenses/by-nc-nd/4.0/>)

This report describes the clinical, microscopic, and bacteriological finding in an imported arctic fox (*Vulpes lagopus*) with severe multifocal suppurative meningoencephalitis and nephritis.

Four pregnant arctic foxes were imported from Norway by air for exhibition. At the time of arrival, all foxes appeared healthy and no clinical abnormalities were present until the sixteenth day of legal quarantine for importation. However, on the seventeenth day, a 2-year-old female fox displayed anorexia, dehydration, and weakness, and the animal was treated from day 20 of quarantine onward with acetic acid Ringer's solution, 25% glucose solution, fursultiamine, primperan, and ursodeoxycholic acid by intravenous injections. On the twenty-second day, it had an abortion, and on the thirty-fourth day, it was found dead in the cage. No clinical abnormalities were observed in the remaining 3 foxes until the end of the quarantine period of 180 days.

A necropsy was performed, and tissue samples from the liver, kidney, heart, lung, stomach, intestines and left brain (cerebrum, cerebellum, midbrain, pons and medulla oblongata) were fixed in 10% neutral-buffered formalin and embedded in paraffin wax. The whole right brain was not histologically examined because it was refrigerated and used as diagnostics samples for rabies (The result was negative). Tissue sections (approximately 3  $\mu$ m thick) were stained with hematoxylin and eosin (HE) and Gram stained for histological examination.

For immunohistochemical analysis, a rabbit anti-bovine glial fibrillary acidic protein (GFAP) serum (Biomedical Technologies, Inc., Stoughton, MA, U.S.A.) was used at a dilution of 1 in 1,024 with a commercial kit (*N*-Histofine Simple Stain MAX-PO<sup>®</sup>; Nichirei Bioscience, Tokyo, Japan).

Samples from the subcutaneous abscess at the costal region, cerebrum, cerebrospinal fluid, and kidney were used for bacterial isolation.

For genetic tests, genomic DNA was extracted from the bacterial colonies using a DNA extraction kit (InstaGene Matrix; Bio-Rad Laboratories, Hercules, CA, U.S.A.). A ~500-bp region of the 16S ribosomal RNA gene (16S rDNA) region was amplified and sequenced using a MicroSeq 500 16S rDNA PCR/Sequencing Kit (Applied Biosystems Life Technologies, Carlsbad, CA, U.S.A.). Therefore, *S. pseudintermedius* identification was confirmed by *pta* PCR-restriction fragment length polymorphism (RFLP) analysis using MboI [5].

The minimum inhibitory concentration (MIC) of antibiotics against the isolate was determined by the broth micro-dilution technique (Dry plate; Eiken Chemical Co., Ltd., Tokyo, Japan). The tested antibiotics were ampicillin, cefazolin, cefotaxime, kanamycin, tetracycline, gentamycin, ciprofloxacin, chloramphenicol, and trimethoprim-sulfamethoxazole.

After the skin was removed at necropsy, a fistula connected to the subcutaneous abscess of the left costal region was observed on the left gluteal region. Liquid pus colored in whitish-yellow was flowed from the fistula to the surrounding subcutaneous connective tissue and the subcutaneous tissue showed gelatinous appearance with edema throughout the left side of the trunk (Fig. 1a). There was no abnormality in appearance on the surface of the cerebrum hemisphere. After fixation, Paramedian cut surfaces of the left corpus callosum, fornix and cerebellum meninges at central lobule showed greyish in color. The renal papilla was pale brown in color and there was a white spot in the renal cortex at the cut surface of the kidney. The left eye showed corneal opacity. No gross abnormalities were found in the other organs.

Histologically, severe diffuse suppurative meningitis were detected in the pons, cerebral peduncles, and cerebellum meninges at central lobule (Fig. 1b). Suppurative encephalitis with multifocal abscesses were also detected in the white matter of the piriform lobe at cerebrum hemisphere (Fig. 1c), corpus callosum, and fornix. Immunohistochemically, proliferation of GFAP-positive astrocytes was observed in the neural tissue surrounding abscesses (Fig. 1c inset). In the kidney, abscesses in the renal papilla (Fig. 1d), microabscesses in the renal cortex, and mild infiltration of lymphocytes and plasma cells in the interstitium around the glomeruli were observed. Numerous Gram-positive cocci were detected in those lesions and some were detected in the macrophages in the renal lesions (Fig. 1d inserted figure) and the blood vessels of the lung.

Gram-positive cocci were isolated from the subcutaneous abscess, the cerebrum, cerebrospinal fluid, and kidney, and were  $\beta$ -hemolytic, catalase-positive, and oxidase-negative. The sequencing of the amplified 16S rDNA region of the isolate confirmed that it was *Staphylococcus* sp., and it was identified as *S. pseudintermedius* by RFLP analysis using MboI. Furthermore, it demonstrated sensitivity to all tested antibiotics.

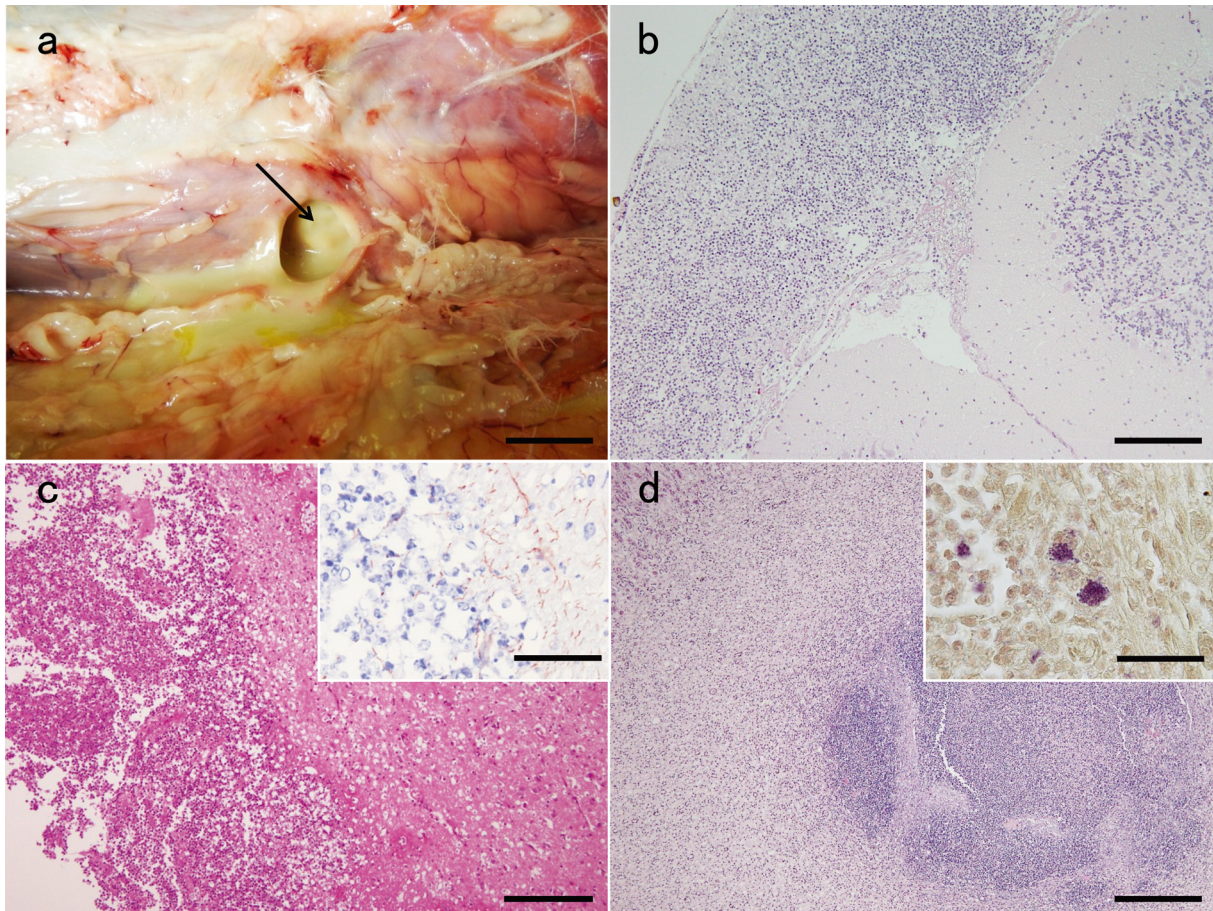
The present case was diagnosed as septicemic infection with severe diffused suppurative meningoencephalitis and nephritis caused by *S. pseudintermedius* because Gram-positive cocci were observed in the suppurative lesions and in the macrophages. Furthermore, the bacteria were isolated from the subcutaneous abscess, cerebrum, cerebrospinal fluid, and kidney, and the isolate was identified as *S. pseudintermedius* by 16S rDNA sequence and RFLP analysis [5].

The present isolate demonstrated sensitivity to all tested antibiotics. On the other hand, the worldwide spread of strains resistant to virtually all antimicrobial agents available in veterinary medicine, namely MRSP, has complicated treatment considerably [13, 16]. It appears that MRSP did not spread out to the arctic foxes imported for exhibition in this case.

Foxes as well as dogs have also been considered as natural hosts of *S. pseudintermedius* [7]. Therefore, opportunistic infections may occur in foxes with weakened immune systems resulting from long-distance transportation, environmental changes and/or pregnancy. An injury leading to the subcutaneous abscess was considered as the probable initial site of *S. pseudintermedius* entry. Subsequently, the bacteria spread throughout the whole body including the kidney and left cerebrum. *S. pseudintermedius* infection has sporadically been reported in other hosts, such as horses and humans [8, 12]. The first case of human infection with *S. pseudintermedius* from a dog bite wound was described over 20 years ago [15]. Systemic *S. pseudintermedius* infection in the organs of foxes is rare and has not been previously reported globally.

In conclusion, this is the first report of multidrug-susceptible *S. pseudintermedius* meningoencephalitis and nephritis in a fox. Further investigation is necessary to clarify the cause of the systemic infection and the virulence factor. In any case, more





**Fig. 1.** a. The subcutaneous tissues of the left costal region. Pus was detected in the fistula (arrow). Bar=2 cm. b. HE staining of the cerebellum showing severe suppurative meningitis. Bar=500  $\mu$ m. c. HE staining of white matter of the piriform lobe at endbrain showing abscess. Bar=200  $\mu$ m. The inserted figure is astrocytes hyperplasia by GFAP Bar=50  $\mu$ m. d. HE staining of the renal papilla showing abscess. Bar=500  $\mu$ m. The inserted figure is Gram staining of marginal region of the renal abscess showing infiltrations of macrophages with numerous Gram-positive cocci. Bar=20  $\mu$ m.

attention will be necessary to develop control measures to prevent opportunistic infectious diseases caused by bacteria such as *S. pseudintermedius* in animals procured for exhibition purposes such as foxes.

**ACKNOWLEDGMENTS.** The authors thank Mr. M. Kobayashi, Ms. M. Shimada, and Ms. K. Tosaki for histopathological assistance.

## REFERENCES

- Allaker, R. P., Lloyd, D. H. and Bailey, R. M. 1992. Population sizes and frequency of staphylococci at mucocutaneous sites on healthy dogs. *Vet. Rec.* **130**: 303–304. [[Medline](#)] [[CrossRef](#)]
- Allaker, R. P., Lloyd, D. H. and Simpson, A. I. 1992. Occurrence of *Staphylococcus intermedius* on the hair and skin of normal dogs. *Res. Vet. Sci.* **52**: 174–176. [[Medline](#)] [[CrossRef](#)]
- Bannoehr, J. and Guardabassi, L. 2012. *Staphylococcus pseudintermedius* in the dog: taxonomy, diagnostics, ecology, epidemiology and pathogenicity. *Vet. Dermatol.* **23**: 253–266, e51–e52. [[Medline](#)] [[CrossRef](#)]
- Bannoehr, J., Ben Zakour, N. L., Waller, A. S., Guardabassi, L., Thoday, K. L., van den Broek, A. H. and Fitzgerald, J. R. 2007. Population genetic structure of the *Staphylococcus intermedius* group: insights into *agr* diversification and the emergence of methicillin-resistant strains. *J. Bacteriol.* **189**: 8685–8692. [[Medline](#)] [[CrossRef](#)]
- Bannoehr, J., Franco, A., Iurescia, M., Battisti, A. and Fitzgerald, J. R. 2009. Molecular diagnostic identification of *Staphylococcus pseudintermedius*. *J. Clin. Microbiol.* **47**: 469–471. [[Medline](#)] [[CrossRef](#)]
- Devriese, L. A., Vancanneyt, M., Baele, M., Vaneechoutte, M., De Graef, E., Snauwaert, C., Cleenwerck, I., Dawyndt, P., Swings, J., Decostere, A. and Haesebrouck, F. 2005. *Staphylococcus pseudintermedius* sp. nov., a coagulase-positive species from animals. *Int. J. Syst. Evol. Microbiol.* **55**: 1569–1573. [[Medline](#)] [[CrossRef](#)]
- Guardabassi, L., Schmidt, K. R., Petersen, T. S., Espinosa-Gongora, C., Moodley, A., Agersø, Y. and Olsen, J. E. 2012. Mustelidae are natural hosts of *Staphylococcus delphini* group A. *Vet. Microbiol.* **159**: 351–353. [[Medline](#)] [[CrossRef](#)]

8. Haenni, M., Targant, H., Forest, K., Sévin, C., Tapprest, J., Laugier, C. and Madec, J. Y. 2010. Retrospective study of necropsy-associated coagulase-positive staphylococci in horses. *J. Vet. Diagn. Invest.* **22**: 953–956. [[Medline](#)] [[CrossRef](#)]
9. Hajek, V. 1976. *Staphylococcus pseudintermedius*, a new species isolated from animals. *Int. J. Syst. Bacteriol.* **26**: 401–408. [[CrossRef](#)]
10. Ludwig, C., de Jong, A., Moyaert, H., El Garch, F., Janes, R., Klein, U., Morrissey, I., Thiry, J. and Youala, M. 2016. Antimicrobial susceptibility monitoring of dermatological bacterial pathogens isolated from diseased dogs and cats across Europe (ComPath results). *J. Appl. Microbiol.* **121**: 1254–1267. [[Medline](#)] [[CrossRef](#)]
11. Medleau, L., Long, R. E., Brown, J. and Miller, W. H. 1986. Frequency and antimicrobial susceptibility of *Staphylococcus* species isolated from canine pyodermas. *Am. J. Vet. Res.* **47**: 229–231. [[Medline](#)]
12. Robb, A. R., Wright, E. D., Foster, A. M. E., Walker, R. and Malone, C. 2017. Skin infection caused by a novel strain of *Staphylococcus pseudintermedius* in a Siberian husky dog owner. *JMM Case Rep.* **4**: r005087. [[Medline](#)]
13. Saab, M. E., Muckle, C. A., Stryhn, H. and McClure, J. T. 2018. Comparison of culture methodology for the detection of methicillin-resistant *Staphylococcus pseudintermedius* in clinical specimens collected from dogs. *J. Vet. Diagn. Invest.* **30**: 93–98. [[Medline](#)] [[CrossRef](#)]
14. Sasaki, T., Kikuchi, K., Tanaka, Y., Takahashi, N., Kamata, S. and Hiramatsu, K. 2007. Reclassification of phenotypically identified *Staphylococcus intermedius* strains. *J. Clin. Microbiol.* **45**: 2770–2778. [[Medline](#)] [[CrossRef](#)]
15. Talan, D. A., Goldstein, E. J., Staatz, D. and Overturf, G. D. 1989. *Staphylococcus intermedius*: clinical presentation of a new human dog bite pathogen. *Ann. Emerg. Med.* **18**: 410–413. [[Medline](#)] [[CrossRef](#)]
16. Weese, J. S. and van Duijkeren, E. 2010. Methicillin-resistant *Staphylococcus aureus* and *Staphylococcus pseudintermedius* in veterinary medicine. *Vet. Microbiol.* **140**: 418–429. [[Medline](#)] [[CrossRef](#)]