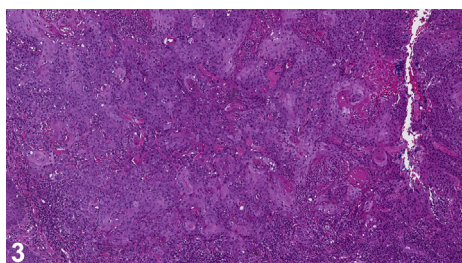
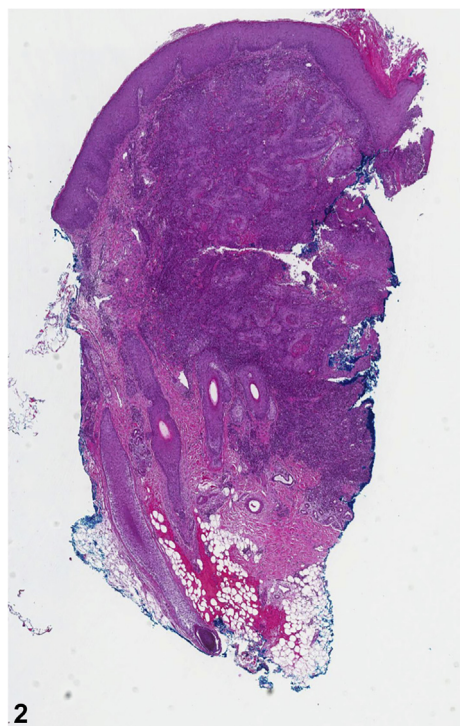
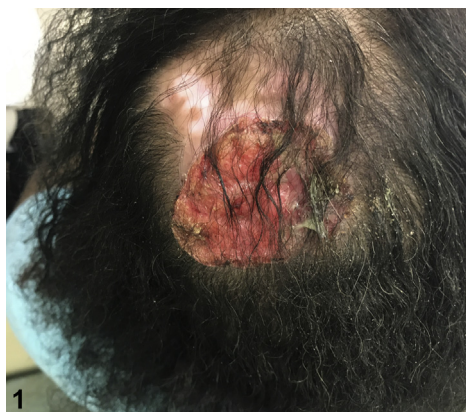

## Rapidly growing tumor on the scalp



Aderonke Obayomi, MD, MPH, Jalal Maghfour, MS, and Andrea Murina, MD  
*New Orleans, Louisiana*

**Key words:** autoimmune disease; lupus; skin of color; squamous cell carcinoma.



From Tulane University School of Medicine.

Funding sources: None.

Conflicts of interest: Dr Murina is a Speaker for Abbvie, Celgene, Janssen, and Novartis. The rest of the authors have no conflicts to disclose.

Correspondence to: Andrea Murina, MD, 1430 Tulane Avenue, New Orleans, LA 70112. E-mail: [amurina@tulane.edu](mailto:amurina@tulane.edu).

JAAD Case Reports 2019;5:991-3.

2352-5126

© 2019 by the American Academy of Dermatology, Inc. Published by Elsevier, Inc. This is an open access article under the CC BY-NC-ND license (<http://creativecommons.org/licenses/by-nc-nd/4.0/>).

<https://doi.org/10.1016/j.jidcr.2019.09.007>

A 52-year-old African-American woman with a 20-year history of systemic lupus erythematosus presented with a tender growth on her scalp (Fig 1). The lesion was present for several months and grew quickly in size. She has been on hydroxychloroquine, 200 mg twice daily for 10 years, without adverse events. On examination, a 4-cm tender ulcerated plaque with a raised border on the edge of a depigmented plaque along with additional depigmented plaques with alopecia in the frontal scalp were seen. Laboratory findings were remarkable for mild leukopenia and normocytic anemia. A biopsy specimen is shown in Figs 2 and 3.

**Question 1: What is your diagnosis?**

- A. Cutaneous sarcoidosis
- B. Lupus erythematosus panniculitis
- C. Poorly differentiated squamous cell carcinoma (SCC)
- D. Proliferating pilar tumor
- E. Ulcerated lichen planopilaris

**Answers:**

**A.** Cutaneous sarcoidosis — Incorrect. Although sarcoidosis can present with papules and plaques on the scalp, it is a diagnosis of exclusion. The histopathology of cutaneous sarcoidosis consists of aggregates of histiocytes with giant cell formation and sparse lymphocytic inflammation.

**B.** Lupus erythematosus panniculitis — Incorrect. Lupus erythematosus panniculitis is a variant of lupus erythematosus that primarily affects the reticular dermis and fat. It presents as tender nodules and plaques that can arise in crops, primarily on the proximal extremities and trunk.

**C.** Poorly differentiated SCC — Correct. This is a case of squamous cell carcinoma occurring within an area of discoid lupus erythematosus (DLE). Biopsy of the scalp lesion found a poorly differentiated squamous cell carcinoma (SCC). DLE is the most common type of cutaneous lupus and is characterized by alopecia, depigmentation, and scars on sun-exposed skin. High-risk SCC is a rare and life-threatening complication that can arise in DLE lesions. SCC has been reported in 2.3% to 3.3% of DLE patients, often with higher rates of recurrence, early metastasis, and mortality in contrast to non-DLE patients.<sup>1</sup> In skin-of-color patients, the most important risk factor for SCC development is chronic scarring and inflammation. Of all SCC cases reported in black patients, 20% to 40% arise from chronic scarring processes.<sup>2</sup>

**D.** Proliferating pilar tumor — Incorrect. Rare malignant variants of pilar tumors have been reported, but most commonly, they are benign and cystic in nature. Histologically, pilar tumors are characterized by trichilemmal keratinization.

**E.** Ulcerated lichen planopilaris — Incorrect. Lichen planopilaris is a follicular variant of lichen planus that leads to cicatricial alopecia of the scalp. Ulcerated lichen planopilaris is a rare and severe subtype of lichen planus. Histopathologic features include perifollicular fibrosis and lichenoid lymphocytic inflammation at the level of the infundibulum.

**Question 2: Which wavelength of ultraviolet (UV) light induces keratinocyte carcinogenesis by the formation of pyrimidine dimers?**

- A. 10 to 280 nm
- B. 280 to 315 nm
- C. 315 to 400 nm
- D. 750 to 1000 nm
- E.  $10^6$  to  $10^9$  nm

**Answers:**

**A.** 100 to 280 nm — Incorrect. This range represents UVC radiation, which is strongly mutagenic but is almost completely blocked by the stratospheric ozone layer.

**B.** 280 to 315 nm — Correct. This range represents UVB radiation. UV radiation is a well-known exacerbating factor for cutaneous lupus erythematosus. UV radiation promotes development of cutaneous lupus by augmenting lymphocytic recruitment and antibody-mediated cytotoxicity. UVB specifically causes keratinocyte apoptosis by damaging DNA via strand breaks and pyrimidine dimer formation. Additionally, UVB increases recruitment of lymphocytic cells by increasing inflammatory cytokine and chemokine release of interleukin-1, tumor necrosis factor- $\alpha$ , intracellular adhesion molecule-1, and histocompatibility class II molecules.<sup>3</sup>

**C.** 315 to 400 nm — Incorrect. This range represents UVA radiation. UVA radiation achieves penetration into the deeper dermis and contributes to keratinocyte apoptosis via mitochondrial oxidative damage.<sup>3</sup>

**D.** 750 to 1000 nm — Incorrect. This range represents infrared radiation, which is converted to heat. There is no evidence for its role in keratinocyte carcinogenesis.

**E.**  $10^6$  to  $10^9$  nm — Incorrect. This range represents microwave radiation, which does not contribute significantly to keratinocyte carcinogenesis.

**Question 3: SCC in discoid lupus is strongly associated with the following:**

- A.** Cigarette smoking
- B.** Increased risk of metastasis
- C.** Location on the ear
- D.** Use of hydroxychloroquine
- E.** UVA-1 phototherapy

**Answers:**

**A.** Cigarette smoking — Incorrect. Although tobacco use may increase risk of SCC transformation in the lip area, the relationship of SCC development in cigarette users with DLE has not been established.<sup>4</sup>

**B.** Increased risk of metastasis — Correct. Patients with discoid lupus are at higher risk to have an aggressive form of SCC with greater propensity to metastasize. The unique immune milieu of DLE can contribute to promotion of SCC. A similar mechanism has also been described in other invasive forms of SCC including chronic burn lesions and Marjolin ulcers.

**C.** Location on the ear — Incorrect. SCCs arising from DLE are most common in sun-exposed areas.

In one study, the most common sites of DLE-related SCC were the lips, cheeks, and back of hands.<sup>5</sup>

**D.** Use of hydroxychloroquine — Incorrect. Although immunosuppressive agents may play a role in SCC in the general population, the use of hydroxychloroquine has not been associated with increased risk of SCC in DLE patients.

**E.** UVA-1 phototherapy — Incorrect. UVA-1 phototherapy is indicated for morphea and systemic sclerosis but is not an established therapy for cutaneous lupus. The role of UVA-1 in photocarcinogenesis in humans has not been established.

**REFERENCES**

1. Alsanafi S, Werth VP. Squamous cell carcinomas arising in discoid lupus erythematosus scars: unusual occurrence in an African-American and in a sun-protected area. *J Clin Rheumatol*. 2011;17:35-36.
2. Gloster HM, Neal K. Skin cancer in skin of color. *J Am Acad Dermatol*. 2006;55:741-760.
3. Kim A, Chong BF. Photosensitivity in cutaneous lupus erythematosus. *Photodermatol Photoimmunol Photomed*. 2013;29(1):4-11.
4. Song F, Qureshi AA, Gao X, Li T, Han J. Smoking and risk of skin cancer: a prospective analysis and a meta-analysis. *Int J Epidemiol*. 2012;41(6):1694-1705.
5. Tao J, Zhang X, Guo N, et al. Squamous cell carcinoma complicating discoid lupus erythematosus in Chinese patients: review of the literature, 1964-2010. *J Am Acad Dermatol*. 2012;66(4):695-696.