

Ovarian Torsion in a Teenage Girl with Genitourinary Anomaly

M. Reza Taheri, M.D., Theodore J. Dubinsky, M.D., and Orpheus Kolokythas, M.D.

We present the clinical presentation, sonography, CT, and MR imaging as well as correlative intra-operative and gross pathological findings of ovarian torsion in a 14-year-old girl. Our findings are discussed in the context of prior imaging studies performed for the evaluation of ovarian torsion. Ovarian torsion is not an uncommon cause of acute abdominal pain in children and teenage girls. Diagnosis of this entity can be difficult based on clinical presentation or on imaging appearance alone.

Case Report

A 14-year-old girl suddenly developed right lower quadrant pain associated with nausea while showering. After an initial evaluation at an outside hospital, she was transferred to our institution. Patient denied fevers, chills, dysuria, urinary frequency, diarrhea, and constipation. She was G0 with no sexual activity. She has had irregular cycles lasting 2-3 months since she was 11, the last of which was too long ago for her to remember. Her past medical history was unremarkable. She had no allergies and denied tobacco, alcohol, illicit drug and medication use. Physical exam was remark-

able for abdominal pain in the lower quadrants and in the midline infraumbilically. External genitalia and the vagina appeared normal. No evidence of a septum or imperforate hymen was seen. On bimanual exam, the external os was open, and no cervical motion tenderness was appreciated. The uterus was felt to be enlarged, and a large, midline mass that was soft to palpation, smooth and somewhat fixed in the pelvis was noted. She had a negative urinalysis. Serum beta HCG was negative. White blood cell count, platelets, creatinine and hematocrit were 17,900 / μ l, 299,000/ μ l, 0.8 mg/dl and 43 %, respectively.

Transabdominal ultrasound was performed at an outside institution and was interpreted as consistent with hematometra with a 10 cm adnexal mass. Based on the available report, it is unclear as to which structure was presumed to represent the uterus or hematometra. After an attempt to drain the hematometra was unsuccessful, a computed tomography (CT) was performed to further evaluate the pelvis and the abdomen. Shortly thereafter, the patient was transferred to our hospital and the US and CT images were provided to the radiology department. The interpretation of the US at our institution is offered in Figure 1. CT images (Figure 2)

Citation: Taheri MR, Dubinsky TJ, Kolokythas O. Ovarian torsion in a teenage girl with genitourinary anomaly. *Radiology Case Reports*. [Online] 2008;3:155.

Copyright: © 2008 The Authors. This is an open-access article distributed under the terms of the Creative Commons Attribution-NonCommercial-NoDerivs 2.5 License, which permits reproduction and distribution, provided the original work is properly cited. Commercial use and derivative works are not permitted.

Abbreviations: CT, computed tomography; MRI, magnetic resonance imaging

M. Reza Taheri, M.D. (Email: rtaheri@u.washington.edu), Theodore J. Dubinsky, M.D., and Orpheus Kolokythas, M.D., are in the Department of Radiology, University of Washington, Seattle, WA, USA.

Published: June 13, 2008

DOI: 10.2484/rcr.v3i2.155

Ovarian Torsion in a Teenage Girl with Genitourinary Anomaly

demonstrated a right adnexal non-enhancing mass as well as a small amount of hemoperitoneum. In addition, the tubular shaped uterus in a patient with an absent left kidney was presumed to represent a unicornuate uterus. The high position of the left ovary in the left paracolic gutter was noted.

To better characterize the nature of the ovarian mass and its relation to the uterus, MRI was performed. MRI confirmed the presence of the unicornuate uterus and a large non contrast-enhancing mass, likely representing a torsed right ovary (Fig. 3). The left ovary located high

in the left paracolic demonstrated an elongated mesovarium and Fallopian tube.

The patient was taken immediately to the operating room where the torsion on the right side was evident. After the ovary was untwisted, it appeared clearly edematous throughout with no obviously viable tissue (Figure 4A). The fallopian tube was also found to be grossly edematous and apparently nonviable down to approximately 1 to 2 cm in length from the cornua. A complete right oophorectomy was performed since the ovary could not be salvaged. The unicornuate uterus ap-

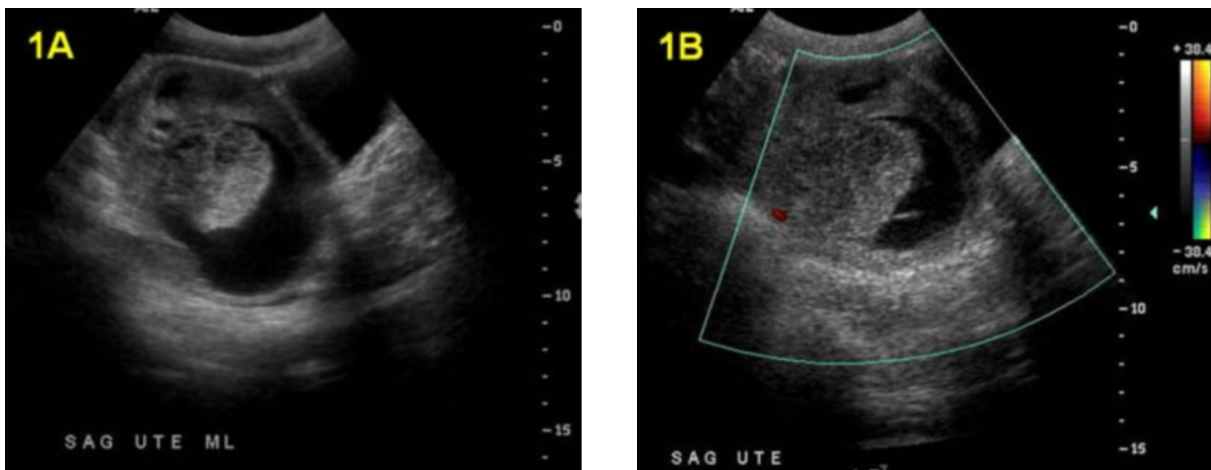


Figure 1A-B. 14-year-old girl with ovarian torsion. Pelvic Sonogram. (A) and (B) Sagittal midline images of the pelvis show a pear-shaped soft tissue structure superior and posterior to the urinary bladder thought to be the uterus with a posterior complex cystic mass with no internal flow by color Doppler exam.

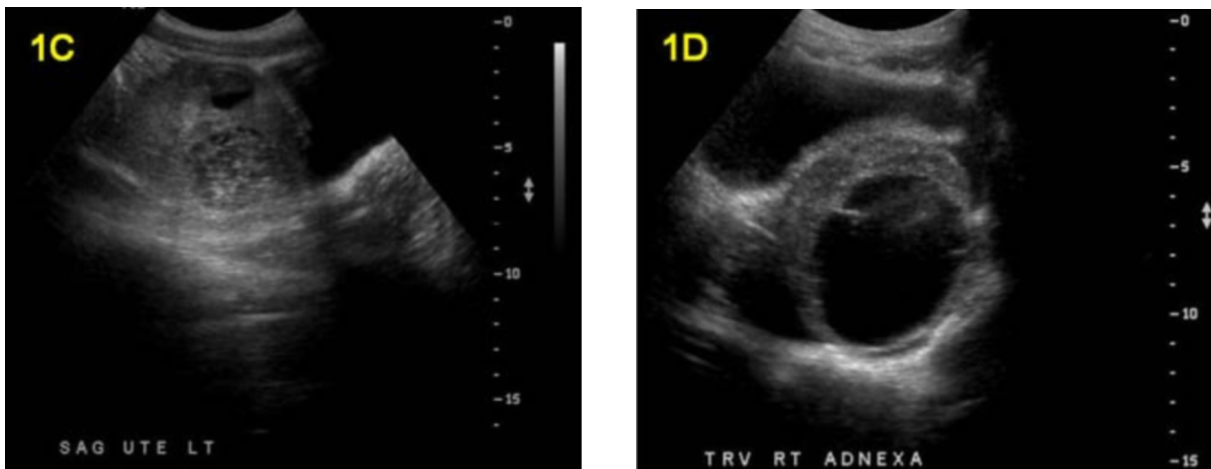


Figure 1C-D. Pelvic Sonogram. (C) Parasagittal and (D) transverse images of the pelvis show the complex heterogeneous round soft tissue mass with septation.

Ovarian Torsion in a Teenage Girl with Genitourinary Anomaly

peared grossly normal. The left ovary was identified high on the pelvic brim extending up along the posterior peritoneal wall in line with the infundibulo-pelvic ligament on that side. Gross pathological appearance (Figure 4B) and histological findings supported the presence of diffuse hemorrhage in necrotic tissue and the absence of a viable mass in the right ovary and fallopian tube. The cross sectional diameter of the ovary, which lacked the hemorrhagic content of the large cystic structures, was approximately 1x8 cm. The patient remains free of neoplasm five months after oophorectomy.

Discussion

Ovarian torsion is the cause of about 3% of acute abdominal pain in females (1). The diagnosis is often difficult to make due to vague symptoms and the high position of reproductive organs in prepubertal children. The most common symptom is unilateral abdominal pain with right sided pain slightly more prevalent than left sided pain. Nausea/vomiting, fever, and a palpable mass are present in 70-80%, 20%, and 20-36% of cases, respectively (2)(3). Although leukocytosis is usually

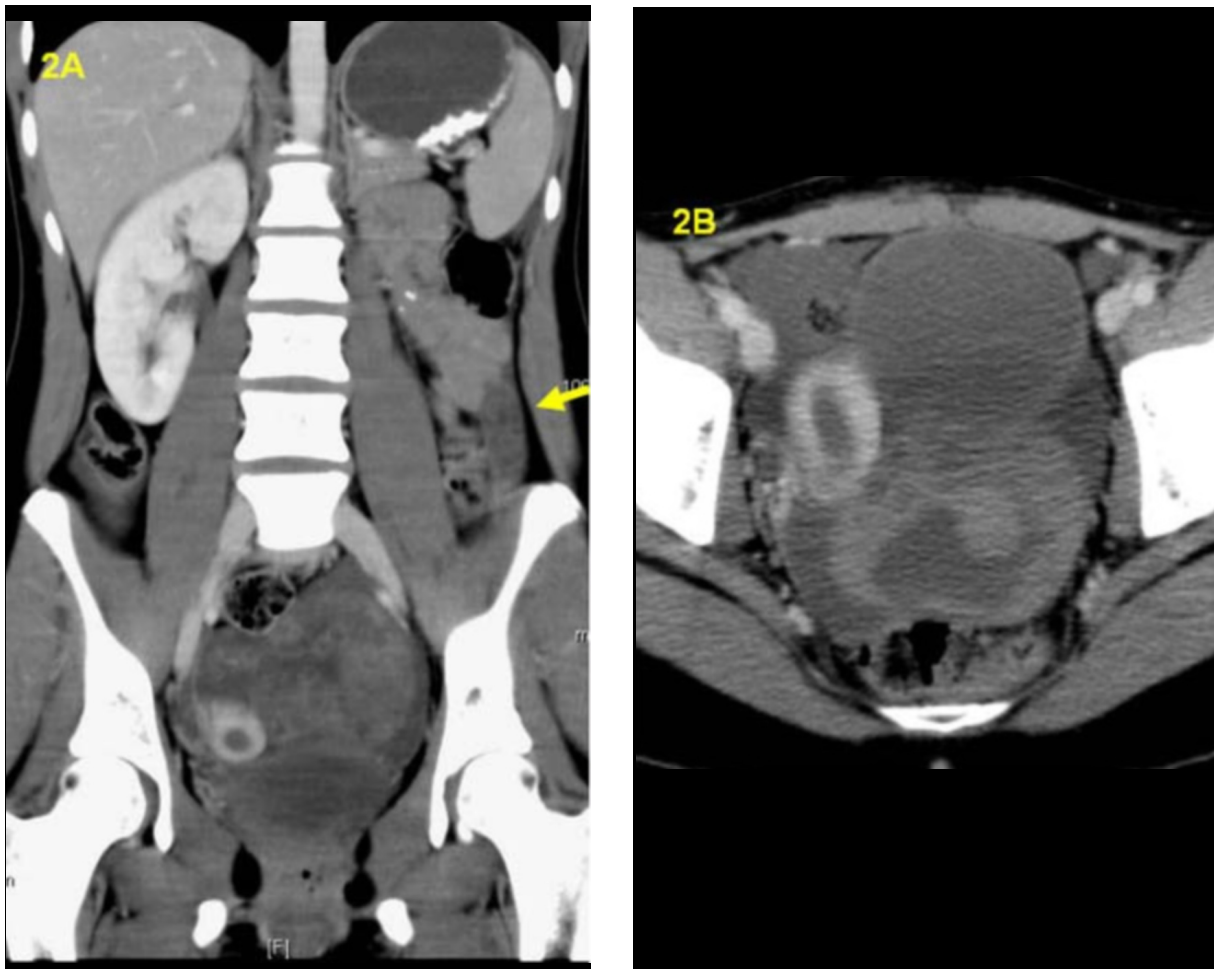


Figure 2A-B. (A) Coronal and (B) axial contrast enhanced CT shows agenesis of the left kidney. The left ovary is laterally displaced to the paracolic gutter (arrow). There is a large non enhancing posterior midline pelvic mass, which has caused right lateral displacement of a tubular shaped uterus. The low density material in the endometrial cavity may represent secretory phase endometrium or small amount of intrauterine fluid. The appendix had a normal appearance (not shown).

Ovarian Torsion in a Teenage Girl with Genitourinary Anomaly

present, the level of leukocytosis does not correlate well with the degree of ischemia (4).

US remains an ideal screening test in children and teenage girls with vague abdominal pain for its widespread and usually immediate availability, lack of ionizing radiation, low cost and high spatial resolution. In addition, US provides dynamic evaluation of the tissue and blood flow. One of the first tasks of the sonographer in such cases is to identify the uterus. Once this organ is well delineated, a sonographic finding of an enlarged ovary and/or distinct solid, cystic, or complex adnexal mass associated with free intra-abdominal fluid in a female with acute lateralized abdominal pain is highly suspicious for an ovarian torsion. As exemplified in this case, reaching a final diagnosis can at times be difficult, particularly in those whose anatomy cannot be clearly defined with US. Given that the US was done at an outside institution and only a brief report was made available, it is difficult to know how the sonographer reached his or her erroneous conclusion of hematometra. Perhaps, the sonographer was unable to define a clear plane between the uterus and the adnexal mass and may have presumed that the mass represented blood in the rudimentary horn of the uterus. In the absence of knowing the patient's b-HCG, these image findings can be

consistent with the clinical presentation of hematometra which also includes lower abdominal pain, nausea, and detection of large uterus by physical examination. Even though the positive predictive value of absent venous flow for ovarian torsion has been reported as high as 94% (5), absence of flow in this case would not help differentiate between ovarian torsion versus hematometra in the rudimentary horn of the uterus. It is unclear as to why an attempt was made to drain the presumed hematometra with a negative b-HCG. Nonetheless, once an attempt to drain the hematometra was unsuccessful, a CT was ordered to further define the anatomy of the pelvis.

CT offers the advantage of a good resolution and a large field of view, which allows for evaluation of other potential causes of a patient's symptoms. Advantages of MR include absence of ionizing radiation to relatively radiosensitive organs of young female patients, enhanced contrast resolution, and the ability to better characterize tissue composition. The enhancement pattern of the ovary can provide clues to the underlying etiology, which can aid in the appropriate management of the patient. Multiple associated signs have been demonstrated in both CT and MR imaging (6,7). Hemorrhage in the adnexal mass and hemoperitoneum, as were seen in this

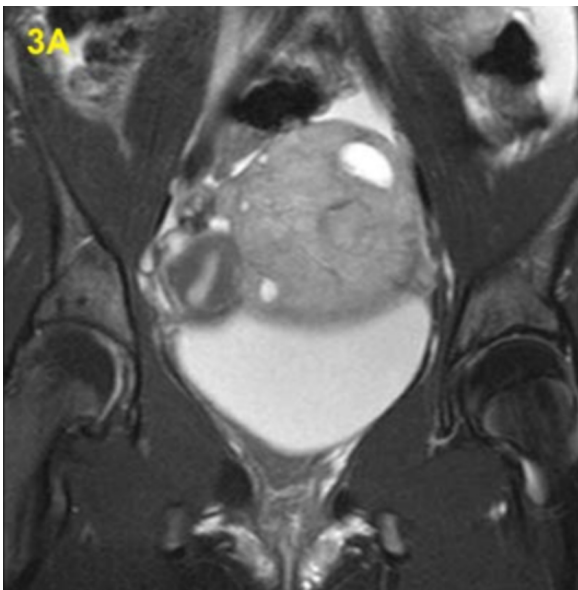


Figure 3A. Coronal STIR MRI shows a heterogeneous mass with cystic components, which appears distinct from the secretory phase uterus.

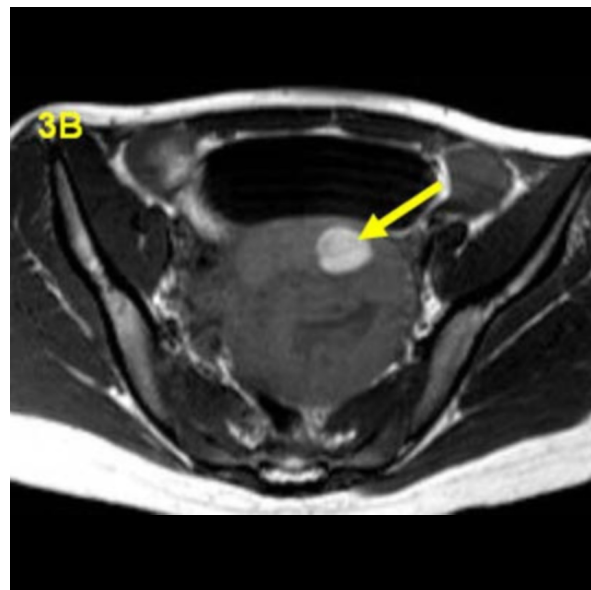


Figure 3B. Axial T1 MRI shows a large hypointense mass with a focal round hyperintense component (arrow).

Ovarian Torsion in a Teenage Girl with Genitourinary Anomaly

case, were reported to be present in 18% and 8% of the cases, respectively. In one study, the presence of multiple follicles in the periphery of a unilaterally enlarged ovary was proposed to be pathognomonic of twisted ovaries. Tubal thickening and twisted vascular pedicle, which were not seen in this case, were the most specific sign,

present in 84% of cases. Application of the observation that a conventional uterus deviates to the affected side in about one third of the patients is difficult, given that the baseline position of the unicornuate uterus was unclear. In this case, both CT and MR defined the unicornuate uterus and a distinct non enhancing adnexal mass,

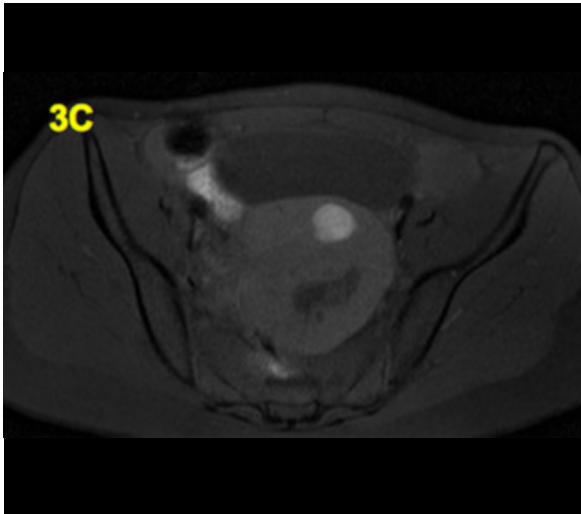


Figure 3C. Axial T1 fat-saturated MRI shows that the signal in the T1 hyperintense component of the mass does not suppress.

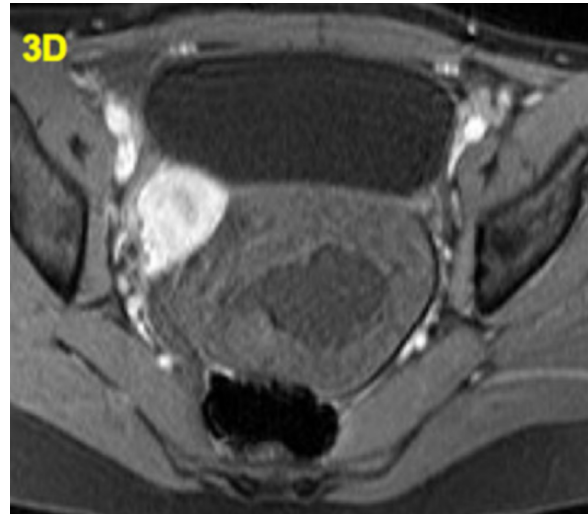


Figure 3D. Axial T1 fat-saturated post-contrast MRI shows no enhancement of the mass in the posterior midline pelvis. There is intense normal enhancement of the uterus to the right of the mass.

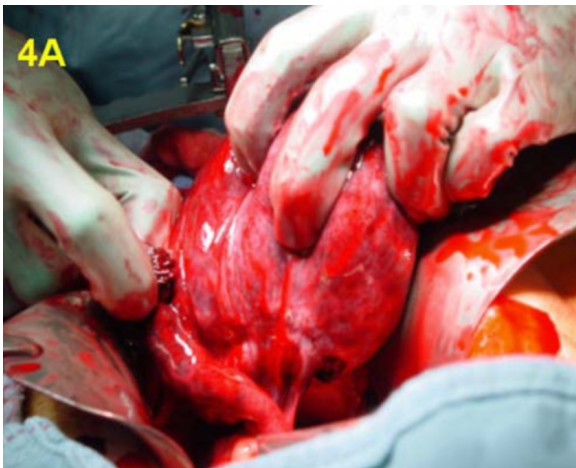

Figure 4A. Intraoperative image shows a large soft, dark red, smooth and glistening right ovary covered in hemorrhage that was clearly torsed when the abdomen was opened.

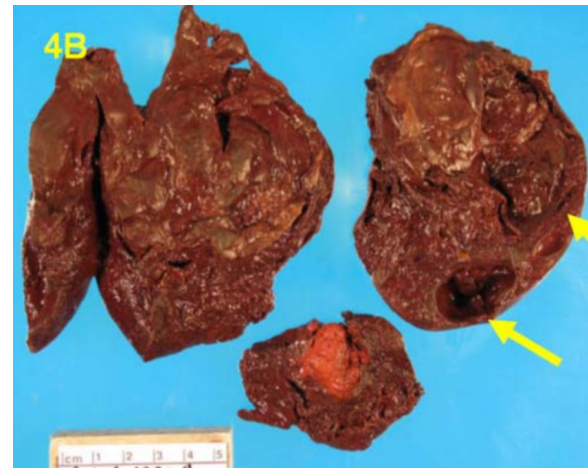


Figure 4B. Bisection of the excised right ovary reveals a boggy deep red stroma with two cystic spaces (arrows).

Ovarian Torsion in a Teenage Girl with Genitourinary Anomaly

which was pathologically proven to be diffuse hemorrhage in necrotic tissue.

In 50-81% of cases involving children and teenage girls, torsion is associated with ipsilateral ovarian tumor or cysts (7). Benign teratoma makes up for 75-95% of these tumors. Normal ovaries can account for up to 25% of torsed ovaries (8). Malignant lesions are uncommon associated findings in this age group.

The most important predisposing factor for ovarian torsion in this case was the enlarged size of the right ovary. Variations of embryogenesis of the fallopian tubes may increase the chances of a future left sided ovarian torsion but are unlikely to have played a key role in the right ovarian torsion. Fallopian tube anomalies are sequelae of abnormally developed müllerian ducts which are typically ipsilateral to the renal anomaly (the left side in this case) (11). Tortuous and elongated fallopian tubes or mesosalpingeal vessels and congenitally elongated supportive ligaments are predisposing factors for ovarian torsion (12). Based on the high position of the left ovary, it is possible that this ovary is at an increased risk of torsion. An unusually absent or elongated right fallopian tube is not a clinical consideration, given that based on both the intraoperative and pathological report, the right fallopian tube was only remarkable for its hemorrhagic and necrotic appearance.

Treatment of ovarian torsion is controversial and includes aspiration as well as partial or complete oophorectomy with or without tubal resection. Factors such as lapsed time, underlying etiology, and other associated findings can impact the surgical management of the patient. In children and in fertile adults, the desire to preserve ovarian function especially reproductive capabilities add an extra level of complexity (9). Contralateral and/or unilateral ovariopexy are also potential options to consider (10). Hemorrhage into an ovarian cyst or into the peritoneum as a differential diagnosis of a b-HCG negative painful pelvic mass may be addressed conservatively or depending on the severity of the bleed, may require intervention such as embolization or surgery.

References

1. Hibbard L, Adnexal torsion. *Am Obstet Gynecol* 1985; 152:456-61 [PubMed]
2. Kokoska ER, Keller MD, Weber TR. Acute ovarian torsion in children. *Am J Surg* 2000; 180: 462-465. [PubMed]
3. Aziz D, Davis V, Allen L, Langer JC. Ovarian torsion in children: is oophorectomy necessary? *J Pediatr Surg* 2004; 39:750-753. [PubMed]
4. Oelsner G, Shashar D. Adnexal Torsion. *Clin Obstet Gynecol* 2006; 49(3):459-463. [PubMed]
5. Ben-Ami M, Perlitz Y, Haddad S. The effectiveness of spectral and color Doppler in predicting ovarian torsion: a prospective study. *Eur J Obstet Gynecol REprod Biol* 2002 104:64-66. [PubMed]
6. Gittleman AM, Price AP, Goffner L, Katz DS. Ovarian torsion; CT findings in a child. *J Pediatr Surg* 2004; 39:1270-1272. [PubMed]
7. Rha SE, Byun JY, Jung SE, et al. CT and MR imaging features of adnexal torsion. *Radiographics* 2002; 22:283-294. [PubMed]
8. Davis AJ, Feins NR. Subsequent asynchronus torsion of normal adnexa in children. *J Pediatr Surg* 2000; 180: 462-465. [PubMed]
9. Breech LL, Adams Hillard PJ. Adnexal torsion in pediatric and adolescent girls. *Curr Opin Obstet Gynecol* 2005; 17:483-489. [PubMed]
10. Canning DA. Ovarian Torsion: To Pex or Not to Pex? Case Report and Review of the Literature. *The Journal of Urology* 2005, Volume 173, Issue 4, Pages 1364-1364. [PubMed]
11. Brody, JM, Koelliker, SL, Frishman, GN. Unicornuate Uterus: Imaging Appearance, Associated Anomalies, and Clinical Implications 1998; 171:1341-1347. [PubMed]
12. Mordehai J., Mares AJ, Barki Y, Finaly R, and Meizner I. Torsion of uterine adnexa in neonates and children: A report of 20 cases 1991 Oct;26(10):1195-9. [PubMed]