



Re-irradiation for oligoprogression under Nivolumab in recurrent head and neck squamous cell carcinoma: A case report



Pierluigi Bonomo^{a,*}, Sara Lucidi^a, Isacco Desideri^a, Vieri Scotti^a, Marta Casati^b, Annarita Palomba^c, Cinzia Ciabatti^a, Pietro Garlatti^a, Daniela Massi^c, Oreste Gallo^d, Lorenzo Livi^a

^a Radiation Oncology, Azienda Ospedaliero-Universitaria Careggi, University of Florence, Florence, Italy

^b Medical Physics, Azienda Ospedaliero-Universitaria Careggi, University of Florence, Florence, Italy

^c Section of Pathological Anatomy, Department of Health Sciences, Azienda Ospedaliero-Universitaria Careggi, University of Florence, Florence, Italy

^d Department of Otolaryngology – Head and Neck Surgery, Azienda Ospedaliero-Universitaria Careggi, University of Florence, Florence, Italy

ARTICLE INFO

Article history:

Received 27 December 2019

Revised 14 April 2020

Accepted 14 April 2020

Available online 17 April 2020

Keywords:

Head and neck cancer

Immunotherapy

Re-irradiation

Oligoprogression

Intensity modulated radiotherapy

Nivolumab

ABSTRACT

Immune checkpoint inhibitors (ICIs) represent a recently introduced class of agents active in head and neck squamous cell carcinoma (HNSCC). For a subgroup of patients with recurrent or metastatic disease, long-term benefit can be achieved: maintaining a sustained response to immunotherapy is therefore a critical factor for its efficacy at an individual level. In analogy to targeted agents, a limited pattern of progression, or “oligoprogression”, can occur. For locally recurrent HNSCC, the potential biologic interplay between the efficacy of ICIs and the design of radiation fields chosen for primary treatment is currently unknown. Here, we report on a patient who presented two subsequent oligoprogessions successfully treated with re-irradiation without interrupting Nivolumab. Both oligoprogressive lesions developed in previously unirradiated areas. We hypothesize the existence of a synergistic effect with optimal spatial cooperation between ICIs and re-irradiation for oligoprogressive disease under immunotherapy.

© 2020 Published by Elsevier B.V. on behalf of European Society for Radiotherapy and Oncology. This is an open access article under the CC BY-NC-ND license (<http://creativecommons.org/licenses/by-nc-nd/4.0/>).

1. Introduction

Over the last 5 years, the therapeutic armamentarium of head and neck squamous cell carcinoma (HNSCC) has been enriched by the advent of immunotherapy. Currently, two drugs are FDA-approved in the recurrent/metastatic (R/M) setting: immune checkpoint inhibitors (ICIs) Nivolumab and Pembrolizumab are both indicated for use in platinum-refractory HNSCC, whereas Pembrolizumab can also be administered in first-line treatment as single agent for patients with Combined Positive Score (CPS) > 20 or in combination with platinum-5 FU chemotherapy for patients with CPS > 1, based on the results of Checkmate 141 [1], Keynote 040 [2] and 048 [3] trials, respectively. Spurred by biologic rationale [4] and pre-clinical evidence [5], several clinical trials were launched to investigate the potential synergistic effect of immunotherapy and radiotherapy (RT) in locally advanced and R/M HNSCC, however in clinical practice their combination is at present investigational. Amongst many yet unresolved questions regarding suitable RT total dose and fractionation, optimal timing

of delivery and sequence of treatment in respect to immunotherapy, two main aspects are worth considering in locally recurrent HNSCC. First, is there a potential interplay between the efficacy of ICIs, or the lack thereof, and the extent of radiation fields designed for primary RT? Second, can re-irradiation be safely performed once the patient has already been exposed to immunotherapy or concurrently with it? Here, we report on two subsequent marginal oligo-progessions developed under Nivolumab which were re-irradiated without interrupting the ICI.

2. Case

A 54-year old woman with previous tobacco exposure (10 pk/years) presented in February 2014 with a painless lump in the neck of 3 cm in right level IB. After proper workup, she was diagnosed with a squamous cell carcinoma of unknown primary of the head and neck and underwent a type 3 modified radical neck dissection with ipsilateral tonsillectomy. The pathologic report showed a 2.5 cm, p16 negative, single metastatic lymph node with extranodal extension (ENE) (pTxN1 according to TNM 7th edition). Adjuvant concurrent chemo-radiotherapy was completed in June 2014. Intensity modulated radiotherapy (IMRT) was delivered with Tomotherapy through a sequential plan, encompassing the follow-

* Corresponding author at: Radiation Oncology, Azienda Ospedaliero-Universitaria Careggi, University of Florence, Largo Brambilla 3, 50134 Florence, Italy.

E-mail address: bonomop@aou-careggi.toscana.it (P. Bonomo).

¹ Orcid code: 0000-0001-8999-5208.

ing structures: the right submandibular lodge and ipsilateral level IB (high risk volume), oral cavity, bilateral palatine tonsils, level IA, right levels II, III and left level IB (intermediate risk), nasopharynx, base of tongue, aryepiglottic folds, pyriform sinuses, right level IV, V and left levels II and III (low risk) receiving 66 Gy, 60 Gy and 50 Gy at conventional fractionation, respectively (Fig. 1). A total of 280 mg/m² of Cisplatin was also administered in 7 weekly introductions. The patient was free of disease until May 2017, when mucosal emergence of the primary tumor occurred: a 1 cm ulcerated lesion developed in the right upper retromolar trigone. One month after its transoral resection with clear margins, a lump developed in left level IIA. In July 2017 the patient underwent a left type 3 modified radical neck dissection which yielded 3 positive lymph nodes out of 20 located at levels IB with ENE, IIA and V, respectively (pTxN3b according to TNM 8th edition). A feasibility study for adjuvant re-irradiation was proposed but ultimately not performed for patient's refusal. After three months from salvage surgery, a multifocal loco-regional relapse was diagnosed: necrotic bilateral retropharyngeal nodes (maximum diameter of 17 mm), a 1.2 × 1.7 cm pre-laryngeal lesion and a rounded lymph node of 12 mm at left level 3 were reported. First line chemotherapy was started in accordance with the Extreme regimen [6]. A partial remission was obtained after 3 cycles, with good tolerance. Overall, after 6 cycles and 10 maintenance bi-weekly doses of Cetuximab, in September 2018 progressive disease was observed: the target lesions were now a 2 cm right infra-parotid adenopathy and the known pre-laryngeal lesion which was more than 30% larger than in previous CT. Thus, second-line Nivolumab was started, at a fixed dose of 240 mg every 2 weeks. After 7 cycles, the patient noticed a fast growing lymphadenopathy in the left supraclavicular fossa. Over just 2 weeks, a fixed mass of 6 cm had developed (Fig. 2). A CT scan (11/1/19) confirmed the focal oligoprogression (Fig. 3), showing a marked regression of the other two pathologic findings and no distant lesions. The site of progressive disease was marginal to the primary IMRT field, since left level 4 had not been encompassed in the low-risk volume (Supplementary Fig. 1). A full re-irradiation course of 66 Gy at conventional fractionation was delivered with Volumetric Modulated Arc Therapy (VMAT) (Supplementary Fig. 2): the treatment was completed on 11/3/19 without interrupting Nivolumab (cycles 9 through 12). The toxicity profile was optimal, with a G1 radiation dermatitis but no unexpected side effects. Over the following weeks, a steady regression of the mass was observed. After less than two months from the end of re-irradiation, a similar pattern of rapid swelling occurred in the right parotid gland, an intentionally spared area of the first RT course (Supplementary Fig. 3). Taking into account

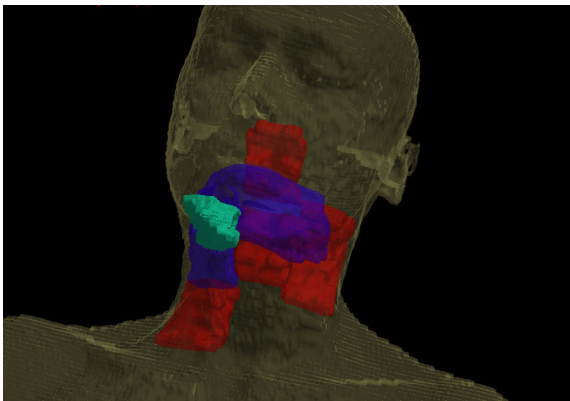


Fig. 1. Shaded surface display of first IMRT plan. Volumes encompassed by PTVs 50, 60 and 66 Gy drawn as red, blue and aqua green halos, respectively. (For interpretation of the references to colour in this figure legend, the reader is referred to the web version of this article.)

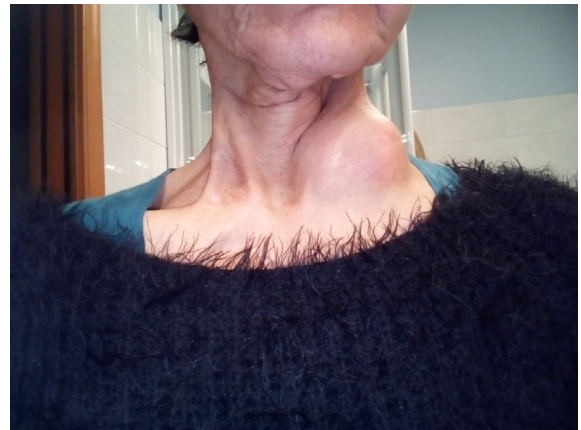

Fig. 2. Left supraclavicular mass.

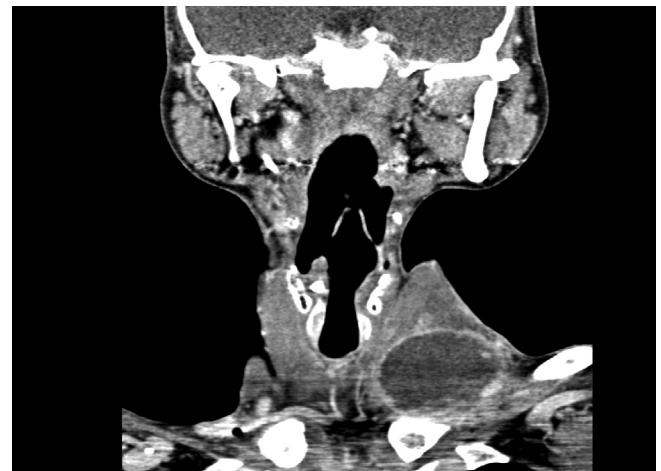

Fig. 3. CT scan showing the oligoprogressive site in the left level 4 and supraclavicular fossa (coronal view).

the dosimetric summation of previous plans, we decided to re-irradiate this second oligoprogressive lesion with VMAT delivering 30 Gy at conventional fractionation, keeping the patient on Nivolumab (Supplementary Fig. 4). Right before the start of treatment on 17/5/19, the overlying skin was infiltrated, with a 4 × 3 cm lesion (Supplementary Fig. 5). During treatment, a 2 cm ulcerative loss developed, requiring the application of daily wound dressings. The treatment was completed on 10/6/19, with mild toxicity. A

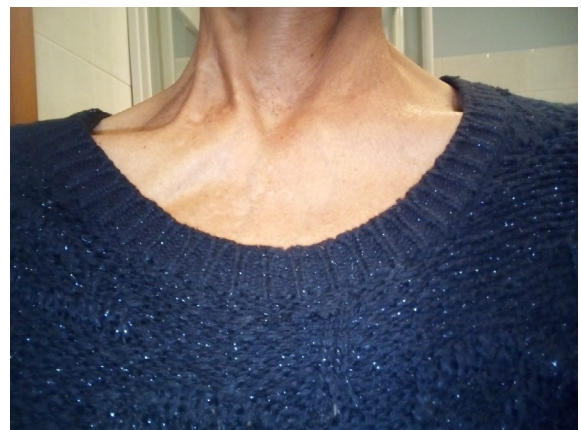

Fig. 4. Complete response in the left supraclavicular mass.

complete healing of the skin developed over the following weeks. Apart from the known left supraclavicular adenopathy, now down to 1 cm, no other evidence of disease was found at last contrast-enhanced CT scan of head, neck, thorax and upper abdomen on 22/2/20 (Fig. 4 and Supplementary Fig. 6). So far, 36 cycles of Nivolumab have been administered (last on 7/04/20), with G1 hypothyroidism and G2 diarrhea as worst immune-related adverse events.

3. Discussion

To the best of our knowledge, this is the first report on two subsequent rounds of re-irradiation for loco-regional oligoprogressive recurrences under immunotherapy in HNSCC. It has been hypothesized [7] that the classical “extended – field “ approach of head and neck radiotherapy may be detrimental to the efficacy of ICI's by inducing a chronic loco-regional immunosuppression. Along this line of thinking, some authors suggested [7–8] that a re-thinking in the design of elective clinical target volumes may be hypothesized, with the aim of not depleting all lymph node levels in the head and neck region. In contrast to this theory, some pre-clinical evidence [9] points more towards a potential “in-situ vaccination” of RT. In R/M HNSCC treated with ICI's, hyperprogression is a rare phenomenon. However, in one of the largest series published so far [10], there was a significant correlation between the development of an accelerated tumor growth with a pattern of regional recurrence, potentially implying a causative relationship with the previous extent of irradiated fields, based on unknown mechanisms. In oncogene-addicted non-small cell lung cancer, the use of local ablative therapy for oligoprogressive disease is an established approach [11], allowing for prolonged disease control and continuation of targeted therapy. In light of the introduction of ICI's into a new continuum of care for R/M HNSCC [12], this concept may be extrapolated to selected cases experiencing oligoprogression under immune checkpoint blockade.

Recently, the safety [13] and potential synergistic effect of combining palliative RT with immunotherapy have been highlighted [14–15]. Very limited data focus on R/M HNSCC. In these few reports [16–20], excellent clinical responses were observed with no major side effects (Supplementary Table 1). Our case report adds to this very limited series: the addition of state of the art re-irradiation to Nivolumab allowed to tackle the only macroscopic site of disease progression, defer the need of a further line of treatment and provide sustained clinical benefit. Oligoprogressive disease is still a relatively unrecognized entity in R/M HNSCC: our approach recalled the use of local ablative therapy for focal disease progression known for NSCLC since a few years [21]. Interestingly, the two oligoprogressive lesions were marginal recurrences in respect to the extended field design chosen as adjuvant treatment for a p16 negative squamous cell carcinoma of unknown primary. As already pointed out, the left supraclavicular fossa and right parotid gland had received minimal and moderate dose from the first irradiation (5 Gy and 22.1 Gy mean dose, respectively). Whereas 66 Gy could have been effective for a 6-cm mass by itself, one could speculate whether 30 Gy in 15 fractions would lead to a long-lasting local control. Interestingly, this dose regimen was experimentally tested in an aggressive dose de-escalation study on adjuvant chemo-radiotherapy for HPV positive oropharyngeal cancer [22–23]. Nevertheless, in both oligorecurrent lesions, the marked clinical response we observed may potentially reflect a “radiosensitizing” effect of Nivolumab, particularly when given concurrently to radiation. In this perspective, an optimal spatial cooperation may have occurred, both at a local and systemic level. Apart from the known PD-L1 positive status of our patient (Supplementary Fig. 7), no predictive biomarkers are available to support the exceptional response we reported. In order to exploit this

potential synergistic effect on a large scale, several gaps of knowledge on biologic interplay must be filled for further development. Nevertheless, we believe that very preliminary reports on selected cases like ours warrant prospective investigations on the combination of RT and immunotherapy in HNSCC.

Declaration of Competing Interest

The authors declare that they have no known competing financial interests or personal relationships that could have appeared to influence the work reported in this paper.

Appendix A. Supplementary data

Supplementary data to this article can be found online at <https://doi.org/10.1016/j.ctro.2020.04.007>.

References

- [1] Ferris RL, Blumenschein Jr G, Fayette J, Guigay J, Colevas AD, Licitra L, et al. Nivolumab for recurrent squamous-cell carcinoma of the head and neck. *N Engl J Med* 2016;375(19):1856–67.
- [2] Cohen EEW, Soulières D, Le Tourneau C, Dinis J, Licitra L, Ahn MJ, et al. Pembrolizumab versus methotrexate, docetaxel, or cetuximab for recurrent or metastatic head-and-neck squamous cell carcinoma (KEYNOTE-040): a randomised, open-label, phase 3 study. *Lancet* 2019;393(10167):156–67. [https://doi.org/10.1016/S0140-6736\(18\)31999-8](https://doi.org/10.1016/S0140-6736(18)31999-8).
- [3] Burtress B, Harrington KJ, Greir R, Soulières D, Tahara M, de Castro G, Jr, et al. Pembrolizumab alone or with chemotherapy versus cetuximab with chemotherapy for recurrent or metastatic squamous cell carcinoma of the head and neck (KEYNOTE-048): a randomised, open-label, phase 3 study. *Lancet* 2019;394(10212):1915–28. [https://doi.org/10.1016/S0140-6736\(19\)32591-7](https://doi.org/10.1016/S0140-6736(19)32591-7).
- [4] Loi M, Desideri I, Greto D, Mangoni M, Sottili M, Meattini I, et al. Radiotherapy in the age of cancer immunology: Current concepts and future developments. *Crit Rev Oncol Hematol* 2017;112:1–10. <https://doi.org/10.1016/j.critrevonc.2017.02.002>.
- [5] Dovedi SJ, Adlard AL, Lipowska-Bhalla G, McKenna C, Jones S, Cheadle EJ, et al. Acquired resistance to fractionated radiotherapy can be overcome by concurrent PD-L1 blockade. *Cancer Res* 2014;74(19):5458–68. <https://doi.org/10.1158/0008-5472>.
- [6] Vermorken JB, Mesia R, Rivera F, Remenar E, Kaweckki A, Rotte S, et al. Platinum-based Chemotherapy plus Cetuximab in head and neck cancer. *N Engl J Med* 2008;359(11):1116–27. <https://doi.org/10.1056/NEJMoa0802656>.
- [7] Sharabi AB, Lim M, DeWeese TL, Drake CG. Radiation and checkpoint blockade immunotherapy: Radiosensitisation and potential mechanisms of synergy. *Lancet Oncol* 2015;16:e498–509. [https://doi.org/10.1016/S1470-2045\(15\)00007-8](https://doi.org/10.1016/S1470-2045(15)00007-8).
- [8] Bonomo P, Desideri I, Loi M, Mangoni M, Sottili M, Marrazzo L, et al. Anti PD-L1 DUrvalumab combined with Cetuximab and Radiotherapy in locally advanced squamous cell carcinoma of the head and neck: a phase I/II study (DUCRO). *Clin Transl Radiat Oncol* 2018;9:42–7. <https://doi.org/10.1016/j.ctro.2018.01.005>.
- [9] Chen DS, Mellman I. Oncology meets immunology: the cancer-immunity cycle. *Immunity* 2013;39(1):1–10. <https://doi.org/10.1016/j.immuni.2013.07.012>.
- [10] Saada-Bouzd E, Defaucheux C, Karabajakian A, Coloma VP, Servois V, Paoletti X, et al. Hyperprogression during anti-PD-1/PD-L1 therapy in patients with recurrent and/or metastatic head and neck squamous cell carcinoma. *Ann Oncol* 2017;28(7):1605–11. <https://doi.org/10.1093/annonc/mdx178>.
- [11] Gomez DR, Tang C, Zhang J, Blumenschein GR, Hernandez M, Lee JJ, et al. Therapy or observation for patients with oligometastatic non-small cell lung cancer: long-term results of a multi-institutional phase II, randomized study. *J Clin Oncol* 2019;37(18):1558–65. <https://doi.org/10.1200/JCO.19.00201>.
- [12] Argiris A, Harrington KJ, Tahara M, Schulten J, Chomette P, Ferreira Castro A, et al. Evidence-based treatment options in recurrent and/or metastatic squamous cell carcinoma of the head and neck. *Front Oncol* 2017;7:72. <https://doi.org/10.3389/fonc.2017.00072>.
- [13] Hwang WL, Pike LRG, Royce TJ, Mahal BA, Loeffler JS. Safety of combining radiotherapy with immune-checkpoint inhibition. *Nat Rev Clin Oncol* 2018;15(8):477–94. <https://doi.org/10.1038/s41571-018-0046-7>.
- [14] Levy A, Massard C, Soria JC, Deutsch E. Concurrent irradiation with the anti-programmed cell death ligand-1 immune checkpoint blocker durvalumab: Single centre subset analysis from a phase 1/2 trial. *Eur J Cancer* 2016;68:156–62. <https://doi.org/10.1016/j.ejca.2016.09.013>.
- [15] Amin NP, Zainib M, Parker SM, Agarwal M, Mattes MD. Multi-institutional report on toxicities of concurrent nivolumab and radiation therapy. *Adv Radiat Oncol* 2018;3(3):399–404. <https://doi.org/10.1016/j.adro.2018.04.015>.
- [16] Nagasaka M, Zaki M, Kim H, Raza SN, Yoo G, Lin HS, et al. PD1/PD-L1 inhibition as a potential radiosensitizer in head and neck squamous cell carcinoma: a case report. *J Immunother Cancer* 2016;4:83.

- [17] Santos LL, Oliveira J, Monteiro E, Santos J, Sarmento C. Treatment of head and neck cancer with photodynamic therapy with Redaporfin: a clinical case report. *Case Rep Oncol* 2018;11(3):769–76. <https://doi.org/10.1159/000493423>.
- [18] Atiq SO, Atiq OO, Atiq MO, Phillips KC, Jacks BB, Moreno M, et al. The role of immunotherapy and radiation therapy in tumor chemosensitivity in advanced head and neck cancer. *Am J Case Rep* 2018;19:1241–4. <https://doi.org/10.12659/AJCR.910224>.
- [19] Finazzi T, Rordorf T, Ikenberg K, Huber GF, Guckenberger M, Garcia Schueler HL. Radiotherapy-induced anti-tumor immune response and immune related adverse events in a case of recurrent nasopharyngeal carcinoma undergoing anti-PD-1 immunotherapy. *BMC Cancer* 2018;18(1):395. <https://doi.org/10.1186/s12885-018-4295-8>.
- [20] Denaro N, Merlano MC. Unexpected response with palliative conventional therapy in head and neck squamous cell carcinoma after anti-programmed death-1 progression. *Head Neck* 2019;41(3):E42–7. <https://doi.org/10.1002/hed.25418>.
- [21] Weickhardt AJ, Scheier B, Burke JM, Gan G, Lu X, Bunn Jr PA, et al. Local ablative therapy of oligoprogressive disease prolongs disease control by tyrosine kinase inhibitors in oncogene-addicted non-small-cell lung cancer. *J Thorac Oncol* 2012;7(12):1807–14. <https://doi.org/10.1097/JTO.0b013e3182745948>.
- [22] Ma DJ, Price KA, Moore EJ, Patel SH, Hinni ML, Garcia JJ, et al. P Phase II evaluation of aggressive dose deescalation for adjuvant chemoradiotherapy in human papillomavirus associated oropharynx squamous cell carcinoma. *J Clin Oncol* 2019;37:1909–18. <https://doi.org/10.1200/JCO.19.00463>.
- [23] Garden AS. Not all 30-Gy regimens are equal. *J Clin Oncol* 2019;37(36):3558–9. <https://doi.org/10.1200/JCO.19.01666>.