

Original Article

Endovascular and microsurgical treatment of cerebral arteriovenous malformations: Current recommendations

Andrew Conger, Charles Kulwin¹, Michael T. Lawton², Aaron A. Cohen-Gadol¹Department of Neurosurgery, Louisiana State University Health Sciences Center, New Orleans, Louisiana, ¹Goodman Campbell Brain and Spine, Department of Neurological Surgery, Indiana University School of Medicine, Indianapolis, Indiana, ²University of California San Francisco, San Francisco, California, USAE-mail: Andrew Conger - aconge@lsuhsc.edu; Charles Kulwin - ckulwin@iupui.edu; Michael Lawton - lawtonm@neurosurg.ucsf.edu;*Aaron Cohen-Gadol - acohenmd@gmail.com

*Corresponding author

Received: 29 September 14 Accepted: 15 January 15 Published: 19 March 15

This article may be cited as:Conger A, Kulwin C, Lawton MT, Cohen-Gadol AA. Endovascular and microsurgical treatment of cerebral arteriovenous malformations: Current recommendations. *Surg Neurol Int* 2015;6:39.Available FREE in open access from: <http://www.surgicalneurologyint.com/text.asp?2015/6/1/39/153707>

Copyright © 2015 Conger A. This is an open-access article distributed under the terms of the Creative Commons Attribution License, which permits unrestricted use, distribution, and reproduction in any medium, provided the original author and source are credited.

Abstract

Background: Cerebral arteriovenous malformations (AVMs) can be a heterogeneous pathological entity whose management requires a complex decision-making process due to the risks associated with their treatment and natural history. Despite the recently published conclusions of the aborted Randomized Trial of Brain Unruptured AVMs (ARUBA) trial, the authors of this article believe multimodality intervention in general and microsurgical resection in particular continue to play a major role in the management of carefully selected ruptured or unruptured AVMs.

Methods: The authors provide an overview of their methodology for endovascular intervention and microsurgical resection and share their technical nuances for successful embolization and microsurgical resection of AVMs with special emphasis on complication avoidance.

Results: The authors have achieved successful outcomes in embolization and resection of cerebral AVMs when using their methodology.

Conclusions: These lesions are among the most technically difficult pathological entities handled by the cerebrovascular specialist, and an overview of technical concepts to help systematize this challenging and variable endeavor can improve the safety of their treatment.

Key Words: Complications, intracranial arteriovenous malformation, microsurgical resection, technique

Video available on:

www.surgicalneurologyint.comAccess this article
online

Website:

www.surgicalneurologyint.com

DOI:

10.4103/2152-7806.153707

Quick Response Code:

**INTRODUCTION**

Brain arteriovenous malformations (AVMs) occur in about 0.02% of the adult population.^[2] The average age of symptomatic onset in patients with AVMs is 33.7 years,^[10] with the majority becoming symptomatic between the ages of 10 and 40.^[9] The most common

presenting scenario is an intracerebral hemorrhage with seizures, focal neurologic deficits, and headache.^[12] According to a recent meta-analysis,^[10] unruptured AVMs carry a 2.2% per year risk of rupture, and previously ruptured lesions carry a 4.5% risk of rupture per year. Obliteration of the AVM nidus by microsurgical resection, stereotactic radiosurgery, endovascular embolization, or

some combination of these three modalities eliminates this ongoing risk of rupture.

Treatment of AVMs is intended to improve upon the natural history of the lesion. However, treatment carries a risk of complications, and short-term data from the aborted Randomized Trial of Brain Unruptured AVMs (ARUBA) trial suggest that treatment does not improve upon the natural history.^[27] As a result, careful assessment of the expected natural history of a given lesion, and the predicted periprocedural risk of morbidity are critically important for determining which AVMs are to be treated. Additionally, careful patient selection, meticulous planning, and experienced technique are essential for maintaining intervention as a reasonable consideration in AVM management. Solid understanding of technical nuances helps the clinician manage and prevent intraoperative complications, maximizing patient outcomes. In this article, we review our experience with endovascular embolization and microsurgical resection of AVMs, emphasizing technical nuances that aid the clinician's avoidance of periprocedural complications.

DIAGNOSIS AND EVALUATION

Most AVMs are diagnosed following the acute onset of symptoms consistent with intracerebral hemorrhage such as headaches and neurological changes secondary to rupture of the lesion. A smaller percentage of AVMs are diagnosed during investigation of focal neurologic deficits, seizures, or headaches.^[12] As neurological imaging improves and becomes easier to obtain, an increasing number of AVMs are being found incidentally.^[28] After diagnosis, a full history is obtained and physical and neurological examinations are performed. Imaging typically includes a computed tomography (CT) scan and nearly always includes digital subtraction angiography (DSA). Magnetic resonance imaging (MRI) is helpful for localization of the lesion in relation to parenchymal landmarks. The DSA is the most important piece of the preoperative imaging. The information it contains regarding hemodynamics and angioarchitecture is indispensable. The results of the preoperative evaluation are used to determine the Spetzler–Martin^[40] and Supplementary^[22] grading scale values, and at our institution, the patient's case is then presented at our interdisciplinary cerebrovascular conference. Based on the clinicians' experience, expertise, and understanding of current literature, management recommendations are presented to the patient and family who then decide how they wish to proceed.

ENDOVASCULAR EMBOLIZATION OF AVMs

Traditionally, endovascular treatment of brain AVMs has served an adjunctive role intended to facilitate microsurgical resection or radiosurgical treatment. As a

curative measure, embolization has not proven effective, and the obliteration rates of approximately 13%^[44] have not justified the 2–20% risk of periprocedural morbidity and the 1–3% risk of mortality.^[13,18,25,43,46] However, recent studies have shown an improvement of obliteration rates to 51–96% without significant increases in morbidity. This is the result of improvements in techniques, but more importantly, refined patient selection.^[36,45]

In 2010, Feliciano *et al.* reviewed and analyzed the existing literature on embolization of AVMs.^[8] This analysis determined that a low number of feeding vessels, noneloquent location, and lack of a direct AV fistula were associated with better outcomes including higher rates of obliteration and lower complication rates.^[8] Other characteristics considered favorable for safe endovascular obliteration include small size, arterial feeders that directly feed the nidus, multiple small but identifiable draining veins, a safe distance between the nidus and branches of the arterial feeders to give room for reflux of embolic material, and arterial feeders whose size and location are amenable to selective catheterization.^[31,45,47]

If a high-grade AVM is not considered safe for any type of curative treatment, embolization may serve as a way to decrease rupture risk by treating specific features associated with hemorrhage such as nidus aneurysms or venous ectasia.^[19,23,25] Additionally, embolization may be used for the reduction of AV shunting through the lesion, improving or resolving a neurologic deficit attributable to vascular steal.^[4,11,20,24] The potential benefits of this type of palliative embolization must be weighed against the published evidence of increased hemorrhage risk from incompletely treated AVMs.^[11,14]

By far the most common use of endovascular embolization at our center is as an adjuvant therapy, facilitating microsurgical resection or stereotactic radiosurgery. Embolization prior to stereotactic radiosurgery has been performed as a way of decreasing the size of the nidus and thus the requisite radiation dose.^[19,23] However, the published outcomes regarding this treatment protocol have been mixed.^[3,6,15,38,39] Although the lower radiation dose decreases the risk to the surrounding normal tissue, several studies have reported a lower rate of obliteration following such a regimen without any decrease in the risk of hemorrhage during the latency period.^[3,15,38] One study showed that for high-grade AVMs in eloquent locations, this treatment protocol shows outcomes comparable to those of other treatment options.^[7]

At our center, embolization has proven most useful as an adjunct to surgical resection. Embolization is useful for decreasing flow through an AVM and for occluding deep arterial feeders that may be difficult to access microsurgically or those accessible only at the end of dissection.^[5,21,34,37] The appropriate timing of

embolization in relation to surgery remains poorly defined. Embolization causes hemodynamic changes in the AVM and surrounding parenchyma;^[42] however, it is not clear what effect these changes have on subsequent surgery.

As a result, some centers prefer to embolize within as little as 24 h of surgery to minimize assumed increased rupture risk after partial embolization, while other centers wait as long as 3 weeks to allow for stabilization of these hemodynamic changes and presumably easier surgical resection.^[31,33,34,42]

It has been the experience of one of our senior author (ACG) that overembolization of an AVM may lead to more technical difficulty during its resection. Overembolization of the majority of the large pedicles leads the AVM to recruit deep white matter feeders to continue arteriovenous shunting. Such expansion of deep white matter feeders [Figure 1], which are most difficult to control intraoperatively, can lead to more blood loss and operative complexity. Such white matter expansion can occur in a short time (within a few days) after AVM overembolization. Therefore, the surgeon must be involved in the planning of embolization. One or two of the dominant AVM feeder pedicles accessible early in operative exposure are left unembolized preoperatively to minimize the risk of white matter expansion before surgery. In our senior author's (ACG) experience, this philosophy has led to less technical difficulty managing the troubling deep white matter feeders that are not amenable to bipolar coagulation.

Because of the varied applications of endovascular embolization in the treatment of cerebral AVMs, it is recommended that development of the treatment plan for an AVM patient includes the input of an endovascular specialist in conjunction with the microsurgeon and that

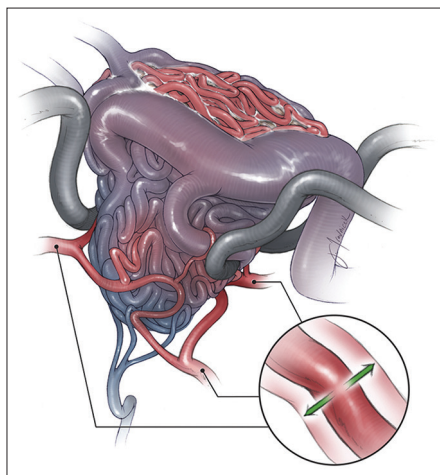


Figure 1: Over-embolization of large arterial pedicles may lead to expansion of white matter feeders (inset), leading to more technical difficulty in managing these deep feeders. Copyright The Neurosurgical Atlas, Aaron A. Cohen-Gadol, MD, MSc. Used with permission

the specific goals of embolization as determined at the outset as this will determine the approach.^[32,35]

Once goals of endovascular therapy have been determined, there are a few technical nuances worth further emphasis and consideration. The starting point for embolization is a stable catheter platform anchored in a cervical vessel. A microcatheter is then passed through this platform and selection of arterial feeders can proceed. Direct nidal feeders are ideal for embolization as all of the embolic material will accumulate in the nidus. En passage vessels must be embolized with great care as the embolic material can reflux into the parenchymal branch of the vessel causing an infarction. Arterial and venous compartments may be connected by either a nidal or fistulous connection. Nidal connections are more amenable to safe embolization than fistulous connections that allow embolic material to rapidly traverse to the venous side and may result in occlusion of a draining vein. This is more likely in AVMs with a single draining vein.

In most cases, liquid embolic agents are used for the treatment of AVMs. Two commonly used varieties are cyanoacrylates and ethylene vinyl alcohol (EVOH). Cyanoacrylates are adhesive monomers that polymerize in contact with ionic compounds, resulting in vessel occlusion and the induction of a chronic inflammatory response.^[16,17] This material is effective and durable, but can be difficult to use due to its rapid polymerization. EVOH is a newer liquid embolic agent that is dissolved in dimethyl-sulfoxide (DMSO) and sold under the trade name Onyx. It solidifies by precipitation rather than polymerization, and is generally easier to work with than cyanoacrylates. It is available in two different viscosities, and must be injected very slowly to avoid angioneurosis.^[29] Long-term data regarding the efficacy of Onyx are lacking, but some studies have shown evidence of recanalization.^[30,31]

MICROSURGICAL RESECTION

Preoperative evaluation

Once an AVM patient is selected for microsurgery, further imaging evaluation determines the best operative plan. Additional time is committed to deriving all information available from the preoperative angiogram sequences, which are studied at length before surgery. One of the senior authors (MTL) has proposed a "box" concept for analyzing AVMs; this concept assigns six surfaces to each AVM: A superficial plane, a deep plane, and four sides. Successful resection of an AVM requires dissection of these six surfaces.^[21] Most AVMs have at least one free surface that requires no parenchymal dissection. Some lesions give the surgeon a direct view of this free surface after the initial exposure, as is the case for lateral convexity AVMs [Figure 2]. Conversely, other AVMs require the

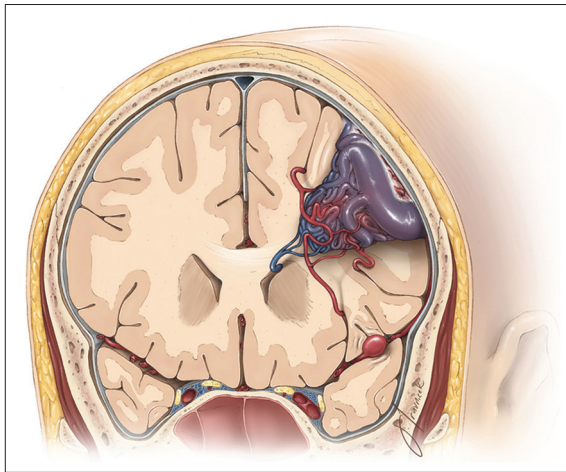


Figure 2: Classic angioarchitecture of a frontal AVM. The draining vein, arterial feeders, and a feeding vessel aneurysm are shown. Note the extension of the AVM to the level of the ventricle and the feeding arteries in the periventricular region. A complete resection of a periventricular AVM often requires exposure of the ventricle. Copyright The Neurosurgical Atlas, Aaron A. Cohen-Gadol, MD, MSc. Used with permission

surgeon to work through a tangential view of the free surface. For example, the free surface of an AVM along the medial aspect of the frontal lobe can be visualized only at an acute angle.^[21] Although every AVM is a unique lesion, certain common strategies for resection can be applied. Nonetheless, AVMs can be classified into seven types based on location, and 32 subtypes based on the involved surface of the brain.^[21] These classifications are useful because they predict the arteries and veins feeding and draining a given AVM, respectively. The long axis of the AVM most often determines how and where the craniotomy is planned, and the involved surfaces of the brain influence patient positioning during surgery to maximize the use of gravity retraction for deep lesions in order to minimize brain transgression and the use of fixed rigid retractors. For example, an AVM along the medial surface of the frontal lobe is approached through an interhemispheric approach with the patient's head turned 90 degrees laterally and the lesion side down. This allows the brain to fall away from the midline, better exposing the free surface of the AVM on the medial aspect of the frontal lobe.

Instrumentation

The operation is performed with the surgeon in the sitting position using an armrest. The surgeon's comfort prevents fatigue and provides smooth microsurgical dissection maneuvers during the critical portions of the case. These critical steps often occur later in the case when fatigue can be present. The initial dissection may be performed with loupes to prevent working into a deep hole, but as the dissection proceeds deeper, the microscope is used with the mouthpiece to minimize redundant and nondeliberate movements such as using the microscope handles to refocus the microscope.

The mouthpiece is critical for microsurgical efficiency. Monitors showing the oculars' view should be available to the other members of the operating room team to allow them to follow the procedure and inform them regarding the dissecting instruments needed for the next step.

Irrigating bipolar forceps of various lengths and tips are an important tool for dissection. The irrigation and coagulation levels of this device must be appropriately balanced to prevent accumulation of char on the tips. The tips of bipolars may be kept in cold saline solution to minimize charring of their tips during their use. Next, a variety of dissecting instruments are needed. The width of the tip of dissectors should be matched to the level of microdissection. The angled dissectors provide more flexibility in working around the corners as all the dissection is performed under direction visualization. Blunt and blind dissection is the cause of significant morbidity because of perforator injuries and unintended parenchymal transgressions. Small aneurysm clips may be used to control bleeding from white matter feeders that are not amenable to bipolar coagulation.

Anesthesia considerations

The administration of general anesthesia and intraoperative monitoring of physiologic parameters during AVM surgery must be a team effort with open communication among the members of the surgical team. Standard noninvasive monitoring is used along with direct arterial pressure monitoring to ensure that the patient's blood pressure is aggressively treated and maintained within designated parameters. Central venous access is used for larger lesions to ensure rapid restoration of fluid and blood volume if necessary. Hemodynamic stability, cerebral perfusion, and management of intracranial pressure are critically important for maximizing patient outcomes, and anesthetic agents should be selected with these parameters in mind while not interfering with neuromonitoring. Intraoperative hypotension can be used to decrease blood loss and facilitate surgical resection; however, it should be used with caution as hypotension can cause ischemia in parenchyma already subject to hypoperfusion due to arteriovenous shunting. Emergence from anesthesia can often be associated with coughing and bucking, causing periodic increases in intracranial pressure and rebleeding, so after difficult operations associated with high blood loss, large AVMs, or any other concern for postoperative bleeding, the patient remains intubated and sedated overnight to avoid these potential complications.^[26]

Patient positioning

As discussed previously, thoughtful positioning of the patient during surgery can facilitate resection by allowing the use of gravity retraction. This is facilitated by referring to the AVM subtypes as described by one of our authors (MTL).^[21] Head position is planned with venous return in mind, keeping the patient's head just above the

level of the heart, and the neck slightly extended while avoiding extreme rotation of the head to one side. This prevents intracranial venous hypertension, which can be problematic for cranial surgery in general and in AVM surgery in particular.

Common mistakes during patient positioning include failure to use free surfaces to access the lesion and maximize gravity retraction. As a result, fixed retractors may become necessary, risking cortical injury and potentially increasing morbidity. Due to the risk of intraoperative bleeding and technical challenges involved in AVM surgery, the operative corridor has to be generous and provide numerous working angles that are flexible to allow timely handling of subcortical bleeding. Finally, patient positioning should take into account operative routes that will minimize any risk to venous drainage of the AVM.

Craniotomy

We use neuronavigation based on MRI data to perform a wide craniotomy in order to expose the AVM nidus, its associated feeding arteries and draining veins, and a region of normal brain surrounding the AVM. If possible, the craniotomy is planned to provide exposure and early opening of cerebrospinal fluid (CSF) cisterns to relax the brain. If this is impractical, we recommend a lumbar drain to gradually drain CSF to provide brain relaxation. A greater number of burr holes and short passes with the craniotome decrease the risk of injury to dilated draining veins that may be traveling in the parasagittal dural leaves and venous lakes. Any violation of the dura during the use of a footplate increases the risk of unintended injury to the draining veins. The avoidance of this complication can be difficult because the engorged draining veins within the dural leaves are often large enough to erode the inner table of the calvarium. The use of the lumbar drain can facilitate thorough dissection of the decompressed dura away from

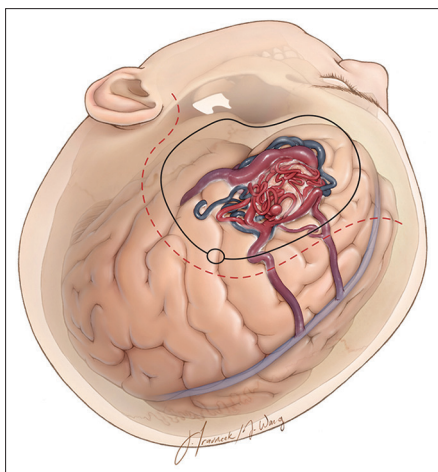


Figure 3: Incision and craniotomy for generous exposure of a left frontal AVM. Copyright *The Neurosurgical Atlas*, Aaron A. Cohen-Gadol, MD, MSc. Used with permission

the inner surface of the calvarium. After the craniotomy, a wide durotomy is made [Figures 3 and 4], with the surgeon taking great care to ensure that no underlying vessels are damaged. The dura is opened slowly and meticulously because scarring from previous hemorrhage may cause it to be adherent to the underlying AVM or an associated vessel. Tearing of a draining vein this early in the operation can be disastrous because of heavy bleeding and the likelihood of occluding the draining vein while attempting to control the hemorrhage.

Subarachnoid dissection

Following the initial exposure, some surface AVMs are readily visualized, while others are obscured by thickened, possibly hemosiderin-stained arachnoid. A draining vein at the surface may herald the path to a deep lesion, whereas others require detection of more subtle surface cues such as small arterialized veins or mildly dilated arterial feeders, either of which can be traced down a sulcus and ultimately to the AVM nidus. Subarachnoid dissection is an important step in laying out the anatomy of the AVM and securing proximal control [Figure 5]. All arachnoid planes are opened if safely possible, including deep fissures and sulci as needed to expose as much of the nidus as possible. Draining veins and feeding arteries may be partially freed of their arachnoid attachments and separated from one another and the surrounding brain to minimize their risk of traction injury during mobilization of the nidus.

While we continue to dissect the subarachnoid membranes, a thorough review of the preoperative angiogram is performed, correlating the anatomic findings seen in the surgical field to the angiogram. This helps us distinguish between arteries and veins, defines the major draining vein, and determines if arteries are terminal or *en passage*. The angiogram discloses the

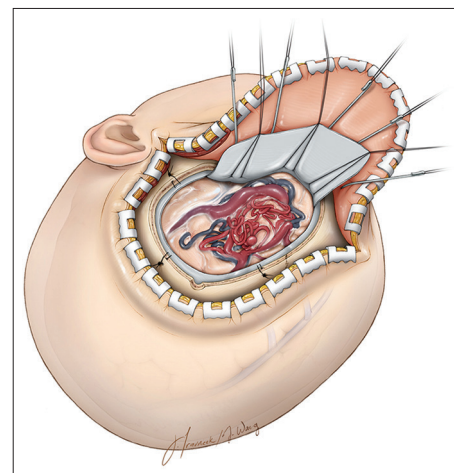


Figure 4: Intradural view of a left-sided frontal convexity AVM. A wide craniotomy is necessary to allow control over the arterial feeders and differentiating AVM related versus *en passage* vessels. Copyright *The Neurosurgical Atlas*, Aaron A. Cohen-Gadol, MD, MSc. Used with permission

compactness of margins and readily visualizes embolic material, allowing its use as a surgical landmark and navigation tool. As discussed previously, detailed study of the preoperative angiogram is essential for successful AVM surgery: This intraoperative review of the angiogram should be a recognition of details already learned, rather than a discovery of new data.^[21]

Defining the draining vein

The fundamental principle of AVM surgery is identification and preservation of the draining vein until all arterial feeders are occluded. Failure to do so results in increased nidal pressure, intraoperative rupture of the AVM, and profuse bleeding from multiple sites along the adjacent normal brain. As the dissection of the arachnoid planes is completed, the distinction of arteries from veins is undertaken.

Determination of the AVM subtype helps predict the expected location of feeding arteries and draining veins, and potentially assists in discerning between the two.^[21] The color of vessels is often not helpful because the arterialized veins appear bright red, similar to the arteries. Vessel size can be an important characteristic because arteries rarely dilate to greater than 4 mm, whereas veins often do. More subtle distinctions include striations seen in the muscular walls of arteries when visualized under high magnification. Tracing a potentially feeding vessel away from an AVM often helps to distinguish it from an *en passage* vessel. Arteries can be traced proximally into sulci and fissures and distally onto the cortical surface, whereas veins show the opposite pattern. Tracing a vein distally often reveals mixing of arterial and venous blood. Lastly, test occlusion of a vessel distal to the AVM causes a vein to turn blue beyond the point of occlusion, whereas an artery remains unchanged.

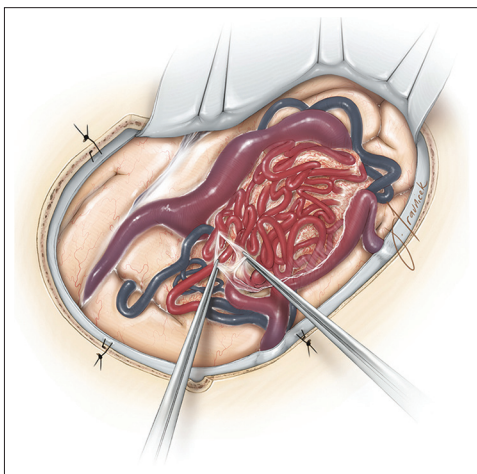


Figure 5: Arachnoid membranes covering the AVM are often thickened and should be generously dissected open to allow for clear identification of margins of the AVM's free surface and surrounding vessels. Embolized vessels and neuronavigation further assist with delineation of the AVM's margins. Copyright *The Neurosurgical Atlas*, Aaron A. Cohen-Gadol, MD, MSc. Used with permission

Once identified, the draining vein is protected throughout the remainder of dissection. Veins are kept irrigated and unstretched, and dissection proceeds on each side of the vein, connecting the developed planes beneath it, but maintaining visualization of the vein so that an instrument passed into the field does not cause its unintended injury. Common mistakes during this part of the operation include failure to distinguish arteries and veins, and inadvertent injury or occlusion of a major draining vein by not being mindful of its presence in the field.

Occluding arterial feeders

After identification of the draining veins, arterial feeders can be identified and occluded [Figure 6]. If possible, the major feeding arteries should be taken first. This decreases flow through the AVM and allows its mobilization while minimizing retraction on the surrounding brain. Usually the major arterial feeders are easily accessible on the cortical surface, sulci, or fissures after exposure of the free surface of the AVM nidus.

Before any artery is occluded, it must be identified as a terminal, *en passage*, or bystander vessel. We perform this maneuver through safely tracing the arteries proximally and distally to the AVM; we exercise patience and do not get distracted or stressed by bleeding from the AVM. Terminal vessels contribute only to the AVM and do not continue beyond the nidus. *En passage* vessels contribute branches to the AVM nidus as they pass on their way to supply brain parenchyma. Bystander vessels are near the AVM, but do not contribute any blood flow to it. Bystander and *en passage* vessels can be distinguished from each other by tracing them, beginning distal to the AVM and working in a proximal direction. Branches contributing to the AVM nidus are coagulated and divided as they identify the *en passage*

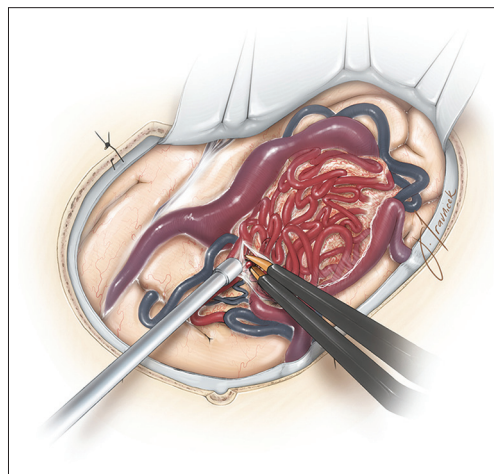


Figure 6: A surface arterial feeder is identified and occluded using bipolar electrocautery. Cortical and sulcal feeding arteries are readily amenable to bipolar coagulation and allow efficient AVM disconnection at this step of the operation. All cortical veins should be carefully protected at this stage. Copyright *The Neurosurgical Atlas*, Aaron A. Cohen-Gadol, MD, MSc. Used with permission

vessel. Absence of any contributions to the AVM nidus identifies bystander vessels, which are then protected with cottonoids. Occlusion of large and very small arterial feeders usually requires clips, whereas medium to small arteries can be coagulated over a length of about 5 mm in a proximal-to-distal direction as close to the AVM nidus as possible. Indiscriminate sacrifice of vessels around the AVM to control bleeding of an unknown source leads to brain ischemia and patient morbidity.

Pial dissection

A small number of AVMs, such as sylvian AVMs, exist entirely within the subarachnoid space, so exposure is complete after subarachnoid dissection; however, most AVMs require transgression of the pia mater for complete dissection. The pial incision is made tightly around the surface of a cone-shaped AVM, whereas it is wider around a sphere-shaped AVM, often requiring resection of some overlying cortex to prevent overhanging tissue that limits visualization and risks incomplete resection. Great care is taken to protect areas of eloquence by keeping the pial incision and subsequent dissection plane as near the AVM as possible along the edges adjacent to eloquent brain. Arterial feeders encountered on the pial surface are divided as the pial incision is made circumferentially around the AVM. These lesions do not conform to regular shapes, therefore it is important not to enter the AVM during this step of resection. Entering the nidus often leads to excessive bleeding and alerts the surgeon to stay on the outside border of the lesion.

Parenchymal dissection

Dissection proceeds into the parenchyma and follows the edge of the nidus around in a circumferential manner [Figure 7]. Although finding an appropriate dissection plane can be challenging, often a gliotic margin of white matter is present and assists with the dissection.

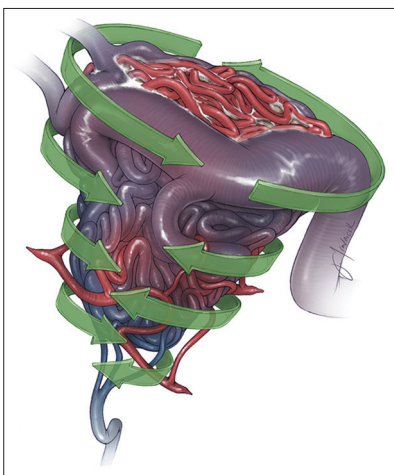


Figure 7: Parenchymal dissection proceeds around the AVM in a circumferential manner while the veins are preserved. Copyright *The Neurosurgical Atlas*, Aaron A. Cohen-Gadol, MD, MSc. Used with permission

An AVM nidus characteristically contains no neural tissue so finding this gliotic plane will allow successful dissection without transgression into normal parenchyma. Once the plane is defined, it is imperative to dissect all the way around the nidus before following the plane deeper into the parenchyma. This prevents working in a deep hole and allows the surgeon to maintain visualization and control of the entire nidus. The parenchymal dissection requires a balance between remaining too close to the nidus, which can cause bleeding, and drifting too far from the nidus into the surrounding white matter, risking neurologic morbidity. Compactness of the nidus has a significant impact on the ease with which this stage of dissection is navigated. A compact nidus has distinct margins that facilitate its dissection from the surrounding parenchyma, whereas a diffuse margin is poorly defined, forcing the surgeon to strike a balance between hemostasis and deeper transgression into the white matter with its attendant morbidity. The diffuseness of AVMs often leads to technical difficulty managing the white matter feeders that resist bipolar coagulation due to their very friable attenuated vessel walls.

Presence of a parenchymal hematoma eases this stage of the operation because it provides a parenchymal corridor that is used during dissection of the AVM. The hemorrhage has already caused neurologic morbidity, decreasing the risk of iatrogenic morbidity as that area's eloquence has been removed from the equation.

As dissection proceeds around the AVM, white matter arterial feeders are often encountered; some of the more superficial ones are amenable to occlusion using bipolar coagulation [Figure 8]. The deeper vessels are small, often friable, and very difficult to coagulate. We sometimes occlude these fine feeders by dissecting out a length

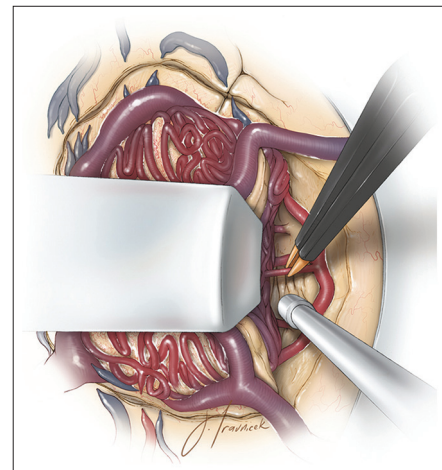


Figure 8: White matter arterial feeders are encountered during parenchymal dissection. A length of the artery is dissected out and some of the more superficial ones may be occluded with bipolar coagulation. Copyright *The Neurosurgical Atlas*, Aaron A. Cohen-Gadol, MD, MSc. Used with permission

of the vessel and applying small clips [Figure 9]. AVM vessels pathologically lose their muscular wall so tracing them away from the AVM often leads to a segment with a more robust wall, facilitating their coagulation.

We also use broad bipolar tips on a low setting during this stage of dissection. Keeping the bipolar tips cold (in ice saline) aids in dissection of these vessels by preventing the tips from becoming sticky. For larger AVMs, these deep arteries are often more problematic because some draining veins have been divided by this point in the operation, causing the remaining arterial feeders to be under high pressure. In select AVMs with angiographically known deep feeders (enlarged lenticulostriate arteries), we have alleviated this problem by dissecting down to the deepest portion of the AVM first (rather than circumdissection) and dividing these deep feeders early during the operation. However, this technique is not widely agreed upon among AVM surgeons.

Deep dissection

Dissection of the deep plane of the AVM is the most difficult. This area of dissection lies at the depths of the resection cavity [Figure 10], is blocked by the AVM nidus, has perforating and choroidal arteries to contend with, and is reached at a time when fatigue is a factor for the surgeon and the impulse to get the AVM out indiscriminately must be constrained. In anticipation of bleeding, the cavity is lined with Telfa strips that help limit bleeding if it occurs. In addition, this maneuver provides landmarks so orientation can be maintained. A retractor is helpful for visualization at this point, preferably placed on the AVM nidus. When bleeding is encountered during this stage, it is often more effective to cover the area with gelfoam and a cottonoid and continue dissection in another area. Going after small bleeders aggressively can

lead to white matter transgression and often only makes the bleeding worse. If deep hematomas are present, they are opened and used to help define the deep plane. For the classic cone-shaped AVM with an ependymal apex, dissection enters the ventricle to prevent truncation of the ependymal tip, which can leave a small remnant and persistent hemorrhage risk. Perforating arteries are often encountered at this point, and are managed as previously discussed. Choroidal arteries are more easily controlled with bipolar electrocautery, although if these vessels are difficult to visualize behind the AVM nidus, clips can be applied. If a choroidal artery gets away, it can cause unrecognized bleeding into the ventricle, risking brain herniation. The ependymal arteries can be a significant source of feeding vessels to the AVM. Therefore, brain herniation at this step of the operation should alert the operator to examine the ventricle to evacuate the blood and deal meticulously with the bleeding ependymal feeding vessels.

Resection

After dissection of the AVM is complete, the draining vein should be noticeably blue, indicating an absence of arterial input. Persistent red color within the vein necessitates inspection for an arterial feeder that was missed. Most commonly an arterial feeder is hidden under the draining vein or a remnant was left in a difficult-to-visualize area of the resection cavity. The draining vein may be temporarily occluded to ensure no swelling within the AVM. If it is unclear whether the arterial supply has been completely occluded, indocyanine green can be administered. No fluorescent signal should be detected within the draining vein. At this point, the AVM nidus is rolled out of the resection cavity attached to its venous pedicle. The draining vein is then

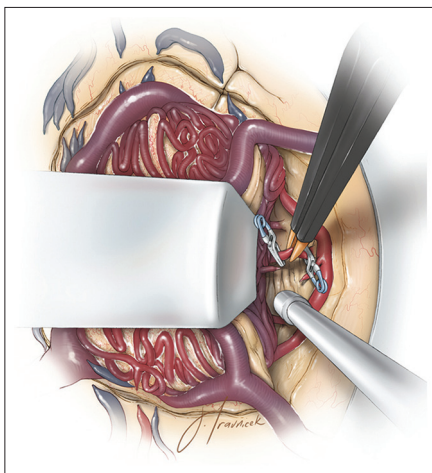


Figure 9: Deep arterial feeders may be clipped and divided as they do not easily occlude with bipolar coagulation. When not in use, bipolar forceps may be kept in ice saline to minimize charring at their tips during their application. Copyright *The Neurosurgical Atlas*, Aaron A. Cohen-Gadol, MD, MSc. Used with permission

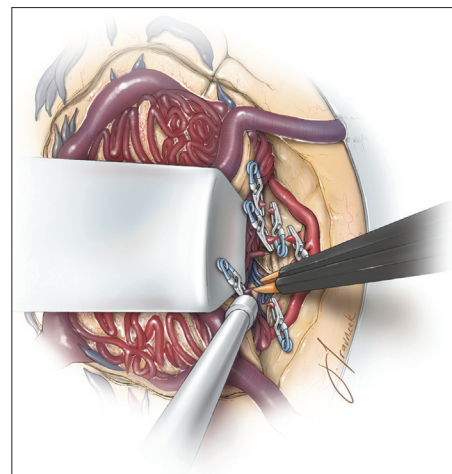


Figure 10: Parenchymal dissection and division of deep arterial feeders proceed toward the ventricle. If bleeding is encountered, the small deep veins and choroidal feeding vessels are coagulated and divided. All arterialized veins are protected until the last stage of the operation. Copyright *The Neurosurgical Atlas*, Aaron A. Cohen-Gadol, MD, MSc. Used with permission

coagulated or clipped and divided [Figure 11]. Inspection of the resection cavity should reveal only minor “ooze,” which can be controlled [Figure 12]. Aggressive bipolar coagulation should be avoided due to the friable nature of the surrounding brain; thrombin solution may be used for minor white matter “oozing.” More persistent bleeding should alert the surgeon to the presence of AVM remnant. One of the senior authors (ACG) routinely performs an intraoperative angiogram for moderate-to-large size AVMs. The resection cavity is observed during a Valsalva maneuver and a period of elevated systolic blood pressure to ensure that no bleeding begins under these conditions.

The technical nuances for AVM resection are illustrated in Video 1 (available on the World Wide Web at <https://www.youtube.com/watch?v=WA2FTX1NKIY>).

Postoperative management

The patient is admitted to the intensive care unit after surgery and his or her systolic blood pressure is kept below what is normal for the patient (~100–120 mm/Hg). The patient is closely observed for evidence of postoperative bleeding. After difficult cases, large AVMs, presence of intraoperative swelling, or any case that causes concern for postoperative hemorrhage, the patient is kept intubated and sedated overnight to prevent the blood pressure spikes that often accompany coughing and gagging during extubation. A postoperative CT and angiogram is obtained on postoperative day 1. If any AVM remnant is observed, the patient is returned for reoperation immediately or as soon as the patient is deemed safe to return to surgery. Pediatric AVMs are notorious for their recurrence, partly due to their noncompact nidus, and must undergo surveillance imaging for years after surgery.

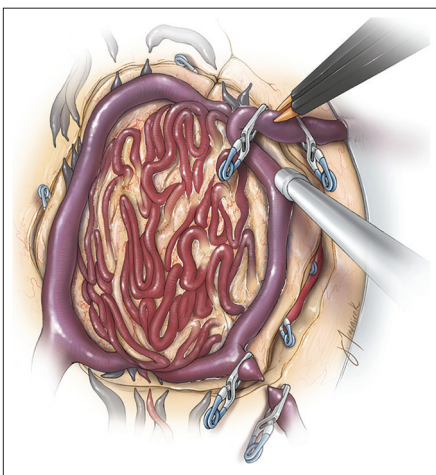


Figure 11: After all arterial feeders are occluded, the primary draining vein is clipped, coagulated, and transected. Copyright *The Neurosurgical Atlas*, Aaron A. Cohen-Gadol, MD, MSc. Used with permission

COMPLICATIONS

Resection or embolization of AVMs can be marred by many complications, including neurologic deficits from overly aggressive dissection or ischemic infarcts, seizures, hydrocephalus, and infection; however, three complications deserving specific consideration are intraoperative rupture, postoperative hemorrhage, and postoperative edema.

Intraoperative AVM rupture is a potentially disastrous consequence of premature occlusion of one or more major draining veins. This complication is usually a result of mistaking numerous smaller arterialized veins for feeding arteries and occluding them, although it can be caused by inadvertent occlusion of the prominent draining vein. This sometimes occurs during attempts to regain hemostasis after the draining vein is injured or by kinking of the vein while the nidus is held in fixed retraction. This can also occur during attempted embolization of a high-flow fistula. All of these unfortunate events are more likely in the event of heavy bleeding and pressured decision-making, underscoring the importance of maintaining hemostasis throughout the dissection.

Residual AVM nidus may lead to bleeding within the adjacent normal brain, leading to intraoperative brain swelling. Once a significant portion of the AVM outflow has been compromised, the nidus swells, arterial feeders engorge and become less responsive to coagulation, and areas of the nidus begin to spontaneously bleed. At this point, careful, methodical dissection is no longer an option, and an operation ensues that we refer to as “commando resection.”^[21] The impending AVM rupture necessitates thoughtful, decisive, and deliberately aggressive mobilization of the nidus and coagulation of

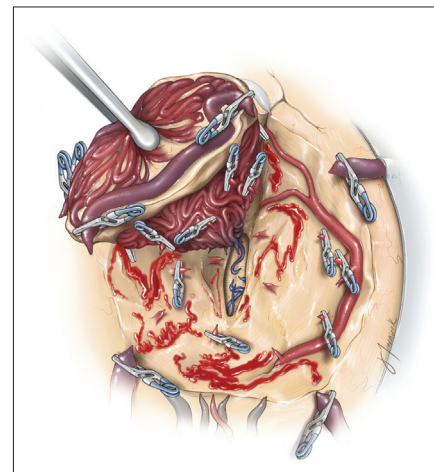


Figure 12: The AVM is removed from the resection cavity, which is inspected for any persistent bleeding. Often, aggressive coagulation should be avoided since the brain may be quite friable. We irrigate the resection cavity with thrombin solution and exercise patience. Copyright *The Neurosurgical Atlas*, Aaron A. Cohen-Gadol, MD, MSc. Used with permission

the remaining larger arterial feeders. Smaller feeders near the base of the AVM are initially ignored as the nidus is removed. Then, with the nidus out of the way, the cavity is rapidly examined for active bleeders and hemostasis is re-established. This often requires dissecting into the white matter to expose a length of these small, friable, deep perforating vessels, followed by clip application. Because of its increased risk of morbidity, this type of resection is clearly not ideal, but it is essential under these circumstances to prevent rupture of the AVM and potentially catastrophic blood loss.

Severe edema and hemorrhage are the two most common postoperative complications after resection or embolization of large AVMs. The exact etiology of these complications remains unclear, but is almost certainly a result of altered hemodynamics in the wake of AVM resection. Two explanations have been reported. Spetzler *et al.* attributed these phenomena to normal perfusion pressure breakthrough, asserting that the arterioles surrounding an AVM have been exposed to low perfusion pressures and are maximally vasodilated.^[41] As a result, these arterioles are unable to immediately autoregulate upon restoration of normal perfusion pressures following AVM resection. This leads to edema and hemorrhage within the surrounding brain. The second explanation, from al-Rodhan *et al.*, suggests that obstruction of venous outflow and stagnant arterial flow in the tissues surrounding the resection cavity combine to cause edema, hypoperfusion, ischemia, and hemorrhage.^[1]

Regardless of the cause, these complications are more common with larger AVMs and with AVMs with high-flow shunting. They can often be minimized or avoided by gradual embolization of portions of the AVM before surgery to allow the surrounding brain to accommodate for hemodynamic changes that ensue after sudden AVM resection. In other words, this is often staged to allow blood flow to return to hypoperfused regions in a piecemeal fashion, rather than all at once following resection. Managing the altered hemodynamics in this staged manner decreases the incidence of these postoperative complications. If edema or hemorrhage develops postoperatively despite meticulous blood pressure control, it can be effectively managed medically with hypertonic therapies or, if necessary, a ventriculostomy to drain CSF and decrease intracranial pressure.

CONCLUSIONS

Microsurgical resection remains the ideal treatment for many cerebral AVMs. It is a definitive and immediate cure for a potentially devastating pathology. Resection can often be facilitated by endovascular embolization, and in carefully selected cases, embolization may be a

curative treatment on its own. Although AVM treatment can be fraught with complications and morbidity, the combination of judicious patient selection, tireless assessment of all preoperative data, meticulous technical skill, and the humility of the clinician to recognize, correct, and learn from one's mistakes results in favorable outcomes for management of one of the most daunting cerebrovascular lesions.

REFERENCES

1. Al-Rodhan NR, Sundt TM Jr, Piepgras DG, Nichols DA, Rufenacht D, Stevens LN. Occlusive hyperemia: A theory for the hemodynamic complications following resection of intracerebral arteriovenous malformations. *J Neurosurg* 1993;78:167-75.
2. Al-Shahi R, Fang JS, Lewis SC, Warlow CP. Prevalence of adults with brain arteriovenous malformations: A community based study in Scotland using capture-recapture analysis. *J Neurol Neurosurg Psychiatry* 2002;73:547-51.
3. Andrade-Souza YM, Ramani M, Beachey DJ, Scora D, Tsao MN, Terbrugge K, *et al.* Liquid embolisation material reduces the delivered radiation dose: A physical experiment. *Acta Neurochir (Wien)* 2008;150:161-4; discussion 4.
4. Batjer HH, Devous MD Sr, Seibert GB, Purdy PD, Ajmani AK, Delarosa M, *et al.* Intracranial arteriovenous malformation: Relationships between clinical and radiographic factors and ipsilateral steal severity. *Neurosurgery* 1988;23:322-8.
5. Bendok BR, El Tecle NE, ElAhmadi TY, Koht A, Gallagher TA, Carroll TJ, *et al.* Advances and innovations in brain arteriovenous malformation surgery. *Neurosurgery* 2014;74 Suppl 1:S60-73.
6. Bing F, Doucet R, Lacroix F, Bahary JP, Darsaut T, Roy D, *et al.* Liquid embolization material reduces the delivered radiation dose: Clinical myth or reality? *AJNR Am J Neuroradiol* 2012;33:320-2.
7. Blackburn SL, Ashley WW Jr, Rich KM, Simpson JR, Drzymala RE, Ray WZ, *et al.* Combined endovascular embolization and stereotactic radiosurgery in the treatment of large arteriovenous malformations. *J Neurosurg* 2011;114:1758-67.
8. Feliciano CE, de Leon-Berra R, Hernandez-Gaitan MS, Rodriguez-Mercado R. A proposal for a new arteriovenous malformation grading scale for neuroendovascular procedures and literature review. *P R Health Sci J* 2010;29:117-20.
9. Fullerton HJ, Achrol AS, Johnston SC, McCulloch CE, Higashida RT, Lawton MT, *et al.* Long-term hemorrhage risk in children versus adults with brain arteriovenous malformations. *Stroke* 2005;36:2099-104.
10. Gross BA, Du R. Natural history of cerebral arteriovenous malformations: A meta-analysis. *J Neurosurg* 2013;118:437-43.
11. Han PP, Ponce FA, Spetzler RF. Intention-to-treat analysis of Spetzler-Martin grades IV and V arteriovenous malformations: Natural history and treatment paradigm. *J Neurosurg* 2003;98:3-7.
12. Hofmeister C, Stapf C, Hartmann A, Sciacca RR, Mansmann U, terBrugge K, *et al.* Demographic, morphological, and clinical characteristics of 1289 patients with brain arteriovenous malformation. *Stroke* 2000;31:1307-10.
13. Jahan R, Murayama Y, Gobin YP, Duckwiler GR, Vinters HV, Vinuela F. Embolization of arteriovenous malformations with Onyx: Clinicopathological experience in 23 patients. *Neurosurgery* 2001;48:984-95; discussion 95-7.
14. Kalani MY, Albuquerque FC, Fiorella D, McDougall CG. Endovascular treatment of cerebral arteriovenous malformations. *Neuroimaging Clin N Am* 2013;23:605-24.
15. Kano H, Kondziolka D, Flickinger JC, Park KJ, Iyer A, Yang HC, *et al.* Stereotactic radiosurgery for arteriovenous malformations after embolization: A case-control study. *J Neurosurg* 2012;117:265-75.
16. Kish KK, Rapp SM, Wilner HI, Wolfe D, Thomas LM, Barr J. Histopathologic effects of transarterial bucrylate occlusion of intracerebral arteries in mongrel dogs. *AJNR Am J Neuroradiol* 1983;4:385-7.
17. Klara PM, George ED, McDonnell DE, Pevsner PH. Morphological studies of human arteriovenous malformations. Effects of isobutyl 2-cyanoacrylate embolization. *J Neurosurg* 1985;63:421-5.
18. Klurfan P, Gunnarsson T, Haw C, Ter Brugge KG. Endovascular treatment

- of brain arteriovenous malformations: The Toronto experience. *Interv Neuroradiol* 2005;11:51-6.
19. Krings T, Hans FJ, Geibprasert S, Terbrugge K. Partial "targeted" embolisation of brain arteriovenous malformations. *Eur Radiol* 2010;20:2723-31.
 20. Kusske JA, Kelly WA. Embolization and reduction of the "steal" syndrome in cerebral arteriovenous malformations. *J Neurosurg* 1974;40:313-21.
 21. Lawton MT. Seven AVMs: Tenets and Techniques for Resection. New York: Thieme Medical Publishers; 2014.
 22. Lawton MT, Kim H, McCulloch CE, Mikhak B, Young WL. A supplementary grading scale for selecting patients with brain arteriovenous malformations for surgery. *Neurosurgery* 2010;66:702-13; discussion 13.
 23. Le Feuvre D, Taylor A. Target embolization of AVMs: Identification of sites and results of treatment. *Interv Neuroradiol* 2007;13:389-94.
 24. Luessenhop AJ, Mujica PH. Embolization of segments of the circle of Willis and adjacent branches for management of certain inoperable cerebral arteriovenous malformations. *J Neurosurg* 1981;54:573-82.
 25. Meisel HJ, Mansmann U, Alvarez H, Rodesch G, Brock M, Lasjaunias P. Effect of partial targeted N-butyl-cyano-acrylate embolization in brain AVM. *Acta Neurochir (Wien)* 2002;144:879-87; discussion 88.
 26. Miller C, Mirski M. Anesthesia considerations and intraoperative monitoring during surgery for arteriovenous malformations and dural arteriovenous fistulas. *Neurosurg Clin N Am* 2012;23:153-64.
 27. Mohr JP, Parides MK, Stapf C, Moquete E, Moy CS, Overbey JR, et al. Medical management with or without interventional therapy for unruptured brain arteriovenous malformations (ARUBA): A multicentre, non-blinded, randomised trial. *Lancet* 2014;383:614-21.
 28. Morris Z, Whiteley W, Longstreth WT Jr, Weber F, Lee YC, Tsumishima Y, et al. Incidental findings on brain magnetic resonance imaging: Systematic review and meta-analysis. *BMJ* 2009;339:b3016.
 29. Murayama Y, Vinuela F, Uthoa A, Akiba Y, Duckwiler GR, Gobin YP, et al. Nonadhesive liquid embolic agent for cerebral arteriovenous malformations: Preliminary histopathological studies in swine rete mirabile. *Neurosurgery* 1998;43:1164-75.
 30. Natarajan SK, Born D, Ghodke B, Britz GW, Sekhar LN. Histopathological changes in brain arteriovenous malformations after embolization using Onyx or N-butyl cyanoacrylate. Laboratory investigation. *J Neurosurg* 2009;111:105-13.
 31. Natarajan SK, Ghodke B, Britz GW, Born DE, Sekhar LN. Multimodality treatment of brain arteriovenous malformations with microsurgery after embolization with onyx: Single-center experience and technical nuances. *Neurosurgery* 2008;62:1213-25; discussion 25-6.
 32. Ogilvy CS, Stieg PE, Awad I, Brown RD Jr, Kondziolka D, Rosenwasser R, et al. AHA Scientific Statement: Recommendations for the management of intracranial arteriovenous malformations: A statement for healthcare professionals from a special writing group of the Stroke Council, American Stroke Association. *Stroke* 2001;32:1458-71.
 33. Potts MB, Jahangiri A, Jen M, Sneed PK, McDermott MW, Gupta N, et al. Deep arteriovenous malformations in the Basal Ganglia, Thalamus, and Insula: Multimodality management, patient selection, and results. *World Neurosurg* 2014;82:386-94.
 34. Pradilla G, Coon AL, Huang J, Tamargo RJ. Surgical treatment of cranial arteriovenous malformations and dural arteriovenous fistulas. *Neurosurg Clin N Am* 2012;23:105-22.
 35. Richling B, Killer M, Al-Schameri AR, Ritter L, Agic R, Krenn M. Therapy of brain arteriovenous malformations: Multimodality treatment from a balanced standpoint. *Neurosurgery* 2006;59:S148-57; discussion S3-13.
 36. Saatci I, Geyik S, Yavuz K, Cekirge HS. Endovascular treatment of brain arteriovenous malformations with prolonged intranidal Onyx injection technique: Long-term results in 350 consecutive patients with completed endovascular treatment course. *J Neurosurg* 2011;115:78-88.
 37. Sanborn MR, Park MS, McDougall CG, Albuquerque FC. Endovascular approaches to pial arteriovenous malformations. *Neurosurg Clin N Am* 2014;25:529-37.
 38. Schwyzer L, Yen CP, Evans A, Zavoian S, Steiner L. Long-term results of gamma knife surgery for partially embolized arteriovenous malformations. *Neurosurgery* 2012;71:1139-47; discussion 47-8.
 39. Shtraus N, Schifter D, Corn BW, Maimon S, Alani S, Frolov V, et al. Radiosurgical treatment planning of AVM following embolization with Onyx: Possible dosage error in treatment planning can be averted. *J Neurooncol* 2010;98:271-6.
 40. Spetzler RF, Martin NA. A proposed grading system for arteriovenous malformations. *J Neurosurg* 1986;65:476-83.
 41. Spetzler RF, Wilson CB, Weinstein P, Mehdorn M, Townsend J, Telles D. Normal perfusion pressure breakthrough theory. *Clin Neurosurg* 1978;25:651-72.
 42. Starke RM, Meyers PM, Connolly ES. Adjuvant endovascular management of brain arteriovenous malformations. In: Winn R, editor. *Youmans Neurological Surgery*. [jo; ade;] Elsevier; 2011. p. 4058.
 43. Taylor CL, Dutton K, Rappard G, Pride GL, Replogle R, Purdy PD, et al. Complications of preoperative embolization of cerebral arteriovenous malformations. *J Neurosurg* 2004;100:810-2.
 44. van Beijnum J, van der Worp HB, Buis DR, Al-Shahi Salman R, Kappelle LJ, Rinkel GJ, et al. Treatment of brain arteriovenous malformations: A systematic review and meta-analysis. *JAMA* 2011;306:2011-9.
 45. van Rooij WJ, Jacobs S, Sluzewski M, van der Pol B, Beute GN, Sprengers ME. Curative embolization of brain arteriovenous malformations with onyx: Patient selection, embolization technique, and results. *AJNR Am J Neuroradiol* 2012;33:1299-304.
 46. Vinuela F, Duckwiler G, Jahan R, Murayama Y. Therapeutic management of cerebral arteriovenous malformations. Present role of interventional neuroradiology. *Interv Neuroradiol* 2005;11:13-29.
 47. Yu SC, Chan MS, Lam JM, Tam PH, Poon WS. Complete obliteration of intracranial arteriovenous malformation with endovascular cyanoacrylate embolization: Initial success and rate of permanent cure. *AJNR Am J Neuroradiol* 2004;25:1139-43.