

Urethral duplication: a rare cause of urinary incontinence in a female child

Atul Khandelwal, Sanjay Gupta, Rajesh Tiwari, Vijoy Kumar, Mahendra Singh

Indira Gandhi Institute of Medical Sciences, Patna, India

KEY WORDS

female ▶ urethra ▶ duplication

ABSTRACT

Female urethral duplication is a rare congenital anomaly. We report a case of complete urethral duplication along with horseshoe kidney in a four-years-old female child presenting with incontinence since childhood.

INTRODUCTION

Urethral duplication and accessory urethra are both extremely rare lower urinary tract malformations, especially in females. One classification, proposed by Stephens, is based on the location and degree of duplications [1]. Type I is complete or incomplete duplication with a dorsal accessory urethra and may communicate with the ventrally placed orthotopic urethra or end blindly. Type II is a complete duplication with accessory urethra in an epispadiac location related to the orthotopic urethra lying below. Type III represents a sinus that simulates an accessory urethra and runs from the prepubic area behind symphysis toward the bladder, with the true urethra positioned ventrally. We report a case of complete urethral duplication along with horseshoe kidney in a four-year-old female child presenting with constant dribbling since childhood.

CASE REPORT

A four-year-old female child presented with urinary continuous loss of urine since childhood while she was passing urine with good stream. Clinical examination revealed normal genitalia with an apparently normal urethral opening below clitoris.

Pubic symphysis was intact and was not split. Hemogram and blood chemistry was normal. Intravenous urography revealed functioning horseshoe kidneys. Micturating cystourethrogram showed smooth walled good capacity bladder and no reflux. Cystoscopy was done under general anesthesia through a normal urethral meatus and showed a normal anatomy of the urethra, bladder neck, and ureteric orifices. A narrow stream of urine was observed gushing out through a small opening located over the clitoris after applying suprapubic pressure with a full bladder. Through a 24 French intravenous canula placed over the clitoral opening, methylene blue was injected. A narrow blue stream was observed effluxing through an opening located above the normal bladder neck confirming the diagnosis of urethral duplication. The bladder was opened through suprapubic incision and there were two internal urethral meatuses with well developed bladder necks, the accessory one located above

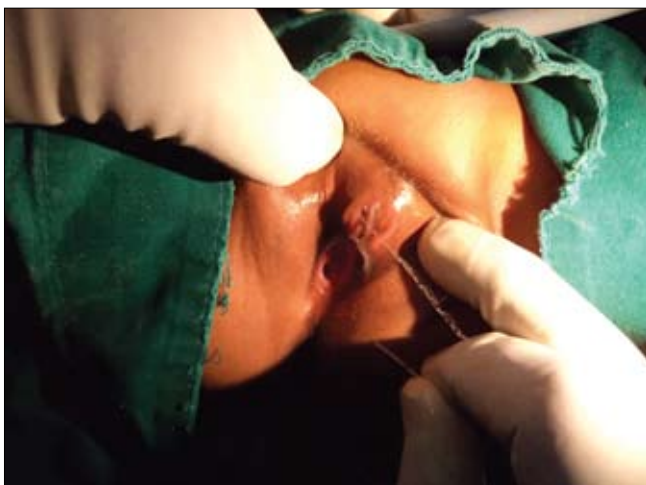

Fig. 1. A visible stream of urine from the accessory urethra after applying suprapubic pressure.

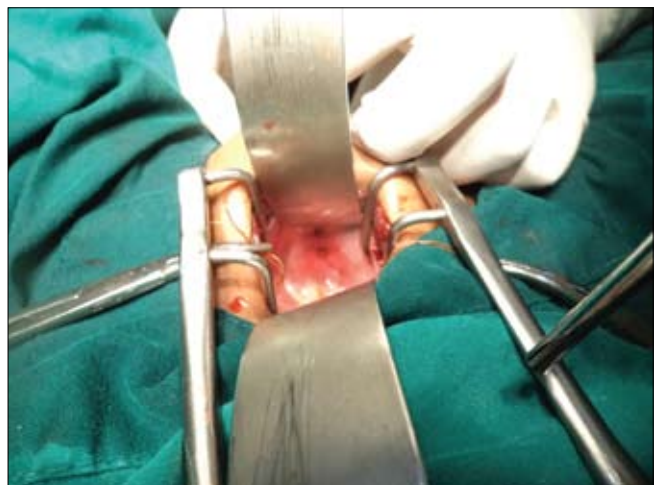

Fig. 2. Accessory urethra opens into the bladder, just above the bladder neck.

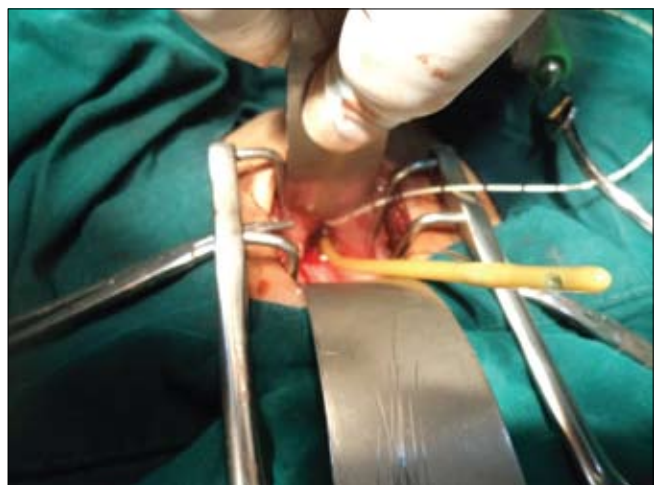


Fig. 3. Ureteric and Foley catheters emerging from accessory and normal urethras, respectively.

the normal one. A four French ureteric catheter was passed through the accessory bladder neck and came out through the clitoral opening. The bladder was bivalved up to the accessory superiorly located bladder neck and distal urethra was dismembered. The bladder was closed in two layers over Foley's catheter. The patient became continent and asymptomatic after removal of the catheter.

DISCUSSION

In the female, complete urethral duplication is rare and most often occurs with the bladder duplication [2]. There may be other anomalies including genitourinary, gastrointestinal, and vertebral deformities [3-6]. The patient reported here has a complete accessory urethra with a single bladder and associated with horseshoe kidney, but no other anal or vertebral anomalies. In the female the accessory urethra is usually sub corporeal, phallic, or vaginal [7]. The accessory urethra of the patient in the present study lay in a phallic position. Such a position for the accessory urethra in the female has been rarely reported.

Most cases present during childhood. A patient with complete patent urethral duplication may be asymptomatic or may present with split urinary stream, incontinence, UTIs, or obstructive voiding symptoms. Radiographic studies and intraoperative findings best distinguish a true duplication [8].

A review of published data revealed 35 cases of female urethral duplication reported since 1970; however, in all but five cases the duplication occurred in association with other anomalies [9]. Nicholas et al. reported two cases of urethral duplication without any anomalies. Multiple etiologies have been postulated to account for duplication. One involves persistence of a cloacal membrane, which can cause posterior displacement of the mesoderm of the urogenital tubercle resulting in a division of the urethral plate. This could explain the association of urethral duplication and genital abnormalities such as bifid clitoris. Another possibility is that inflammation of a vascular injury temporarily obstructs the development and leads to urethral plate division and subsequent duplication [10].

CONCLUSION

Urethral duplication in girls is very rare but should be considered in girls who have complete incontinence since birth. A thorough examination is required. Our patient's urethral duplication is unique in that it is a complete duplication with phallic accessory urethra and associated with a horseshoe kidney. Surgical management is the main treatment modality.

REFERENCES

- Stephens F: *Abnormal Embryology - Cloacal Dysgenesis: Congenital Malformations of the urinary tract*, New York, Praeger Publishing Scientific 1983, pp. 15-52.
- Williams DI: *Female urethral anomalies and obstruction*. In: D.I. Williams & J.H. Johnston, Paediatric Urology, 2nd ed., London, Butterworth 1982, pp. 279-287.
- Haralson IP: *Double bladder and urethra with imperforate anus and ureterorenal: a case presentation with review of literature*. J Urol 1980; 123: 776-777.
- Esham W, Holt AH: *Complete duplication of bladder and urethra. A case report*. J Urol 1980; 123: 773-775.
- Hunter TB & Tonkin LD: *Complete duplication of the colon in association with the urethral duplication*. Gastrointest Radiol 1979; 4: 93-95.
- Woodhouse CRJ, Williams DI: *Duplication of the lower urinary tract in children*. Br J Urol 1979; 51: 481-487.
- Kaur M, Pleasure JR: *Complete duplication of the female urethra in a neonate*. Clin Paediatr (Philadelphia) 1982; 21: 759-760.
- Elmore JM, Wilson TS, Zimmern PE: *Adult presentation of complete female urethral duplication*. BJU Int 2003; 92 Suppl 3: e13.
- Cost NG, Lucas SM, Baker LA: *Two girls with urethral duplication*. Urology 2008; 72: 800-802.
- Walther MM, Woodard JR: *Subpubic fistula: a urethral duplication*. J Urol 1996; 155: 1728-1729.

Correspondence

Atul Khandelwal
Indira Gandhi Institute of Medical Sciences
Department of Urology
Sheikhpura
800014 Patna, India
phone: +91 773 946 99 59
dratulkhandelwal@yahoo.com