

Radiofrequency ablation in a patient with radiation enteritis

A case report

Xing-jie Shen, MD, Liang Liu, MD, Jing-yu Zhu, MD*

Abstract

Rationale: Radiation enteritis (RE) is one of the serious complications caused by the radiotherapy and it can occur in any segment of the intestine, including small intestine, colon, and rectum. It can cause a number of serious problems of the intestine, such as chronic ulcers, bleeding, intestinal stenosis, intestinal fistula, and perforation. At present, there is no standard treatment guideline for the RE.

Patient Concerns: A 54-year-old male patient received surgery and chemotherapy for rectal cancer and radiofrequency ablation (RFA) for a single metastatic carcinoma of the liver. Three years later, he was diagnosed with recurrent lesion in the rectal anastomotic stoma and was treated with radiotherapy with a total dose of 70 Gy. Following this, he had persistent abdominal pain and diarrhea for 1 year.

Diagnoses: Colonoscopy confirmed a diagnosis of RE.

Interventions: Since intestinal probiotics, intestinal mucosal protectants, antidiarrheal drugs, and other treatments were not effective; the patient was treated by RFA.

Outcomes: Clinical symptoms of the patient were gradually decreased after the RFA. Colonoscopy examination was performed 3 months later and intestinal mucosa was found to have healed well.

Lessons: RFA is an effective treatment for patients with RE, and it is expected to be one of the standard treatments for the RE.

Abbreviations: RE = radiation enteritis, RFA = radiofrequency ablation.

Keywords: radiation enteritis, radiofrequency ablation, therapy

1. Introduction

Radiotherapy is one of the methods for cancer treatment.^[1] In China, the number of patients who received radiotherapy for malignant tumors is increasing year by year.^[2] The radiotherapy is accompanied by adverse effects on normal tissues and organs. Radiation enteritis (RE) is one of the serious complications caused by the radiotherapy and it can occur in any segment of the intestine, including small intestine, colon, and rectum. In China, the incidence of the RE is on the rise.^[2]

Editor: N/A.

This work was supported by grants from the Shandong province medical and health science and technology development plan (clinical study of minimally invasive treatment under endoscopy of gastrointestinal mucosa) (2016WS0124) and the fourth Batch Items of Jinan Science and Technology Development Plan in 2016 (Clinical Medicine Science and Technology Innovation Plan) (201602355).

The authors have no conflicts of interest to disclose.

Department of Gastroenterology, Ji'nan Central Hospital Affiliated to Shandong University, Jinan, China.

* Correspondence: Jing-yu Zhu, Department of Gastroenterology, Jinan Central Hospital Affiliated to Shandong University, Lixia District, Jinan, Shandong, P.R. China (e-mail: jingyu_esd@126.com).

Copyright © 2018 the Author(s). Published by Wolters Kluwer Health, Inc. This is an open access article distributed under the terms of the Creative Commons Attribution-Non Commercial License 4.0 (CCBY-NC), where it is permissible to download, share, remix, transform, and buildup the work provided it is properly cited. The work cannot be used commercially without permission from the journal.

Medicine (2018) 97:47(e13328)

Received: 13 June 2018 / Accepted: 26 October 2018

<http://dx.doi.org/10.1097/MD.0000000000013328>

Foreign scholars reported that the incidence of the RE was as high as 20%.^[3] The RE causes a number of serious problems of the intestine, such as chronic ulcers, bleeding, intestinal stenosis, intestinal fistula, and perforation, which seriously affects patients' quality of life.^[3] At present, there is no standard treatment guideline for the RE. The effects of drugs, hyperbaric oxygen and other treatments in the RE are not very accurate.^[1,4–7] Radiofrequency ablation (RFA) is an emerging non-invasive method which is operated by means of endoscopy. The RFA causes coagulation and necrosis of the intestinal mucosa by thermal effect. Currently, it has been widely used for the treatment of Barrett esophagus and chronic erosive gastritis. Unfortunately, studies reporting the treatment of RE by RFA are lacking. We herein report the case of a patient with RE who received the RFA therapy.

2. Case presentation

A 54-year-old male patient was admitted to our hospital with bloody stool and mild anemia for 2 months and he was diagnosed as rectal cancer in our hospital in March 2013. He received surgery for rectal cancer on March 26, 2013 and 6 cycles of chemotherapy were given after the surgery (the chemotherapy regimen is FOLFOX). A single metastatic carcinoma of the liver was discovered in September 2013 and then he was given the RFA in the liver. Since then, the patient was in a stable condition for more than a year. In March 2015, multiple metastatic lesions were found in his liver, and chemoembolization was performed on March 25, 2015, then, 4 cycles of adjuvant chemotherapy were given after the operation (raltitrexed + bevacizumab). The

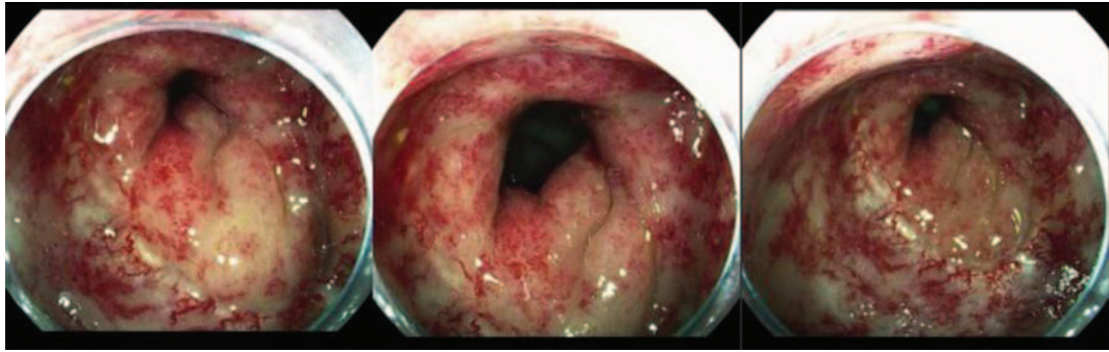


Figure 1. Hyperemia, edema, erosion and chronic ulceration in the intestinal mucosa under endoscopic observation.

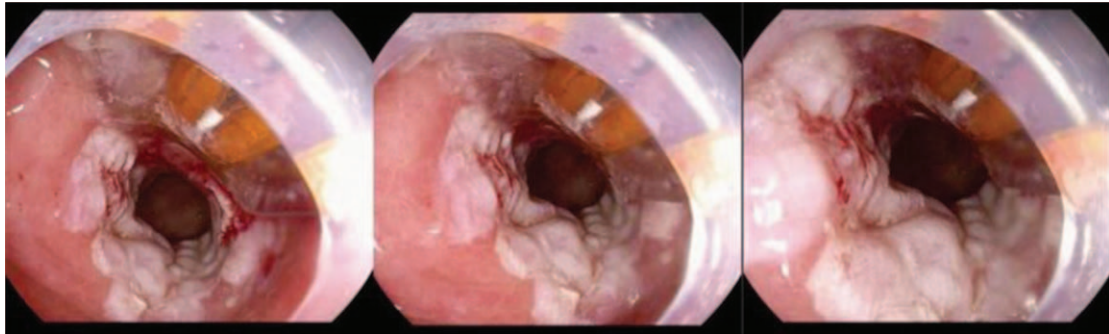


Figure 2. RFA therapy, power 48W 12J/cm², twice radiofrequency ablation for each diseased intestine segment, until all diseased areas were covered. RFA= radiofrequency ablation.

patient received PET-CT examination and a recurrence lesion was found in the rectal anastomotic stoma in August 2016. He was given the radiotherapy with a total dose of 70 Gy in the next 50 days. Unfortunately, the patient complained of persistent abdominal pain (physical examination found that the tenderness of left side of abdomen was obviously), diarrhea and hematochezia in June 2017 and he was diagnosed as the RE by colonoscopy soon. It was a pity that intestinal probiotics, intestinal mucosal protectants, antidiarrheal drugs, and other treatments were not effective. The patient was treated with the RFA (COVIDIEN, Barrx Flex RFA Cart 1190A-115A, The United States) on 4 September 2017. The RFA procedure: lesion size and scope were observed by routine colonoscopy. RFA

electrode (power 48W 12J/cm²) was placed on the lesion for burning in order to cause coagulation and necrosis of the intestinal mucosa. Removing the tissue which was solidified and necrotic and repeating the above procedure again (Fig. 1 and Fig. 2). The clinical symptoms of the patient were gradually decreased after the RFA. A colonoscopy examination was performed 3 months later and the intestinal mucosa was found healed well (Fig. 3). At present, the patient is in follow-up, without obvious gastrointestinal symptoms. This study was approved by the Ethical Committee of Ji'nan Central Hospital Affiliated to Shandong University. Informed written consent was obtained from the patient for publication of this case report and accompanying images.

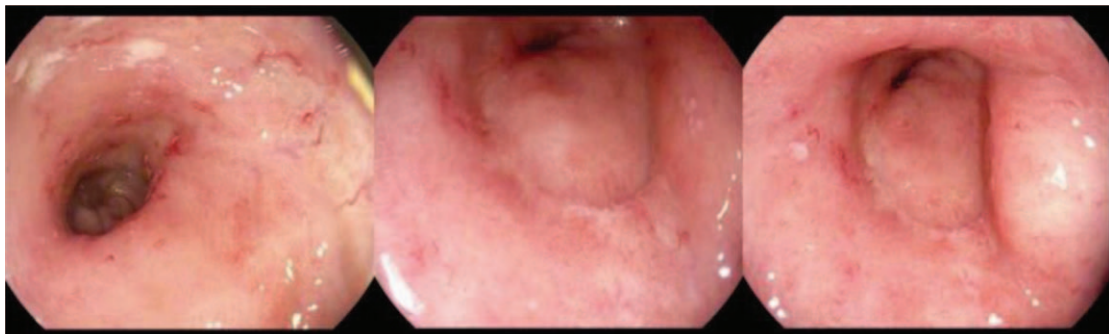


Figure 3. Colonoscopy examination was performed 3 months later and the intestinal mucosa healed well.

3. Discussion

RE is a serious complication caused by short-term exposure to radiotherapy at the abdominal and pelvic levels. The pathological changes of RE are damage of the intestinal mucosa and radiation injury of connective tissue.^[8] Radiation exposed intestinal epithelial cells are generatory and damage the intestinal wall and mucosal epithelial regeneration system.^[9] The speeds of exfoliation and necrosis of epithelial cells are faster than that of crypt cell production, resulting in the villi of the intestinal wall becoming progressively thinner. When damage is aggravated, the intestinal wall may develop some tiny ulcers, which can merge with each other and form many macroscopic ulcerative lesions.^[9] With further aggravation of the lesions, endothelial cells that from the submucosa of the intestinal wall arterioles swelling and deformation, the vascular cavities are then filled with many thrombi and occlusive endovascularitis develops. Meanwhile, collagen deposition and fibrosis lead to the damage of terminal blood vessels of the intestinal wall together with reduction of the capillaries, causing insufficient intestinal blood supply.^[10] In addition, accompanied by telangiectasia, chronic hemorrhage can be found in the intestinal tract. Complications such as refractory ulcers, abdominal infection and abdominal abscess can also be detected.^[11] Scarring and fibrosis results in intestinal stenosis and obstruction. Intestinal fistula can occur in severe cases.

The treatments of RE include internal medicine, hyperbaric oxygen, intestinal nutrition, and traditional Chinese medicine, but their clinical efficacies are not accurate.^[1,4-7,12] At present, the RFA is a well-validated treatment of Barrett's esophagus and chronic erosive gastritis,^[13-15] however, there are no clinical data on the treatment of RE. From this case, we can draw a conclusion that the symptoms of the patient were significantly decreased after RFA therapy, and the intestinal mucosa recovered well. Mechanisms regarding the treatment of RE were not very clear, although the following ways may have been involved. Ischemic and coagulative necrosis of the intestinal mucosal epithelial cells prompted states of dysfunction, edema, or degeneration. The growth of the paligenetic intestinal mucosal epithelial cells was accelerated, alleviating acute or chronic inflammation of the intestinal wall and reducing or eliminating the intestinal fibrosis tissue. This then reduced intestinal hypersensitivity, which was caused by inflammation.

In this case report, some limitations should be considered. First, in this case, long-term follow-up remains necessary. Second, the relatively high cost of the RAF increased the patients' medical costs to some extent.

Of course, RFA therapy in our endoscopy center is still in a preliminary stage. Further research should pay more attention to

prospective and multi-center studies with a larger number of subjects and longer follow-up times.

In conclusion, RFA is an effective treatment for patients with RE, and it is expected to be one of the standard treatments for RE.

Author contributions

Methodology: Jing-yu Zhu.

Writing – original draft: Xing-jie Shen, Jing-yu Zhu.

Writing – review & editing: Liang Liu, Jing-yu Zhu.

Jing-yu Zhu orcid: 0000-0002-1693-7370.

References

- [1] Shadad AK, Sullivan FJ, Martin JD, et al. Gastrointestinal radiation injury: prevention and treatment. *World J Gastroenterol* 2013;19:199–208.
- [2] Qin Q, Huang Q, Zhong Q, et al. Clinical risk factors for late intestinal toxicity after radiotherapy: a systematic review protocol. *Syst Rev* 2013;2:39–44.
- [3] Kalaiselvan R, Theis VS, Dibb M, et al. Radiation enteritis leading to intestinal failure 1994 patient-years of experience in a national referral centre. *Eur J Clin Nutr* 2014;68:166–70.
- [4] Fuccio L, Frazzoni L, Guido A. Prevention of pelvic radiation disease. *World J Gastrointest Pharmacol Ther* 2015;6:1–9.
- [5] Vidal-Casariago A, Calleja-Fernández A, Cano-Rodríguez I. Effects of oral glutamine during abdominal radiotherapy on chronic radiation enteritis: a randomized controlled trial. *Nutrition* 2015;31:200–4.
- [6] Jahraus CD, Bettenhausen D, Malik U, et al. Prevention of acute radiation-induced proctosigmoiditis by balsalazide: randomized, double-blind, placebo controlled trial in prostate cancer patients. *Int J Radiat Oncol Biol Phys* 2015;63:1483–7.
- [7] Tahir AR, Westhuyzen J, Dass J, et al. Hyperbaric oxygen therapy for chronic radiation-induced tissue injuries: Australasia's largest study. *Asia Pac J Clin Oncol* 2015;11:68–77.
- [8] Berthrong M. Pathologic changes secondary to radiation. *World J Surg* 1986;10:155–70.
- [9] Yeoh EK, Horowitz M. Radiation enteritis. *Surg Gynecol Obstet* 1987;165:373–9.
- [10] Mathews R, Rajan N, Josefson L, et al. Hyperbaric oxygen therapy for radiation induced hemorrhagic cystitis. *J Urol* 1999;161:435–7.
- [11] Tas S, Ozkul F, Arik MK, et al. The effect of amifostine on bacterial translocation after radiation induced acute enteritis. *Acta Cir Bras* 2016;31:156–60.
- [12] Zhu L, Wang H. Research progress on the treatment of radiation enteritis with Chinese and Western Medicine. *Asia-Pacific Tradit Med* 2017;13:46–8.
- [13] Carmelo L, Giuseppe I, Leonardo HE, et al. Outcomes of radiofrequency ablation for dysplastic barrett's esophagus: a comprehensive review. *Gastroenterol Res Pract* 2016;2016: Article ID 4249510, 8 pages, <http://dx.doi.org/10.1155/2016/4249510>.
- [14] Sreenarasimhaiah J. Endoscopic applications of cryospray ablation therapy-from barrett's esophagus and beyond. *World J Gastrointest Endosc* 2016;8:546–52.
- [15] Orman ES, Li N, Shaheen NJ. Efficacy and durability of radiofrequency ablation for barrett's esophagus: systematic review and meta-analysis. *Clin Gastroenterol Hepatol* 2013;11:1245–55.