

# Anesthetic management of off-pump simultaneous coronary artery bypass grafting and lobectomy

## Case report and literature review

Xian Zhao, MD<sup>a</sup>, Yuhong Li, MD, PhD<sup>b,\*</sup>, Hai-Ying Kong, MD, PhD<sup>c</sup>, Lin Zhang, PhD<sup>b</sup>, Xiao-Hong Wen, MD<sup>c</sup>

### Abstract

**Rationale:** Survey data show approximately 10% patients with lung cancer may present concomitant coronary heart disease. Simultaneous surgery is a challenge for anesthetist. We review our experience in the anesthesia with 5 patients who required simultaneous off-pump coronary artery bypass grafting (OPCABG) and pulmonary resection for lung cancer.

**Patient concerns:** Between 2014 and 2016, 5 patients with ASA (American Society of Anesthesiologists) grade II or III, underwent combined OPCABG and lung resection in the first Affiliated Hospital, Zhejiang University School of Medicine.

**Diagnoses:** All five patients were diagnosed with coronary heart disease and peripheral pulmonary carcinoma

**Interventions:** Five patients received general anesthesia with double-lumen endobronchial tube for lung separation. The anesthetics were used, which caused slight hemodynamic fluctuations during induction of anesthesia; while during the maintenance of anesthesia, supplemented by Dexmedetomidine, the drug doses were titrated according to the depth of anesthesia. Guided by cardiac index (CI), stroke volume variation (SV) and oxygen delivery (DO<sub>2</sub>), different strategies were taken at the different stage of surgery, during lung resection, SVV was kept about 13% to 15%, and less than 10% during OPCABG.

**Outcomes:** Five patients were transferred to intensive care unit (ICU) with intubation after surgery, duration of ventilation was 10 to 18 hours, and length of ICU stay and hospital stay were 1.8 to 2.5 ds and 11 to 16 ds, respectively. All of patients were discharged with not any perioperative complication.

**Lessons:** In summary, anesthetists should focus on the maintenance of the balance between oxygen supply and demanding, which was achieved by close monitoring, titration of anesthetics and goal-directed fluid therapy during surgical procedures.

**Abbreviations:** ABG = arterial blood gas, ACT = activate-clotting-time, ASA = American Society of Anesthesiologists, BIS = bispectral index, bmp = beat per minute, CHD = coronary heart disease, CI = cardiac index, CO = cardiac output, CRBC = concentrated red blood cells, CT = computerized tomography, CVP = central venous pressure, DO<sub>2</sub> = oxygen delivery, DO<sub>2</sub>I = oxygen delivery index, dPV = difference of peak velocity, ECG = electrocardiogram, EtCO<sub>2</sub> = end-tidal CO<sub>2</sub>, FGF = fresh gas flow, FiO<sub>2</sub> = inspired O<sub>2</sub> fraction, GDT = goal directed therapy, ICU = intensive care unit, IMA = left internal mammary artery, LAD = left anterior descending artery, NYHA = New York Heart Association, OLV = one lung ventilation, OPCABG = off-pump coronary artery bypass grafting, PEEP = positive end-expiratory pressure, PET = positron emission tomography, PO<sub>2</sub> = oxygen partial pressure, REPE = re-expansion pulmonary edema, RL = Ringer's lactate solution, RVEDV = right ventricular end-diastolic volume, ScVO<sub>2</sub> = saturation central venous oximetry, SICU = surgical intensive care unit, SpO<sub>2</sub> = pulse oxygen saturation, SV = saphenous vein, SVI = stroke volume index, SVRI = systemic vascular resistance index, SVV = stroke volume variation, TEE = transesophageal echocardiography, TNM = TNM Classification of Malignant Tumors, UO = urine output, VATS = video-assisted throacosopic surgery.

**Keywords:** anesthesia, GDT, lung resection, OLV, OPCABG

### 1. Introduction

Lung cancer and coronary heart diseases (CHD) are among most common diseases in the elderly people in China.<sup>[1,2]</sup> With the

population aging, patients with CHD have an increasing incidence of lung cancers.<sup>[1,2]</sup> The abroad survey data shows, approximately 10% patients with lung cancer may present

Editor: Helen Gharaei.

Y-HL: Equal contributing first author

Funding: This research was supported by Natural Science Foundation of Zhejiang Province (CN) (LY15H030013, LY14H300002) and Zhejiang Public Welfare Technology Application Research Project (2015C33285)

The authors have no conflicts of interest to disclose.

<sup>a</sup> Department of Anesthesiology, Zhejiang University International Hospital, Hangzhou, <sup>b</sup> Department of Anesthesiology and Medical Research Center, Shaoxing People's Hospital, Shaoxing, <sup>c</sup> Department of Anesthesiology, the First Affiliated Hospital, Zhejiang University School of Medicine, Hangzhou, China.

\* Correspondence: Yuhong Li, Department of Anesthesiology and Medical Research Center, Shaoxing People's Hospital, Shaoxing, Zhejiang, China (e-mail: yuh\_lj@qq.com)

Copyright © 2017 the Author(s). Published by Wolters Kluwer Health, Inc.

This is an open access article distributed under the terms of the Creative Commons Attribution-Non Commercial License 4.0 (CCBY-NC), where it is permissible to download, share, remix, transform, and buildup the work provided it is properly cited. The work cannot be used commercially without permission from the journal.

Medicine (2017) 96:50(e8780)

Received: 16 April 2017 / Received in final form: 26 October 2017 / Accepted: 27 October 2017

<http://dx.doi.org/10.1097/MD.00000000000008780>

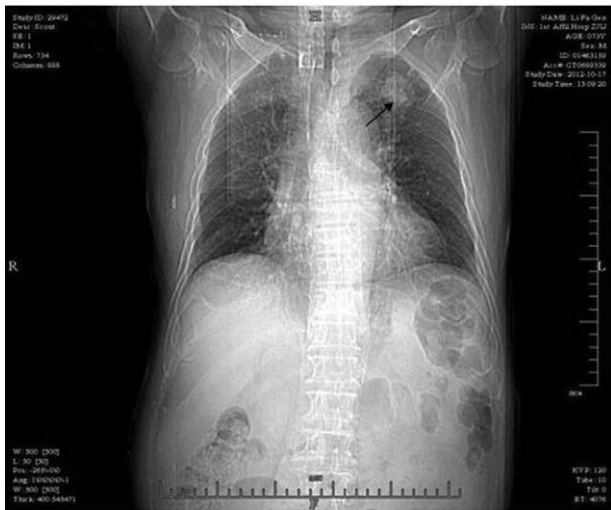

Figure 1. Chest x-ray demonstrates a neoplasm at the left lung.

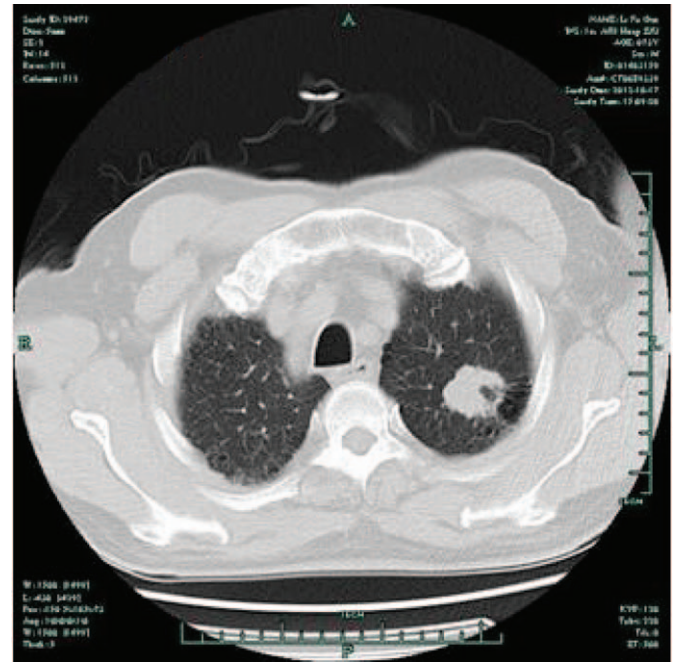


Figure 2. Computed tomography demonstrates a lesion at the right lung.

concomitant CHD.<sup>[3]</sup> Although there is no relevant epidemiological data in China, it was reported that, there were about 23% of 1023 patients with lung cancer associated with CHD.<sup>[4]</sup> It is a challenge for thoracic surgeons to treat such patients with lung cancers and concurrent severe CHD because of pulmonary resection done without myocardial revascularization, patients will probably be at cardiac risk, otherwise, patients will be facing delay in lung cancer treatment. In recent decades, thoracic surgeons have made great progress in the performing the both of these procedures during a single operation.<sup>[5–7]</sup> Simultaneous surgery is another challenge for the anesthetist. For example, one lung ventilation (OLV), required promoting surgical access of lobectomy, may disturb the myocardial oxygen supply and demand balance,<sup>[1,2,8,9]</sup> in particular, patients will be doomed to face more risks in the condition of lobectomy done under OLV before coronary revascularization. Perioperative fluid therapy is another challenging;<sup>[7]</sup> restrictive fluid strategy is helpful to reduce the occurrence of re-expansion pulmonary edema (REPE), postoperative hypoxemia, and lung injury, but is not conducive to the hemodynamic stability during the coronary artery bypass grafting (CABG).<sup>[10–12]</sup> Thus, anesthesia management for the patients with lung cancer undergoing concomitant off-pump CABG (OPCABG) and pulmonary resection is rather more complicated. We report our anesthesia experiences with 5 patients who required simultaneous OPCABG and pulmonary resection for lung cancer.

## 2. Clinical data

Between year of 2014 and 2016, 5 patients underwent selective simultaneous OPCABG and lobectomy under general anesthesia in the First Affiliated Hospital, Medicine School, Zhejiang University. Patients with diagnosis of severe CHD through angiography and resectable lung cancer were recruited in this case report study, which was conducted after obtaining the protocol from the Ethics Committee of the First Affiliated Hospital, Medicine School, Zhejiang University (Hangzhou, PR of China, No. 2014150, Official in charge: Zhangfei Shou) and written informed consent from patients or their family member.

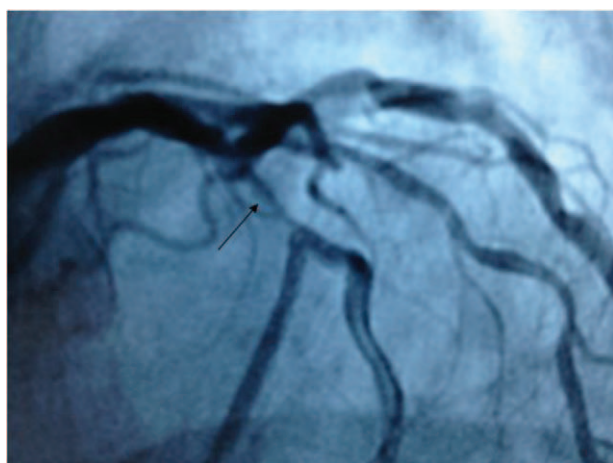
### 2.1. Patients demographics

A total 4 males and 1 female were included in this case report study. Mean age was  $67 \pm 5$  years (range, 68–78 years). All five patients were admitted to our service with first symptom of pulmonary disease. All procedures were conducted according to the standard of diagnosis and treatment. Comprehensive analysis of physical examination and laboratory test showed all patients had hypertension, and 4 had diabetes. Chest computerized tomography (CT) showed that 2 patients in the left upper lobe (Fig. 1), 3 patients had lesions in the right upper (Fig. 2) and middle lobes, and pulmonary cancer was confirmed based on biopsy pathology through fiberoptic bronchoscopy; while clinical lung cancer staging was based on pathologic findings, chest CT, or results of positron emission tomography (PET), and all patients in the present study were in stage I or stage II by using TNM Classification of Malignant Tumors (TNM) staging system in accordance with the New International System for Staging Lung Cancer. Pulmonary function tests showed that forced expiratory volume in 1 second was within normal range for all patients.

The 12-lead electrocardiogram (ECG) reflected inferior infarct with anterolateral ST-T changes in three patients. Coronary angiography showed that three patients had three vessels diseases, and four patients had proximal lesions in the left anterior descending artery (70%, 90%, 75%, and 85%, respectively) as well as three patients had lesions in the first obtuse marginal artery (95%, 80%, and 90%, respectively) (Fig. 3) with class I cardiac function for two patients, and class II for three patients (New York Heart Association, NYHA). Transthoracic echocardiography revealed the normal left ventricular size with grade I diastolic dysfunction and normal regional wall motions and no valvular abnormalities in all patients. A summary of the preoperative clinical data was presented in Table 1.

### 2.2. Procedure

All patients fasted overnight, and received diazepam 5 mg orally and morphine 0.1 mg/kg, 30 minutes before entering operation



**Figure 3.** Cardiac catheterization demonstrates 90% stenosis of the left coronary artery.

theater. After patients entered the operation theater, catheterization of the left radial artery for the measurement of arterial blood pressure, left median cubital vein for infusion of fluid or drugs, and introducer catheters were placed for monitoring central venous pressure (CVP) and PreSep (Edwards Lifescience, Irvine, CA) oximetry catheter was inserted for monitoring saturation central venous oximetry (ScVO<sub>2</sub>) through the right internal jugular vein under local anesthesia and mask oxygen-inspiration (2–4 L/min). Cardiac output (CO), stroke volume index (SVI), cardiac index (CI), stroke volume variation (SVV), systemic vascular resistance index (SVRI), and oxygen delivery index (DO<sub>2</sub>I) were monitored using FloTrac/Vigileo set (Edwards Lifescience, Irvine, CA). Three-dimensional transesophageal echocardiographic (TEE) probe (Philips IE Elite, Netherland) was placed after the induction of anesthesia for monitoring of cardiac activity and guiding fluid therapy combined with FloTrac/Vigileo. ECG, pulse oxygen saturation (SpO<sub>2</sub>), invasive blood pressure, CVP and arterial blood gas (ABG), urine output, end-tidal CO<sub>2</sub> (EtCO<sub>2</sub>), and body temperature were monitored during surgery. In addition, bispectral index (BIS) was recorded for depth of anesthesia by BIS monitor Model A-2000TM (Aspect Medical Systems, Natick, MA).

Defibrillator was ready, and heart rate (HR) and mean blood pressure (MAP) was maintained within in normal range of 50 to 80 beat per minute (bpm) and 90 to 105 mm Hg, respectively, before general anesthesia was induced with intravenous

midazolam (5 mg), fentanyl (550 µg), and vecuronium (8 mg). Double-lumen endobronchial tube (Broncho-Cath 35–39 Charrieré; Mallinckrodt Medical Ltd, Athlone, Ireland) were placed and confirmed by fiberoptic bronchoscopy (bronchoscope BF-3C40; OD, 2.8 mm; Olympus Europe, Hamburg, Germany). All patients were ventilated via the circuit of the Zeus (Dräger, Lübeck, Germany) anesthesia workstation with the tidal volume of 6 mL/kg, positive end-expiratory pressure (PEEP) of 5 cm H<sub>2</sub>O, and respiratory frequency of 12 breaths/min or adjusted to maintain EtCO<sub>2</sub> at 35 to 45 mm Hg. The inspiratory–expiratory ratio was 1:2 with peak inspiratory pressure limitation of 30 cmH<sub>2</sub>O. The inspired O<sub>2</sub> fraction (FiO<sub>2</sub>) was set at 0.4 to 0.5 before OLV, and 0.6 to 0.7 during OLV, to maintain SpO<sub>2</sub> more than 95%. The anesthesia was maintained with fentanyl (0.02 mg/kg/h), midazolam (0.04 mg/kg/h), sevoflurane (0.8%–1.5%), dexmedetomidine (0.3–0.5 µg/kg/h), and vecuronium included intermittently as needed. BIS values were adjusted at 40 to 60 to ensure the proper depth of anesthesia. Intraoperative HR and MAP were maintained within in normal range of 50 to 75 beat per minute (bpm) and 90 to 105 mm Hg, respectively, according to our local policy. HR was controlled within the range through atropine or esmolol; while MAP through nitroglycerin, or phenylephrine/epinephrine.

Combination of cardiac and thoracic surgery was performed with myocardial revascularization carried out first for all patients. After patients were placed on the supine position, surgical procedure was performed through median sternotomy and Octopus device (Medtronic, Inc., Minneapolis, MN) was used for cardiac stabilization. Systemic anticoagulation was achieved with heparin 2 mg/kg. Left internal mammary artery (IMA) was anastomosed with the left anterior descending artery (LAD), and saphenous vein (SV) grafts were grafted to other coronary arteries. After OPCABG, protamine was used as reversal of heparin, maintaining activate-clotting-time (ACT) within 1.2 times of baseline values. Then, radical lung resection and dissection of the lymphnodes for 3 patients, palliative lung segment resection for the 2 elderly patients was performed via opening the affected side pleura. Double-lumen endobronchial tube was replaced by single lumen tracheal tube after surgery, thereafter; all patients were shifted to surgical intensive care unit (SICU) on full mechanical ventilation support.

### 2.3. Goal-directed fluid therapy

Considering the characteristics of the hemodynamic fluctuations during OPCABG procedure, the goal of fluid is to optimize myocardial oxygen demand-supply balance basing on maintaining hemodynamic ranges: CI, 2.5 to 4.2 L/min/m<sup>2</sup>; SVI, 30 to 65

**Table 1**  
**Preoperative clinical data.**

Patients no.	Case 1	Case 2	Case 3	Case 4	Case 5
Age	67	54	70	65	71
Sex	Female	Male	Male	Male	Male
Height	150	168	170	169	171
Body weight	42.5	75	70	65	67
CT <sub>n</sub> I	0.486	0.272	1.574	0.012	0.429
Pro-BNP	549	427	265	564	127
Coronary angiography (stenosis more than 70%)	Two vessels	Three vessels	Two vessels	Three vessels	Three vessels
Lung cancer clinical stage	IA	IIA	IB	IIB	IIA
Comorbidities	Hypertension COPD Diabetes mellitus	Hypertension Diabetes mellitus	Hypertension COPD	Hypertension Diabetes mellitus	Hypertension Diabetes mellitus

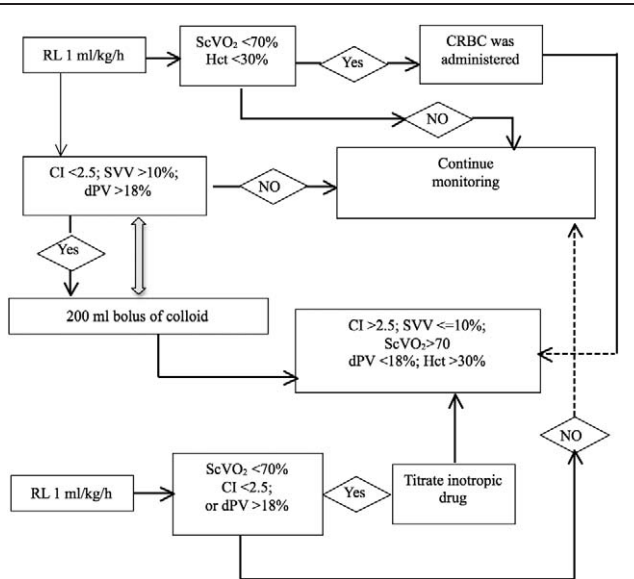


Figure 4. The flowchart protocol for goal-directed fluid therapy.

mL/m<sup>2</sup>; difference of peak velocity (dPV), <18%; SVV, <10%; ScVO<sub>2</sub>, >70%; systemic vascular resistance index (SVRI), 1500 to 2500 dynes/cm<sup>5</sup>/m<sup>2</sup>; oxygen delivery index (DO<sub>2</sub>I), 450 to 600 mL/min/m<sup>2</sup>; in addition to the goals in standard care such as CVP at 6 to 8 mm Hg; MAP at 90 to 105 mm Hg, HR 50 to 70 beat/min, ABG analysis values (pH 7.35–7.45, PaO<sub>2</sub> >100 mm Hg, and PaCO<sub>2</sub> 35–45 mm Hg), SpO<sub>2</sub> >95%, hematocrit >30%, and urine output >1 mL/kg/h.

All patients received maintenance of Ringer’s lactate solution 1 mL/kg/h, if the CI was less than 2.5 L/min/m<sup>2</sup>, SVV more than 10%, or dPV more than 18%, 200 mL bolus dose of colloid were given, which was repeated in frequent intervals till the target CI, SVV and levels were achieved. With continuous low ScVO<sub>2</sub> (<70%) along with low dPV (<18%) or CI (<2.5 L/min/m<sup>2</sup>), it was the time to initiate the inotropic support of dobutamine with starting from 5 μg/kg/min or epinephrine with starting dose of 0.05 μg/kg/min or milrinone, vassopressor and

Table 2

Intraoperative hemodynamic parameters.

Patients no	Case 1	Case 2	Case 3	Case 4	Case 5
MAP/HR					
T <sub>0</sub>	120/55	105/90	99/81	106/60	120/71
T <sub>1</sub>	105/60	90/80	98/75	87/62	87/65
T <sub>2</sub>	105/70	110/75	103/78	100/80	90/61
T <sub>3</sub>	116/60	108/70	106/76	109/60	109/60
T <sub>4</sub>	100/61	100/65	96/65	95/61	99/59
T <sub>5</sub>	100/60	105/70	104/71	97/63	108/64
CI/CVP					
T <sub>0</sub>	3.5/7	3.0/8	3.6/7	4.2/8	3.9/7
T <sub>1</sub>	2.6/6	2.9/9	2.9/7	3.0/7	2.9/7
T <sub>2</sub>	2.7/7	2.9/10	3.0/7	3.0/7	3.0/9
T <sub>3</sub>	2.9/6	2.8/7	3.0/8	3.1/6	2.9/7
T <sub>4</sub>	2.7/7	3.0/9	2.7/6	2.9/6	2.8/7
T <sub>5</sub>	2.9/8	3.1/7	3.0/7	3.0/7	2.9/8

T<sub>0</sub> (Baseline), T<sub>1</sub> (before tracheal intubation), T<sub>2</sub> (after tracheal intubation), T<sub>3</sub> (open chest), T<sub>4</sub> (end of CABG), T<sub>5</sub> (sternal closure).

CI=cardiac index, CVP = central venous pressure, HR=heart rate, MAP = mean arterial pressure.

so on; while the maintaining dose of such inotropic support was titrated to maintain CI within 2.0 to 4.2 L/min/m<sup>2</sup>. If ScVO<sub>2</sub> was less than 70%, along with low Hct (<30%), concentrated red blood cells (CRBC) was administered to maintain Hct within the normal range (Fig. 4). We titrated the dose balance between the inotropic agents, vasodilators, and dexmedetomidine on the basis of maintaining the parameters such as right ventricular end-diastolic volume (RVEDV) within the target values. During the pulmonary lung resection, we adopted the restricted fluid therapy; the key difference was the SVV was kept in the ranges of 13% to 15% according to our experience and local policy.

2.4. Postoperative follow-up

Patients had scheduled follow-up visits twice daily before extubation; once a day for the first-week in SICU; then once a week till discharge.

All parameters associated to patients’ characteristic, hemodynamics and post-operative outcome were displayed in raw data.

3. Results

Pathological diagnosis of pulmonary was adenocarcinoma in 3 cases; squamous cell carcinoma in 2, pTNM stage was IA in 1 cases, IIA in 2, IB in 1 and IIB in 1 (Table 1). The intraoperative hemodynamic parameters were displayed in Table 2; while the amount of fluid infusion, blood loss and urine output during the surgery were shown in Table 3. Table 4 presented the outcomes for five patients during and after anesthesia. There were two patients developed atrial fibrillation, and another two patients developed transient lower cardiac output, which improved after symptomatic treatment. There was no accident related to anesthesia happened for all the patients during the operation and there was no patients died, no serious respiration and circulation relative complications, or new incidences of myocardial infarction occurred after surgery during hospital stay.

Table 3

The amount of fluid infusion, blood loss and urine output during operation.

Patients No	Case 1	Case 2	Case 3	Case 4	Case 5
Total fluid, mL	3900	4500	4700	3500	4300
Crystalloid, mL	2600	3140	3650	2160	2900
Artificial colloid, mL	500	600	500	500	500
CRBC, mL	400	300	300	400	400
Plasma, mL	400	460	440	440	500
Blood loss, mL	650	670	340	340	540
Urine output, mL	2500	3000	2400	2400	2600

CRBC=concentrated red blood cells.

Table 4

The outcome for all patients during and after anesthesia.

Patients no.	Case 1	Case 2	Case 3	Case 4	Case 5
Operation time, min	350	400	230	300	270
Duration of ventilation, h	15	18	10	13	15
Duration inotrope usage, ds	1.5	1.4	1	1.4	1.7
Length of ICU stay, ds	2.3	2.5	1.8	1.9	2.1
Length of hospital, ds	11	16	13	13	14

#### 4. Discussion

For patients with lung cancer and concurrent CHD, surgery procedure is the best treatment. There are typically three surgical procedures available according to which problem will be solved first: OPCABG followed by or before lung resection (two-stage operation); simultaneous OPCABG and lung resection (one-stage operation). With OPCABG before lung cancer surgery, patients should receive antiplatelet therapy or anticoagulation therapy for one month to one year.<sup>[13]</sup> They will face the risk between severe hemorrhage and missing the optimal timing of surgery.

With OPCABG after lung resection, patients with CHD who will receive non-cardiac surgery are high risk of perioperative major adverse cardiac events. Patients will more likely develop peri-operative hypoxemia,<sup>[14]</sup> various types of arrhythmia,<sup>[15]</sup> even cardiac arrest,<sup>[16]</sup> which may lead to lethal myocardial infarction. Perioperative myocardial ischemia has identified as a major predictor of cardiac complications,<sup>[17]</sup> which can lead to high morbidity and mortality.<sup>[18]</sup>

The one-stage operation can beside obviously avoid the above disadvantages; it has also included following advantages: one incision and one anesthesia with shorter overall hospital stay and less cost of medical care. Previous references showed that it could reduce the risk of postoperative complications.<sup>[19–22]</sup> Surgical procedures can be performed either through left lateral thoracotomy or median sternotomy, or both.<sup>[19,20]</sup> Our surgical team chose the median sternotomy as a preferable approach in the present study,<sup>[22]</sup> which reduced duration of OLV, thus can reduce the postoperative respiratory complication compared with the left lateral thoracotomy. Poor exposure is of the major defects of this surgical route, which might be easier with assistance of thoracoscope and video-assisted throacoscopic surgery (VATS).<sup>[22]</sup>

It is known that it is key important to maintain the balance between oxygen supply and demanding for all patients with coronary artery diseases under surgery. During the intraoperative period, various factors can aggravate the burden on the cardiovascular system and influence oxygen supply and oxygen demand, such as stimulation of the sympathetic nervous system by surgery, use of anesthetics, endotracheal intubation and major blood loss. In addition, various anesthetics cause vasodilation and depression of cardiac muscle, which may result in decreased cardiac output and cardiac decompensation. Therefore, the main goal of anesthesia management during simultaneous OPCABG and lung resection was to ensure the oxygen supply–demand balance.

In order to alleviate myocardial ischemia and to avoid perioperative myocardial infarction during simultaneous operation, it has been recommended that OPCABG perform before lung surgery.<sup>[23]</sup> Poor exposure from the block of heart along with coronary bypass grafts increased the difficulty of pneumonectomy, especially for the performance on the upper left lung surgery. From the point of anesthesia, our experience showed that OLV might improve the surgical exposure. Double-lumen endobronchial tubes were used for all of patients and facilitated by fibrotic bronchoscopy, which can ensure ideal lung isolation, reduce the blind adjustment, and thus enhance the safety of OLV.<sup>[24]</sup> During OLV, hypoxemia was reported to occur, increasing the incidence of perioperative MI as well as affecting postoperative outcomes.<sup>[25]</sup> Thus, prevention and treatment of hypoxemia associated with OLV is a priority for anesthetists. Ng and Swanevelde<sup>[26]</sup> suggested that hypoxemia be attenuated by manipulation of ventilation and perfusion independently. Appropriate alveolar recruitment, PEEP, and avoidance of high

tidal volumes were used. TEE was also used to monitor intravascular fluid status and myocardial function. The afterload to the right ventricle increased due to lung collapse during OLV, and the right ventricle might need a higher end diastolic volume for maintaining the cardiac output variables. Furthermore, sevoflurane was used as the main anesthetic agent. Volatile anesthetics have dose-dependent inhibitory effects on the inflammatory process during OLV and are preferred to total intravenous anesthesia.<sup>[27]</sup>

As for the choice of the anesthesia for this one-stage operation, many clinical studies showed that general anesthesia combined thoracic epidural could provide superior postoperative complete pain relief allowing inspiration and coughing without the risk of respiratory depression.<sup>[28,29]</sup> But another study suggested thoracic epidural anesthesia be cautiously used as that may exit underlying risks in low systemic hemodynamics, decreased oxygen partial pressure (PO<sub>2</sub>) but increases pulmonary shunt during one-lung ventilation; while increased the risk of postoperative bleeding for the combination surgery,<sup>[30]</sup> thus general anesthesia was chosen for all five patients in this study. Special attention should be focus on the reduction of hemodynamic fluctuations during both induction and maintenance of anesthesia, which was archived by the anesthetics selection and titration delivery.<sup>[31]</sup> In the present study, midazolam (5 mg), fentanyl (550 μg), and vecuronium were administered after rather stable hemodynamics titrated by nitroglycerin. Afterword, anesthesia was maintained by fentanyl, midazolam and sevoflurane; small dosing dexmedetomidine was given based on the protocol and our experiences. Previous study showed that dexmedetomidine reduced post-surgical myocardial injury in patients who had undergone OPCABG.<sup>[32–34]</sup>

Maintaining the stable hemodynamic state may ensure the oxygen supply-demand balance and promote the operation security. Stable hemodynamic state can be guaranteed not only by careful surgical manipulation during operation,<sup>[20]</sup> but above-mentioned anesthetic techniques as well.<sup>[30]</sup> Additionally, fluid therapy technique has been considered to play an important role for maintaining hemodynamic stability.<sup>[35,36]</sup> The key issue is the fluid strategies facing contradict between the surgical procedure of OPCABG, depending volume for maintenance of hemodynamics, and lung resection, preferring the restrictive fluid for prevention of reexpansion pulmonary edema. How to reconcile the contradictions was a huge challenge for thoracic anesthetists. Many reports supported goal-directed therapy (GDT) for both of OPCABG and lung surgery to guide intravenous fluid and inotropic therapy by using CO or similar parameters. It involves goal-directed manipulation of cardiac preload, afterload, and contractility to achieve a balance between systemic oxygen demand and delivery.<sup>[35–37]</sup> In this study, the GDT strategy was based on our experience or with reference to the related literatures<sup>[38,39]</sup> SVV was set 10% during OPCABG, while 13% to 15% during lung surgery. In order to prevent the respiratory complication, relative restricted strategy was always under consideration; fluid loading dose and titration-up of vascular active drug was given at the same time during lung surgery. Result showed that there was no patients have respiratory-related or renal related post-operative complication.

In summary, combined OPCABG and lung resection could be performed safely for five patients. OLV is necessary for surgical performance, which make the anesthesia more complicated and more challenging. From our knowledge and experiences, the key point to perform anesthesia for combined OPCABG and lung resection was to maintain the balance between oxygen supply and

demanding, achieving from good monitoring, anesthetics choice, titration of anesthesia depth, GDT, and continuous small dose of dexmedetomidine.

## References

- [1] Jiang G, Wang D, Li W, et al. Coronary heart disease mortality in China: age, gender, and urban-rural gaps during epidemiological transition. *Rev Panam Salud Publica* 2012;31:317–24.
- [2] Chen PC, Muo CH, Lee YT, et al. Lung cancer and incidence of stroke: a population-based cohort study. *Stroke* 2011;42:3034–9.
- [3] Ciriaco P, Carretta A, Calori G, et al. Lung resection for cancer in patients with coronary arterial disease: analysis of short-term results. *Eur J Cardiothorac Surg* 2002;22:35–40.
- [4] Han SL, Zhang S. The correlation study between lung cancer and coronary heart disease. *Lin Chuang Fei Ai Zha Zhi* 2012;17:934–5. (in Chinese).
- [5] Tourmousoglou CE, Apostolakis E, Dougenis D. Simultaneous occurrence of coronary artery disease and lung cancer: what is the best surgical treatment strategy? *Interact Cardiovasc Thorac Surg* 2014;19:673–81.
- [6] Yang Y, Xiao F, Wang J, et al. Simultaneous surgery in patients with both cardiac and noncardiac diseases. *Patient Prefer Adherence* 2016; 10:1251–8.
- [7] Ma X, Huang F, Zhang Z, et al. Lung cancer resection with concurrent off-pump coronary artery bypasses: safety and efficiency. *J Thorac Dis* 2016;8:2038–45.
- [8] Ren M, Zhang WP, Zhu SM. Effects of inverse ratio ventilation combined with PEEP on pulmonary function and inflammatory cytokine levels in patients undergoing pulmonary lobectomy during one-lung ventilation. *Zhejiang Yi Xue* 2017;39:200–4. (in Chinese).
- [9] Pinheirode Oliveira R, Hetzel MP, dos Anjos Silva M, et al. Mechanical ventilation with high tidal volume induces inflammation in patients without lung disease. *Crit Care Med* 2010;14:R39.
- [10] Li YH, Zhao L, Wang TL. Clinical research of goal directed fluid management in geriatric patients undergoing thoracic surgery. *Yi Xue Yan Jiu Za Zhi* 2013;9:92–6.
- [11] Pipanmekaporn T, Punjasawadwong Y, Charuluxananan S, et al. Association of positive fluid balance and cardiovascular complications after thoracotomy for noncancer lesions. *Risk Manag Healthc Policy* 2014;7:121–9.
- [12] Kapoor PM, Magoon R, Rawat RS, et al. Goal-directed therapy improves the outcome of high-risk cardiac patients undergoing off-pump coronary artery bypass. *Ann Card Anaesth* 2017;20:83–9.
- [13] Fleisher LA, Fleischmann KE, Brown KA, et al. 2009 ACCF/AHA focused update on perioperative beta blockade incorporated into the ACC/AHA 2007 guidelines on perioperative cardiovascular evaluation and care for noncardiac surgery. *J Am Coll Cardiol* 2009;54:e13–118.
- [14] Wu DH, Xu MY. The right double-lumen on the airway management for pneumonectomy patients: a retrospective analysis of 2504 lung operations. *Shanghai Yixue* 2010;33:590–2.
- [15] Wu DH, Xu MY, Mao T, et al. Risk factors for intraoperative atrial fibrillation: a retrospective analysis of 10 563 lung operations in a single center. *Ann Thorac Surg* 2012;94:193–7.
- [16] Xu MY, Zhang XF, Shen YF, et al. A retrospective analysis of 16 perianesthesia cardiac arrest cases among 12832 thoracic surgery patients. *Shanghai Yixue* 2010;33:342–5. (in Chinese).
- [17] Mangano DT, Browner WS, Hollenberg M, et al. Association of perioperative myocardial ischemia with cardiac morbidity and mortality in men undergoing no cardiac surgery. The Study of Perioperative Ischemia Research Group. *N Engl J Med* 1990;323:1781–8.
- [18] Mangano DT. Perioperative cardiac morbidity. *Anesthesiology* 1990; 72: 153–184. Mangano DT, Goldman L. Preoperative assessment of patients with known or suspected coronary disease. *The New England Journal of Medicine* 1995; 333: 1750–1756.
- [19] Ahmed AA, Sarsam MA. Off-pump combined coronary artery bypass grafting and left upper lobectomy through left posterolateral thoracotomy. *Ann Thorac Surg* 2001;71:2016–8.
- [20] Saxena P, Tam RK. Combined off-pump coronary artery bypass surgery and pulmonary resection. *Ann Thorac Surg* 2004;78:498–501.
- [21] Hensens AG, Zeebregts CJ, Liem TH, et al. Concomitant coronary artery revascularization and right pneumonectomy without cardiopulmonary bypass. *J Cardiovasc Surg (Torino)* 1999;40:161–3.
- [22] Mitropoulos F, Kanakis MA, Apostolou A, et al. T-bar utilization for concomitant coronary artery bypass graft operation and left upper lobectomy. *Case Rep Surg* 2016;2016:8760849.
- [23] Danton MH, Anikin VA, McManus KG, et al. Simultaneous cardiac surgery with pulmonary resection: presentation of series and review of literature. *Eur J Cardiothorac Surg* 1998;13:667–72.
- [24] Pennefather SH, Russell GN. Placement of double lumen tubes—time to shed light on an old problem. *Br J Anaesth* 2000;84:308–10.
- [25] Kazan R, Bracco D, Hemmerling TM. Reduced cerebral oxygen saturation measured by absolute cerebral oximetry during thoracic surgery correlates with postoperative complications. *Br J Anaesth* 2009;103:811–6.
- [26] Ng A, Swanevelder J. Hypoxaemia associated with one-lung anaesthesia: new discoveries in ventilation and perfusion. *Br J Anaesth* 2011; 106:761–3.
- [27] Espinoza A, Bergsland J, Lundblad R, et al. Wide sternal retraction may impede internal mammary artery graft flow and reduce myocardial function during off-pump coronary artery bypass grafting: presentation of two cases. *Interact Cardiovasc Thorac Surg* 2012;15:42–4.
- [28] Behera BK, Puri GD, Ghai B. Patient-controlled epidural analgesia with fentanyl and bupivacaine provides better analgesia than intravenous morphine patient-controlled analgesia for early thoracotomy pain. *J Postgrad Med* 2008;54:86–90.
- [29] Hashemzadeh S, Hashemzadeh K, Hosseinzadeh H, et al. Comparison thoracic epidural and intercostal block to improve ventilation parameters and reduce pain in patients with multiple rib fractures. *J Cardiovasc Thorac Res* 2011;3:87–91.
- [30] Li XQ, Tan WF, Wang J, et al. The effects of thoracic epidural analgesia on oxygenation and pulmonary shunt fraction during one-lung ventilation: a meta-analysis. *BMC Anesthesiol* 2015;15:166.
- [31] Maddali MM, Al-Jadidi AM, Zacharias S. Novel anaesthetic approach for surgical access and haemodynamic management during off-pump coronary artery bypass through a left thoracotomy. *Indian J Anaesth* 2012;56:75–8.
- [32] Chi X, Liao M, Chen X, et al. Dexmedetomidine attenuates myocardial injury in off-pump coronary artery bypass graft surgery. *J Cardiothorac Vasc Anesth* 2016;30:44–50.
- [33] Ren J, Zhang H, Huang L, et al. Protective effect of dexmedetomidine in coronary artery bypass grafting surgery. *Exp Ther Med* 2013; 6:497–502.
- [34] Ammar AS, Mahmoud KM, Kasemy ZA, et al. Cardiac and renal protective effects of dexmedetomidine in cardiac surgeries: a randomized controlled trial. *Saudi J Anaesth* 2016;10:395–401.
- [35] Zhang J, Chen CQ, Lei XZ, et al. Goal-directed fluid optimization based on stroke volume variation and cardiac index during one-lung ventilation in patients undergoing thoracoscopy lobectomy operations: a pilot study. *Clinics (Sao Paulo)* 2013;68:1065–70.
- [36] Diaper J, Ellenberger C, Villiger Y, et al. Transoesophageal Doppler monitoring for fluid and hemodynamic treatment during lung surgery. *J Clin Monit Comput* 2008;22:367–74.
- [37] Li P, Qu LP, Qi D, et al. Significance of perioperative goal-directed hemodynamic approach in preventing postoperative complications in patients after cardiac surgery: a meta-analysis and systematic review. *Ann Med* 2017;2:1–9.
- [38] Romagnoli S, Rizza A, Ricci Z. Fluid status assessment and management during the perioperative phase in adult cardiac surgery patients. *J Cardiothorac Vasc Anesth* 2016;30:1076–84.
- [39] Osawa EA, Rhodes A, Landoni G, et al. Effect of perioperative goal-directed hemodynamic resuscitation therapy on outcomes following cardiac surgery: a randomized clinical trial and systematic review. *Crit Care Med* 2016;44:724–33.