



OPEN ACCESS

EXTENDED REPORT

Efficient therapy of ischaemic lesions with VEGF₁₂₁-fibrin in an animal model of systemic sclerosisShadab Allipour Birgani,¹ Marion Mailänder,¹ Ines Wasle,¹ Hermann Dietrich,² Johann Gruber,³ Oliver Distler,⁴ Roswitha Sgonc¹**Handling editor** Tore K Kvien

► Additional material is published online only. To view please visit the journal online (<http://dx.doi.org/10.1136/annrheumdis-2015-207548>).

¹Division of Experimental Pathophysiology and Immunology, Biocenter, Medical University of Innsbruck, Innsbruck, Austria

²Central Laboratory Animal Facilities, Medical University of Innsbruck, Innsbruck, Austria

³Department of Internal Medicine VI, Medical University of Innsbruck, Innsbruck, Austria

⁴Department of Rheumatology, Center of Experimental Rheumatology, University Hospital Zurich, Zurich, Switzerland

Correspondence to

Professor Roswitha Sgonc, Division of Experimental Pathophysiology and Immunology, Biocenter, Medical University of Innsbruck, Innrain 80-82, Innsbruck 6020, Austria; roswitha.sgonc@i-med.ac.at

Received 4 March 2015

Revised 1 July 2015

Accepted 1 August 2015

Published Online First

11 September 2015



Open Access
Scan to access more
free content



CrossMark

To cite: Allipour Birgani S, Mailänder M, Wasle I, et al. *Ann Rheum Dis* 2016;**75**:1399–1406.

ABSTRACT

Background In systemic sclerosis (SSc), chronic and uncontrolled overexpression of vascular endothelial growth factor (VEGF) results in chaotic vessels, and intractable fingertip ulcers. Vice versa, VEGF is a potent mediator of angiogenesis if temporally and spatially controlled. We have addressed this therapeutic dilemma in SSc by a novel approach using a VEGF₁₂₁ variant that covalently binds to fibrin and gets released on demand by cellular enzymatic activity. Using University of California at Davis (UCD)-206 chickens, we tested the hypothesis that cell-demanded release of fibrin-bound VEGF₁₂₁ leads to the formation of stable blood vessels, and clinical improvement of ischaemic lesions.

Methods Ninety-one early and late ischaemic comb and neck skin lesions of UCD-206 chickens were treated locally with VEGF₁₂₁-fibrin, fibrin alone, or left untreated. After 1 week of treatment the clinical outcome was assessed. Angiogenesis was studied by immunofluorescence staining of vascular markers quantitatively analysed using TissueQuest.

Results Overall, 79.3% of the lesions treated with VEGF₁₂₁-fibrin showed clinical improvement, whereas 71.0% of fibrin treated controls, and 93.1% of untreated lesions deteriorated. This was accompanied by significantly increased growth of stable microvessels, upregulation of the proangiogenic VEGFR-2 and its regulator TAL-1, and increase of endogenous endothelial VEGF expression.

Conclusions Our findings in the avian model of SSc suggest that cell-demanded release of VEGF₁₂₁ from fibrin matrix induces controlled angiogenesis by differential regulation of VEGFR-1 and VEGFR-2 expression, shifting the balance towards the proangiogenic VEGFR-2. The study shows the potential of covalently conjugated VEGF-fibrin matrices for the therapy of ischaemic lesions such as fingertip ulcers.

INTRODUCTION

Systemic sclerosis (SSc, scleroderma), a devastating autoimmune connective tissue disease affecting the skin and viscera, is characterised by microangiopathy, immunological abnormalities and fibrosis.¹ Although great progress has been made in unscrambling the complex pathogenic interactions between the immune system, the vasculature and fibrotic processes, the ultimate aetiology still remains unclear.² However, apoptosis of endothelial cells (ECs) is considered to be a primary event in the

pathogenesis of SSc that precedes inflammation and fibrosis.³

The search for the ultimate aetiology as well as the evaluation of new therapeutic approaches requires appropriate animal models. The University of California at Davis (UCD) chicken lines 200 and 206 are the only animal model displaying all hallmarks of SSc, that is, microvascular damage, severe perivascular mononuclear cell infiltration, and fibrosis of skin and viscera, circulating antinuclear antibodies, and anti-EC antibodies.⁴

Vascular alterations in human and avian SSc predominantly affect the microvasculature with intimal proliferation, occlusion of blood vessel and capillary necrosis, leading to a decreased blood flow, a state of chronic ischaemia and clinical manifestations such as fingertip ulcers and comb lesions.^{5–6} Tissue hypoxia normally induces neoangiogenesis, but in SSc vascular repair and angiogenesis seem to be strongly disturbed.^{7–9} One of the key molecules in the induction of angiogenesis is vascular endothelial growth factor (VEGF). It is involved in several steps of angiogenesis including migration, proliferation and survival of ECs.¹⁰ In patients with SSc, VEGF expression is upregulated, but seems to be uncontrolled and chronic.^{11–14} Sufficient angiogenesis depends on the tight regulation of VEGF expression.¹⁵ Prolonged exposure to VEGF results in the formation of a chaotic capillary network with irregularly shaped, dilated capillaries, a morphology similar to that seen in SSc.^{16–17} Thus, the chronic VEGF overexpression found in SSc might paradoxically lead to a disturbed vessel morphology rather than to promote the formation of new functional and stable vessels. Recently, increased serum levels of the antiangiogenic VEGF_{165b} isoform have been reported in patients with SSc, which could at least partly explain the lack of sufficient angiogenesis despite strongly elevated VEGF levels.¹⁸ However, very high levels of VEGF are associated with the absence of fingertip ulcers.^{11–19} This suggests that the concentrations of proangiogenic VEGF isoforms have to exceed a certain threshold level to overcome the inhibitory effects of antiangiogenic factors, and that a further increase of VEGF might have beneficial effects in the prevention and therapy of fingertip ulcers. Yet, therapeutic VEGF can play either a helpful or harmful role in tissue vascularisation, depending on the dose and pharmacokinetics of its administration.^{16–20–21} Hence, uncontrolled long-term

overexpression as in SSc or a burst release leads to chaotic morphology of the newly formed vessels with reduced blood flow, whereas a short-time upregulation of VEGF initiates angiogenesis, which results in the formation of stable blood vessels.²² Thus, in SSc, there is a therapeutic need for a temporally and spatially controlled availability of proangiogenic VEGF at sites of ischaemia (eg, fingertip ulcers).

In nature, the longer VEGF isoforms are bound to extracellular matrix (ECM) components until liberated in a tightly controlled manner by local enzymatic activity of cells invading the matrix.²³ The ECM provides a bioactive dynamic structure, which controls EC activities by various mechanisms ranging from cell anchorage and growth factor binding to integrin-mediated activation, and thus is crucial for functional and sustained vascular growth.²⁴ In order to mimic nature, Andreas Zisch *et al*²⁵ have developed a method to covalently bind VEGF₁₂₁ to a fibrin matrix, in which VEGF₁₂₁ is released upon demand by enzymatic cleavage. Grafting experiments with this fibrin-bound VEGF variant demonstrated controlled growth of morphologically normal blood vessels.²⁶ Based on this evidence, we hypothesised that local administration of VEGF₁₂₁-fibrin and consequent cell demanded release of VEGF from the fibrin matrix should overcome the uncontrolled VEGF expression found in SSc, and induce sufficient angiogenesis to heal and prevent ischaemic ulcers. Here we present the therapeutic efficacy of this novel approach in the spontaneous avian model of SSc.

MATERIALS AND METHODS

Animals and study design

UCD-206 chickens were bred and maintained at the Central Laboratory Animal Facilities of the Medical University of Innsbruck. Animal breeding, housing, treatment and collection of tissue samples were carried out in accordance with the Animal Experiment Directive of the European Union (Directive 2010/63 EU) and the Austrian law on the protection of animals used for scientific purposes ('Tierversuchsgesetz' BGBl I Nr. 501/1989 idF 2005 and BGBl I Nr. 114/2012) after approval by the Federal Ministry of Science and Research (GZ 66.011/082-C/GT/2007, GZ 66.011/082-C/GT/2010, and GZ 66.011/077-WF/II/3b/2014). The clinical stage of early skin lesions is classified in the comb as C+ (erythema), C++ (erythema and oedema), C+++ (ulceration with onset of necrosis), C++++ (comb lost due to self dubbing) in the neck skin as N+ (erythema), N++ (erythema and oedema), and N+++ (ulceration with onset of necrosis), N++++ (fibrosis).³ Comb lesions developed between 9 days and 27 days of age (mean 14.7±4.1 SD), neck lesions between 22 days and 37 days of age (mean 26.0±3.9 SD).

For the present study, lesions were treated at the stages of C++ and C+++, neck lesions at stage N+++ either with VEGF₁₂₁ modified fibrin gel, with fibrin gel only, or left untreated (comb lesions n=10 per group, neck lesions treated with VEGF₁₂₁-fibrin or fibrin n=11 each, untreated n=9). Chickens were randomly assigned to receive VEGF₁₂₁-fibrin, fibrin or no treatment, and received a code for blinded clinical and histological analyses.

Procedures

In order to mimic the natural binding of VEGF to ECM, we used VEGF₁₂₁ modified with the factor XIIIa substrate sequence NQEQVSPL. This variant, α_2 PI₁₋₈-VEGF₁₂₁, spontaneously cross-links to fibrinogen by the transglutamination activity of factor XIII (FXIII) during fibrin polymerisation.²⁵ VEGF₁₂₁-fibrin gel matrices were prepared by mixing 20 µg/mL

α_2 PI₁₋₈-VEGF₁₂₁ (kindly provided by A Zisch) with fibrinogen solution (Tisseel, Baxter AG, Vienna, Austria) diluted with sterile Tris buffered saline (pH 7.2) to a final concentration of 10 mg/mL fibrinogen, and 2 U/mL FXIII (Baxter AG, Vienna, Austria) prior to initiation of fibrin gelation by addition of 2 U/mL thrombin (Tisseel, Baxter AG, Vienna, Austria). For placebo control, α_2 PI₁₋₈-VEGF₁₂₁ was omitted. The mixture was immediately applied to the lesion with the help of a small plastic ring to keep it in place till gel was formed, which took 20–30 s. The ring was then removed, and the gel covered with Opsite Flexigrid (Smith & Nephew, Hull, UK) to keep it moist.

After 7 days, the dressing was removed; pictures were taken for documentation and macroscopic analysis by comparison with pictures taken before treatment. The animals were sacrificed under Narkodorm anaesthesia (Pentobarbital, CP-Pharma, D-31303 Burgdorf, Germany, 20 mg/kg intravenous) by cardiac exsanguination. Combs and neck skin biopsies were shock frozen in liquid nitrogen and stored at -196°C till further analyses. The clinical outcome was evaluated by three experts (HD, JG and RS) independently, and in a blinded manner. The degree of change was scored as follows: 0=no change, +1=improvement, +2=strong improvement, -1=deterioration, -2=strong deterioration.

Immunofluorescence staining

Angiogenesis was studied by indirect immunofluorescence (IIF) tests on 4 µm frozen tissue sections using antibodies specific for the EC marker von Willebrand factor (vWF), and α smooth muscle actin (α SMA) or desmin, which are expressed by pericytes (PCs) and smooth muscle cells (SMCs), and serve as markers for stable blood vessel formation. Expression of VEGF, VEGFR-1, VEGFR-2 and TAL-1 by ECs was also analysed by IIF double staining with the respective antibody and anti-vWF antibody. Nuclei were stained with DAPI. See online supplementary text for details on antibodies and staining procedure.

Microscopy and quantitative analysis

IIF staining was analysed in a blinded manner using a Nikon Eclipse E800 fluorescence microscope (Nikon, Tokyo, Japan). For quantitative analysis digital black and white (b/w) pictures were acquired from 10 fields of view per tissue section using a 20× objective lens (Plan Apo 20×/0.75 DICM α /0.17 WD 1.0) with filter settings for FITC, RRX and DAPI in series (jpeg fine, size 1280×960, source s1.3M, CCD mode).

ECs and non-ECs expressing VEGF, VEGFRs or TAL-1 were quantified using the image analysis software TissueQuest cytometer (TQ 4.0 TissueQuest Software, TissueGnostics, Vienna, Austria). This microscopy-based multicolour tissue cytometry software permits multicolour analysis of single cells within tissue sections similar to flow cytometry. The principle of the method and the algorithms used have been described in detail elsewhere.²⁷ In brief, the DAPI channel is the master marker for the identification of all events. This mask is then used in a corrected form to measure staining intensity in the other channels. Cut-off values for FITC and RRX channels were defined according to isotype controls, coexpressions were depicted in scattergrams of normalised grey values, and numbers of single positive and double positive cells were calculated as cells per mm². To discriminate PCs and SMCs, parameters were chosen in order to identify α SMA positive cells within the basal lamina and outside.

Statistical analysis

GraphPad Prism software V.6.0 was used for statistical analyses. Since the majority of our data did not pass the D'Agostino and

Pearson omnibus normality test, two groups were compared by the non-parametrical Mann-Whitney U test after testing the global null hypothesis by the Kruskal-Wallis test. Local p values were adjusted by the global p value to preserve the family-wise error rate.²⁸ p Values ≤ 0.05 were considered statistically significant.

RESULTS

Primary outcome

To evaluate whether VEGF₁₂₁ modified fibrin heals and prevents ischaemic ulcerations, we locally treated early inflammatory comb lesions (C++), and late comb and neck skin ulcers (C+++, N+++) of UCD-206 chickens. After 1 week of treatment the clinical outcome was assessed (figure 1). Two animals treated with VEGF₁₂₁-fibrin had lost the dressing and therefore were excluded from the study, that is, one with C++ lesion and one with N+++ lesion. From the comb lesions treated with VEGF₁₂₁-fibrin in the early inflammatory C++ stage, six (66.7%) showed improvement, one (11.1%) deterioration and two (22.2%) halt of disease progression. Fibrin treated C++

lesions improved in two chickens (20.0%), worsened in seven (70.0%) and showed no change in one animal. All 10 untreated C++ lesions deteriorated. Nine comb lesions (90.0%) treated with VEGF₁₂₁-fibrin in the late ischaemic C+++ stage showed improvement, one lesion deteriorated. In the fibrin treated group only one C+++ lesion improved slightly, eight (80.0%) worsened and one (10.0%) was unchanged. In the untreated C+++ group there was one (10.0%) spontaneous healing, one without change and eight (80.0%) with clear deterioration. Ulcerations of neck skin were clearly improved in eight animals (80.0%) after VEGF₁₂₁-fibrin treatment, and showed no change in two chickens. Fibrin treatment improved only two N+++ lesions (18.2%), two (18.2%) were unaltered and seven (63.6%) progressed further. All 10 untreated lesions were strongly deteriorated. There was 100% agreement between the three blinded independent investigators in the semiquantitative clinical assessment in 60% of the cases; in 38% of the cases, two of the investigators showed 100% concordance, one differed by one degree up or down. The three investigators disagreed only in two cases on the severity of deterioration.

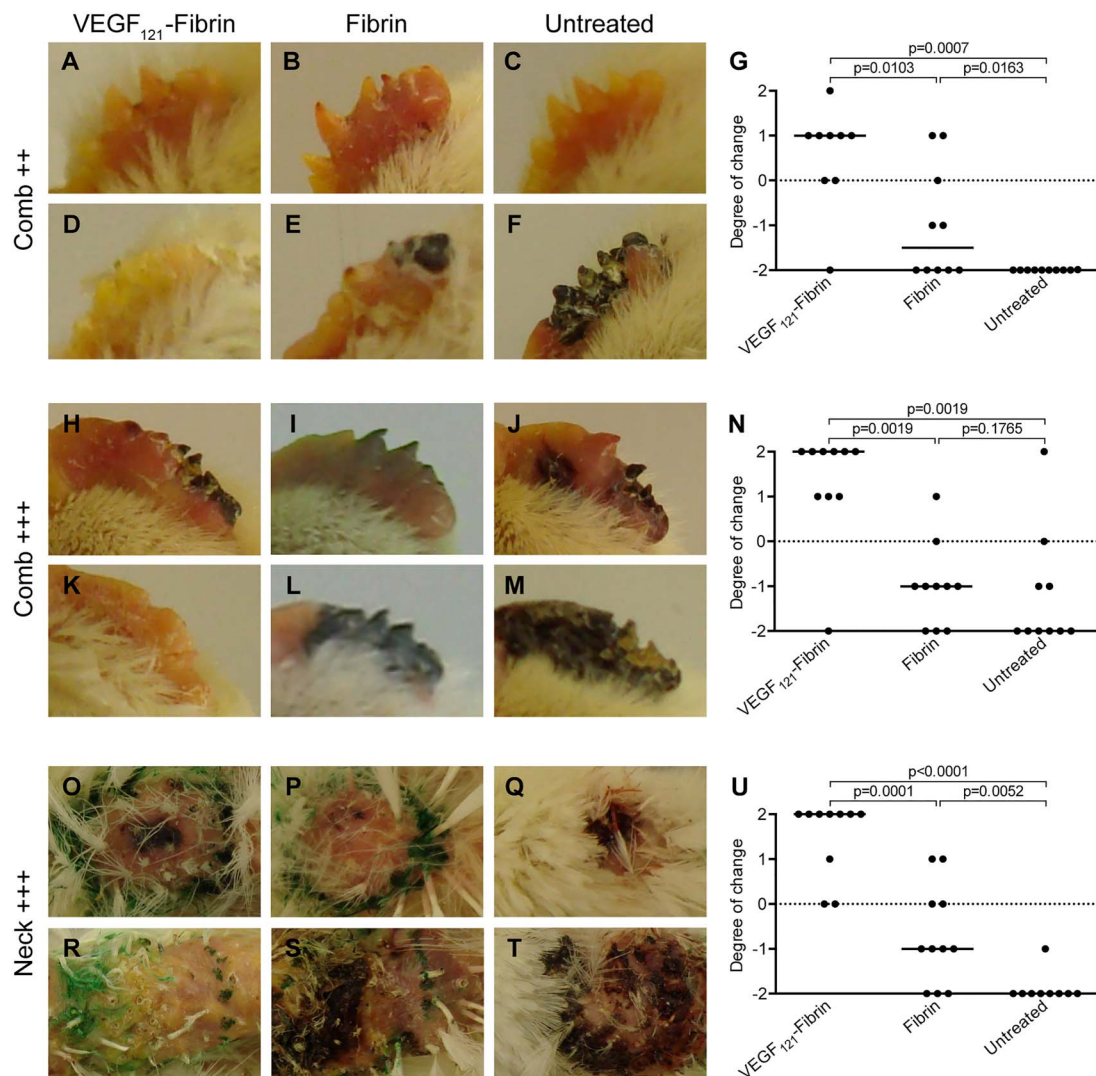


Figure 1 Clinical outcome 7 days after treatment. Representative examples of comb and neck lesions photographed before (A–C, H–J, O–Q), and after 1 week of treatment (D–F, K–M, R–T). Lesions at beginning of therapy: ++, erythema and oedema; +++, beginning necrosis. Results of clinical assessment by three blinded examiners of comb ++ (G), comb +++ (N), and neck +++ (U). Degree of change: 0=no change, +1=improvement, +2=strong improvement, –1=deterioration, –2=strong deterioration. p Values have been calculated using the Mann-Whitney U test adjusted by the Kruskal-Wallis test. Each dot represents a single lesion. Horizontal lines indicate the median. VEGF, vascular endothelial growth factor.

Effect of VEGF₁₂₁-fibrin on angiogenesis

To assess whether VEGF₁₂₁-fibrin induces the growth of mature blood vessels, we quantitatively analysed frozen tissue sections stained by IIF with EC specific anti-vWF antibodies and anti- α SMA antibodies as a marker for mural cells. One of the fibrin treated C++ samples was lost due to accidental defrosting, and thus not included in the studies on angiogenesis. Microvascular density was significantly increased in VEGF₁₂₁-fibrin treated early comb lesions, late comb lesions, and neck skin ulcers compared with fibrin treated and untreated lesions (figure 2A, D, G). The difference was also significant between VEGF₁₂₁-fibrin and fibrin treated samples. Fibrin itself also increased the number of ECs significantly compared with untreated lesions. PC numbers were significantly elevated in all VEGF₁₂₁-fibrin treated groups compared with untreated controls (figure 2B, E, H). Fibrin alone increased the number of PCs as well, but to a lesser extent. In late comb and neck ulcers, however, the effect of VEGF₁₂₁-fibrin was significantly higher than of fibrin only. Significantly more vascular SMCs (vSMCs) were found in all VEGF₁₂₁-fibrin treated lesions, and fibrin only groups compared with untreated controls (figure 2C, F, I). Increase of mural cell numbers after treatment with VEGF₁₂₁-fibrin was confirmed by desmin staining (see online supplementary figure S1).

To study the regulatory effects of VEGF₁₂₁-fibrin on the expression of VEGF receptors VEGFR-1 and VEGFR-2, we determined the numbers of VEGFR-1/vWF double stained cells and the numbers of VEGFR-2/vWF double stained cells using TissueQuest, and calculated first the ratio of VEGFR-1 to VEGFR-2 expressing ECs. We then calculated the change of this ratio (x) in relation to healthy controls with the equation

$x = (y \times 100/\bar{x}_{\text{healthy}}) - 100$, where y is the VEGFR-1: VEGFR-2 ratio of individual samples. Whereas in the majority of untreated lesions the VEGFR-1:VEGFR-2 ratio was increased in relation to healthy controls, the change of the VEGFR-1: VEGFR-2 ratio was significantly lower after VEGF₁₂₁-fibrin treatment compared with untreated combs, and fibrin treated comb lesions (figure 3A, B). Neck skin lesions also showed a clear change of VEGFR-1:VEGFR-2 ratio after treatment with VEGF₁₂₁-fibrin compared with fibrin and untreated controls. However the significance between groups was lost after Kruskal-Wallis adjustment (VEGF₁₂₁-fibrin: median=-75.2 (IQR=-90.9 to -53.0), fibrin: -66.5 (-83.1 to 179.1); figure 3C-F). The reduction of the VEGFR-1:VEGFR-2 ratio was in part due to increased VEGFR-2 expression. To confirm this finding we also analysed the expression of TAL-1/SCL, a positive regulator of VEGFR-2 (figure 4). Compared with untreated controls VEGF₁₂₁-fibrin increased the number of TAL-1 expressing ECs in early comb lesions, late comb lesions and neck ulcers. In the latter, the difference between VEGF₁₂₁-fibrin and fibrin treatment was also statistically significant, whereas in comb lesions TAL-1 expressing ECs were elevated by fibrin compared with untreated controls.

Furthermore, we wanted to know if the exogenous VEGF₁₂₁-fibrin has an influence on VEGF production by ECs. The number of VEGF expressing ECs was increased after VEGF₁₂₁-fibrin treatment of comb and neck ulcers compared with fibrin and untreated controls. These differences were clearly significant in C+++, but not significant after Kruskal-Wallis adjustment in neck lesions (VEGF₁₂₁-fibrin: 235.4 (72.9-636.7), fibrin: 74.1 (36.0-316.8), untreated control: 116.4 (54.9-146.7); figure 5).

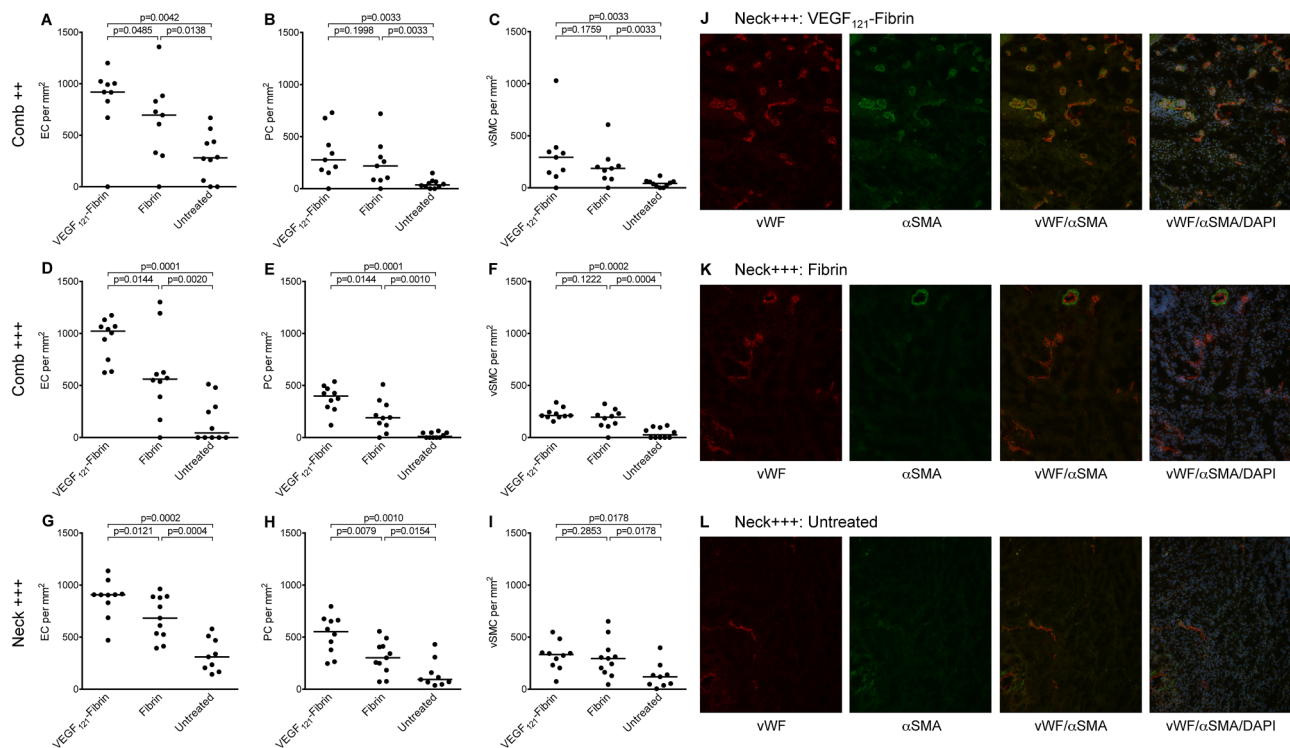


Figure 2 Effects of VEGF-therapy on angiogenesis. (A–I) display quantitative analyses of endothelial cells (ECs), pericytes (PCs) and vascular smooth muscle cells (vSMCs) after 1 week of treatment of early inflammatory comb lesions (C++, A–C), of comb ulcers (C+++, D–F), and neck ulcers (N+++, G–I). p Values have been calculated using the Mann-Whitney U test adjusted by the Kruskal-Wallis test. Each dot represents a single lesion. Horizontal bars indicate median values. Representative false colour immunofluorescence pictures of neck skin ulcers treated locally with VEGF₁₂₁-fibrin (J), fibrin (K) or left untreated (L) depicting vWF staining, α smooth muscle actin (α SMA) staining, vWF/ α SMA overlays and vWF/ α SMA/DAPI overlays. Original magnification $\times 200$. VEGF, vascular endothelial growth factor; vWF, von Willebrand factor.

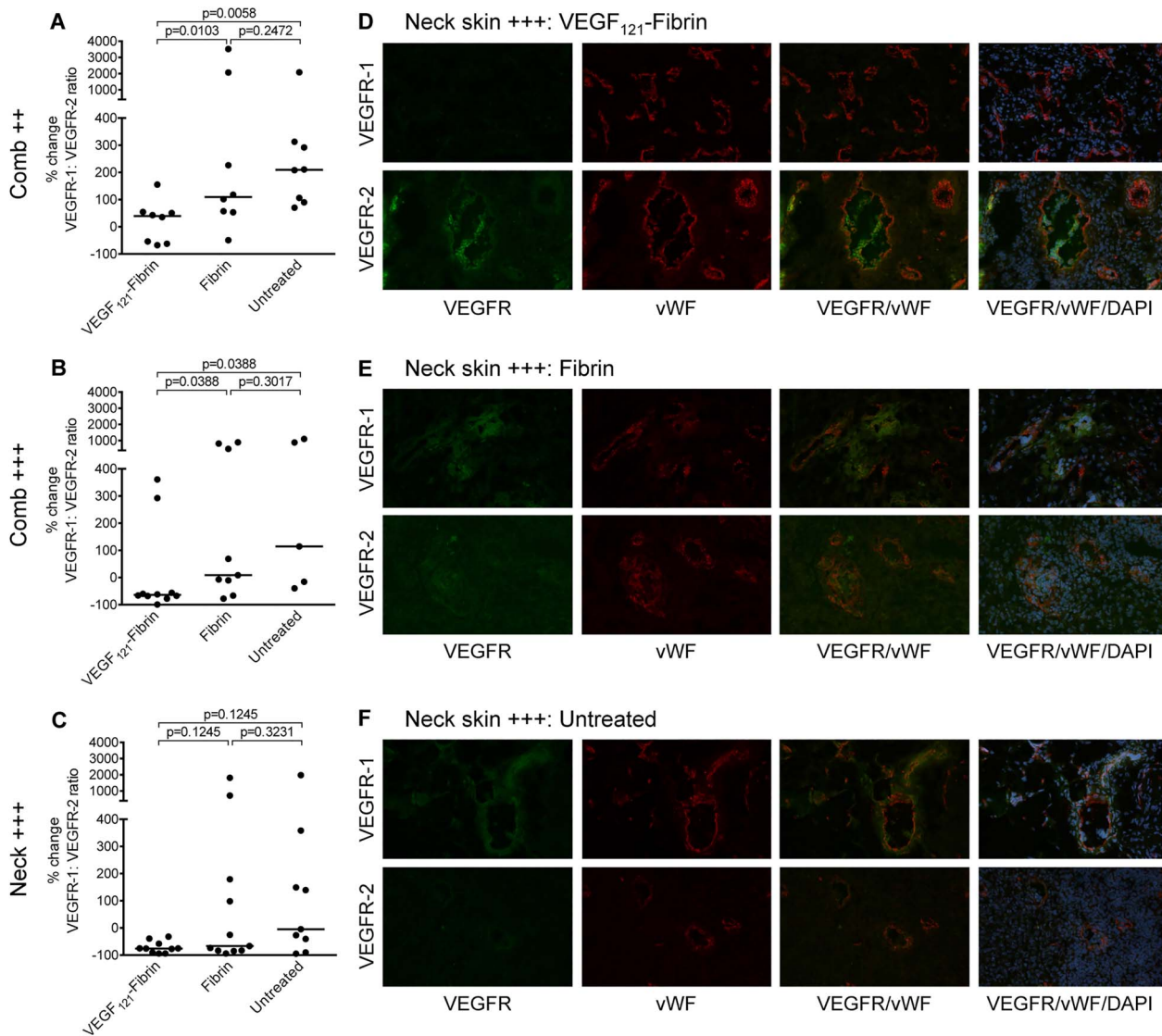


Figure 3 Endothelial expression of VEGFR-1 and VEGFR-2. Changes in the ratio of VEGFR-1 to VEGFR-2 expressing endothelial cells after 1 week of treatment of early inflammatory comb lesions (C++; A), of comb ulcers (C+++; B) and neck ulcers (N+++; C). Data expressed as change of the VEGFR-1:VEGFR-2 ratio in % from healthy control chickens, where the mean value of healthy chickens was defined as 0% change. Note that some deteriorated lesions showed no VEGFR-1 and VEGFR-2 expression, so that it was not possible to calculate the VEGFR-1:VEGFR-2 ratio. p Values have been calculated using the Mann-Whitney U test adjusted by the Kruskal-Wallis test. Each dot represents a single lesion. Horizontal bars indicate median values. Representative false colour immunofluorescence pictures of neck skin ulcers treated locally with VEGF₁₂₁-fibrin (D), fibrin (E) or left untreated (F) showing single channel and overlays; upper panels: VEGFR-1, lower panels: VEGFR-2. Original magnification $\times 200$. VEGF, vascular endothelial growth factor; vWF, von Willebrand factor.

DISCUSSION

The novelty and attractiveness of the current approach lies in the bioavailability of VEGF on cellular demand. This specifically addresses an unmet need in SSC where we have the situation of insufficiently increased VEGF levels. Moreover, some of the overexpressed VEGF might be antiangiogenic.²⁹ Both aspects are addressed by the fibrin-bound VEGF gel: it provides locally in the wound bed sufficient amounts of VEGF and at the same time, the release of VEGF is on demand of the cells and the local release is stopped after it is no longer required. Our study in UCD-206 chickens convincingly showed the clinical efficacy of the topical VEGF₁₂₁-fibrin therapy. In most cases of early treatment, that is, in combs with oedema but no ulceration, VEGF₁₂₁-fibrin prevented the development of ischaemic ulcers. In total, only two animals (6.9%) did not respond to VEGF₁₂₁-fibrin at all, and showed the same disease progression

as untreated animals. Spontaneous healing was observed in only one untreated chicken with comb ulcer. Fibrin gel alone had a moderate improving effect on five lesions (16.1%). Overall, 79.3% of the VEGF₁₂₁-fibrin treated lesions showed clear clinical improvement, whereas 71.0% of fibrin treated controls and 93.1% of untreated lesions had deteriorated. It should be noted here that, although closed bred, UCD-206 chickens are not an inbred line, and thus, like humans do not react uniformly.

VEGF₁₂₁-fibrin had effectively promoted angiogenesis, leading to increased microvascular density. This is also reflected by significantly more ECs in comb and neck lesions treated with VEGF₁₂₁-fibrin compared with fibrin or untreated controls. Nascent blood vessels initially consist only of ECs and have to be stabilised by mural cells.³⁰ Mural cells of capillaries are referred to as PCs, those of arteries, arterioles, and veins as vSMCs. They

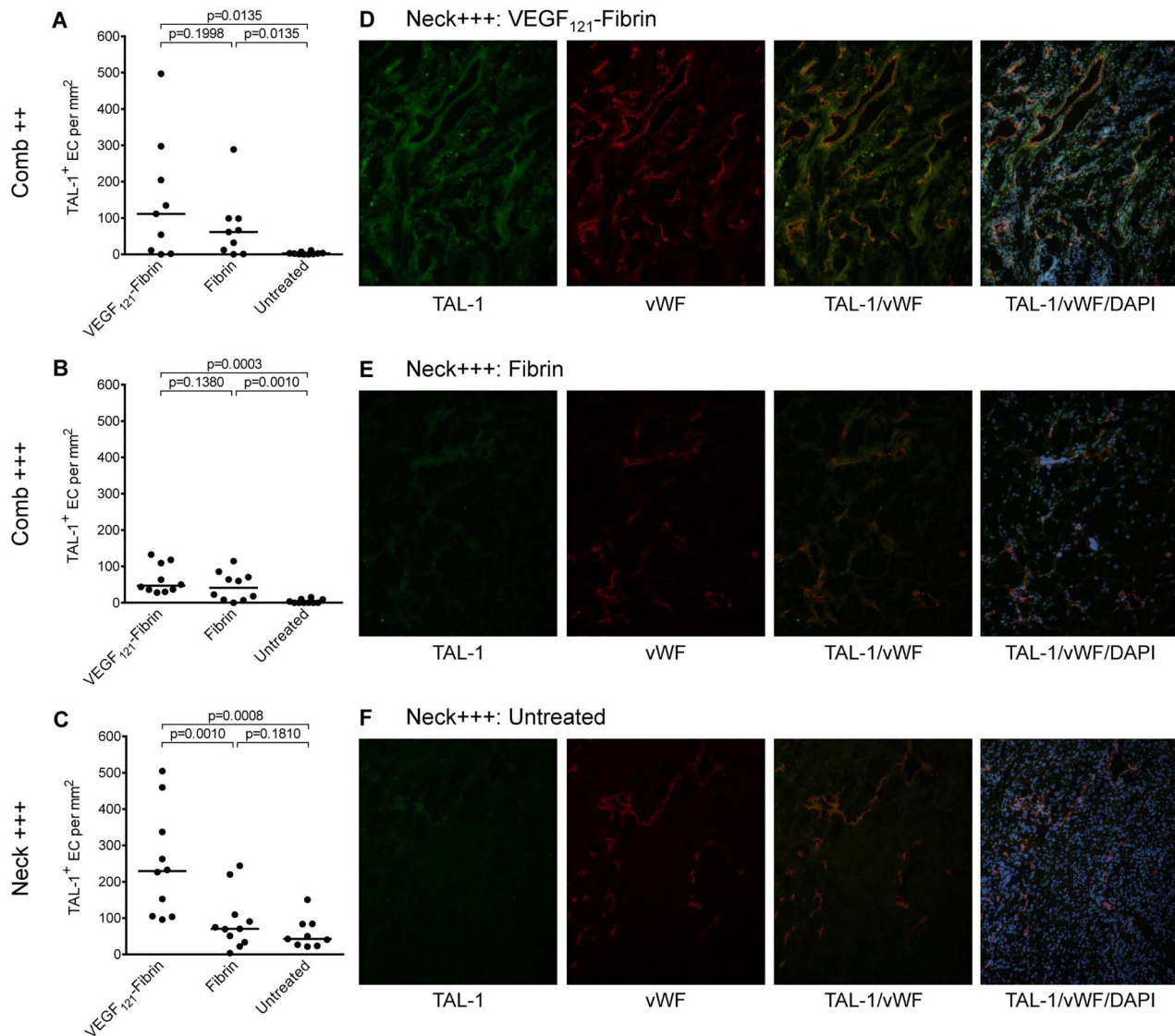


Figure 4 Endothelial expression of the VEGFR-2 regulator TAL-1. TAL-1 expression in endothelial cells (ECs) was quantified on immunofluorescence TAL-1/vWF double stained frozen tissue sections 1 week after treatment of early inflammatory comb lesions (C++; A), of comb ulcers (C+++; B) and neck ulcers (N+++; C). p Values have been calculated using the Mann-Whitney U test adjusted by the Kruskal-Wallis test. Each dot represents a single lesion. Horizontal bars indicate median values. Representative false colour immunofluorescence pictures of neck skin ulcers treated locally with VEGF₁₂₁-fibrin (D), fibrin (E) or left untreated (F) showing single channel and overlays. Original magnification $\times 200$. VEGF, vascular endothelial growth factor; vWF, von Willebrand factor.

both express α SMA, but can be distinguished by their localisation.³¹ We have set the parameters of the image analysis software TissueQuest in order to discriminate vSMCs, which are separated from ECs by the basement membrane or in larger arteries by the intima, and PCs, which share the basement membrane with the ECs and are in direct contact with these. Whereas only few mural cells were detected in untreated lesions, all the blood vessels of VEGF₁₂₁-fibrin treated ulcers looked ensheathed by PCs or vSMCs suggesting the formation of mature, stable vessels. Desmin staining corroborated these findings.

The fibrin glue Tisseel, which we used to form the fibrin matrix, stimulated angiogenesis itself. Fibrin is the major component of blood clots, and serves as a provisional matrix during wound healing. Fibrin supports every stage of angiogenesis, that is, migration of ECs, tube formation and vessel maturation. In a rabbit model of hind limb ischaemia it has been found to promote angiogenesis even without the addition of any other proangiogenic factor.³² Thrombin, another component of

Tisseel, as well as FXIII are also known to mediate angiogenesis.^{33 34} FXIII was used to covalently bind VEGF₁₂₁ to fibrin, but was also added to the placebo control. In vitro and in vivo studies have revealed that FXIII promotes migration and proliferation of ECs, inhibits apoptosis, and downregulates the antiangiogenic factor TSP-1 via VEGFR-2 activation.^{34 35} Thus, all three components might contribute to the therapeutic effect of VEGF₁₂₁-fibrin. However, VEGF₁₂₁-fibrin showed significantly greater efficacy than the fibrin sealant with FXIII, especially in the treatment of late ischaemic ulcers of comb and neck skin.

Therapy with VEGF₁₂₁-fibrin affected the expression of VEGFR-1 and VEGFR-2. Most of the VEGF signalling described to date is primarily mediated via VEGFR-2, that is, survival, migration, proliferation and vascular tube formation.³⁶ In developmental angiogenesis VEGFR-1 acts as decoy receptor negatively regulating VEGFR-2 signalling.³⁷ The role of VEGFR-1 in postnatal angiogenesis is less clear, and seems to be context dependent. However, several lines of evidence suggest an

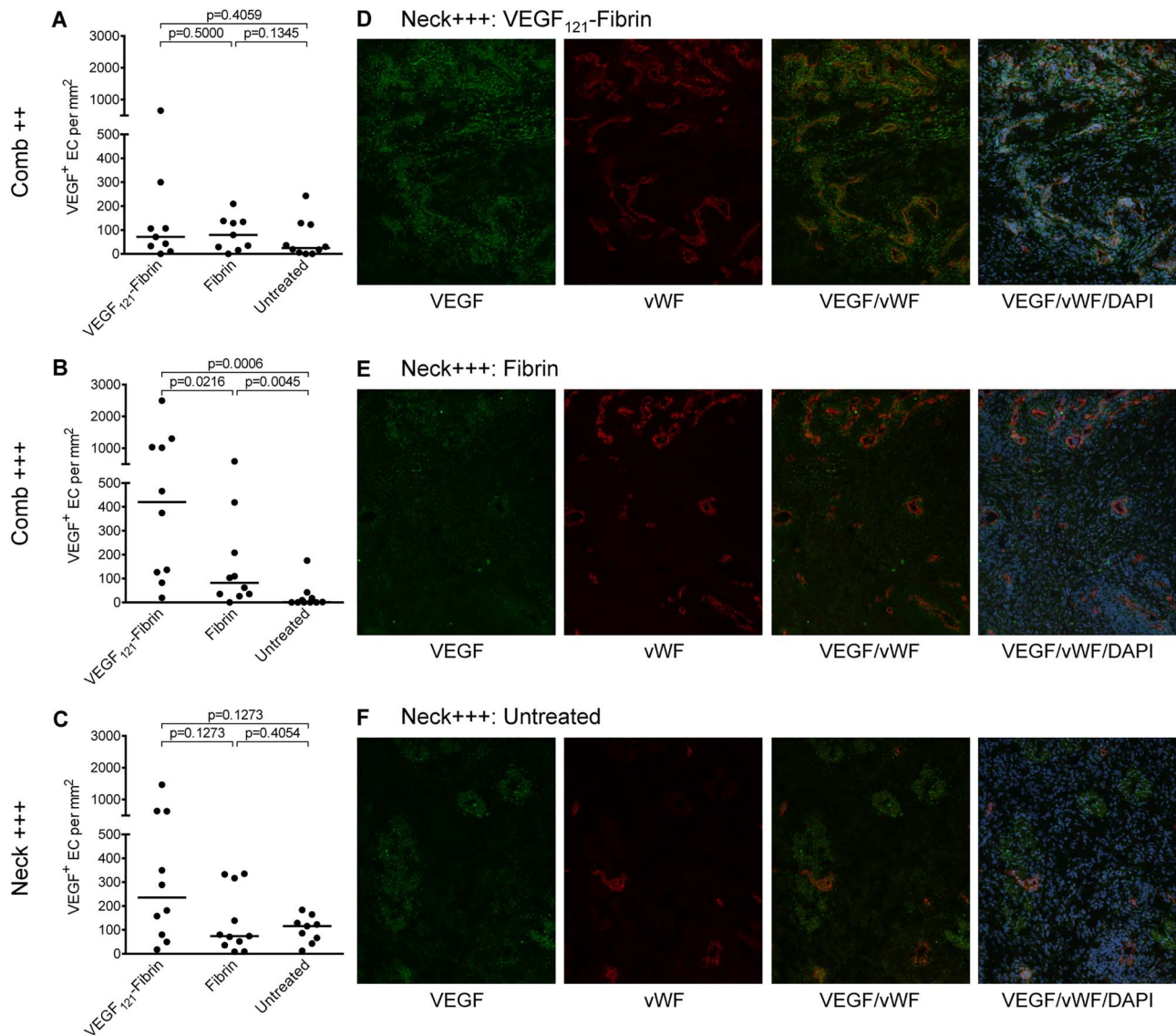


Figure 5 Endogenous VEGF expression in endothelial cells (ECs). Endogenous VEGF expression by ECs was quantified on immunofluorescence VEGF/vWF double stained frozen tissue sections after 1 week of treatment of early inflammatory comb lesions (C++; A), of comb ulcers (C+++; B) and neck ulcers (N+++; C). p Values have been calculated using the Mann-Whitney U test adjusted by the Kruskal-Wallis test. Each dot represents a single lesion. Horizontal bars indicate median values. Representative false colour immunofluorescence pictures of neck skin ulcers treated locally with VEGF₁₂₁-fibrin (D), fibrin (E) or left untreated (F) showing single channel and overlays. Original magnification $\times 200$. VEGF, vascular endothelial growth factor; vWF, von Willebrand factor.

association of increased VEGFR-1 expression with impaired angiogenesis. VEGFR-1 levels are increased in chronic non-healing wounds, whereas in normal healing wounds granulation tissue formation is positively correlated with a decline in VEGFR-1.³⁸ Elevated VEGFR-1 levels have been reported to promote endothelial injury in children with lupus nephritis,³⁹ and to inhibit endothelial repair in PR3-ANCA associated vasculitis.⁴⁰ Upregulation of VEGFR-1 and VEGFR-2 was demonstrated in SSc skin.^{14 41} However, some of these semiquantitative results are contradictory. Whereas one study described a more pronounced VEGFR-2 expression, the other found more VEGFR-1. In bone marrow, diminished angiogenesis was associated with decreased VEGFR-2 expression and high VEGF levels.⁴² It is possible that differences between patients and the small sample numbers account for diverging results, but in general, they indicate activation of the VEGF/VEGFR system and imbalanced expression of VEGF and its receptors. VEGF action is regulated by the availability of its receptors. Therefore, it

seems very likely that the ratio of VEGFR-1:VEGFR-2 rather than the absolute numbers determines the angiogenic status in the tissue. In lesional UCD-206 comb and neck skin the balance between the two receptors is shifted towards VEGFR-1. On exposure to VEGF₁₂₁-fibrin the VEGFR-1:VEGFR-2 ratio was normalised due to differential regulation of VEGFR-1 and VEGFR-2 expression with a relative increase in endothelial VEGFR-2. Upregulation of VEGFR-2 expression concurred with increased TAL-1 expression. TAL-1 is a basic-helix-loop-helix transcription factor known to be essential for haematopoietic development. It is also required during vascular development and angiogenesis, and has been identified as a positive regulator of VEGFR-2.⁴³ Moreover, endogenous VEGF expression was induced by modified VEGF₁₂₁ in comb and neck skin ulcers. As autocrine VEGF signalling is required for endothelial survival,⁴⁴ this might indicate the induction of lasting vascularisation.

All these results support the notion that cell-demanded release of fibrin-bound VEGF is capable of translating a

supraphysiological dose into a physiological tiny dose, of sustaining this dose long enough to permit vessels to mature into stable vessels, and of stopping it if no longer needed. Otherwise chronic exposure would have harmful effects again. Furthermore, this study indicates that even a singular local administration of VEGF₁₂₁-fibrin can achieve sufficient revascularisation to improve existing ulcers or prevent the development of ulcers in our SSc animal model. For clinical applications, long-term effects and potential side effects of VEGF₁₂₁ need particular attention.

Acknowledgements The authors dedicate this paper to the late Andreas Zisch, whose work on biopolymeric matrices for the delivery of growth factors paved the way for successful therapeutic angiogenesis. He was involved in the design of the present study, and we would like to thank him for many fruitful discussions, and for providing $\alpha_2\text{P}1_{1-8}$ -VEGF₁₂₁. The authors also thank Gabriele Stöckl for technical assistance.

Contributors RS and OD conceived and designed the study. RS and HD treated the animals and collected the tissues. JG conceived the grading for the clinical assessment. RS, HD and JG evaluated the clinical outcome. SAB, MM and IW did experiments and analysed the data. RS oversaw all experiments, data analyses and interpretation. RS and SAB wrote the manuscript. OD, HD and JG edited the report. All authors have seen and approved the final manuscript.

Funding This work was funded by the Austrian Science Fund (FWF): P23230-B13.

Competing interests OD has/had consultancy relationship and/or has received research funding in the area of systemic sclerosis and related conditions from Actelion, Pfizer, Ergonex, BMS, Sanofi-Aventis, United BioSource Corporation, Roche/Genentech, Medac, Biovitrium, Boehringer Ingelheim Pharma, Novartis, 4D Science, Active Biotec, Bayer-Schering, Sinox, Serodapharm, EpiPharm, GSK and Biogen.

Provenance and peer review Not commissioned; externally peer reviewed.

Data sharing statement Raw data can be provided upon request.

Open Access This is an Open Access article distributed in accordance with the terms of the Creative Commons Attribution (CC BY 4.0) license, which permits others to distribute, remix, adapt and build upon this work, for commercial use, provided the original work is properly cited. See: <http://creativecommons.org/licenses/by/4.0/>

REFERENCES

- Gabrielli A, Avedimento EV, Krieg T. Mechanisms of disease: scleroderma. *New Engl J Med* 2009;360:1989–2003.
- Katsumoto TR, Whitfield ML, Connolly MK. The pathogenesis of systemic sclerosis. *Ann Rev Pathol* 2011;6:509–37.
- Sgonc R, Gruschwitz MS, Dietrich H, et al. Endothelial cell apoptosis is a primary pathogenetic event underlying skin lesions in avian and human scleroderma. *J Clin Invest* 1996;98:785–92.
- Wick G, Andersson L, Hala K, et al. Avian models with spontaneous autoimmune diseases. *Adv Immunol* 2006;92:71–117.
- Sgonc R. The vascular perspective of systemic sclerosis: of chickens, mice and men. *Int Arch Allergy Immunol* 1999;120:169–76.
- Kahaleh MB. Raynaud phenomenon and the vascular disease in scleroderma. *Curr Opin Rheumatol* 2004;16:718–22.
- Beyer C, Schett G, Gay S, et al. Hypoxia. Hypoxia in the pathogenesis of systemic sclerosis. *Arthritis Res Ther* 2009;11:220.
- Trojanowska M. Cellular and molecular aspects of vascular dysfunctions in systemic sclerosis. *Nat Rev Rheumatol* 2010;6:453–60.
- Liakouli V, Cipriani P, Marrelli A, et al. Angiogenic cytokines and growth factors in systemic sclerosis. *Autoimmun Rev* 2011;10:590–4.
- Chung AS, Ferrara N. Developmental and pathological angiogenesis. *Annu Rev Cell Dev Biol* 2011;27:563–84.
- Distler O, Rosso A, Giacomelli R, et al. Angiogenic and angiostatic factors in systemic sclerosis: increased levels of vascular endothelial growth factor are a feature of the earliest disease stages and are associated with the absence of fingertip ulcers. *Arthritis Res* 2002;4:R11.
- Ricciardi V, Stefanantoni K, Vasile M, et al. Abnormal plasma levels of different angiogenic molecules are associated with different clinical manifestations in patients with systemic sclerosis. *Clin Exp Rheumatol* 2011;29:S46–52.
- Avouac J, Vallucci M, Smith V, et al. Correlations between angiogenic factors and capillaroscopic patterns in systemic sclerosis. *Arthritis Res Ther* 2013;15:R55.
- Distler O, Distler JHW, Scheid A, et al. Uncontrolled expression of vascular endothelial growth factor and its receptors leads to insufficient skin angiogenesis in patients with systemic sclerosis. *Circ Res* 2004;95:109–16.
- Carmeliet P. VEGF gene therapy: stimulating angiogenesis or angioma-genesis? *Nat Med* 2000;6:1102–3.
- Drake CJ, Little CD. Exogenous vascular endothelial growth factor induces malformed and hyperfused vessels during embryonic neovascularization. *Acad Sci USA* 1995;92:7657–61.
- Sulli A, Secchi ME, Pizzorni C, et al. Scoring the nailfold microvascular changes during the capillaroscopic analysis in systemic sclerosis patients. *Ann Rheum Dis* 2008;67:885–7.
- Manetti M, Guiducci S, Romano E, et al. Increased plasma levels of the VEGF165b splice variant are associated with the severity of nailfold capillary loss in systemic sclerosis. *Ann Rheum Dis* 2013;72:1425–7.
- Bielecki M, Kowal K, Lapinska A, et al. Peripheral blood mononuclear cells from patients with systemic sclerosis spontaneously secrete increased amounts of vascular endothelial growth factor (VEGF) already in the early stage of the disease. *Adv Med Sci* 2011;56:255–63.
- Vale PR, Isner JM, Rosenfield K. Therapeutic angiogenesis in critical limb and myocardial ischemia. *J Interv Cardiol* 2001;14:511–28.
- Lee RJ, Springer ML, Blanco-Bose WE, et al. VEGF gene delivery to myocardium: deleterious effects of unregulated expression. *Circulation* 2000;102:898–901.
- Dor Y, Djonov V, Abramovitch R, et al. Conditional switching of VEGF provides new insights into adult neovascularization and pro-angiogenic therapy. *EMBO J* 2002;21:1939–47.
- Park JE, Keller GA, Ferrara N. The vascular endothelial growth factor (VEGF) isoforms: differential deposition into the subepithelial extracellular matrix and bioactivity of extracellular matrix-bound VEGF. *Mol Biol Cell* 1993;4:1317–26.
- Eming SA, Hubbell JA. Extracellular matrix in angiogenesis: dynamic structures with translational potential. *Exp Dermatol* 2011;20:605–13.
- Zisch AH, Schenk U, Schense JC, et al. Covalently conjugated VEGF-fibrin matrices for endothelialization. *J Control Release* 2001;72:101–13.
- Ehrbar M, Djonov VG, Schnell C, et al. Cell-demanded liberation of VEGF₁₂₁ from fibrin implants induces local and controlled blood vessel growth. *Circ Res* 2004;94:1124–32.
- Ecker RC, Steiner GE. Microscopy-based multicolor tissue cytometry at the single-cell level. *Cytometry A* 2004;59:182–90.
- Bender R, Lange S. Adjusting for multiple testing—when and how? *J Clin Epidemiol* 2001;54:343–9.
- Manetti M, Guiducci S, Romano E, et al. Overexpression of VEGF 165b, an inhibitory splice variant of vascular endothelial growth factor, leads to insufficient angiogenesis in patients with systemic sclerosis. *Circ Res* 2011;109:e14–26.
- Carmeliet P, Jain RK. Molecular mechanisms and clinical applications of angiogenesis. *Nature* 2011;473:298–307.
- Gerhardt H, Betsholtz C. Endothelial-pericyte interactions in angiogenesis. *Cell Tissue Res* 2003;314:15–23.
- Fan CL, Gao PJ, Gu YJ, et al. Therapeutic angiogenesis by intramuscular injection of fibrin particles into ischaemic hindlimbs. *Clin Exp Pharmacol Physiol* 2006;33:617–22.
- Tsopanoglou NE, Maragoudakis ME. Thrombin's central role in angiogenesis and pathophysiological processes. *Eur Cytokine Netw* 2009;20:171–9.
- Dardik R, Solomon A, Loscalzo J, et al. Novel proangiogenic effect of factor XIII associated with suppression of thrombospondin 1 expression. *Arterioscler Thromb Vasc Biol* 2003;23:1472–7.
- Dardik R, Loscalzo J, Eskaraev R, et al. Molecular mechanisms underlying the proangiogenic effect of factor XIII. *Arterioscler Thromb Vasc Biol* 2005;25:526–32.
- Koch S, Tugues S, Li X, et al. Signal transduction by vascular endothelial growth factor receptors. *Biochem J* 2011;437:169–83.
- Hiratsuka S, Minowa O, Kuno J, et al. Flt-1 lacking the tyrosine kinase domain is sufficient for normal development and angiogenesis in mice. *Proc Natl Acad Sci USA* 1998;95:9349–54.
- Eming SA, Lauer G, Cole M, et al. Increased levels of the soluble variant of the vascular endothelial growth factor receptor VEGFR-1 are associated with a poor prognosis in wound healing. *J Invest Dermatol* 2004;123:799–802.
- Edelbauer M, Kshirsagar S, Riedl M, et al. Soluble VEGF receptor 1 promotes endothelial injury in children and adolescents with lupus nephritis. *Pediatr Nephrol* 2012;27:793–800.
- Le Roux S, Pepper RJ, Dufay A, et al. Elevated soluble Flt1 inhibits endothelial repair in PR3-ANCA-associated vasculitis. *J Am Soc Nephrol* 2012;23:155–64.
- Mackiewicz Z, Sukura A, Povilenaitė D, et al. Increased but imbalanced expression of VEGF and its receptors has no positive effect on angiogenesis in systemic sclerosis skin. *Clin Exp Rheumatol* 2002;20:641–6.
- Carrai V, Miniati I, Guiducci S, et al. Evidence for reduced angiogenesis in bone marrow in SSc: immunohistochemistry and multiparametric computerized imaging analysis. *Rheumatology* 2012;51:1042–8.
- Kappel A, Schlaeger TM, Flamme I, et al. Role of SCL/Tal-1, GATA, and ets transcription factor binding sites for the regulation of Flk-1 expression during murine vascular development. *Blood* 2000;96:3078–85.
- Lee S, Chen TT, Barber CL, et al. Autocrine VEGF signaling is required for vascular homeostasis. *Cell* 2007;130:691–703.