

Treatment of Nocardial Brain Abscess in a Patient With Systemic Lupus Erythematosus and Idiopathic Thrombocytopenic Purpura: Case Report and a Review of the Literature

Lauren Harris ¹, Ioana Raducanu ², Hu Liang Low ¹

1. Neurosurgery, Queen's Hospital, London, GBR 2. Microbiology, Queen's Hospital, London, GBR

Corresponding author: Lauren Harris, lauren.harris7@nhs.net

Abstract

Brain abscesses due to *Nocardia* species account for 1-2% of all cerebral abscesses, often in immunosuppressed individuals, with a mortality three times higher than other cerebral abscesses. Early diagnosis and management are vital for good outcomes.

We report a case of a right frontal *Nocardia* brain abscess in an immunosuppressed 38-year-old female. She presented with headaches, confusion, memory deficits, and personality change. She remained systemically well, with normal inflammatory markers. She underwent two open surgical drainages, with excision of the abscess wall. She made an excellent recovery with minimal edema and no contrast enhancement on imaging at eight weeks postoperatively.

Management of *Nocardia* brain abscess includes a prompt diagnosis with direct microscopic examination and initiation of correct antibiotic therapy for good outcomes. We recommend open surgical resection, including excision of the abscess wall, followed by long-term antimicrobial therapy, to enhance the rate of recovery.

Categories: Neurology, Infectious Disease, Neurosurgery

Keywords: brain abscess, nocardia species, abscess wall, treatment, neurosurgery

Introduction

Over 30 *Nocardia* species are associated with human diseases, of which *Nocardia asteroides*, *Nocardia brasiliensis*, *Nocardia farcinica*, and *Nocardia nova* are the most prevalent [1]. They are not a part of human saprophyte flora and are rarely contaminants [1]. The microorganism can be inhaled and spread hematogenously from the lungs to the brain or maybe inoculated directly through the skin. Nocardial infections usually present as isolated pulmonary infections, followed by disseminated disease. Nocardial brain abscesses are rare and almost always occur in the context of disseminated disease [2].

We report a very rare case of an isolated nocardial brain abscess in a patient with systemic lupus erythematosus (SLE) and idiopathic thrombocytopenic purpura (ITP). The patient was initially treated with aspiration of the abscess but it recurred. Open drainage and excision of the abscess wall were then carried out with excellent results. Here, we also present a review of the surgical treatment of nocardial brain abscesses.

Case Presentation

A 38-year-old, African American, right-handed female presented with three weeks of right-sided headache, confusion, memory deficit, and personality change. Her physical and neurological examination was otherwise unremarkable. Hematological, biochemical, and inflammatory markers were within the normal range.

Her medical history included treated non-Hodgkin lymphoma, asthma, hypertension, and bilateral cerebellar infarcts. Three months before presentation, she was diagnosed with SLE and ITP, for which she was commenced on prednisolone and rituximab, a B-lymphocyte depleting anti-CD20 monoclonal antibody. She denied any history of smoking, drinking, or the use of illicit substances.

Magnetic resonance imaging (MRI) revealed a multiloculated, ring-enhancing lesion within the right frontal pars triangularis (Figure 1). Enhanced computed tomography scans of her chest, abdomen, and pelvis revealed no abnormalities. Given her normal C-reactive protein levels and the lack of any extracerebral lesions, the favored diagnosis was a primary brain neoplasm. She underwent a neuro-navigated aspiration of the lesion and, to our surprise, thick pus was noted.

Review began 08/04/2021

Review ended 08/21/2021

Published 08/27/2021

© Copyright 2021

Harris et al. This is an open access article distributed under the terms of the Creative Commons Attribution License CC-BY 4.0., which permits unrestricted use, distribution, and reproduction in any medium, provided the original author and source are credited.

How to cite this article

Harris L, Raducanu I, Low H (August 27, 2021) Treatment of Nocardial Brain Abscess in a Patient With Systemic Lupus Erythematosus and Idiopathic Thrombocytopenic Purpura: Case Report and a Review of the Literature. Cureus 13(8): e17498. DOI 10.7759/cureus.17498

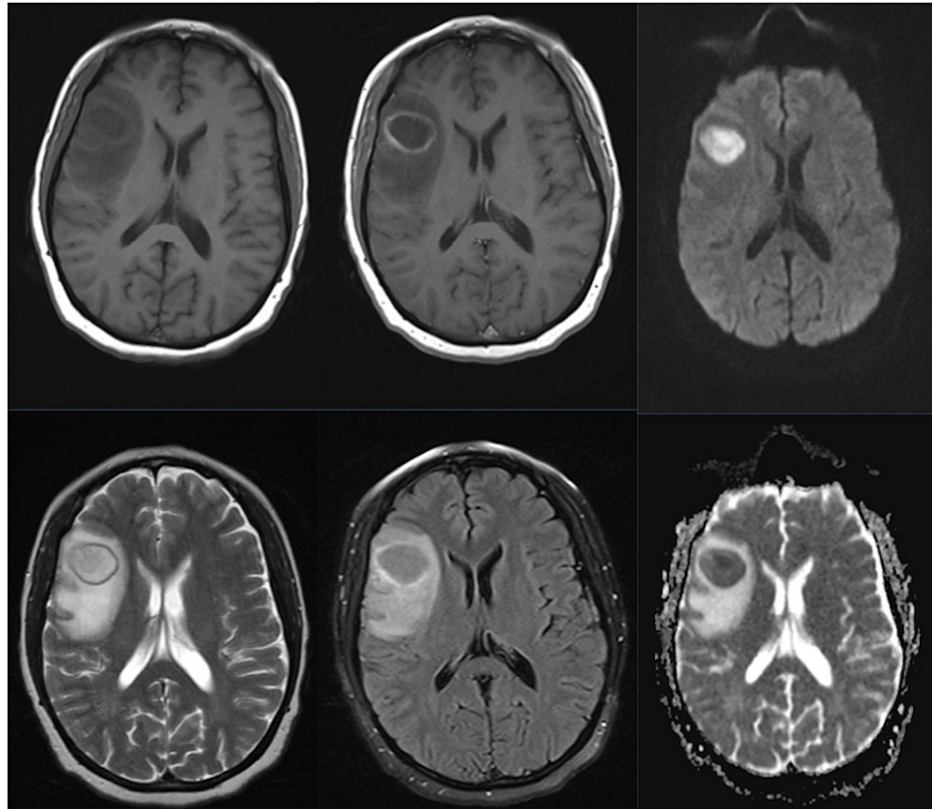


FIGURE 1: Preoperative MRI scan.

Preoperative right frontal multiloculated, ring-enhancing lesion, with surrounding edema and restricted diffusion.

First row: Preoperative T1-weighted, T1 + contrast, diffusion imaging. Second row: Preoperative T2-weighted, FLAIR, and ADC.

ADC: apparent diffusion coefficient; FLAIR: fluid-attenuated inversion recovery; MRI: magnetic resonance imaging

Examination of the pus and a portion of the cavity wall revealed pleomorphic gram-positive hyphae with extensive branching filaments (Figure 2). No neoplastic features were seen. The hyphae were then identified with a 99.9% certainty as *Nocardia farcinica* using matrix-assisted laser desorption/ionization-time-of-flight spectrometry and partial sequencing of 16S rDNA. A 100% certainty was not possible due to a 99% sequence homology between *Nocardia farcinica* and *Nocardia kroppenstedtii* [5]. Tests for acid-fast bacilli, human immunodeficiency virus, hepatitis B, and toxoplasma were all negative.

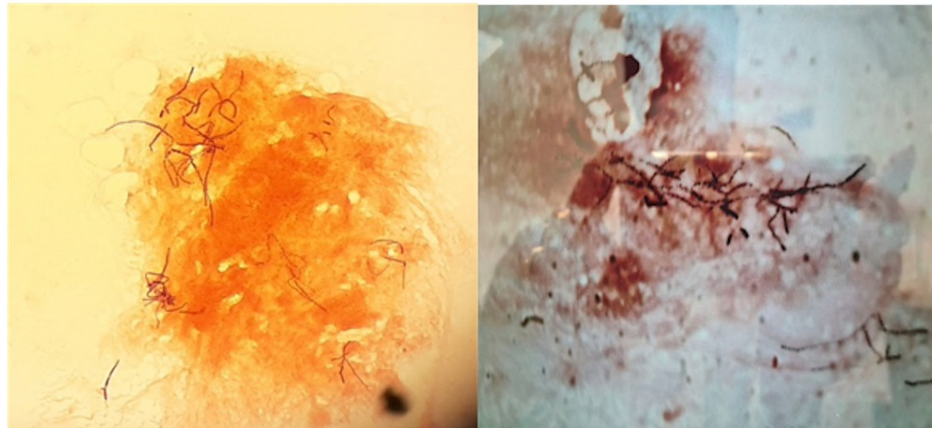


FIGURE 2: Nocardia isolate.

Extensively branched gram-positive hyphae fragmented into coccoid elements (magnification 100×).

She was placed on a six-week course of intravenous meropenem 2 g three times a day, followed by 12 months of oral co-trimoxazole 2,400 mg four times a day. The immediate postoperative period was uncomplicated, and early and postoperative scans showed good decompression of the abscess. However, repeat scans three weeks later showed a significant recurrence of the lesion. At this time, she underwent open drainage of the abscess as well as the removal of the abscess walls. She responded very well to surgery, and repeat scans showed no recollection, along with complete removal of enhancing abscess walls at two months postoperatively (Figure 3).

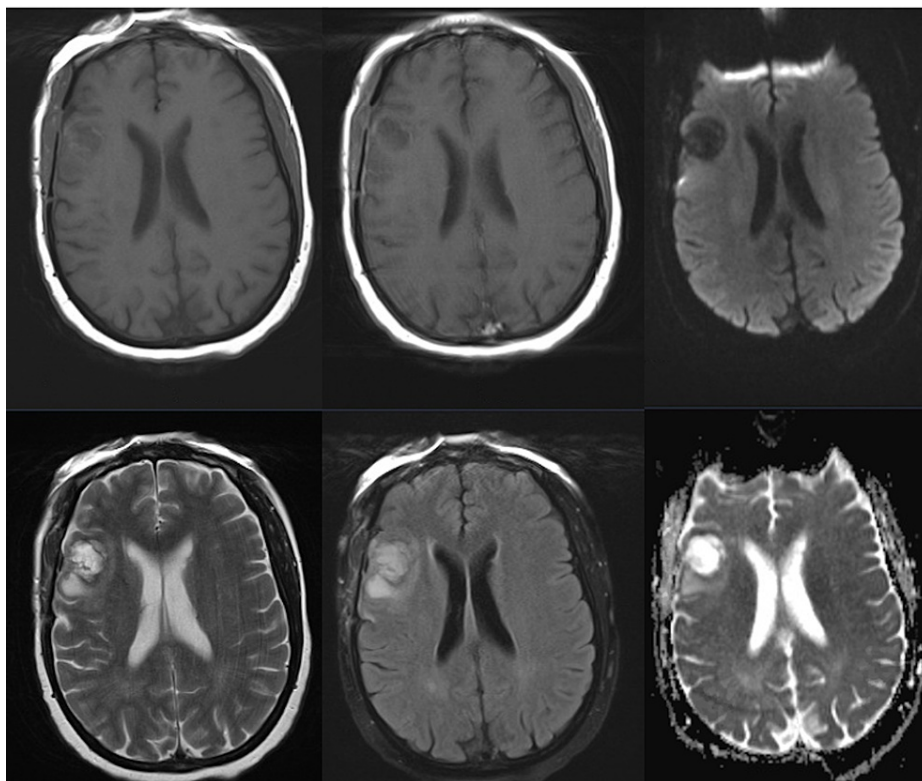


FIGURE 3: Two months postoperative MRI scan.

Two months postoperative loss of enhancement of the residual abscess and minimal edema.

First row: Two months postoperative T1-weighted, T1 + contrast, diffusion imaging. Second row: Two months postoperative T2-weighted, FLAIR, and ADC

ADC: apparent diffusion coefficient; FLAIR: fluid-attenuated inversion recovery; MRI: magnetic resonance imaging

To date, at the nine-month follow-up, the patient remains well, with no clinical or radiological evidence of recurrence. While the microbiology plan was for a one-year course of oral antibiotics, the patient was non-compliant and stopped at two months. MRI imaging was performed at two, four, and six months postoperatively, with continued improvement, minimal cavity, and no enhancement or perilesional edema. Clinically, she had two episodes of focal motor seizures at four months postoperatively, which resolved with 250 mg levetiracetam twice daily as advised by the neurology team. The initial neuropsychiatric symptoms resolved, and she resumed work after two months.

Discussion

Nocardia species are aerobic gram-positive, catalase-positive, acid-fast bacteria, which produce branched, aerial hyphae up to 2 μm in diameter that often fragment into coccobacilli-shaped elements [1,4]. The diagnosis is challenging due to the non-specific presentation, the requirement for invasive diagnostic procedures, and the difficulty in the isolation and identification of the *Nocardia* species [3]. There are no serodiagnostic tests, and 16SrRNA may not definitively distinguish between different species of *Nocardia*, which exhibit different antibiotic susceptibilities [5-7]. Microscopic examination of Gram-stained specimens can give a rapid diagnosis as the thin gram-positive beaded branching filaments are pathognomonic [8].

Nocardia species are opportunistic pathogens that affect mainly immunosuppressed individuals. Steroid use appears to be an independent risk factor [9]. Our patient had been on steroids and rituximab prior to her infection.

As mortality from *Nocardia* is three times higher than that of other brain abscesses (30% versus 10%), early diagnosis and management are vital [10]. Good outcomes are expected with prompt diagnosis and initiation of appropriate treatment. Differentials include intrinsic or metastatic brain tumors, toxoplasmosis, meningioma, cerebral tuberculosis, and cerebral *Mycobacterium* non-tuberculosis infections [11-15]. Management options include surgery, antibiotics if the organism has been identified from a specimen, cerebrospinal fluid or blood cultures, or a combination [16,17]. Pathogen identification and antibiotic

susceptibility tests are performed on the specimen.

In 1928, Sargent was the first to report a successful excision of a brain abscess [18]. Indications for surgery include reducing intracranial pressure, confirming the diagnosis, obtaining pus for microbiological diagnosis, enhancing the efficacy of antimicrobial therapy (particularly in fungal abscesses due to poor blood-brain barrier penetration of antifungals), and avoiding spread into the ventricles [18]. This must be balanced against the risks of surgery, particularly in eloquent or deep locations, and the patients' comorbidities. Surgical options include image-guided stereotactic aspiration versus the more invasive craniotomy and excision, including the abscess wall where possible. Since the advent of stereotaxy and the development of better antibiotics, the majority of cerebral abscesses have been treated successfully with pus aspiration and long-term intravenous antibiotics.

Aspiration is associated with lower risks (mortality of 6.6% versus 12.7% for open drainage of brain abscesses) and is the treatment of choice for deep-seated lesions [19]. However, a case for open drainage of abscesses and partial or complete removal of the abscess wall can be made for superficial lesions, which involve the non-eloquent brain, are well-encapsulated, multiloculated, or contain foreign material. This is particularly pertinent in the case of nocardial abscesses as the lesions formed are often multiloculated and contain viscid pus that is not easily aspirated. Viable nocardial hyphae may also be found within the abscess walls, as demonstrated in our case. These factors may explain the high recurrence rate of nocardial abscesses [10]. Although there are no controlled, prospective studies comparing the outcomes of abscess aspiration to excision or its effect on the duration of antibiotic therapy, retrospective studies suggest that abscess excision is associated with a faster resolution of neurological deficits, low abscess recurrence, and a shorter duration of antibiotics treatment [20-26]. This must be balanced against the risks of a more invasive procedure, with the potential to damage the surrounding cortex and its associated function. In nocardial abscesses, the mortality rate has been documented as 24% after initial craniotomy and excision, 50% after aspiration and drainage, and 30% after non-operative therapy [10]. In our case, aspiration of the abscess was trialed first, with a rapid recurrence. We believe that the removal of the abscess wall during the second operation hastened the clinical recovery and contributed to the good long-term outcome in our patient.

Nocardia has been increasingly recognized in SLE, most commonly with manifestations in the lungs (81%), with central nervous system (CNS) involvement in 13% [27]. The presentation can be with seizures, headaches, focal neurological deficit, or can mimic an SLE flare-up [28]. *Nocardia* in SLE has a high mortality of 35%, increasing to 75% when the CNS is involved [27]. This mortality is related to a delay in diagnosis and the immunosuppressed state of the patient. A summary of *Nocardia* brain abscesses associated with SLE and ITP is presented in Table 1. To our knowledge, this is the second case of a *Nocardia farcinica* brain abscess in a patient with SLE. Of the 14 previously published studies, only one advocated excision of the abscess, with good clinical outcomes after six weeks of antibiotics [29].

Author; Year	Age, Gender	Organism	Location	Presentation	Management	Duration	Outcome
Stewart and Basten; 1975 [30]	31, M	-	Parietal	Hydrocephalus	Aspiration	7 months	Died (MRSA sepsis)
Mc-Nab et al.; 2000 [31]	24, F	<i>N. asteroides</i>	Occipital	-	Cotrimoxazole, cefixime, shunting	-	-
Moitra et al.; 2003 [32]	-	<i>N. asteroides</i>	-	Headache	Biopsy, linezolid	-	-
Yoneyama et al.; 2004 [29]	2 patients, F	-	-	-	Excision, TMP/SMX, minocycline, cefotaxime	6 weeks	Good
Kilincer et al.; 2005 [33]	39, F	<i>N. farcinica</i>	Temporoparietal	Seizure	Aspiration, ceftriaxone, TMP/SMX, minocycline	12 months	Good
Cheng et al.; 2005 [28]	42, F	<i>N. asteroides</i>	Frontal	Headache	Stereotactic aspiration, TMP/SMX	12 months	Good
Justiniano et al.; 2007 [34]	37, M	<i>N. asteroides</i>	Multiple: frontal and occipital	Seizure, slurred speech, hemiparesis	Biopsy, TMP/SMX + linezolid	-	Good
Bashir and Ranganathan; 2010 [35]	54, F	<i>N. asteroides</i>	Multiple: frontal, temporal, cerebellar	Headache, confusion	TMP/SMX	12 months	Good
Ueda et al.; 2014 [36]	69, M	<i>N. elegans</i>	Cerebellar	-	TMP/SMX and clarithromycin	6 months	Good
Jeong et al.; 2017 [37]	51, M	<i>N. asiatica</i>	Multiple: supratentorial and cerebellar	Hemiparesis, dysarthria, dizziness, vomiting, fever	Aspiration, TMP/SMX, and ceftriaxone	10 months	Died
*Barata et al.; 2000 [38]	40, F	<i>Nocardia</i> (not specified)	Frontal	Headache, vomiting	Aspiration, TMP/SMX	10 months	Good
*Wakhlou et al.; 2004 [39]	42, M	<i>N. asteroides</i>	Frontal	Hemiparesis	Aspiration, ceftriaxone, amikacin, TMP/SMX	12 months	Good
*Lai et al.; 2005 [40]	68, M	<i>N. farcinica</i>	Parietal, temporal	Headache	TMP/SMX	12 months	Good
*Frank et al.; 2010 [41]	83, M	<i>Nocardia</i> (not specified)	Cerebellar, occipital	Dysarthria, ptosis, tremor, ataxia	Meropenem, TMP/SMX	2 months	Died (MI)
Present case	38, F	<i>N. farcinica</i>	Frontal	Headache, personality change	Excision, meropenem, TMP/SMX	12 months	Good

TABLE 1: A summary of Nocardia species brain abscess in patients with systemic lupus erythematosus and idiopathic thrombocytopenic purpura (designated by *).

F: female; M: male; TMP/SMX: trimethoprim-sulfamethoxazole (co-trimoxazole); MRSA: methicillin-resistant *Staphylococcus aureus*; MI: myocardial infarction

Conclusions

Nocardial abscesses should be included in the differential in immunocompromised patients presenting with brain lesions. As there are no serological or hematological markers of nocardial infections in the brain, and the mortality is high, early acquisition and examination of material from the lesion either via biopsy or open surgery are essential. Open surgical drainage with excision of the abscess walls followed by long-term

antimicrobial therapy may be more effective than the simple aspiration of nocardial abscesses.

Additional Information

Disclosures

Human subjects: Consent was obtained or waived by all participants in this study. **Conflicts of interest:** In compliance with the ICMJE uniform disclosure form, all authors declare the following: **Payment/services info:** All authors have declared that no financial support was received from any organization for the submitted work. **Financial relationships:** All authors have declared that they have no financial relationships at present or within the previous three years with any organizations that might have an interest in the submitted work. **Other relationships:** All authors have declared that there are no other relationships or activities that could appear to have influenced the submitted work.

References

- Bennett JE, Dolin R, Blaser MJ: Principles and practice of infectious diseases . Elsevier Inc., Philadelphia, PA; 2014. [10.1016/C2012-1-00075-6](https://doi.org/10.1016/C2012-1-00075-6)
- Kim S, Lee KL, Lee DM, et al.: Nocardia brain abscess in an immunocompetent patient . *Infect Chemother.* 2014, 46:45-9. [10.3947/ic.2014.46.1.45](https://doi.org/10.3947/ic.2014.46.1.45)
- Xu S, Hou X, Li D, et al.: Efficient differentiation of *Nocardia farcinica*, *Nocardia cyriacigeorgica* and *Nocardia beijingensis* by high-resolution melting analysis using a novel locus. *J Med Microbiol.* 2020, 69:1367-72. [10.1099/jmm.0.001205](https://doi.org/10.1099/jmm.0.001205)
- Zhu JW, Zhou H, Jia WQ, You J, Xu RX: A clinical case report of brain abscess caused by *Nocardia brasiliensis* in a non-immunocompromised patient and a relevant literature review. *BMC Infect Dis.* 2020, 20:328. [10.1186/s12879-020-05052-0](https://doi.org/10.1186/s12879-020-05052-0)
- Wang HL, Seo YH, LaSala PR, Tarrand JJ, Han XY: Nocardiosis in 132 patients with cancer: microbiological and clinical analyses. *Am J Clin Pathol.* 2014, 142:513-23. [10.1309/AJCPW84AFTUWMHYU](https://doi.org/10.1309/AJCPW84AFTUWMHYU)
- McTaggart LR, Doucet J, Witkowska M, Richardson SE: Antimicrobial susceptibility among clinical *Nocardia* species identified by multilocus sequence analysis. *Antimicrob Agents Chemother.* 2015, 59:269-75. [10.1128/AAC.02770-14](https://doi.org/10.1128/AAC.02770-14)
- Larruskain J, Idigoras P, Marimón JM, Pérez-Trallero E: Susceptibility of 186 *Nocardia* sp. isolates to 20 antimicrobial agents. *Antimicrob Agents Chemother.* 2011, 55:2995-8. [10.1128/AAC.01279-10](https://doi.org/10.1128/AAC.01279-10)
- Public Health England, Standards Unit, Bacteriology: UK Standards for Microbiology Investigations. Identification of aerobic actinomycetes. (2016). Accessed: May 20, 2021: <https://www.gov.uk/government/publications/smi-id-10-identification-of-aerobic-actinomycetes>.
- Coussement J, Lebeaux D, van Delden C, et al.: Nocardia infection in solid organ transplant recipients: a multicenter European case-control study. *Clin Infect Dis.* 2016, 63:338-45. [10.1093/cid/ciw241](https://doi.org/10.1093/cid/ciw241)
- Mamelak AN, Obana WG, Flaherty JF, Rosenblum ML: Nocardial brain abscess: treatment strategies and factors influencing outcome. *Neurosurgery.* 1994, 35:622-31. [10.1227/00006123-199410000-00007](https://doi.org/10.1227/00006123-199410000-00007)
- Yamada SM, Nakai E, Toyonaga S, Nakabayashi H, Park KC, Shimizu K: A rapidly enlarging nocardial brain abscess mimicking malignant glioma. *J Nippon Med Sch.* 2005, 72:308-11. [10.1272/jnms.72.308](https://doi.org/10.1272/jnms.72.308)
- Iannotti CA, Hall GS, Procop GW, Tuohy MJ, Staugaitis SM, Weil RJ: Solitary *Nocardia farcinica* brain abscess in an immunocompetent adult mimicking metastatic brain tumor: rapid diagnosis by pyrosequencing and successful treatment. *Surg Neurol.* 2009, 72:74-9; discussion 79. [10.1016/j.surneu.2008.02.025](https://doi.org/10.1016/j.surneu.2008.02.025)
- Menkü A, Kurtsoy A, Tucer B, Yildiz O, Akdemir H: Nocardia brain abscess mimicking brain tumour in immunocompetent patients: report of two cases and review of the literature. *Acta Neurochir (Wien).* 2004, 146:411-4; discussion 414. [10.1007/s00701-004-0215-6](https://doi.org/10.1007/s00701-004-0215-6)
- Livingston C, Uemura M, Patel R, Afshar M: Nocardia farcinica masquerading as intracerebral metastases in advanced metastatic prostatic cancer. *BMJ Case Rep.* 2020, 13:e235678. [10.1136/bcr-2019-235678](https://doi.org/10.1136/bcr-2019-235678)
- Muricy EC, Lemes RA, Bombarda S, Ferrazoli L, Chimara E: Differentiation between *Nocardia* spp. and *Mycobacterium* spp.: critical aspects for bacteriological diagnosis. *Rev Inst Med Trop Sao Paulo.* 2014, 56:397-401. [10.1590/s0036-46652014000500005](https://doi.org/10.1590/s0036-46652014000500005)
- Chow FC, Marson A, Liu C: Successful medical management of a *Nocardia farcinica* multiloculated pontine abscess. *BMJ Case Rep.* 2013, 2013:bcr2013201308. [10.1136/bcr-2013-201308](https://doi.org/10.1136/bcr-2013-201308)
- Peters BR, Saubolle MA, Costantino JM: Disseminated and cerebral infection due to *Nocardia farcinica*: diagnosis by blood culture and cure with antibiotics alone. *Clin Infect Dis.* 1996, 23:1165-7. [10.1093/clinids/23.5.1165](https://doi.org/10.1093/clinids/23.5.1165)
- Alvis Miranda H, Castellar-Leones SM, Elzain MA, Moscote-Salazar LR: Brain abscess: current management. *J Neurosci Rural Pract.* 2013, 4:S67-81. [10.4103/0976-3147.116472](https://doi.org/10.4103/0976-3147.116472)
- Ratnaik TE, Das S, Gregson BA, Mendelow AD: A review of brain abscess surgical treatment--78 years: aspiration versus excision. *World Neurosurg.* 2011, 76:431-6. [10.1016/j.wneu.2011.03.048](https://doi.org/10.1016/j.wneu.2011.03.048)
- Arlotti M, Grossi P, Pea F, et al.: Consensus document on controversial issues for the treatment of infections of the central nervous system: bacterial brain abscesses. *Int J Infect Dis.* 2010, 14 Suppl 4:S79-92. [10.1016/j.ijid.2010.05.010](https://doi.org/10.1016/j.ijid.2010.05.010)
- Mut M, Hazer B, Narin F, Akalan N, Ozgen T: Aspiration or capsule excision? Analysis of treatment results for brain abscesses at single institute. *Turk Neurosurg.* 2009, 19:36-41.
- Tan WM, Adnan JS, Mohamad Haspani MS: Treatment outcome of superficial cerebral abscess: an analysis of two surgical methods. *Malays J Med Sci.* 2010, 17:23-9.
- Sarmast AH, Showkat HI, Kirmani AR, Bhat AR, Patloo AM, Ahmad SR, Khan OM: Aspiration versus excision: a single center experience of forty-seven patients with brain abscess over 10 years. *Neurol Med Chir (Tokyo).* 2012, 52:724-30. [10.2176/nmc.52.724](https://doi.org/10.2176/nmc.52.724)
- Gadgil N, Patel AJ, Gopinath SP: Open craniotomy for brain abscess: a forgotten experience? . *Surg Neurol Int.* 2013, 4:34. [10.4103/2152-7806.109522](https://doi.org/10.4103/2152-7806.109522)

25. Pandey P, Umesh S, Bhat D, et al.: Cerebellar abscesses in children: excision or aspiration?. *J Neurosurg Pediatr.* 2008, 1:31-4. [10.3171/PED-08/01/031](https://doi.org/10.3171/PED-08/01/031)
26. Mampalam TJ, Rosenblum ML: Trends in the management of bacterial brain abscesses: a review of 102 cases over 17 years. *Neurosurgery.* 1988, 23:451-8. [10.1227/00006123-198810000-00008](https://doi.org/10.1227/00006123-198810000-00008)
27. Mok CC, Yuen KY, Lau CS: Nocardiosis in systemic lupus erythematosus. *Semin Arthritis Rheum.* 1997, 26:675-85. [10.1016/s0049-0172\(97\)80003-0](https://doi.org/10.1016/s0049-0172(97)80003-0)
28. Cheng HM, Huang DF, Leu HB: Disseminated nocardiosis with initial manifestation mimicking disease flare-up of systemic lupus erythematosus in an SLE patient. *Am J Med.* 2005, 118:1297-8. [10.1016/j.amjmed.2005.03.027](https://doi.org/10.1016/j.amjmed.2005.03.027)
29. Yoneyama T, Yamakami I, Mine S, Saeki N, Yamaura A, Ozaki H, Nakazaki M: [Nocardial brain abscess: surgery and postoperative antibiotic therapy]. *No Shinkei Geka.* 2004, 32:457-62.
30. Stewart G, Basten A: Letter: lupus erythematosus and brain scanning. *Ann Intern Med.* 1975, 83:733-4. [10.7326/0003-4819-83-5-733](https://doi.org/10.7326/0003-4819-83-5-733)
31. Mc-Nab P, Fuentealba C, Ballesteros F, Pacheco D, Alvarez M, Dabanch J, Cona E: [Nocardia asteroides infection in a patient with systemic lupus erythematosus]. *Rev Med Chil.* 2000, 128:526-8. [10.4067/S0034-98872000000500011](https://doi.org/10.4067/S0034-98872000000500011)
32. Moitra RK, Auckland C, Cawley MI, Jones G, Cooper C: Systemic nocardiosis in a splenectomized patient with systemic lupus erythematosus: successful treatment using linezolid. *J Clin Rheumatol.* 2003, 9:47-50. [10.1097/01.RHU.0000049715.31325.72](https://doi.org/10.1097/01.RHU.0000049715.31325.72)
33. Kilincer C, Hamamcioglu MK, Simsek O, et al.: Nocardial brain abscess: review of clinical management. *J Clin Neurosci.* 2006, 13:481-5. [10.1016/j.jocn.2005.04.031](https://doi.org/10.1016/j.jocn.2005.04.031)
34. Justiniano M, Glorioso S, Dold S, Espinoza LR: Nocardia brain abscesses in a male patient with SLE: successful outcome despite delay in diagnosis. *Clin Rheumatol.* 2007, 26:1020-2. [10.1007/s10067-006-0262-x](https://doi.org/10.1007/s10067-006-0262-x)
35. Bashir H, Ranganathan P: An unusual case of cerebellar hemorrhage in a patient with systemic lupus erythematosus. *Arthritis Care Res (Hoboken).* 2010, 62:738-42. [10.1002/acr.20114](https://doi.org/10.1002/acr.20114)
36. Ueda Y, Yamamoto K, Watanabe K, Yamashita H, Ohmagari N, Mimori A: [Obstructive pneumonia and brain abscess due to Nocardia elegans in a patient with systemic lupus erythematosus]. *Kansenshogaku Zasshi.* 2014, 88:282-7. [10.11150/kansenshogakuzasshi.88.282](https://doi.org/10.11150/kansenshogakuzasshi.88.282)
37. Jeong JH, Moon SM, Park PW, et al.: Multiple brain abscesses caused by Nocardia asiatica in a patient with systemic lupus erythematosus: the first case report and literature review. *Ann Lab Med.* 2017, 37:459-61. [10.3343/alm.2017.37.5.459](https://doi.org/10.3343/alm.2017.37.5.459)
38. Barata CH, Oliveira DA, Colombo AL, Pereira CA: [Brain abscess caused by Nocardia sp in immunosuppressed patient]. *Rev Soc Bras Med Trop.* 2000, 33:609-12. [10.1590/s0037-86822000000600015](https://doi.org/10.1590/s0037-86822000000600015)
39. Wakhlu A, Agarwal V, Dabadghao S, Prasad KN, Nityanand S: Nocardiosis in patients of chronic idiopathic thrombocytopenic purpura on steroids. *J Assoc Physicians India.* 2004, 52:591-3.
40. Lai CC, Lee LN, Teng LJ, Wu MS, Tsai JC, Hsueh PR: Disseminated Nocardia farcinica infection in a uraemia patient with idiopathic thrombocytopenia purpura receiving steroid therapy. *J Med Microbiol.* 2005, 54:1107-10. [10.1099/jmm.0.46084-0](https://doi.org/10.1099/jmm.0.46084-0)
41. Frank M, Woschnagg H, Mölzer G, Finsterer J: Cerebellar nocardiosis and myopathy from long-term corticosteroids for idiopathic thrombocytopenia. *Yonsei Med J.* 2010, 51:131-7. [10.3349/ymj.2010.51.1.131](https://doi.org/10.3349/ymj.2010.51.1.131)