

Case Report

Vascular Anomaly in the Fallopian Canal Encountered Unexpectedly During Cochlear Implantation

Itay Chen¹, Jean-Yves Sichel¹, Eliel Ben-David², Ronen Perez¹¹Department of Otolaryngology-Head and Neck Surgery, Shaare Zedek Medical Center, Faculty of Medicine, Hebrew University of Jerusalem, Jerusalem, Israel²Department of Radiology, Shaare Zedek Medical Center, Faculty of Medicine, Hebrew University of Jerusalem, Jerusalem, Israel

ORCID IDs of the authors: I.C. 0000-0002-4998-1775; J.-Y.S. 0000-0002-4949-879X; E.B.-D. 0000-0001-7548-5725; R.P. 0000-0001-8682-6927.

Cite this article as: Chen I, Sichel J, Ben-David E, Perez R. Vascular anomaly in the fallopian canal encountered unexpectedly during cochlear implantation. *J Int Adv Otol.* 2021;17(6):574-576.

A 68-year-old male with progressive sensorineural hearing loss underwent left cochlear implant surgery. While developing the posterior tympanotomy and identifying the facial nerve mastoid segment, gentle stimulation by the nerve stimulator resulted in unexpected profuse venous bleeding. After achieving hemostasis with Surgicel and Spongostan, the posterior tympanotomy was extended exposing a large aberrant vein running parallel to the tympanic and mastoid segments of the facial nerve in the fallopian canal. Good exposure and careful palpation of the vein assisted in ruling out facial nerve hemangioma. An intraoperative decision to proceed with implantation, taking into account limited benefit from future magnetic resonance imaging, was taken. The patient had a temporary 3-month post-operative facial nerve weakness, probably from pressure applied during hemostasis. Auditory cochlear implant function was excellent. A larger than normal diameter of the tympanic and mastoid segments of the facial nerve was seen in re-reviews of the preoperative computed tomography. We believe drawing the readers' attention to this anomaly, which to the best of our knowledge has not been previously described, can assist in the choice of preoperative imaging and increase awareness of deviation from the norm of facial nerve diameter. In addition, knowledge of possible venous anomalies may aid surgeons in such intraoperative decisions.

KEYWORDS: Cochlear implantation, facial nerve, fallopian canal, vascular anomaly

INTRODUCTION

Cochlear implantation (CI) is a viable option for individuals with severe to profound hearing loss who do not benefit from hearing aids.¹ The reported possible relationship between hearing loss and dementia emphasizes the importance of CI in the elderly.² The objective of CI surgery is complete insertion of the electrode array to the scala tympani of the cochlea with minimal risk to the facial nerve (FN).³ As part of the candidates' presurgical evaluation, temporal bone imaging is obtained consisting of computed tomography (CT), magnetic resonance imaging (MRI), or both.⁴ In this report, we present a unique case in which a large aberrant vein running parallel to the tympanic and mastoid segments of the FN in the fallopian canal was encountered unexpectedly during CI surgery risking the FN. This anomaly, which to the best of our knowledge was not previously reported, posed questions relating to pre-operative imaging and intraoperative decisions. The case report was approved by the Shaare Zedek Medical Center Helsinki Committee.

CASE PRESENTATION

A 68-year-old male with bilateral progressive sensorineural hearing loss presented at our center for CI consultation. The patient successfully used bilateral hearing aids for most of his life, but in the years before presentation benefit from amplification became limited. According to audiometric tests, he was a suitable candidate for CI. The left ear was chosen for implantation due to poorer auditory function. A high-resolution temporal bone CT was obtained; it was interpreted by the surgeons and the neuro-radiologists as within normal limits. According to our center's protocol, an MRI is obtained only in the presence of anatomical abnormalities in the CT or in the total absence of auditory responses in order to assess the auditory nerve.

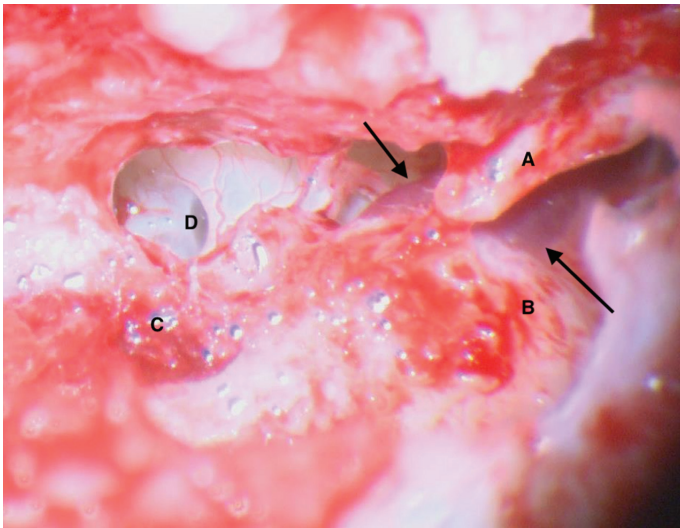


Figure 1. Intraoperative photograph showing the short process of incus (A), lateral semicircular canal (B), area of mastoid segment of the FN after bleeding control (C), round window (D), and enlarged vein accompanying the tympanic segment of the FN (arrows). FN, facial nerve.

Surgery was conducted under general anesthesia with FN monitoring (NIM-Response 3.0 System, Medtronic Xomed, Jacksonville, Florida). After elevating the skin flaps and drilling the processor bed, a mastoidectomy was performed exposing the lateral semicircular canal and incus short process. A posterior tympanotomy was developed carefully while identifying the mastoid segment of the FN. Following the FN inferiorly, the nerve area was noted to be mildly bluish and shiny. Gentle stimulation of the nerve in this area with the FN monitor stimulator resulted in profuse venous bleeding. The significant bleeding was controlled by applying pressure (in the vicinity of the FN) with Surgicel (Nu-Knit; Ethicon; Somerville, NJ) and Spongostan (Absorbable Haemostatic Gelatin Sponge, Johnson and Johnson Ethicon Inc, USA). After hemostasis was achieved, the posterior tympanotomy was completed exposing the round window. A large blood vessel running along the tympanic segment of the FN was seen (Figure 1). Extending exposure of the facial recess demonstrated that the intratympanic vessel was continuous with the vein along the mastoid segment in the area in which we encountered the bleeding. In view of this surprising and unique anatomic abnormality, an

intraoperative decision, whether to proceed with implantation while taking into account the possible differential diagnosis of FN hemangioma, had to be taken. Careful gentle palpation of the vein running along the tympanic segment was helpful in our decision to proceed with the implantation. Stimulation of the FN with 0.3 mV in the tympanic segment (proximal to the area of bleeding) resulted in monitor response confirming the continuity of the nerve. Subsequently, the CI electrode array was fully inserted through the round window.

Post-operative temporary FN weakness (House Brackmann III), probably resulting from the pressure applied during hemostasis, was seen on the left implanted side and completely recovered after 3 months. Upon follow-up, the patient's post CI hearing function was very good, and he was extremely satisfied.

DISCUSSION

The first issue worth discussing in this case relates to preoperative imaging. Conducting an MRI or CT venography in addition to CT may have been helpful in preventing the unexpected finding and lower morbidity. In the post-surgical re-review of the CT, we found that the FN tympanic segment diameter was 2.3 mm on the left and 1.1 mm on the right (Figure 2A). The mastoid segment diameter was 2.1 mm on the left and 1.4 mm on the right (Figure 2B). In the literature, the average diameter of the FN tympanic segment and the mastoid segment is reported to be 1.093 mm (± 0.573) and 1.332 mm (± 0.649), respectively.⁵ The possible diagnosis of persistent stapedia artery (PSA) was raised but was found to be unlikely due to (a) the presence of a normal ipsilateral foramen spinosum which may be absent or hypoplastic in PSA (Figure 3), (b) the larger than normal diameter of the mastoid segment of the fallopiian canal (2.1 mm) which is not typical of PSA, and (c) the absence of a blood vessel and canal originating from the internal carotid artery which may be present in PSA as described by Lindemann et al.⁶ This case emphasizes the importance of assessing the diameter of the facial nerve. When a deviation from the norm is noted, the possibility of obtaining additional imaging such as CT venography or MRI before surgery should be considered.

The second issue relates to the intraoperative decision whether to proceed with implantation. One of our main concerns was possible

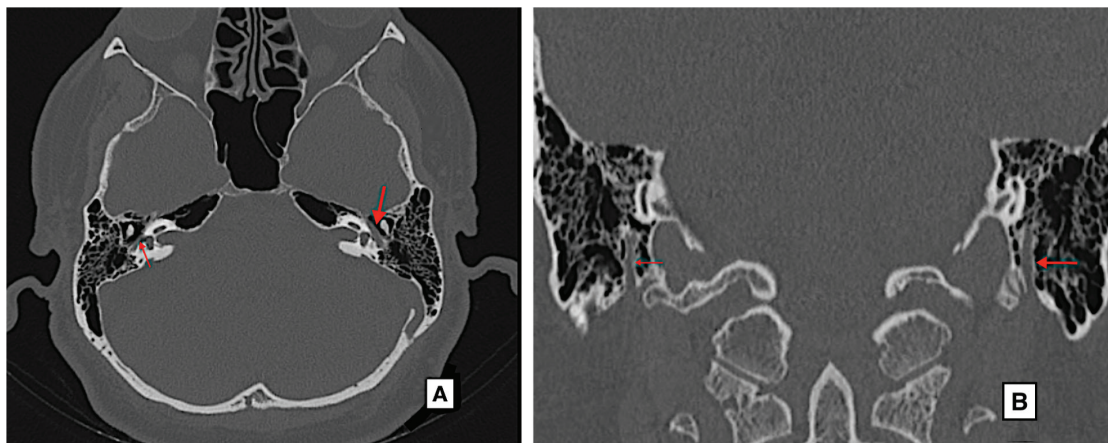


Figure 2. (A) CT, thin slice, bone reconstruction algorithm and window, axial image: Left facial nerve tympanic segment (large arrow) is wider than the right (small arrow). (B) CT, thin slice, bone reconstruction algorithm and window, coronal image: Left facial nerve mastoid segment (large arrow) is wider than the right (small arrow). CT, computed tomography.

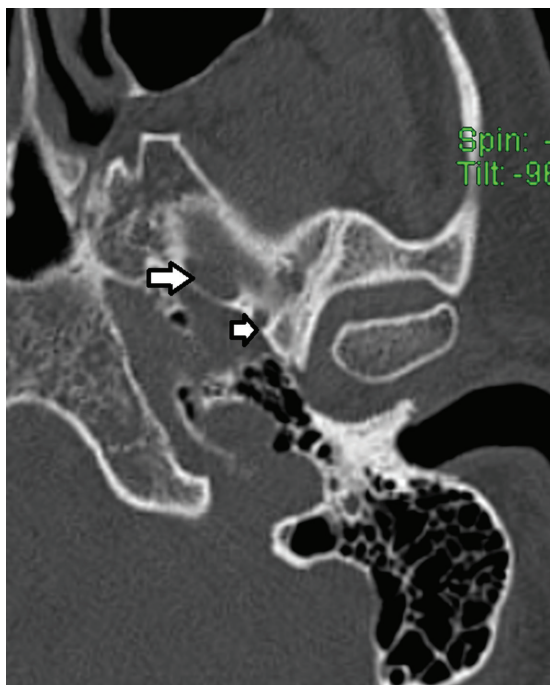


Figure 3. CT, thin slice, bone reconstruction algorithm and window, axial image. Foramen spinosum (small arrow), foramen ovale (large arrow).

differential diagnosis such as FN hemangioma, knowing that implantation would limit the use and yield of MRI for future follow-up and diagnosis. Fortunately, proceeding with implantation proved to be the correct decision. After the follow-up of 42 months, the patient is doing well with respect to auditory and facial nerve function. A CT conducted recently, 3 years after the implantation (mainly due to the patient's interest in a contra-lateral second implant), was similar to the preoperative imaging in terms of fallopian canal anatomy.

CONCLUSION

A rare venous anatomical anomaly in the fallopian canal which was encountered unexpectedly is described. We believe reporting this case and drawing the attention of the readers to the possibility of

such an anomaly can (a) assist the CI team in the choice of preoperative imaging and increase awareness to deviation from the norm of FN diameter, (b) aid CI surgeons in making the correct intraoperative decision whether to proceed with implantation.

Ethics Committee Approval: Ethics committee approval was received for this study from the Ethics Committee of Shaare Zedek Medical Center Helsinki.

Informed Consent: N/A.

Peer Review: Externally peer-reviewed.

Author Contributions: All authors significantly contributed to the manuscript and approved the final version.

Conflict of Interest: The authors have no conflict of interest to declare.

Financial Disclosure: The authors declared that this study has received no financial support.

REFERENCES

1. Perez R, Kishon-Rabin L. Cochlear implants-pediatric. In: Kountakis SE, ed. *Encyclopedia of Otolaryngology, Head and Neck Surgery*. Berlin/Heidelberg, Germany: Springer-Verlag; 2013.
2. Lin FR, Yaffe K, Xia J, et al. Hearing loss and cognitive decline in older adults. *JAMA Intern Med*. 2013;173(4):293-299.
3. Topsakal V, Matulic M, Assadi MZ, Mertens G, Rompaey VV, Van de Heyning P. Comparison of the surgical techniques and robotic techniques for cochlear implantation in terms of the trajectories toward the inner ear. *J Int Adv Otol*. 2020;16(1):3-7.
4. Tamplen M, Schwalje A, Lustig L, Alemi AS, Miller ME. Utility of preoperative computed tomography and magnetic resonance imaging in adult and pediatric cochlear implant candidates. *Laryngoscope*. 2016;126(6):1440-1445.
5. Vianna M, Adams M, Schachern P, Lazarini PR, Paparella MM, Cureoglu S. Differences in the diameter of facial nerve and facial canal in Bell's palsy: a 3-dimensional temporal bone study. *Otol Neurotol*. 2014;35(3):514-518.
6. Lindemann TL, Austin KL, Gadre AK. Successful cochlear implantation in the face of persistent stapedia artery: surgical technique and imaging features. *J Int Adv Otol*. 2020;16(3):463-466.