


Silicone adhesive multilayer foam dressings for preventing facial pressure injuries in COVID-19 patients in prone position

Journal of the Intensive Care Society
2022, Vol. 0(0) 1–3
© The Intensive Care Society 2022
Article reuse guidelines:
sagepub.com/journals-permissions
DOI: 10.1177/17511437221079122
journals.sagepub.com/home/jics


Pia Otto¹, Tobias Großkreutz¹ and Stefan Köberich² 

Abstract

The development of facial pressure injury (PI) during prone position is frequently described. During the COVID-19 pandemic, the number of patients with facial PIs increased. This quality improvement project describes the effectiveness of using silicone adhesive multilayer foams for preventing facial PIs in COVID-19 patients in need of prone position therapy. After introduction of foam dressing on chin and forehead to the standard protocol procedures for PI prevention, the decrease in number of patients developing facial PIs was statistically significant. Based on these results, the use of silicone adhesive multilayer foam will be implemented as a standard procedure for facial PIs prevention.

Keywords

COVID-19, acute respiratory distress syndrome, prone position, pressure ulcer

Introduction

Facial pressure injuries (PI) are common in patients with acute respiratory distress syndrome (ARDS) in need of prone position therapy.^{1,2} In our institution, the standard protocol for facial PI prevention for patients in prone position is to position the face in a disposable polyurethane foam prone head positioner with minimal head turning every 1 to 2 hours. However, during the first and second wave of the COVID-19 pandemic in Germany, we recognized a surge of facial PIs in prone positioned COVID-19 patients. Based on the result of a non-clinical study, case reports and expert recommendations,^{3–6} we changed our PI prevention management. In addition to the standard protocol, we started to use silicone adhesive multilayer foam (Mepilex[®] border flex) for preventing PIs at chin and forehead (Figure 1) beginning from 01/2021 at one of our ICUs. To evaluate the effectiveness of the new prevention management on PI development at chin and forehead, we performed a retrospective patient chart analysis.

Method

All patients with COVID-19 and with mild to severe ARDS, admitted to the specific ICU until 05/2021 and with at least one documented pronation cycle were included in this retrospective chart analysis. Patients were excluded if they were transferred from other ICUs of our institution because some of the ICUs started also using foam dressing for preventing PIs which could be seen as a bias in our analysis.

The following data were extracted: age, gender, BMI, number of pronation cycles and total time of prone position, ARDS severity and number of PIs on chin and/or forehead.

Data are displayed as mean and standard deviation or number and percentage based on scale measure. Differences between groups were analysed using t-test or chi-square test.

Results

We could include 49 patients in our patient chart analysis. Patients' characteristics are displayed in Table 1.

Overall, 23 out of 49 patients (46.9%) developed a PI at the chin and/or forehead. In the group where a silicone adhesive multilayer foam was not used (no-foam group), 17 out of 25 patients (68.0%) developed a PI; in the group where a foam dressing was applied (foam group), 6 out of 24 patients (25.0%) developed a PI ($p = 0.003$). Differences could be observed in developing chin or forehead PIs. Eleven out of 25 patients (44.0%) in the no-foam group developed a PI at the forehead compared to five out of 24 patients (20.8%) in the foam group ($p = 0.84$). Statistically significant differences could be observed regarding the development of PIs at the chin. Eleven out of 25 patients (44.0%) in the no-foam group developed a PI compared to 4 out of 24 patients (16.7%) in the foam group ($p = 0.038$) (Figure 2).

Discussion

Our retrospective patient chart analysis revealed a statistically significant reduction in the development of PIs at chin and/or forehead after applying a silicone adhesive multilayer foam dressing on chin and forehead during prone

¹Department of Anesthesiology and Critical Care, Faculty of Medicine, Medical Center - University of Freiburg, Freiburg, Germany

²Nursing Direction, Faculty of Medicine, Medical Center - University of Freiburg, Freiburg, Germany

Corresponding author:

Stefan Köberich, Nursing Direction, Faculty of Medicine, Medical Center, University of Freiburg, Hugstetter Str. 55, Freiburg 79106, Germany.
Email: stefan.koeberich@uniklinik-freiburg.de

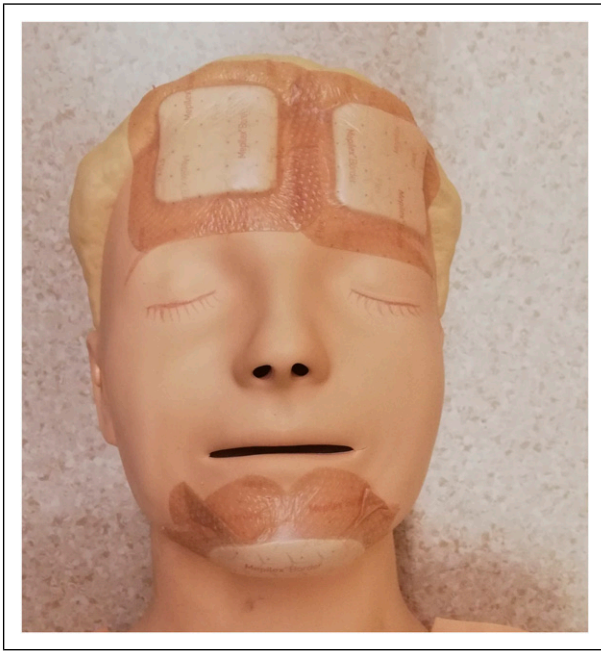


Figure 1. Illustration of how to apply silicone adhesive multilayer foams to a patient's face.

position. Our results are in line with those of other studies and case reports.^{5,6}

According to Peko and colleagues, silicone adhesive multilayer foam dressings are able to prevent the development of PI due to cushioning the skin area at risk, absorbing shear loads within the dressing and alleviating the bodyweight loads.³ These foam dressings have also been applied to other body areas, for example, the sacral region or the heels, and have shown protective effects in the development of PIs.^{7,8}

Even though a multilayer foam dressing seems to be able to prevent PIs in the facial region, other influencing factors on PI development should be carefully considered when turning the patient in prone position. Some of these factors are not influenceable (e.g. the amount of vasopressive drugs) but those that could be influenced should be subject of permanent quality control. For example, some clinical experts recommend that turning the patient should be executed by trained staff only and that the head should be turned on a regular basis.^{2,9} Both measures could be trained and improved.

Preventing PIs in prone-positioned patients is a great challenge and should be a subject of further research.

Table 1. Patients' characteristics.

	All patients (n = 49)	Patients without foam dressing (n = 25)	Patients with foam dressing (n = 24)	p
Age (years)	57.8 (± 9.4)	58.3 (± 8.4)	57.3 (± 10.4)	0.71
BMI (kg/m ²)	29.6 (± 5.2)	29.4 (± 6.0)	29.9 (± 4.5)	0.77
Sex				
Female	12 (24.5%)	4 (16.0%)	8 (33.3%)	0.16
Male	37 (75.5%)	21 (84.0%)	16 (66.7%)	
ARDS severity				
Mild/Moderate	9 (18.4%)	4 (16.0%)	5 (20.8%)	0.73
Severe	40 (81.6%)	21 (84.0%)	40 (79.2%)	
Prone position				
Total pronation cycles	7.8 (± 5.0)	7.6 (± 4.8)	8.1 (± 5.3)	0.72
Total time of prone position (minutes)	7374.9 (± 4835.6)	7169.0 (± 4795.7)	7598.7 (± 4976.4)	0.76

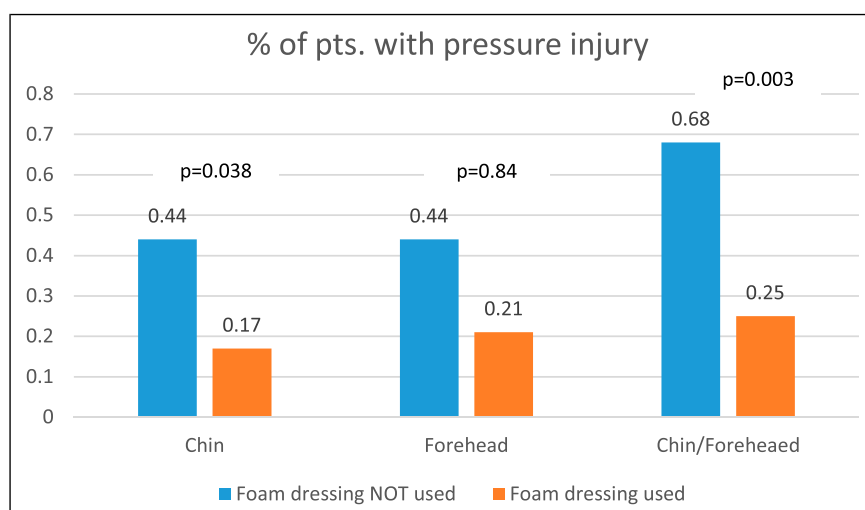


Figure 2. Distribution of pressure injuries at different body areas using and not using multilayer foam dressings.

Conclusion

Applying silicone adhesive multilayer foam dressings on facial skin areas at risk for developing PIs seems to be a feasible and effective measure for PI prevention in COVID-19 patients with ARDS and with the need of prone position therapy.

Declaration of conflicting interests

The author(s) declared no potential conflicts of interest with respect to the research, authorship, and/or publication of this article.

Funding

The author(s) received no financial support for the research, authorship, and/or publication of this article.

ORCID iD

Stefan Köberich  <https://orcid.org/0000-0001-6171-382X>

References

1. Binda F, Galazzi A, Marelli F, et al. Complications of prone positioning in patients with COVID-19: a cross-sectional study. *Intensive Crit Care Nurs* 2021; 67: 103088.
2. Jiang ST, Fang CH, Chen JT, et al. The face of COVID-19: facial pressure wounds related to prone positioning in patients undergoing ventilation in the intensive care unit. *Otolaryngol Head Neck Surg* 2021; 164: 300–301.
3. Peko L, Barakat-Johnson M, and Gefen A. Protecting prone positioned patients from facial pressure ulcers using prophylactic dressings: a timely biomechanical analysis in the context of the COVID-19 pandemic. *Int Wound J* 2020; 17: 1595–1606.
4. Barakat-Johnson M, Carey R, Coleman K, et al. Pressure injury prevention for COVID-19 patients in a prone position. *Wound Pract Res J Aust Wound Manag Assoc* 2020; 28: 50.
5. Kim RS, and Mullins K. Preventing facial pressure ulcers in acute respiratory distress syndrome (ARDS). *J Wound Ostomy Cont Nurs* 2016; 43: 427–429.
6. Jackson ME, Verano JX, Fry JE, et al. Skin preparation process for the prevention of skin breakdown in patients who are intubated and treated with rotoprone. *Respir Care* 2012; 57: 311–314.
7. Hahnel E, Genedy ME, Tomova-Simitchieva T, et al. The effectiveness of two silicone dressings for sacral and heel pressure ulcer prevention compared with no dressings in high-risk intensive care unit patients: a randomized controlled parallel-group trial. *Br J Dermatol* 2020; 183: 256–264.
8. Beeckman D, Fourie A, Raepsaet C, et al. Silicone adhesive multilayer foam dressings as adjuvant prophylactic therapy to prevent hospital-acquired pressure ulcers: a pragmatic non-commercial multicentre randomized open-label parallel-group medical device trial. *Br J Dermatol* 2021; 185: 52–61.
9. Perrillat A, Foletti JM, Lacagne AS, et al. Facial pressure ulcers in COVID-19 patients undergoing prone positioning: how to prevent an underestimated epidemic? *J Stomatol Oral Maxillofac Surg* 2020; 121: 442–444.