

Access this article online

Quick Response Code:



Website:

www.jorthodsci.org

DOI:

10.4103/jos.jos_148_21

Anthropometric measurements of peri-oral region in a sample of Iraqi thalassemic patients

Riad Al-Tae, Aqeel Ibrahim Lazim Al-Saedi¹ and Mohammed Nahidh²

Abstract:

OBJECTIVES: Thalassemia, one of the most widespread autosomal recessive disorders, is characterized by anomalies in the synthesis of hemoglobin beta chains and is frequently coupled with variable craniofacial characteristics. Thalassemic patients suffer from severe anemia, which triggers several defense mechanisms in the body, such as bone marrow expansion, which forces the bones to expand, resulting in craniofacial bone deformities. This study aims to assess and compare the orofacial dimensions of β -thalassemia patients with those of a control group across similar ages and gender.

MATERIALS AND METHODS: Three hundred Iraqi individuals agreed to participate in this study (150 non-thalassemic and 150 thalassemic patients with an equal distribution of genders). A well-trained researcher carried out five anthropometric measurements by using an electronic digital caliper. Gender and group differences were tested using an independent sample *t* test.

RESULTS: Mouth width showed clinical and statistically significant group differences among all measurements in the study group.

CONCLUSIONS: All measurements except mouth width showed nonsignificant clinical group differences.

Keywords:

Orofacial measurements, soft tissues, thalassemia major

Introduction

Thalassemia major is an inherited blood disease recognized by the production of abnormal hemoglobin products and was first described by Dr. Thomas Cooley in 1925.^[1] Hemoglobin includes alpha and beta chains, and it is important in properly oxygenating the body. The major reason behind thalassemia is the faulty production of alpha or beta chains.^[2] In thalassemic patients, hemoglobin levels fall below the healthy threshold.^[3]

Thalassemia, in general, has two chief forms: alpha thalassemia and beta thalassemia. Each form can be divided

into subcategories.^[4] Thalassemic patients can be treated in relation to the stage of severity of their condition.^[5] For mild cases of thalassemia, patients may simply suffer from mild anemia and iron deficiency; in severe cases, death may be anticipated. Most frequently, blood transfusions are used to manage patients with thalassemia as blood transfusions permit these individuals' bloodstreams to be inundated with sufficient quantities of healthy and normal hemoglobin.^[6]

Bone marrow is considered central to body hematopoiesis. In response to anemia, it activates and increases in size. Bone marrow expansion or overgrowth, particularly of the skull, is considered a systemic symptom of esthetic concern. As

This is an open access journal, and articles are distributed under the terms of the Creative Commons Attribution-NonCommercial-ShareAlike 4.0 License, which allows others to remix, tweak, and build upon the work non-commercially, as long as appropriate credit is given and the new creations are licensed under the identical terms.

For reprints contact: WKHLRPMedknow_reprints@wolterskluwer.com

How to cite this article: Al-Tae R, Al-Saedi AI, Nahidh M. Anthropometric measurements of peri-oral region in a sample of Iraqi thalassemic patients. *J Orthodont Sci* 2022;11:4.

Department of Oral and Maxillofacial Surgery, College of Dentistry, Almaaqaq University, ¹Department of Oral Diagnosis, College of Dentistry, University of Basrah, Basrah, ²Department of Orthodontics, College of Dentistry, University of Baghdad, Baghdad, Iraq

Address for correspondence:

Prof. Mohammed Nahidh, College of Dentistry, University of Baghdad, Baghdad, Iraq. E-mail: m_nahidh79@yahoo.com

Submitted: 28-May-2021

Revised: 12-Jun-2021

Accepted: 20-Oct-2021

Published: 28-Jan-2022

wide head and facial bones, such as the maxilla, have increased activity in thalassemia major patients, the deformation of bones in this area of the head and face causes abnormalities in hard tissue and consequently in soft tissue.^[7]

The major features in these patients are facial dysmorphism and malocclusion. Changes in the craniofacial bones can affect the hard and soft tissues and present with classical “chipmunk facies” or a “rodent-like” appearance.^[7] The features of chipmunk facies are characterized by frontal bossing, a depressed nasal bridge, a partially obliterated maxillary sinus, maxillary hypertrophy with protrusion and spacing of the upper incisors, increased overjet, reduced overbite, and class II malocclusion with reduced ramus height.^[8-10]

In Iraq, only three papers have studied the skeletal, soft tissue, and dental patterns of thalassemic patients,^[11-13] and the direct anthropometric analysis of such cases has been assessed only in a few studies worldwide.^[2,7,14] Therefore, this study was conducted to evaluate and compare some orofacial anthropometric measurements in a sample of thalassemic patients from southern Iraq.

Materials and Methods

This study was approved by the ethical committee of the College of Dentistry, Basrah University (Ref No. 3, Jan. 2020).

One hundred and fifty Iraqi patients suffering from β -thalassemia major, as diagnosed by a specialized hematologist by using hemoglobin electrophoresis at the Center of Hereditary Blood Diseases in Basrah, agreed to participate in this study. They included 75 males and 75 females with ages ranging between 20 and 40 years old. A control sample of equivalent number, ages, and gender free from craniofacial abnormalities and facial surgery were recruited as well.

A well-trained orthodontist measured the orofacial parameters by using a special electronic digital sliding caliper (Mitutoyo, Japan) with minimal pressure to the soft tissues in both the study and control groups. The following facial landmarks [Figure 1] were used in this study:^[15,16]

1. Subnasale (sn): The point where the lower margin of the nasal septum (columella) meets the integument of the upper lip in the mid-sagittal plane
2. Labrale superior (ls): The most anterior point of the upper lip. It is the point in the mid-sagittal plane cut by a tangent drawn at the highest elevation of the upper margin of the integumental lip
3. Labrale inferior (li): The point on the lower margin

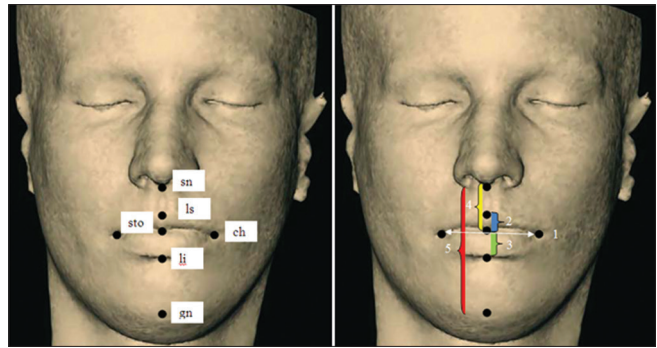


Figure 1: Landmarks and measurements used in the study

4. Stomion (sto): The point where the slit of the mouth with closed lips cuts the mid-sagittal plane
5. Chelion (ch): The point in the mouth opening where the lateral margins of the upper and lower lips meet (i.e., the corners of the mouth)
6. Gnathion (gn): The midpoint between the soft tissue pogonion (the most prominent or anterior point on the chin bony profile) and menton (lowest point on the contour of the soft tissue chin).

The orofacial measurements taken in this study [Figure 1] included:^[2,7,14]

1. Mouth width (ch-ch): The distance between the right and left chelions.
2. Height of upper vermillion (ls-sto): The distances between the stomion and labrale superior.
3. Height of lower lip vermilions (sto-li): The distances between the stomion and labrale inferior.
4. Height of the total upper lip (sn-sto): The distance between subnasale and stomion.
5. Lower facial height (sn-gn): The distance between subnasale and gnathion.

The analysis of the gathered data was performed using SPSS software version 25. Intra- and inter-examiner reliability was tested using the intra-class correlation coefficient. The normality of the data distribution was examined using the Shapiro–Wilk test. Gender and group differences were studied using an independent sample *t* test. Probability values of more than 0.05 were considered nonsignificant.

Results

Intra- and inter-examiner reliability indicated excellent reliability (ICC = 0.95 and 0.9, respectively). The data were normally distributed, as indicated by Shapiro–Wilk test.

The descriptive statistics and gender differences for the measured variables in the control and study groups are presented in Tables 1 and 2. Generally, there

were significant gender differences in both groups for all variables except upper lip vermilion height in the control group, which showed a nonsignificant difference.

The differences between the control and study groups are presented in Table 3 for both genders and the total sample. There were significant differences in some variables and nonsignificant differences in others. Reviewing the mean values revealed an approximation between both groups, and all differences were statistically significant except in the width of the mouth which showed clinical and statistical differences [Table 3].

Discussion

This study is considered the first Iraqi study concerning the anthropometric analysis of some orofacial dimensions in thalassemic patients in comparison to a control group.

Evaluation of the facial measurements can be considered of importance in forensic medicine, orthodontics, and prosthodontics.^[17]

The age of the sample participants ranged between 20 and 40 years to minimize the effect of growth on the measurements.^[18]

Table 1: Descriptive statistics and gender differences of the measurements in the control group

Parameters (mm.)	Descriptive statistics				Gender differences	
	Males		Females		t test	P
	Mean	S.D.	Mean	S.D.		
Mouth width	52.060	3.368	45.413	3.901	11.169	0.000
Height of upper lip vermilions	10.840	1.741	11.068	1.401	-0.884	0.378
Height of lower lip vermilions	10.365	1.664	10.920	1.334	-2.252	0.026
Height of the total upper lip	23.473	3.380	21.344	2.522	4.372	0.000
Lower facial height	63.112	6.887	58.803	4.283	4.602	0.000

P>0.05=Nonsignificant difference, 0.05 ≥ P>0.01=Significant difference, P≤0.01=Highly significant

Table 2: Descriptive statistics and gender differences of the measurements in the study group

Parameters (mm.)	Descriptive statistics				Gender difference	
	Males		Females		t test	P
	Mean	S.D.	Mean	S.D.		
Mouth width	45.984	4.712	41.944	6.114	4.532	0.000
Height of upper lip vermilions	11.393	4.413	9.733	1.454	3.094	0.002
Height of lower lip vermilions	11.708	2.201	10.461	1.162	4.338	0.000
Height of the total upper lip	23.469	2.816	21.425	2.881	4.394	0.000
Lower facial height	64.665	5.799	59.096	5.715	5.924	0.000

P>0.05=Nonsignificant difference, 0.05 ≥ P>0.01=Significant difference, P≤0.01=Highly significant

Table 3: Descriptive statistics and group differences of the measurements in both genders and the total samples

Genders	Parameters (mm.)	Descriptive statistics				Group difference	
		Control		Thalassemia		t test	P
		Mean	S.D.	Mean	S.D.		
Males	Mouth width	52.060	3.368	45.984	4.712	12.550	0.000
	Height of upper lip vermilions	10.840	1.741	11.393	4.413	-1.010	0.314
	Height of lower lip vermilions	10.365	1.664	11.708	2.201	-4.215	0.000
	Height of the total upper lip	23.473	3.380	23.469	2.816	0.008	0.994
	Lower facial height	63.112	6.887	64.665	5.799	-1.494	0.137
Females	Mouth width	45.413	3.901	41.944	6.114	5.808	0.004
	Height of upper lip vermilions	11.068	1.401	9.733	1.454	5.724	0.000
	Height of lower lip vermilions	10.920	1.334	10.461	1.162	2.245	0.026
	Height of the total upper lip	21.344	2.522	21.425	2.881	-0.184	0.854
	Lower facial height	58.803	4.283	59.096	5.715	-0.356	0.723
Total	Mouth width	48.737	4.931	43.964	5.805	7.674	0.000
	Height of upper lip vermilions	10.954	1.579	10.563	3.379	1.283	0.201
	Height of lower lip vermilions	10.643	1.528	11.085	1.862	-2.247	0.025
	Height of the total upper lip	22.409	3.158	22.447	3.018	-0.108	0.914
	Lower facial height	60.957	6.111	61.881	6.382	-1.280	0.202

P>0.05=Nonsignificant difference, 0.05 ≥ P>0.01=Significant difference, P≤0.01=Highly significant

Reviewing the literature, only three Iraqi studies have been conducted to compare the skeleto-dental and soft tissue profiles of thalassemic patients with a control group.^[11-13]

Regarding the present study, all of the measured parameters were significantly higher in males in the control group, except for the lower lip vermilion height [Table 1]. This is logical as males have greater liner dimensions than females do. The same was true for the thalassemic patients [Table 2].

The measurements of the control and study groups are presented in Table 3 for both genders and the total samples. Considering the male group, the width of the mouth and the height of the upper lip vermilion differed significantly between the control and study groups, while the other parameters showed nonsignificant differences. Karakas *et al.*^[7] found nonsignificant differences in the mouth width and the height of the upper lip, while Gupta and Arora^[14] found a significant difference in the mouth width and the height of the upper lip.

In the female group, the mouth width and heights of the upper and lower lip vermilions differed significantly between the control and study females with nonsignificant differences being present for the remaining measurements. Karakas *et al.*^[7] found a nonsignificant difference in mouth width and a significant difference in the height of the upper lip. Gupta and Arora^[14] found a significant difference in the mouth width and the height of the upper lip.

In the total samples, only the mouth width and the height of the upper lip vermilion differed significantly. Karakas *et al.*^[7] found a significant difference in mouth width and the height of the upper lip. In contrast, Naimi *et al.*^[2] found a nonsignificant difference in the mouth width, the height of the upper vermilion, and the lower facial height, while the upper lip heights differed significantly. Moreover, Gupta and Arora^[14] found a significant difference in the width of the mouth and total upper lip height.

The differences among various studies can be attributed to the difference in sample size and ethnic groups studied, participants' ages, the duration of symptoms, and the severity of the cases regarding their underlying skeletal and dental discrepancies.

Al-Ani^[11] attributed the shorter upper-lip length in thalassemic patients of both genders to the severity of class II sagittal skeletal patterns in addition to the role of the vertical growth tendency and protrusion of the front teeth that evert the upper lip.^[19,20] The vertical growth

pattern of thalassemic patients is indicated by the slightly insignificant increase in lower facial height.

In Table 3, the differences between the mean values of the measurements between the study and control groups were clinically insignificant except for the mouth width due to the "rodent-like" facial appearance caused by frontal bossing, prominent cheek (malar) bones, saddle nose, maxillary protrusion, mandibular retrusion, flaring of the maxillary anterior teeth, lip incompetence, and malocclusion. Thus, the statistically significant group difference is not important from a clinical point of view.

Conclusions

In conclusion, all of the anthropometric measurements showed nonsignificant differences between the normal and thalassemic subjects except for the mouth width, which showed clinical and statistical group differences.

These findings for thalassemic patients could be important for orthodontists to identify the causes of deformity and modify treatments to achieve maximum esthetic and functional results and for oral-maxillofacial surgeons during surgical interventions.

Ethics committee approval

Ethics committee approval was received for this study from Basrah University, College of Dentistry Ethics Committee on researches (No. 3/5-1-2020).

Declaration of patient consent

Informed consent was obtained from patients who participated in this study.

Financial support and sponsorship

Nil.

Conflicts of interest

There are no conflicts of interest.

References

1. Cao A, Galanello R. Beta-thalassemia. *Genet Med* 2010;12:61-76.
2. Naimi AJ, Bolourian S, Mohammadzadeh M, Farahmand M, Ghanbari F, Samiee S. Investigating the relationship between major thalassemia diseases with anthropometric sizes of head and facial soft tissue. *Biosci Biotech Res Comm* 2017;10:233-40.
3. Habibian N, Alipour A, Rezaianzadeh A. Association between iron deficiency anemia and febrile convulsion in 3- to 60-month-old children: A systematic review and meta-analysis. *Iran J Med Sci* 2014;39:496-505.
4. Muncie HL Jr, Campbell JS. Alpha and beta thalassemia. *Am Fam Physician* 2009;80:339-44.
5. Bernaudin F, Verlhac S, Chevret S, Torres M, Coic L, Arnaud C, *et al.* G6PD deficiency, absence of alpha thalassemia, and hemolytic rate at baseline are significant independent risk factors for abnormally high cerebral velocities in patients with sickle cell anemia. *Blood* 2008;112:4314-7.

6. Helmi N, Bashir M, Shireen A, Ahmed IM. Thalassemia review: Features, dental considerations and management. *Electron Physician* 2017;9:4003-8.
7. Karakas S, Tellioglu AM, Bilgin M, Omurlu IK, Caliskan S, Coskun S. Craniofacial characteristics of thalassemia major patients. *Eurasian J Med* 2016;48:204-8.
8. Hattab FN. Thalassemia major and related dentomaxillofacial complications: Clinical and radiographic overview with reference to dental care. *Int J Experiment Dent Sci* 2017;6:95-104.
9. Abu Alhaija ESJ, Hattab FN, Al-Omari MAO. Cephalometric measurements and facial deformities in subjects with β -thalassaemia major. *Eur J Orthod* 2002;24:9-19.
10. Toman HA, Hassan R, Hassan R, Nasir A. Craniofacial deformities in transfusion-dependent thalassemia patients in Malaysia: Prevalence and effect of treatment. *Southeast Asian J Trop Med Public Health* 2011;42:1233-40.
11. Al-Ani RA. Soft tissue profile analysis for Iraqi patients with β -Thalassemia major. *Mustansiria Dent J* 2008;5:187-93.
12. Al-Ani RA, Ghaib NH. Skeleto-dental features analysis of Iraqi Thalassemic patients aged 13-15 years (Cross sectional cephalometric study). *Iraqi Orthod J* 2011;7:19-23.
13. Thajeel AT, Al-Taei JA. Cephalometric analysis of craniofacial deformity of β -thalassemic major by using computed tomography. *J Bagh Coll Dentistry* 2013;25:39-43.
14. Gupta G, Arora M. Association of orofacial features of β -thalassemia major patients. *J Evolution Med Dent Sci* 2018;7:3409-11.
15. Jacobson A, Jacobson RL. *Radiographic Cephalometry: From Basics to 3-d Imaging*. 2nd ed. Chicago: Quintessence Publishing; 2006.
16. Meneghini F, Biondi P. *Clinical Facial Analysis; Elements, Principles, and Techniques*. 2nd ed. Berlin: Springer-Verlag Berlin Heidelberg; 2012.
17. Basnet BB, Parajuli PK, Singh RK, Suwal P, Shrestha P, Baral D. An anthropometric study to evaluate the correlation between the occlusal vertical dimension and length of the thumb. *Clin Cosmet Investig Dent* 2015;7:33-9.
18. Littlewood SJ, Mitchell L. *An Introduction to Orthodontics*. 5th ed. Oxford: Oxford University Press; 2019.
19. Amini F, Jafari A, Eslamian L, Sharifzadeh S. A cephalometric study on craniofacial morphology of Iranian children with beta-thalassemia major. *Orthod Craniofac Res* 2007;10:36-44.
20. Takriti M, Dashash M. Craniofacial parameters of Syrian children with b-thalassemia major. *J Investig Clin Dent* 2011;2:135-43.