

Case Report

Large oral lipoma: Case report and literature review in Iran

Ahmad Motagi¹, Atousa Aminzadeh², Seyed M. Razavi³

¹Departments of Oral Surgery, ²Oral Pathology, School of Dentistry, Khorasgan (Isfahan) Branch, Islamic Azad University, ³Torabinejad Dental Research Center and Department of Oral and Maxillofacial Pathology, School of Dentistry, Isfahan University of Medical Sciences, Isfahan, Iran.

ABSTRACT

Lipoma is a benign mesenchymal tumor of fat with uncertain pathogenesis. Although the most common mesenchymal neoplasm in trunk and proximal portions of the extremities, it is rarely seen in the oral cavity. Oral lipomas are clinically soft, smooth-surfaced nodular masses that mostly are less than 3 cm in size. Typically the tumor is asymptomatic unless bitten or become noticeable because of their size. The buccal mucosa and buccal vestibule are the most common intraoral sites and account for 50% of all cases. Reported here is a relatively large lipoma of buccal mucosa that was treated surgically under local anesthesia. In an 18-month postsurgical follow up no complication or recurrence has occurred. This case will also be compared to intraoral lipomas reported in Iranian population. As lipomas are usually smaller than 3 cm in diameter, lipoma with the size reported, is of clinical importance. Since the large lipomas are in differential diagnosis with other, even malignant, mesenchymal, or salivary gland tumors. Thus, this case report recommends clinical awareness in diagnosis of large intraoral soft tissue lesions.

Key Words: Buccal mucosa, fatty tumor, lipoma, mouth mucosa

Received: September 2011
Accepted: January 2012

Address for correspondence:
Assistant Professor, Atousa
Aminzadeh, Department
of Oral Pathology, School
of Dentistry, Khorasgan
(Isfahan) Branch, Islamic
Azad University, Isfahan,
Iran.
E-mail: a.aminzadeh@
khuif.ac.ir

INTRODUCTION

Lipoma is a benign mesenchymal tumor of fat. This tumor is rarely seen in the oral cavity, although by far it represents the most common mesenchymal neoplasm elsewhere such as trunk, shoulders, neck, and axilla. Although the etiology and pathogenesis of lipomas is not well known, lipomas appear to be more common in obese people.^[1]

Clinically oral lipomas are seen as yellow (deeper tumors may appear pink) soft, smooth-surfaced nodular masses less than 3 cm in size that might be sessile or pedunculated. Typically the tumor is asymptomatic unless bitten or become noticeable because of their size. Many patients have noticed the lesion months or years before diagnosis.^[1]

The most common intraoral site for lipoma is buccal mucosa and buccal vestibule. Lipomas of the oral and maxillofacial region have shown equal predilection for involvement of men and women, although one study has reported a marked male predilection. Lipoma is uncommon in children and affected patients mostly are 40 years of age or older.^[1]

Histopathologically most oral lipomas are composed of mature fat cells very similar in appearance to the surrounding normal fat. Individual cells have a clear cytoplasm with a flat nucleus located on the periphery of the cell. Lipoma is usually well circumscribed and may demonstrate a thin fibrous capsule. Lipomas are treated by conservative local excision, and recurrence is rare.^[1,2]

CASE REPORT

A 36-year old otherwise healthy male patient was referred to oral surgeon with an asymptomatic, swelling in the right buccal mucosa that he had been aware of for 2 years.

In clinical examination an obvious submucosal swelling with intact overlying mucosa was observed.

Access this article online



Website: www.drj.ir

The clinical appearance was similar to mesenchymal tumors, salivary gland tumors, or even bone tumor with soft tissue invasion. An omnipaue contrast CT scan was taken, in which a well-circumscribed lesion with a density similar to adipose tissue was shown [Figure 1].

With a provisional diagnosis of oral lipoma under local anesthesia, surgical excision of the lesion was performed. When a deep seated, yellow, well-circumscribed soft tissue mass with a lobulated surface $4 \times 3.5 \times 1.2$ (length \times width \times thickness) centimeters in size was totally excised and submitted for microscopic examination in 10% buffered formalin [Figures 2 and 3].

In pathology laboratory, the submitted specimen was processed and embedded in paraffin using standard procedures. From the paraffin block a 3μ section was prepared and stained with Hematoxylin and Eosin stain (H and E) to allow histopathologic examination.

In microscopic examination of H and E stained slides, using light microscope (Olympus, Japan), a well-circumscribed nodular mass was seen. Which showed a distinct lobular pattern composed of mature adipocytes, cells with large clear cytoplasm and a flat dark nucleus on periphery. Thin septa of fibrous tissue was seen between the closely packed normal looking fat cells. At the borders, lesion was surrounded by a thin fibrous capsule. According to histopathologic features a definitive diagnosis of lipoma was made [Figure 4]. In an 18-month postsurgery follow-up no recurrence or complication has occurred.

DISCUSSION

Lipoma is a very common benign tumor of adipose tissue, but its presence in oral region is relatively uncommon. Once present, a mucosal oral lipoma may increase to 5 to 6 cm over a period of years, but

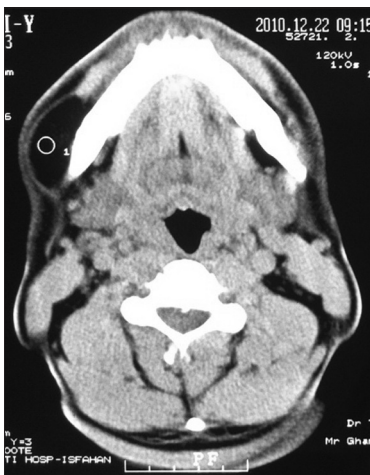

Figure 1: Axial omnipaue contrast CT scan of the lesion

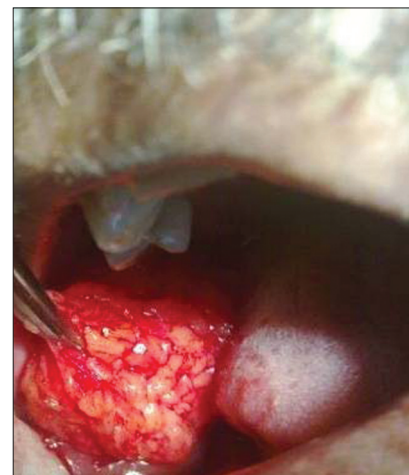

Figure 2: Surgical removal of the lesion via an intraoral approach

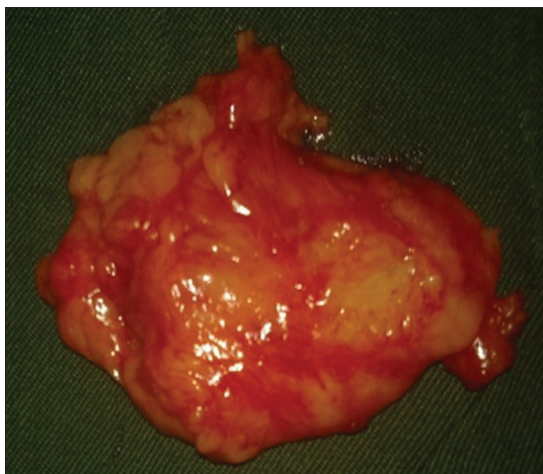


Figure 3: Macroscopic image of the lesion with the lobular surface ($4 \times 3.5 \times 1.2$ cm)

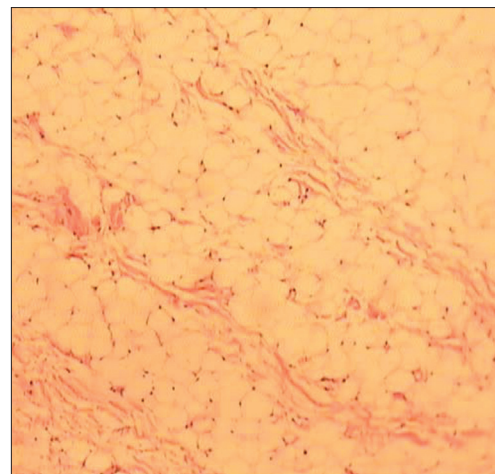


Figure 4: Microscopic image of the lesion, closely packed fat cells separated by thin septa of the fibrous tissue (H and E, $\times 100$)

most cases are less than 3 cm in greatest dimension at diagnosis. Conservative surgical removal is the treatment of choice with occasional recurrences expected.^[3]

As mentioned before, it is believed that oral lipomas tend to occur with equal predilection for involvement of men and women. But Furlong^[4] *et al.* mentioned that oral lipoma is seen more frequently in men (as presented here). Although it should be mentioned here that Freitas^[5] *et al.* showed oral lipoma has a predilection of occurrence for women. The place of involvement was the most common place for occurrence of intraoral lipomas.

For size only few large lipomas have been reported in the English literature.^[6] As the mean size of oral lipoma in 450 cases was 1.66 cm (0.2-10 cm) in diameter.^[7]

In Iranian population we found only five entities introducing intra oral lipoma. A case of oral lipoma was reported in a 57-year old woman with a size of 1.5 cm in diameter.^[8] Saghafi^[9] *et al.* reported a case of osteolipoma in a 68-year old male patient, 1.8 cm in the largest dimension. Tavakoli^[10] *et al.* reported two cases of oral Lipoma one: in a 50-year old male in junction of hard and soft palate with 1.5 cm in diameter and second: a 63-year old male patient with the involvement of lateral border of tongue where the greatest dimension of the lesion reported was 1 cm.

The lesion reported here is to a great extent larger than other intraoral lipomas reported in Iran. This report and the reports of Saghafi, Tavakoli may recommend a male predilection for lipoma of oral cavity in Iran. Despite mentioned case reports patient reported here is under 40 year of age.

CONCLUSION

Although intraoral lipoma is rare, authors recommend the clinical awareness that lipoma can occur in oral cavity, even larger than we usually expect.

REFERENCES

1. Nevill B, Damm D, Allen C, Bouquot J. Oral and Maxillofacial Pathology. 3rd ed. Missouri: Saunders; 2009. p. 523-4.
2. Regezi J, Sciubba J, Jordan R. Oral Pathology Clinical Pathologic Correlations. 5th ed. Philadelphia: Saunders; 2008. p. 176-7.
3. Bouquot J, Nikai H. Lesions of the Oral cavity. In: Gneep D, editor. Diagnostic surgical pathology of the head and neck. 1st ed. Philadelphia: Saunders; 2001. p. 192-3.
4. Furlong MA, Fanburg-Smith JC, Childers EL. Lipoma of the oral and maxillofacial region: Site and subclassification of 125 cases. Oral Surg Oral Med Oral Pathol Oral Radiol Endod 2004;98:441-50.
5. Freitas MA, Freitas VS, Lima AA, Pereira FB, dos Santos JN. Intraoral lipomas: A study of 26 cases in a Brazilian population. Quintessence Int 2009;40:79-85.
6. Colella G, Biondi P, Caltabiano R, Vecchio GM, Amico P, Magro G. Giant intramuscular lipoma of the tongue: A case report and literature review. Cases J 2009;7:130-3.
7. Studart-Soares E, Costa F, Sousa FB, Alves A, Osterne R. Oral lipomas in a Brazilian population: A 10-year study and analysis of 450 cases reported in the literature. Med Oral Patol Oral Cir Bucal 2010;15:691-6.
8. Lavaf S, Azizi A, Sajady F. A case report of oral lipoma. Sci Med J Ahwaz Univ Med Sci 2009;7:130-3.
9. Saghafi SH, Rahpeyma A, Salehinejad J, Zare R. Osteolipoma of the oral cavity: A case report and review of the literature. Iran J Otorhinolaryngol 2007;19:161-4.
10. Tavakoli A, Razavi M, Khabazian A. Lipoma in Oral Mucosa: Two case reports. Dent Res J (Isfahan) 2010;7:41-3.

How to cite this article: Motagi A, Aminzadeh A, Razavi SM. Large oral lipoma: Case report and literature review in Iran. Dent Res J 2012;9:350-2.

Source of Support: Nil. **Conflict of Interest:** None declared.