

Access this article online

Quick Response Code:



Website:  
www.e-tjo.org

DOI:  
10.4103/tjo.tjo\_63\_17

# The rescue effect of adalimumab in the treatment of refractory pediatric panuveitis complicated with steroid-induced glaucoma

Wei-Ning Ku<sup>1</sup>, Chun-Ju Lin<sup>1,2</sup>, Yi-Yu Tsai<sup>1,2</sup>

## Abstract:

We report the rescue effects of adalimumab (HUMIRA®) therapy in a case of refractory pediatric panuveitis complicated with steroid-induced glaucoma. A 13-year-old girl had suffered from blurred vision since January 2013. Bilateral idiopathic panuveitis with macular edema (ME) was diagnosed. She had previously been treated with systemic steroids, methotrexate, cyclosporine, and mycophenolate. All treatments had failed to suppress the ocular inflammation and ME persisted. Intravitreal dexamethasone implant injections were given to both eyes and ME subsided; however, complications with steroid-induced glaucoma and cataract occurred. ME also recurred following absorbance of the dexamethasone implant. After administration of subcutaneous adalimumab injections every 2 weeks, inflammatory activity was well controlled and ME subsided. Phacoemulsification and posterior intraocular lens implantation were performed in both eyes. Menorrhagia and anemia were noted 9 months after adalimumab treatment. Thereafter, adalimumab was reduced and her anemia improved. Her vision had remained 20/20 for 33 months. Refractory pediatric uveitis usually requires more aggressive treatment. Intraocular glucocorticoid releasing implant could be used to lessen the possible systemic side effects in children. Intravitreal dexamethasone implant was effective in treating the inflammatory ME but could be complicated with steroid glaucoma and cataract. Tumor necrosis factor-blocking agents have been used to treat chronic, refractory uveitis in adults as well as children. Adalimumab was a favorable biological agent in steroid-responding pediatric patient of refractory noninfectious uveitis but could be complicated with menorrhagia. Long-term follow-up and more cases are mandatory.

## Keywords:

Adalimumab, menorrhagia, refractory pediatric uveitis, steroid responder

## Introduction

Noninfectious pediatric uveitis is an inflammatory eye disease that can lead to ocular complications and vision loss.<sup>[1]</sup> The incidence may range from 7 to 27 in 100,000 persons/year, among children and adolescents.<sup>[2]</sup> In the developed world, most pediatric uveitis cases are undifferentiated or associated with juvenile idiopathic arthritis (JIA) (13%–47%).<sup>[3]</sup> The uveitis can also lead to complications in over half the cases in children, including iris synechiae,

iris scarring, corneal calcium deposition, glaucoma, cataracts, macular edema (ME), and/or visual loss.<sup>[3]</sup> Therefore, when facing the possible scenario of pediatric uveitis, we need to expedite diagnosis and aggressive treatment to prevent further uveitis-related comorbidity.

In many uveitic cases, topical corticosteroids are the first-line of treatment. When ocular inflammation cannot be suppressed by topical steroids, systemic corticosteroid will be considered. However, children often poorly tolerate long-term systemic

This is an open access journal, and articles are distributed under the terms of the Creative Commons Attribution-NonCommercial-ShareAlike 4.0 License, which allows others to remix, tweak, and build upon the work non-commercially, as long as appropriate credit is given and the new creations are licensed under the identical terms.

For reprints contact: reprints@medknow.com

**How to cite this article:** Ku WN, Lin CJ, Tsai YY. The rescue effect of adalimumab in the treatment of refractory pediatric panuveitis complicated with steroid-induced glaucoma. Taiwan J Ophthalmol 2018;8:164-7.

<sup>1</sup>Department of Ophthalmology, China Medical University Hospital, China Medical University, <sup>2</sup>School of Medicine, College of Medicine, China Medical University, Taichung, Taiwan

## Address for correspondence:

Dr. Chun-Ju Lin,  
Department of Ophthalmology,  
2 Yuh-Der Road,  
Taichung 40447, Taiwan.  
E-mail: doctoraga@gmail.com

Submission: 10-06-2017  
Accepted: 05-09-2017

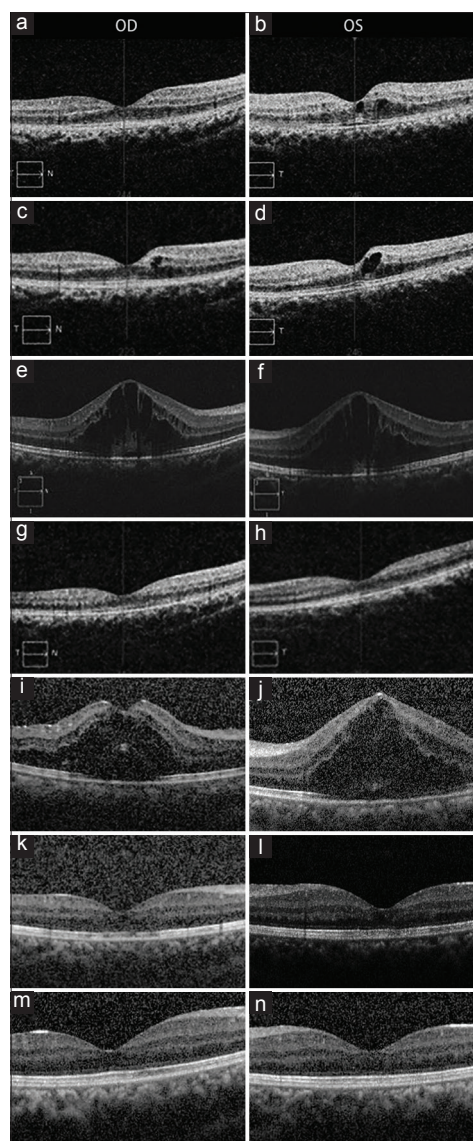
corticosteroid treatment. Corticosteroid-resistant uveitis or steroid responder is another issue. When facing such situations, conventional immunomodulatory therapy, most often methotrexate, is added.<sup>[2]</sup> In cases of refractory pediatric uveitis with poor response to methotrexate treatment, antitumor necrosis factor alpha (anti-TNF $\alpha$ ) agents could serve as rescue therapy.

A number of studies have demonstrated that the majority of corticosteroid- and methotrexate-resistant uveitis patients improve under anti-TNF $\alpha$  agents regarding control of inflammation and improvement of vision.<sup>[2]</sup> Adalimumab (HUMIRA<sup>®</sup>, AbbVie Inc.) has received U. S. Food and Drug Administration approval to be used in treating adults with noninfectious intermediate, posterior, and panuveitis. Open-label studies have demonstrated the efficacy of adalimumab therapy for refractory uveitis associated with JIA.<sup>[4]</sup> We report the rescue effects of adalimumab therapy in a case of refractory pediatric panuveitis complicated with steroid-induced glaucoma.

### Case Report

A 13-year-old girl without any significant medical history had suffered from blurred vision since January 2013. Her best-corrected visual acuity (BCVA) was 20/30 in the right eye and 20/50 in the left eye at initial presentation. A slit-lamp examination revealed no lid edema, mild conjunctival congestion, no corneal edema, anterior chamber cells 2+, clear lens, and Grade 2 vitreous haze in both eyes. Neither retinal hemorrhage nor exudate was found. Fluorescein angiography showed retinitis and ME without retinal vasculitis. No extraocular manifestations were found.

Her routine serum biochemistry was within normal limits. Rapid plasma regain, anti-Toxoplasma Immunoglobulin M, anti-Toxoplasma Immunoglobulin G, and human leukocyte antigen B27 were negative. Erythrocyte sedimentation rate and c-reactive protein were not elevated. Antinuclear antibody was checked using indirect fluorescent antibody method which was negative. JIA or Behçet's disease had been ruled out by the rheumatologist. Bilateral idiopathic panuveitis with mild ME [Figure 1a and b] was diagnosed. Initially, she was treated with topical prednisolone acetate ophthalmic suspension 1% and oral systemic prednisolone 20 mg daily to suppress ocular inflammation, with good response. However, her intraocular pressure (IOP) was elevated to 22 mmHg following steroid use. Thus, we slowly reduced the dose of systemic steroid and added timolol maleate ophthalmic solution to limit her IOP to 16 mmHg. Nevertheless, ocular inflammation with ME in both eyes recurred when oral systemic steroids levels were lowered to 10 mg daily [Figure 1c and d].



**Figure 1:** (a) Mild ME in the presentation OD. (b) Mild ME in the presentation OS. (c) ME recurred when oral steroids tapered OD. (d) ME recurred when oral steroids tapered OS. (e) ME deteriorated under immunomodulatory therapy OD. (f) ME deteriorated under immunomodulatory therapy OS. (g) ME subsided after Ozurdex OD. (h) ME subsided after Ozurdex OS. (i) ME recurred when Ozurdex absorbed OD. (j) ME recurred when Ozurdex absorbed OS. (k) ME subsided after two adalimumab injections OD. (l) ME subsided after two adalimumab injections OS. (m) No ME under adalimumab treatment OD. (n) No ME under adalimumab treatment OS. OD, right eye. OS, left eye

Methotrexate 7.5 mg weekly had been prescribed for 12 months. As her parents worried about the side effects of methotrexate, cyclosporine 200 mg daily started before anti-TNF $\alpha$  therapy. Due to recurrent ME, mycophenolate had substituted cyclosporine for 4 weeks before anti-TNF $\alpha$  therapy, but showed no improvement. Then, cyclosporine restarted due to National Health Insurance reimbursement. We replaced steroid treatment with methotrexate combined with either cyclosporine or mycophenolate. However, the above immunomodulatory therapy failed to control the ocular inflammation and ME deteriorated [Figure 1e and f]. After

obtaining informed oral and written consent from the parents, dexamethasone intravitreal implant (Ozurdex, Allergan, Irvine, CA) injections were given to both eyes and ME subsided [Figure 1g and h]. Steroid-induced glaucoma was noted. IOP elevated in both eyes around 35 mmHg 1 month and 50 mmHg 2 months after dexamethasone implant injections. Fortunately, IOP was controlled with full antiglaucoma medication. IOP dropped to 13 mmHg 3 months later. Cataract developed gradually.

After 6 months, ME recurred [Figure 1i and j] when the dexamethasone intravitreal implant was absorbed. Her BCVA worsened to 20/100 in the right eye and counting fingers at 30 cm in the left eye due to ME and cataract. QuantiFERON for latent tuberculosis infection and viral hepatitis titers including hepatitis B surface antigen, antibody to hepatitis B surface antigen, immunoglobulin G antibody to hepatitis B core antigen, hepatitis C antibody were checked before starting adalimumab treatment. After administration of two subcutaneous adalimumab injections every 2 weeks, the anterior/posterior chamber inflammatory activity was well-controlled and ME subsided [Figures 1k and l]. Phacoemulsification and posterior intraocular lens implantation were performed in both eyes. Her BCVA improved to 20/20. Her macula remained flat [Figure 1m and n] under adalimumab treatment. However, menorrhagia was noted after treatment with adalimumab every 2 weeks for 9 months (from September 2014 to June 2015). Hemoglobin was 12.3 g/dl in August 2014 and dropped to 9 g/dl in June 2015. Anemia improved after decreasing adalimumab treatment to once every 4 weeks until now. Her hemoglobin increased to 13.6 g/dl after 2 months and remained stable. During that period of time, only adalimumab and cyclosporine were used systemically. Cyclosporine tapered to 75 mg daily after anti-TNF $\alpha$  therapy. Topical 0.5% loteprednol etabonate (Lotemax Ophthalmic Suspension 0.5%, Bausch and Lomb, Inc., Rochester, NY, USA) was combined with adalimumab and cyclosporine treatment. Her vision has remained 20/20 for 33 months.

## Discussion

Pediatric noninfectious uveitis is a relatively uncommon severe disease, with potential significant long-term complications such as cataracts, glaucoma, ME, and eventually blindness.<sup>[5]</sup> For these reasons, refractory uveitis usually requires early and aggressive treatment. Conventional immunomodulatory therapy is often needed to preserve visual acuity and to prevent significant morbidity of chronic steroid administration.<sup>[6]</sup>

Cytokines, such as TNF $\alpha$ , have been shown to be involved in apoptosis and inflammation. They also

participate in the pathogenesis of autoimmune ocular inflammatory disease.<sup>[7]</sup> TNF $\alpha$  blocking agents have been recently used to treat chronic, refractory uveitis in adulthood<sup>[8,9]</sup> as well as in childhood.<sup>[3,10-12]</sup> Adalimumab is a recombinant human IgG1 monoclonal antibody to TNF $\alpha$  that also affects receptor-bound TNF $\alpha$ . It is approved for use in children with enthesitis-related arthritis,<sup>[13]</sup> severe plaque psoriasis,<sup>[14]</sup> severe Crohn's disease,<sup>[15]</sup> and active JIA.<sup>[14]</sup> It has also been used in the patients with intraocular inflammation as a rescue therapy, and been shown to be effective in controlling uveitis in a pediatric group.<sup>[7]</sup> Furthermore, adalimumab has the advantages of the convenience of subcutaneous administration, stable serum concentrations, and more favorable safety profile for treating uveitis in children.<sup>[16]</sup> In the study of Castiblanco *et al.*, adalimumab therapy was effective in reducing active inflammation and achieving steroid-free remission in 77% of the pediatric uveitis patients. These patients were able to discontinue using topical and oral steroids.<sup>[7]</sup>

Steroid treatment was effective in our patient, but her IOP elevated slightly (22 mmHg) after oral and topical steroid use. Moreover, the treatment of dexamethasone intravitreal implant was very effective in subsiding inflammatory ME, but was complicated with steroid-induced glaucoma and cataract. We therefore discontinued steroid treatment. Other immunomodulatory therapies, including methotrexate and cyclosporine, also failed to control the ocular inflammation. The results of this report suggest that adalimumab was a favorable biological agent in this pediatric steroid-responding patient of refractory noninfectious uveitis, and may reduce the requirement of concomitant immunosuppressive therapies.

Although rare, it is important to discuss black box warning, including liver enzyme elevation, tuberculosis reactivation, invasive fungal, other opportunistic infections, and development of malignancies such as lymphoma and leukemia, in children and adolescents who have long life expectancy.<sup>[17]</sup> Menorrhagia and severe menstrual pain related to the use of adalimumab in a psoriatic patient have also been reported.<sup>[18]</sup> Physicians should be aware of the menstrual side effects of adalimumab.

In the literature, adalimumab is effective in reducing active inflammation and the achieving steroid-free remission among pediatric uveitis patients. The results of this case report suggest that adalimumab is a favorable biological agent in treating pediatric refractory steroid-responding panuveitis, with a reasonable side effect profile. More case studies and longer follow-ups are mandatory to further confirm the efficacy and explore any additional effects of this treatment.

## Declaration of patient consent

The authors certify that they have obtained all appropriate patient consent forms. In the form the patient(s) has/have given his/her/their consent for his/her/their images and other clinical information to be reported in the journal. The patients understand that their names and initials will not be published and due efforts will be made to conceal their identity, but anonymity cannot be guaranteed.

## Acknowledgement

We would like to acknowledge Henry Bair for English editing.

## Financial support and sponsorship

Nil.

## Conflicts of interest

The authors declare that there are no conflicts of interests of this paper.

## References

1. Angeles-Han ST, Rabinovich CE. Uveitis in children. *Curr Opin Rheumatol* 2016;28:544-9.
2. Lerman MA, Lewen MD, Kempen JH, Mills MD. Uveitis reactivation in children treated with tumor necrosis factor alpha inhibitors. *Am J Ophthalmol* 2015;160:193-2000.
3. Lerman MA, Burnham JM, Chang PY, Daniel E, Foster CS, Hennessy S, *et al.* Response of pediatric uveitis to tumor necrosis factor- $\alpha$  inhibitors. *J Rheumatol* 2013;40:1394-403.
4. García-De-Vicuña C, Díaz-Llopis M, Salom D, Bou R, Díaz-Cascajosa J, Cordero-Coma M, *et al.* Usefulness of adalimumab in the treatment of refractory uveitis associated with juvenile idiopathic arthritis. *Mediators Inflamm* 2013;2013:560632.
5. Cunningham ET Jr. Uveitis in children. *Ocul Immunol Inflamm* 2000;8:251-61.
6. Lyon F, Gale RP, Lightman S. Recent developments in the treatment of uveitis: An update. *Expert Opin Investig Drugs* 2009;18:609-16.
7. Castiblanco C, Meese H, Foster CS. Treatment of pediatric uveitis with adalimumab: The MERSI experience. *J AAPOS* 2016;20:145-7.
8. Díaz-Llopis M, Salom D, García-de-Vicuña C, Cordero-Coma M, Ortega G, Ortega N, *et al.* Treatment of refractory uveitis with adalimumab: A prospective multicenter study of 131 patients. *Ophthalmology* 2012;119:1575-81.
9. Levy-Clarke G, Jabs DA, Read RW, Rosenbaum JT, Vitale A, Van Gelder RN, *et al.* Expert panel recommendations for the use of antitumor necrosis factor biologic agents in patients with ocular inflammatory disorders. *Ophthalmology* 2014;121:785-96.e3.
10. Saurenmann RK, Levin AV, Rose JB, Parker S, Rabinovitch T, Tyrrell PN, *et al.* Tumor necrosis factor alpha inhibitors in the treatment of childhood uveitis. *Rheumatology (Oxford)* 2006;45:982-9.
11. Simonini G, Taddio A, Cattalini M, Caputo R, De Libero C, Naviglio S, *et al.* Prevention of flare recurrences in childhood-refractory chronic uveitis: An open-label comparative study of adalimumab versus infliximab. *Arthritis Care Res (Hoboken)* 2011;63:612-8.
12. Doycheva D, Zierhut M, Blumenstock G, Stuebiger N, Januschowski K, Voykov B, *et al.* Immunomodulatory therapy with tumor necrosis factor  $\alpha$  inhibitors in children with antinuclear antibody-associated chronic anterior uveitis: Long-term results. *Br J Ophthalmol* 2014;98:523-8.
13. Burgos-Vargas R, Tse SM, Horneff G, Pangan AL, Kalabic J, Goss S, *et al.* A randomized, double-blind, placebo-controlled multicenter study of adalimumab in pediatric patients with enthesitis-related arthritis. *Arthritis Care Res (Hoboken)* 2015;67:1503-12.
14. Alwawi EA, Mehlis SL, Gordon KB. Treating psoriasis with adalimumab. *Ther Clin Risk Manag* 2008;4:345-51.
15. Asgharpour A, Cheng J, Bickston SJ. Adalimumab treatment in Crohn's disease: An overview of long-term efficacy and safety in light of the EXTEND trial. *Clin Exp Gastroenterol* 2013;6:153-60.
16. Tugal-Tutkun I. Pediatric uveitis. *J Ophthalmic Vis Res* 2011;6:259-69.
17. Jeroudi A, Angeles-Han ST, Yeh S. Efficacy of adalimumab for pediatric Vogt-Koyanagi-Harada syndrome. *Ophthalmic Surg Lasers Imaging Retina* 2014;45:332-4.
18. Scheinfeld N. Menorrhagia and severe menstrual pain related to the use of adalimumab in a psoriatic. *J Dermatolog Treat* 2008;19:188-9.