

# Full-endoscopic discectomy via the interlaminar approach for disc herniation at L4-L5 and L5-S1

## An observational study

Wenbin Hua, MD, Ji Tu, MM, Shuai Li, MD, Xinghuo Wu, MD, Yukun Zhang, MD, Yong Gao, MD, Xianlin Zeng, MD, Shuhua Yang, MD, Cao Yang, MD\*

### Abstract

The purpose of this retrospective study was to investigate the clinical outcomes of full-endoscopic discectomy via the interlaminar approach in the treatment of lumbar disc herniation (LDH) at L4-L5 under general anesthesia.

Eighty-four patients who underwent full-endoscopic discectomy via the interlaminar approach at L4-L5 or L5-S1 were included. Durations of surgery, intraoperative radiation, postoperative bedrest, and hospitalization as well as perioperative complications were recorded. The visual analog scale (VAS) score for leg and back pain and the Oswestry disability index (ODI) score were evaluated preoperatively and at 3, 6, and 12 months postoperatively.

The mean durations of surgeries in surgeries involving L4-L5 and L5-S1 were  $69.8 \pm 18.8$  and  $67.0 \pm 20.1$  minutes, respectively. The mean durations of intraoperative radiation were  $1.2 \pm 0.3$  and  $1.3 \pm 0.3$  seconds, respectively. The mean VAS and ODI scores improved significantly postoperatively compared with the preoperative scores. The perioperative complications included intraoperative epineurium injury in 3 cases without nerve injury, cerebrospinal fluid leakage, or cauda equina syndrome. The total recurrence rate after 12 months follow-up was 1.2% (one case at L5-S1).

Full-endoscopic discectomy via the interlaminar approach could be considered as one of the alternative options for the treatment of LDH at L4-L5.

**Abbreviations:** CT = computed tomography, LDH = lumbar disc herniation, MRI = magnetic resonance imaging, ODI = Oswestry disability Index, VAS = visual analog scale.

**Keywords:** discectomy, full-endoscopic, interlaminar approach, laminectomy

## 1. Introduction

Lumbar disc herniation (LDH) is the most common spinal degenerative disease, and many patients require surgical treatment, such as discectomy and/or laminectomy. Open discectomy via interlaminar approach was first introduced in the early 20th century.<sup>[1]</sup> Hijikata<sup>[2]</sup> introduced their first experiences with the closed percutaneous nucleotomy in 1975. Full-endoscopic discectomy via the transforaminal approach and interlaminar approach were first reported by Ruetten et al<sup>[3,4]</sup> in

2005 and 2006, respectively. Since then, full-endoscopic discectomy has become the most commonly performed minimally invasive procedure for LDH.<sup>[5-7]</sup>

Even though full-endoscopic discectomy can be performed via either the interlaminar or transforaminal approach in most patients with LDH,<sup>[4,6,8-11]</sup> it is difficult to determine which approach is better. Full-endoscopic discectomy via the transforaminal approach is preferred at both L4-L5 and L5-S1 because it does not require the removal of the ligamentum flavum or lamina.<sup>[12]</sup> In some cases, sufficient decompression may be difficult for disc herniation at L5-S1 via the transforaminal route; in such cases, the interlaminar approach is preferred.<sup>[13]</sup>

There are some studies about full-endoscopic discectomy via the interlaminar approach at L5-S1,<sup>[14,15]</sup> however there is few study about full-endoscopic discectomy via the interlaminar approach at L4-L5 under general anesthesia. The purpose of this retrospective study was to investigate the clinical outcomes of full-endoscopic discectomy via the interlaminar approach in the treatment of LDH at L4-L5 under general anesthesia.

## 2. Materials and methods

### 2.1. Patient population and grouping

In this retrospective study, 84 patients (65 males, 19 females) who underwent full-endoscopic discectomy via the interlaminar approach at L4-L5 or L5-S1 in our department between January 2015 and June 2016 were included. In these patients, 30 surgeries were performed at L4-L5 and 54 at L5-S1.

Editor: Jin-Sung Kim.

Funding: This work was supported by the National Natural Science Foundation of China (Grant no. 81772401 and U1603121).

WH, JT, and SL contributed equally to this work.

The authors have no conflicts of interest to disclose.

Department of Orthopaedics, Union Hospital, Tongji Medical College, Huazhong University of Science and Technology, Wuhan, China.

\* Correspondence: Cao Yang, Department of Orthopaedics, Union Hospital, Tongji Medical College, Huazhong University of Science and Technology, Wuhan 430022, China (e-mail: yangcao1971@sina.com).

Copyright © 2018 the Author(s). Published by Wolters Kluwer Health, Inc. This is an open access article distributed under the terms of the Creative Commons Attribution-Non Commercial-No Derivatives License 4.0 (CCBY-NC-ND), where it is permissible to download and share the work provided it is properly cited. The work cannot be changed in any way or used commercially without permission from the journal.

Medicine (2018) 97:17(e0585)

Received: 1 December 2017 / Accepted: 6 April 2018

<http://dx.doi.org/10.1097/MD.00000000000010585>

Inclusion criteria were as follows: single-level herniated disc at either L4-L5 or L5-S1; radiating pain in the unilateral lower limb; standard conservative treatment for at least 12 weeks without satisfactory results; and magnetic resonance imaging (MRI) and/or computed tomography (CT) indicating a herniated disc at L4-L5 or L5-S1, in agreement with clinical symptoms and signs.

Exclusion criteria were as follows: extreme lateral disc herniation; spinal canal stenosis, lumbar spondylolisthesis, and/or segmental instability confirmed by radiography; evidence of infection, tumor, or other lesions; and surgical history involving the corresponding segment.

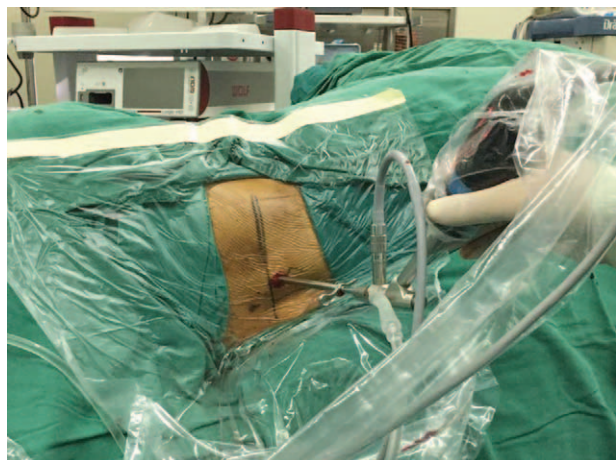Every patient meets all the inclusion criteria without any one of the exclusion criteria can be chosen to be operated by full-endoscopic discectomy via the interlaminar approach. According to the surgical segment of discectomy, patients included were categorized into 2 groups: L4-L5 group and L5-S1 group.

## 2.2. Full-endoscopic instruments

A full-endoscopic surgical system (Spinendos, Munchen, Germany) was used. A direction-variable drill (Spinendos) was used because of technical superiority, such as smaller diameter, well-designed surface, and variable direction. Radiofrequency probing (Trigger-Flex; Elliquence, Baldwin, NY) was used to control bleeding of soft tissue.

## 2.3. Surgical technique

The surgeries were performed under general anesthesia with the patients in the lateral position, with their hips flexed to achieve a wider interlaminar space (Fig. 1). All the surgeries were performed by the senior author, who has many years of experience in microsurgical discectomy and microendoscopic discectomy. Posteroanterior and lateral fluoroscopy was used to locate the interlaminar space at L4-L5 or L5-S1. Soft tissue expanders were applied to separate the muscles via a small skin incision, to allow the insertion of the working cannula and endoscopic surgical system. All the subsequent procedures were performed under constant irrigation with excellent visualization. The inferior edge of the cranial lamina on the side of the lesion and the ligamentum flavum were exposed under visualization using an endoscopic camera system.<sup>[3,4,8,9]</sup> Then, a 5-mm incision



**Figure 1.** Full-endoscopic discectomy via the interlaminar approach performed in the lateral position.

was placed on the ligamentum flavum using a laminectomy rongeur, which enabled the access into the spinal canal (Figs. 2 and 3).

Any interlaminar window with diameter <7 mm was enlarged to accommodate the working cannula. In each case of L4-L5 discectomy, the direction-variable drill was used to partially resect the cranial lamina in order to enlarge the interlaminar space. In cases of L5-S1 discectomy, the spinal canal was adequately exposed after exposing the ligamentum flavum. Then, the direction-variable drill was used in some cases of L5-S1 discectomy with narrow interlaminar space.

Then the herniated nucleus pulposus tissue was exposed and removed to ensure sufficient decompression of the nerve root (Figs. 2 and 3). Before ending the surgery, we ensured there was no significant free disc tissue, dural sac damage, or active bleeding. No drainages were required.

## 2.4. Clinical evaluation

The durations of surgery, intraoperative radiation, postoperative bedrest and hospitalization as well as perioperative complications were recorded. Postoperative MRI or CT imaging was performed when necessary. The visual analog scale (VAS) score for leg pain and back pain (with 0 indicating no pain, and 10 indicating the worst conceivable pain) and Oswestry disability index (ODI) score (range, 0–100)<sup>[16]</sup> were used preoperatively and at 3, 6, and 12 months postoperatively. MacNab criteria were used to evaluate surgical effectiveness.

## 2.5. Statistical analyses

All data are presented as mean ± standard deviation. The independent-samples *t* test was used to compare preoperative and postoperative data and the data between the groups. Statistical analyses were performed using SPSS version 18.0 (SPSS Inc., Chicago, IL), and the corresponding graphs were generated using GraphPad Prism 6 (GraphPad Software, Inc., San Diego, CA). A *P* value <.05 was considered statistically significant.

## 2.6. Ethics statement

This study was conducted in accordance with the guidelines of the Declaration of Helsinki and was approved by the ethics committee of our hospital. Written informed consents were obtained from all the patients.

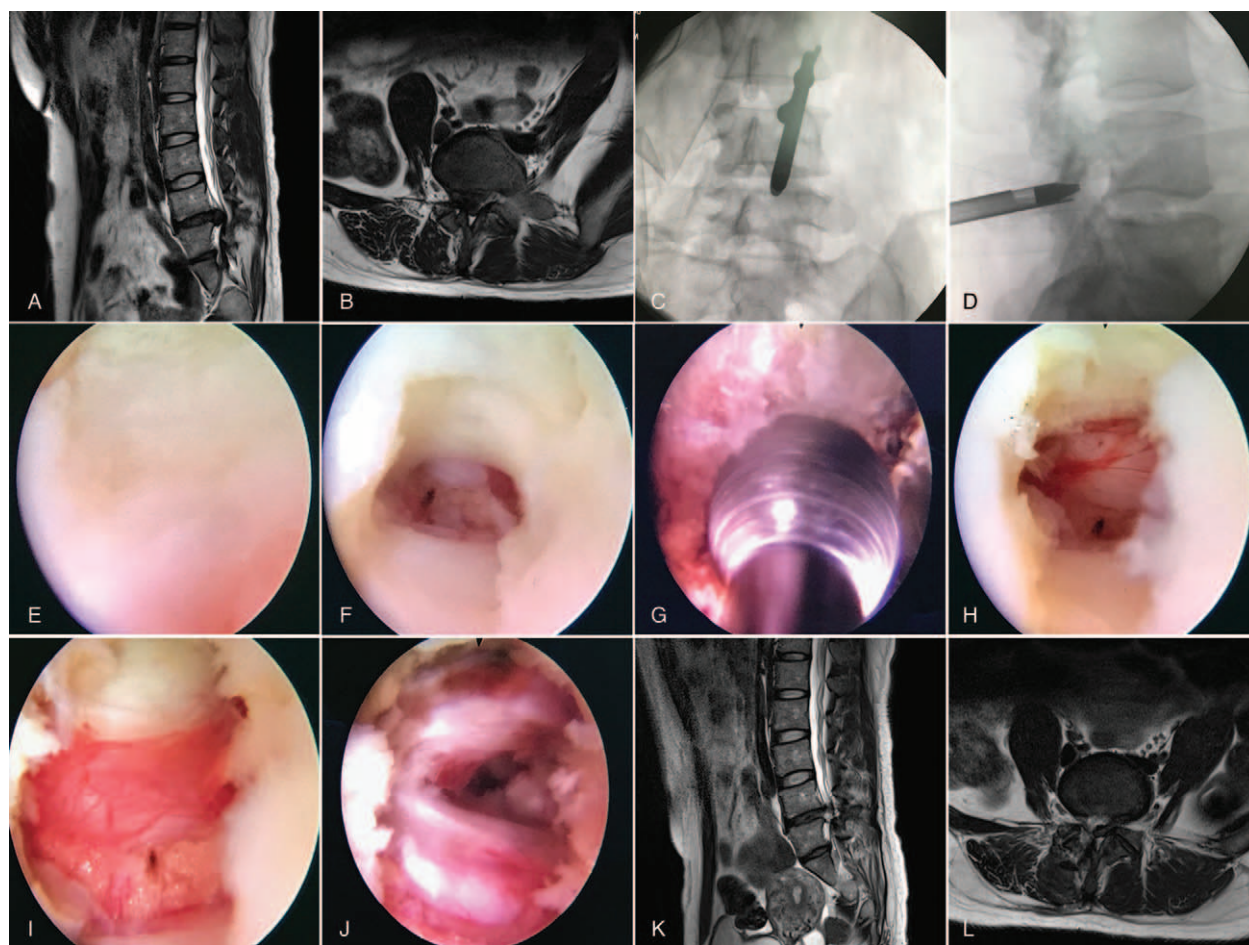
## 3. Results

### 3.1. Demographic data

The baseline demographic and clinical characteristics of both groups are summarized in Table 1.

### 3.2. Clinical outcomes

Follow-up examinations were conducted at 3, 6, and 12 months postoperatively. The mean durations of surgery in L4-L5 group and L5-S1 group were  $69.8 \pm 18.8$  (range, 45–120) and  $67.0 \pm 20.1$  (range, 40–150) minutes, respectively ( $P > .05$ ). The mean durations of intraoperative radiation, postoperative bedrest, and hospitalization are summarized in Table 2 ( $P > .05$ ). In both groups, the duration of surgery rapidly decreased in the initial cases and then tapered to a steady value in the latter cases, which is similar to the learning curve of the technique (Fig. 4).



**Figure 2.** The procedure of full-endoscopic discectomy via the interlaminar approach performed in a 32-year-old female patient diagnosed with lumbar disc herniation at L4-L5. (A and B) preoperative magnetic resonance imaging (MRI) shows lumbar disc herniation at L4-L5; (C and D) intraoperative anteroposterior and lateral fluoroscopy to confirm the interlaminar space; (E) ligamentum flavum; (F) ligamentum flavum incised; (G) cranial lamina resected by the direction-variable drill; (H) dural sac exposed; (I) cranial lamina partial resected with the dural sac and herniated disc exposed; (J) dural sac, traversing nerve root, and axilla after decompression; (K and L) MRI 10 days after the surgery shows herniated lumbar disc decompressed. MRI = magnetic resonance imaging.

In both groups, compared with the preoperative scores, the mean VAS scores and ODI scores improved significantly postoperatively (Table 3, Fig. 5). According to the MacNab criteria, the outcomes rated as excellent and good were 20 (66.7%) and 7(23.3%) in the L4-L5 group, 34 (63.0%) and 16 (29.6%) in the L5-S1 group, respectively (Table 3).

### 3.3. Perioperative complications and recurrences

Intraoperative epineurium injury occurred in 3 patients without nerve injury, dural injury, or cauda equina syndrome. No postoperative pain medications were required.

Only one patient suffered from recurrence resulting in a total recurrence rate of 1.2% after 12 months follow-up. He had undergone L5-S1 discectomy with laminectomy, and developed recurrence 3 months later, which was treated with minimally invasive transforaminal lumbar interbody fusion.

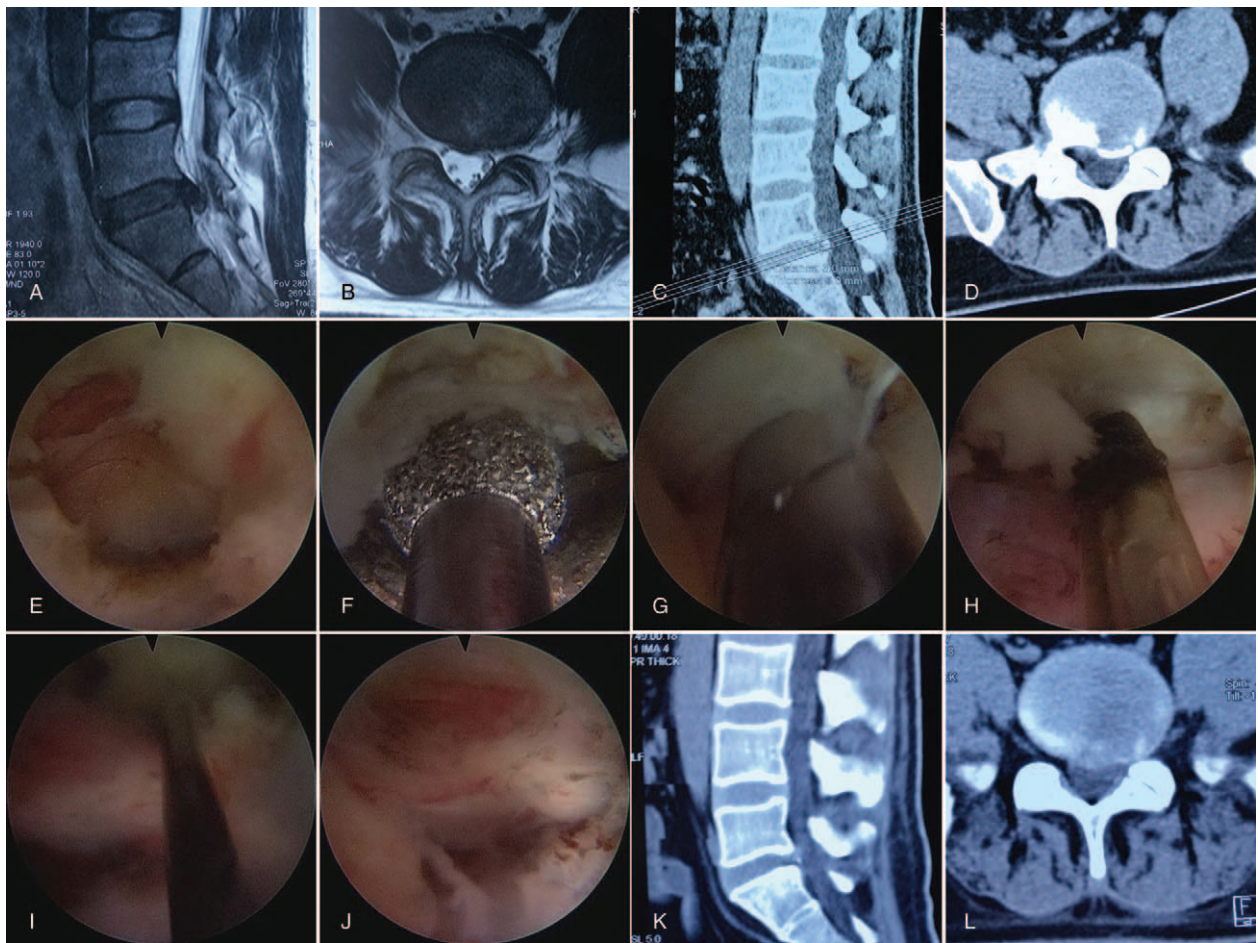
## 4. Discussion

Sufficient decompression is the main goal of surgical treatment in LDH. Even though lesser trauma and quicker recovery are achieved by full-endoscopic discectomy via the interlaminar

approach,<sup>[4,8,9]</sup> sufficient decompression may be technically difficult, especially in patients with narrow interlaminar spaces, posterior marginal osteoproliferation of the vertebrae, ossification of the posterior longitudinal ligaments, lumbar stenoses, and recurrences.<sup>[10,17]</sup> However, with the development of new techniques and tools, most of these challenges have been overcome.<sup>[10,18,19]</sup> To enlarge the interlaminar space and sufficiently decompress a herniated disc, the cranial lamina can be partially resected with the aid of a drill, including the distance between the cranial and caudal laminae and the distance between the medial borders of the processus articularis and the midline.<sup>[3,8]</sup>

Because of the same approach as open discectomy, microsurgical discectomy, and microendoscopic discectomy, full-endoscopic discectomy via the interlaminar approach can be easily performed by spine surgeons with experience in microsurgical discectomy and microendoscopic discectomy.<sup>[4,8,9]</sup>

Laminectomy may be necessary during full-endoscopic discectomy via the interlaminar approach because of narrow interlaminar space, especially at L4-L5.<sup>[9,10]</sup> Therefore, every surgery at L4-L5 and a few at L5-S1 were performed with minimally invasive laminectomy, depending on the width of the interlaminar space. During the surgeries of full-endoscopic



**Figure 3.** The procedure of full-endoscopic discectomy via the interlaminar approach performed in a 33-year-old male patient diagnosed with lumbar disc herniation at L5-S1. (A and B) preoperative magnetic resonance imaging shows lumbar disc herniation at L5-S1; (C and D) preoperative computed tomography (CT) shows herniated and calcified lumbar disc at L5-S1; (E) interlaminar space exposed; (F) cranial lamina resected by the direction variable drill; (G) herniated disc exposed and extracted; (H) a radiofrequency electrode is applied to control bleeding; (I and J) dural sac, traversing nerve root, and axilla after decompression; (K and L) CT one day after the surgery shows herniated and calcified disc decompressed. CT=computed tomography.

discectomy via the interlaminar approach, laminectomy and disc resection procedures should be performed under visualization to guarantee complete decompression, ensure minimal trauma, and prevent segment instability.<sup>[4,8,9,20]</sup>

**Table 1**  
General information of patients in the 2 groups.

	L4-L5 group	L5-S1 group
n	30	54
Male/ Female	23/7	42/12
Age, years	39.0±11.9 (17-68)	35.9±12.2 (18-73)
Central	5	7
Paracentral	7	15
Prolapsus/sequestered	18	32
Symptoms		
Low back pain	28	51
Leg pain	30	54
Signs		
Lasegue's sign +	29	51
Paresthesia in lower leg	27	49
Lower extremity weakness	26	46

Additionally, the variable-direction drill was used in laminectomy to enlarge the interlaminar space so the working cannula and endoscopic system could be inserted. This drill has a well-designed surface, and variable-direction capability; as a result, the laminectomy procedure was safer and easily controlled. Furthermore, this drill can decrease bleeding of the lamina after laminectomy because of the small bone particles packed at the laminectomy surface. Full-endoscopic discectomy via the interlaminar approach causes no damage to the facet joints and

**Table 2**  
Comparison of durations of surgery, intraoperative radiation, postoperative bedrest and hospitalization in the 2 groups.

	L4-L5 group	L5-S1 group	P
n	30	54	-
Duration of surgery, minutes	69.8±18.8 (45-120)	67.0±20.1 (40-150)	.527
Duration of intraoperative radiation, seconds	1.2±0.3 (1.0-2.0)	1.3±0.3 (1.0-2.0)	.635
Duration of postoperative bedrest, hours	10.9±2.4 (8-16)	10.5±2.3 (8-16)	.462
Duration of postoperative hospitalization, days	5.5±1.0 (4-7)	5.7±0.9 (4-7)	.486

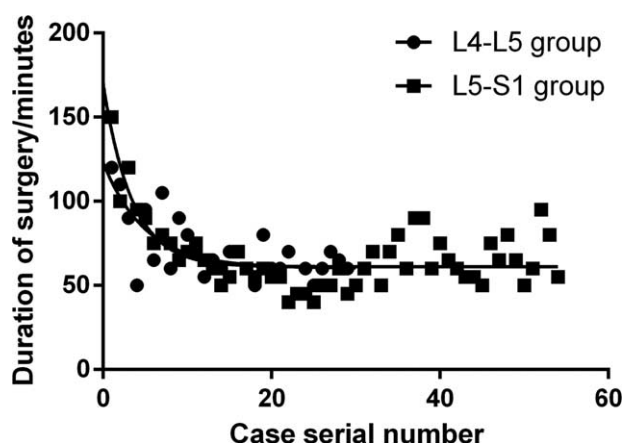


Figure 4. The learning curve in the 2 groups.

iatrogenic instability; therefore, parameters such as diameter of the osseous interlaminar space and sequestering of the disc material are no longer contraindications, thus, making full-endoscopic discectomy via the interlaminar approach technically possible in most cases of LDH.<sup>[4,8,9]</sup>

Full-endoscopic discectomy results in minimal trauma, rapid rehabilitation, and less intraspinal adhesions, and facilitates revision surgeries.<sup>[7,9]</sup> According to the literature regarding endoscopic discectomy via interlaminar approach, the mean durations of surgery was 29 to 68.5 minutes.<sup>[4,5,15,21]</sup> Because of the learning curve associated with full-endoscopic discectomy, the duration of earlier surgeries was longer.<sup>[14,17,21,22]</sup> The mean durations of the surgery in the present study were in accordance with those reported in the literature.

Although conventional surgeries can achieve good results,<sup>[23-26]</sup> scarring of the epidural space has been observed postoperatively.<sup>[27]</sup>

**Table 3**  
Comparison of VAS and ODI scores, MacNab evaluation in the 2 groups.

	L4-L5 group (N#)	L5-S1 group (N#)
VAS leg pain scores		
Preop	7.7 ± 1.1 (30)	7.8 ± 1.2 (54)
3 months Postop	1.6 ± 0.8* (29)	1.8 ± 0.7* (51)
12 months Postop	1.4 ± 0.6* (27)	1.5 ± 0.5* (48)
VAS back pain scores		
Preop	4.1 ± 1.0 (30)	4.4 ± 1.1 (54)
3 months Postop	1.5 ± 0.7* (29)	1.8 ± 0.6* (51)
12 months Postop	1.2 ± 0.6* (27)	1.4 ± 0.5* (48)
ODI (%)		
Preop	49.8 ± 10.2 (30)	51.2 ± 10.9 (54)
3 months Postop	16.9 ± 6.3* (29)	17.9 ± 5.3* (51)
12 months Postop	14.1 ± 5.2* (27)	15.4 ± 4.8* (48)
MacNab evaluation		
Excellence	20	34
Good	7	16
Fair	2	4
Poor	1	0
Excellence/good rate	90.0%	92.6%

ODI=Oswestry disability index, Postop=preoperative, Pre-op=preoperative, VAS=visual analog scale.

\* P < .05 versus preoperative data.

# Number of patients included before surgery and during follow-up.

Epidural adhesions have been confirmed by MRI in many cases, though only 10% result in clinical symptoms.<sup>[27]</sup> According to the absence of clinical symptoms and intraoperative findings at the time of revision surgery, full-endoscopic discectomy via the interlaminar approach appears to reduce scarring.<sup>[8]</sup> Only slight scarring in the access area and the spinal canal has been observed in cases of recurrent herniation.<sup>[8]</sup> In the recurrent case in this study, no significant intraspinal adhesions were observed.

Recurrence is an important problem in both conventional discectomy and full-endoscopic discectomy via the interlaminar approach. Ruetten et al<sup>[9]</sup> reported that the recurrence rate of LDH after full-endoscopic discectomy via the interlaminar approach was 6.6%, similar to that after microsurgical discectomy (5.5%). Sencer et al<sup>[6]</sup> reported that the recurrence rate after full-endoscopic discectomy via the interlaminar approach was 3.8% and Passacantilli et al<sup>[21]</sup> reported a recurrence rate of 5.0%. Hsu et al<sup>[22]</sup> reported a reoperation rate as high as 13.0%, and noted that more recurrences occurred in the early phase of the learning curve. In the present study, the recurrence rate was 1.2% after 12 month follow-up. Even though a low recurrence rate was observed until the final follow-up, more recurrences might be observed with a longer follow-up period. Additionally, the senior author has many years of experience in microsurgical discectomy and microendoscopic discectomy; therefore, full-endoscopic discectomy via the interlaminar approach should be performed by surgeons with similar experiences in microsurgical discectomy or microendoscopic discectomy to lower the recurrence rate.

On the other hand, full-endoscopic discectomy via the interlaminar approach has some disadvantages, such as the steep learning curve.<sup>[14,17,22]</sup> A learning course and personal experiences are necessary for the surgeons to master the key techniques of full-endoscopic discectomy via the interlaminar approach. Additionally, muscles, facet cysts, and ligaments may be difficult to identify under endoscopic visualization, increasing the risk for iatrogenic injury.<sup>[17]</sup> Care must be taken to prevent dural sac damage or intraspinal hematoma.<sup>[28]</sup> During full-endoscopic discectomy via the interlaminar approach, if the herniated disc cannot be sufficiently decompressed, due to severe intraspinal bleeding or anatomical obstruction, conventional surgeries should be performed, if necessary.

### 5. Conclusions

Full-endoscopic discectomy via the interlaminar approach could be considered as one of the alternative options for the treatment of LDH at L4-L5. However, this study is limited by its small sample size and short follow-up period, with patients lost to follow-up, which may have affected our analyses of the outcomes. Further comparative studies and prospective, randomized, controlled studies should be conducted to assess the clinical outcomes.

### Author contributions

**Conceptualization:** Wenbin Hua, Cao Yang.

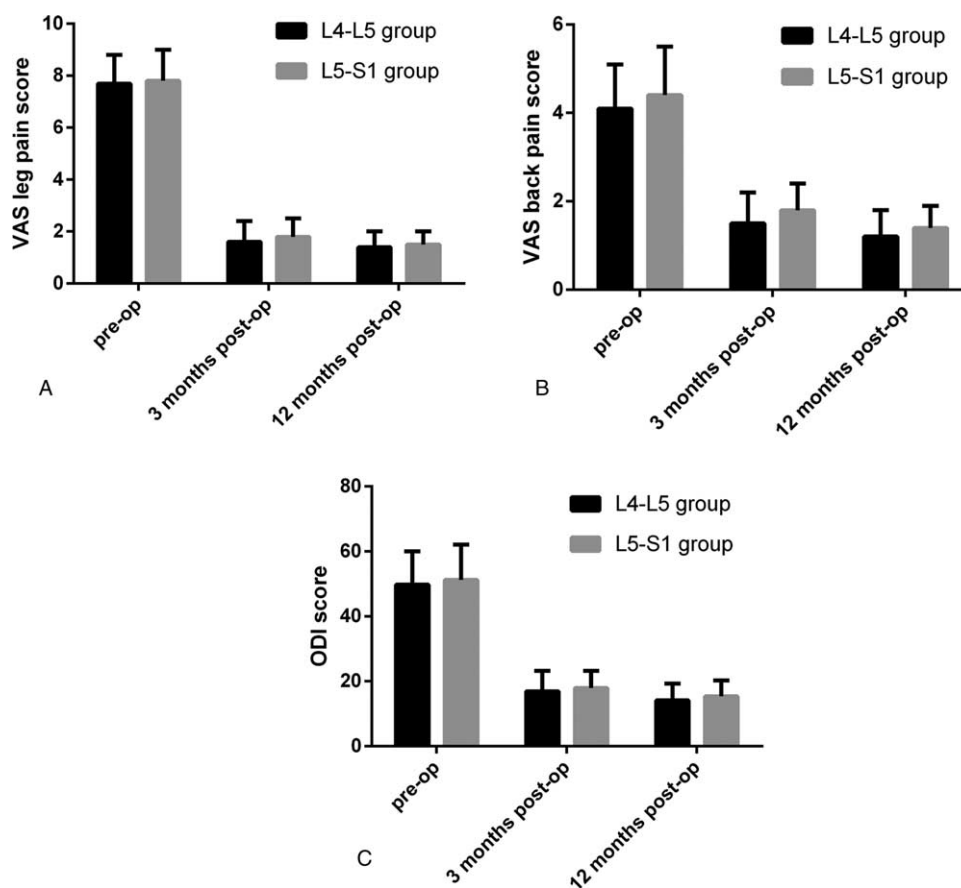
**Data curation:** Wenbin Hua, Ji Tu, Shuai Li, Xinghuo Wu, Yukun Zhang, Yong Gao, Xianlin Zeng, Cao Yang.

**Formal analysis:** Wenbin Hua, Ji Tu, Shuai Li.

**Funding acquisition:** Cao Yang.

**Investigation:** Wenbin Hua, Cao Yang.

**Software:** Ji Tu, Shuai Li.



**Figure 5.** The mean values of visual analog scale (VAS) scores for leg and back pain, and Oswestry disability index (ODI) scores. Preop, preoperative; postop, postoperative. ODI=Oswestry disability index, VAS=visual analog scale.

**Supervision:** Shuhua Yang, Cao Yang.

**Writing – original draft:** Wenbin Hua.

**Writing – review & editing:** Wenbin Hua.

## References

- Weinstein J, Spratt KF, Lehmann T, et al. Lumbar disc herniation. A comparison of the results of chemonucleolysis and open discectomy after ten years. *J Bone Joint Surg Am* 1986;68:43–54.
- Hijikata S. Percutaneous nucleotomy. A new concept technique and 12 years' experience. *Clin Orthop Relat Res* 1989;9–23.
- Ruetten S, Komp M, Godolias G. An extreme lateral access for the surgery of lumbar disc herniations inside the spinal canal using the full-endoscopic uniportal transforaminal approach-technique and prospective results of 463 patients. *Spine (Phila Pa 1976)* 2005;30:2570–8.
- Ruetten S, Komp M, Godolias G. A new full-endoscopic technique for the interlaminar operation of lumbar disc herniations using 6-mm endoscopes: prospective 2-year results of 331 patients. *Minim Invasive Neurosurg* 2006;49:80–7.
- Wang B, Lu G, Liu W, et al. Full-endoscopic interlaminar approach for the surgical treatment of lumbar disc herniation: the causes and prophylaxis of conversion to open. *Arch Orthop Trauma Surg* 2012;132:1531–8.
- Sencer A, Yorukoglu AG, Akcakaya MO, et al. Fully endoscopic interlaminar and transforaminal lumbar discectomy: short-term clinical results of 163 surgically treated patients. *World Neurosurg* 2014;82:884–90.
- Li M, Yang H, Yang Q. Full-endoscopic technique discectomy versus microendoscopic discectomy for the surgical treatment of lumbar disc herniation. *Pain Physician* 2015;18:359–63.
- Ruetten S, Komp M, Merk H, et al. Use of newly developed instruments and endoscopes: Full-endoscopic resection of lumbar disc herniations via the interlaminar and lateral transforaminal approach. *J Neurosurg Spine* 2007;6:521–30.
- Ruetten S, Komp M, Merk H, et al. Full-endoscopic interlaminar and transforaminal lumbar discectomy versus conventional microsurgical technique: a prospective, randomized, controlled study. *Spine (Phila Pa 1976)* 2008;33:931–9.
- Ruetten S, Komp M, Merk H, et al. Recurrent lumbar disc herniation after conventional discectomy: a prospective, randomized study comparing full-endoscopic interlaminar and transforaminal versus microsurgical revision. *J Spinal Disord Tech* 2009;22:122–9.
- Yeung AT, Tsou PM. Posterolateral endoscopic excision for lumbar disc herniation: surgical technique, outcome, and complications in 307 consecutive cases. *Spine (Phila Pa 1976)* 2002;27:722–31.
- Choi KC, Lee JH, Kim JS, et al. Unsuccessful percutaneous endoscopic lumbar discectomy: a single-center experience of 10,228 cases. *Neurosurgery* 2015;76:372–80. discussion 380–1; quiz 381.
- Nie H, Zeng J, Song Y, et al. Percutaneous endoscopic lumbar discectomy for l5-s1 disc herniation via an interlaminar approach versus a transforaminal approach: a prospective randomized controlled study with 2-year follow up. *Spine (Phila Pa 1976)* 2016;41(suppl 19):B30–7.
- Xu H, Liu X, Liu G, et al. Learning curve of full-endoscopic technique through interlaminar approach for l5/s1 disk herniations. *Cell Biochem Biophys* 2014;70:1069–74.
- Li ZZ, Hou SX, Shang WL, et al. The strategy and early clinical outcome of full-endoscopic l5/s1 discectomy through interlaminar approach. *Clin Neurol Neurosurg* 2015;133:40–5.
- Fairbank JC, Couper J, Davies JB, et al. The Oswestry low back pain disability questionnaire. *Physiotherapy* 1980;66:271–3.
- Wang B, Lu G, Patel AA, et al. An evaluation of the learning curve for a complex surgical technique: the full endoscopic interlaminar approach for lumbar disc herniations. *Spine J* 2011;11:122–30.

- [18] Komp M, Hahn P, Merk H, et al. Bilateral operation of lumbar degenerative central spinal stenosis in full-endoscopic interlaminar technique with unilateral approach: prospective 2-year results of 74 patients. *J Spinal Disord Tech* 2011;24:281–7.
- [19] Komp M, Hahn P, Oezdemir S, et al. Bilateral spinal decompression of lumbar central stenosis with the full-endoscopic interlaminar versus microsurgical laminotomy technique: a prospective, randomized, controlled study. *Pain Physician* 2015;18: 61–70.
- [20] Mochida J, Toh E, Nomura T, et al. The risks and benefits of percutaneous nucleotomy for lumbar disc herniation. A 10-year longitudinal study. *J Bone Joint Surg Br* 2001;83:501–5.
- [21] Passacantilli E, Lenzi J, Caporlingua F, et al. Endoscopic interlaminar approach for intracanal l5-s1 disc herniation: classification of disc prolapse in relation to learning curve and surgical outcome. *Asian J Endosc Surg* 2015;8:445–53.
- [22] Hsu HT, Chang SJ, Yang SS, et al. Learning curve of full-endoscopic lumbar discectomy. *Eur Spine J* 2013;22:727–33.
- [23] Ebeling U, Reichenberg W, Reulen HJ. Results of microsurgical lumbar discectomy. Review on 485 patients. *Acta Neurochir (Wien)* 1986;81:45–52.
- [24] Williams RW. Microlumbar discectomy. A 12-year statistical review. *Spine (Phila Pa 1976)* 1986;11:851–2.
- [25] Nystrom B. Experience of microsurgical compared with conventional technique in lumbar disc operations. *Acta Neurol Scand* 1987;76:129–41.
- [26] Hermantin FU, Peters T, Quartararo L, et al. A prospective, randomized study comparing the results of open discectomy with those of video-assisted arthroscopic microdiscectomy. *J Bone Joint Surg Am* 1999;81: 958–65.
- [27] Annertz M, Jonsson B, Stromqvist B, et al. No relationship between epidural fibrosis and sciatica in the lumbar postdiscectomy syndrome. A study with contrast-enhanced magnetic resonance imaging in symptomatic and asymptomatic patients. *Spine (Phila Pa 1976)* 1995;20:449–53.
- [28] Choi KC, Kim JS, Ryu KS, et al. Percutaneous endoscopic lumbar discectomy for l5-s1 disc herniation: transforaminal versus interlaminar approach. *Pain Physician* 2013;16:547–56.