

Case Report

Lower lip numbness due to the mandibular canal narrowing after dental reimplantation: A case report

Nafiseh Shamloo¹, Yaser Safi², Kamyar Fathpour³, Masood Yaghmaei⁴, Nika Bahemmat⁵

Departments of ¹Oral and Maxillofacial Pathology, ²Oral and Maxillofacial Radiology, and ⁴Oral and Maxillofacial Surgery, School of Dentistry, Shahid Beheshti University of Medical Sciences, Tehran, ³Dental Materials Research Center and Department of Operative Dentistry, Faculty of Dentistry, Isfahan University of Medical Sciences, Isfahan, ⁵Department of Oral and Maxillofacial Radiology, Faculty of Dentistry, Alborz University of Medical Sciences, Karaj, Iran

ABSTRACT

Mandibular canal is the most important anatomical landmark in the body of mandible which always must be considered for implant surgery in posterior mandibular region. Damage to vessels and inferior alveolar nerve that passes through the mandibular canal can cause problems such as hemorrhage and neurosensory disturbances. Damage to the mandibular canal can occur during implant surgery. Depending on the severity of injuries, it would result in temporary or permanent neurosensory disturbances. We have reported a case that mandibular canal narrowing occurred following implant surgery and resulted in anesthetic and hypoesthetic areas in the lower lip. Patient had a history of implant surgery in the region of teeth numbered 30 and numbered 31. The inserted implant failed after 6 years, and reimplantation was done in this area, but due to lower lip numbness in the right side, the second implant was removed, and another implant was inserted in the region of the tooth numbered 32. After 2 years, right lower lip numbness was reported again by the patient. Cone beam computed tomography images showed canal narrowing in the region of the tooth numbered 31 where the second implant was inserted. It seems that the main cause for anesthesia and hypoesthesia in this patient is canal narrowing due to damage during implant replacement and removal.

Key Words: Cone beam computed tomography, implant, inferior alveolar canal, mandible

Received: July 2014

Accepted: September 2014

Address for correspondence:

Dr. Nika Bahemmat,
Department of Oral and
Maxillofacial Radiology,
Faculty of Dentistry, Alborz
University of Medical
Sciences, Karaj, Iran.
E-mail: nika_bahemmat@
yahoo.co.in

INTRODUCTION

Mandibular canal is a canal within the mandible that begins from mandibular foramen on the medial surface of the ascending ramus. It turns obliquely downward and forward in the ramus, and then horizontally forward in the mandible body and terminates in mental foramen. It carries inferior alveolar neurovascular bundle.^[1]

Dental implant surgery has become routine treatment in dentistry and is generally considered to be a successful

surgical method. However, complications should be taken into consideration. Errors in evaluation and planning, errors in injection of local anesthetic for the implant surgery procedure, bone preparation (drilling) mistakes, and placement errors of the implant are four most frequent causes of injury to the mandibular nerve related to dental implant surgery. Nerve damage may result in damages ranging from mild paresthesia to complete anesthesia or even disabling dysesthesia.^[2]

The following case report describes dental implant treatment for a patient which caused lower lip numbness by a compression phenomenon in the mandibular canal in the site of the implant.

CASE REPORT

A 60-year-old man was referred from a dental clinic to the author's clinic due to lower lip numbness in the

Access this article online



Website: www.drj.ir
www.drjjournal.net
www.ncbi.nlm.nih.gov/pmc/journals/1480

right side. The complication started after one implant was inserted in the region of right mandibular molar.

In 2005, patient had a history of implant surgery in the region of teeth numbered 30 and numbered 31 [Figure 1a and b]. The size of implant in the region of the tooth numbered 31 was 4 mm × 12 mm. (Meastro implant, Biohorizon external system, Birmingham, USA). According to the surgical guidelines, the implant was inserted with 35 N/cm² torque. The surgeon considered it as optimal primary stability for two stage approach. This implant failed after 6 years in 2011. The patient had a history of comprehensive periodontal treatment due to generalized mild-moderate chronic periodontitis. The maintenance phase was incomplete and plaque index was 55% at the time of implant failure. Considering plaque accumulation and misdirection of supra structure, we diagnosed the failure to be due to biological and biomechanical factors. The dentist removed failed implant by surgery and unscrewing technique with approximate torque of 60 N/cm². A new implant was replaced (Meastro implant, Biohorizon internal system, Birmingham, USA). According to the surgical guidelines, the implant was inserted with 25 N/cm² torque as optimal primary stability. The implant size was 5 mm × 10.5 mm. The amount of keratinized gingiva was sufficient and about 3 mm. A few days after replacement surgery, the patient reported lower lip numbness in the right side. The invasion to the mandibular canal was obvious in panoramic radiograph [Figure 1c]. Because of this complication, dentist removed the implant after 1 week and replaced another implant posterior to this area, in the region of the tooth numbered 32. The distance between this new implant and inferior alveolar canal (IAC) was about 2 mm. Patient reported improvement in the sign following the last implant removal in the region of the tooth numbered 31.

In 2013, patient was referred to our clinic with complication of right lower lip numbness again, and numbness was exacerbating with time. Sensory deprivation mapping was done around the lower lip, which is shown in the Figure 2. The red outlined region is the area of anesthesia, and the blue bordered region is the hypoesthetic site.

Cone beam computed tomography (CBCT) images were provided with Soredex's Scanora 3D scanner machine (Helsinki, Finland, Voxel size: 200 μm, Field of view: 7.5 cm × 10 cm). In CBCT images, abnormal narrowing of the mandibular canal was observed in the

tooth numbered 31 area where the second implant was inserted and then removed [Figure 3]. It was interesting that canal narrowing in the mentioned area was in all directions including buccal, lingual, upper and lower borders. The diameter of the mandibular canal in the

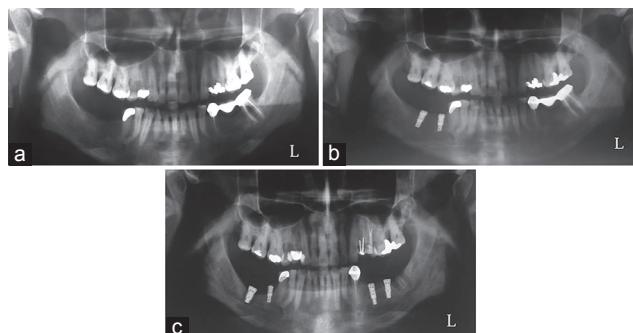


Figure 1: (a and b) Panoramic radiographs show implant replacement in the region of teeth numbered 30 and 31. (c) The interaction of the implant with the mandibular canal is obvious in panoramic radiograph.

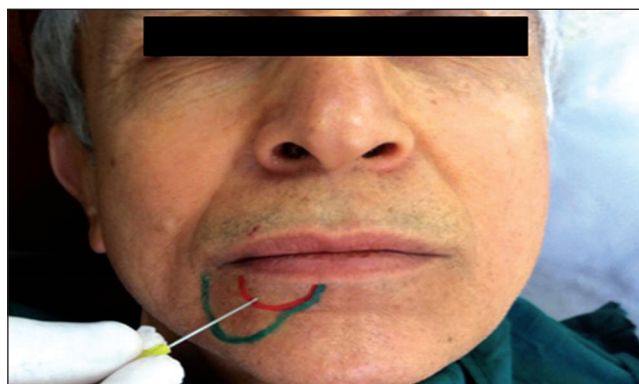


Figure 2: Sensory deprivation mapping was done around the lower lip. The red outlined region is the area of anesthesia, and the blue bordered region is the hypoesthetic site.

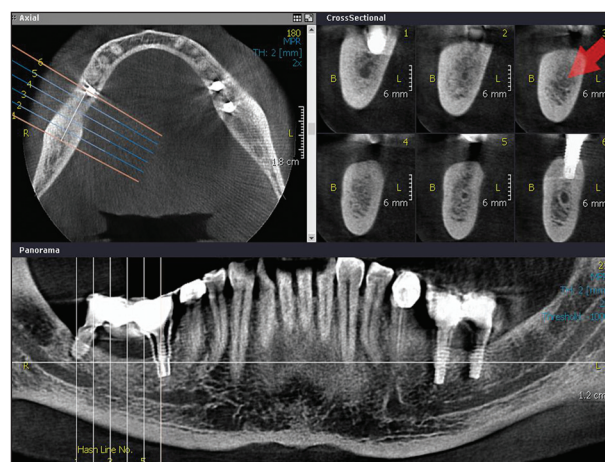


Figure 3: Cone beam computed tomography images show abnormal narrowing of the mandibular canal in the region of right second molar.

narrowed area was 0.2 mm, but the average canal diameter except the narrowing site was 3.2 mm. It should be mentioned that digital panoramic radiographs have high sensitivity to show narrowing of the canal.^[3]

It seems that the main cause for anesthesia and hypoesthesia in this patient is canal narrowing due to damage during implant replacement and removal. Exacerbation of canal narrowing leads to anesthetic area enlargement.

DISCUSSION

More than 70% of dentists have experienced patients with postoperative paresthesia/dysesthesia or anesthesia as a result of dental procedures. The most common nerve affected is the mandibular nerve, which may be injured during either implant surgery or bone grafting procedures.^[4] Nerve injury after implant surgery can be caused by direct injury of drilling or indirect injury. Indirect nerve injury may occur more frequently in a nerve that is not protected by a bony canal.^[5]

Nerve injury caused by implant placement may occur despite correct osseous preparation, when the implant is inserted beyond the vertical confines of the prepared bone, compressing or breaching the superior wall of IAC and forcing bone into the canal. Delayed osseous healing and remodeling from localized injury can cause excess bone formation and compromise the IAC cross-sectional diameter. Hence, remodeling of the IAC cortical rim causes narrowing of the canal and can compress the inferior alveolar nerve (IAN).^[2]

When the IAN fibers are damaged by implant fixtures, retrograde degeneration toward the central nervous system and Wallerian degeneration toward the periphery starts from around the site of the injury within just a few minutes. Even if the nerve fibers become disconnected, they will be rapidly reconnected when the implant fixtures are removed. These defense mechanisms and repair reactions can be completed within 2-3 weeks.^[6] It can justify the improvement in lip numbness in our case after removal of the interacting canal implant.

Seddon described three levels of nerve injury, based on the severity of the injury, the prognosis and the time for recovery: Neuropraxia, axonotmesis, and neurotmesis. Neuropraxia is most commonly due to compression of the nerve. Recovery is complete and takes a few hours to days. Axonotmesis is defined as a loss of nerve continuity. In this situation, the recovery, which takes several months, is ultimately incomplete. Neurotmesis

is the most severe grade of injury to the peripheral nerve. Complete recovery is impossible, although partial recovery may occur if primary repair is undertaken.^[7] The main mechanism of injury to peripheral nerves is compression. Compression of the arterial blood supply to the nerve results in increased vascular permeability, edema and ischemia, and the amount of oxygen delivered to the nerve is, thereby reduced.^[5] The classic response in cases of neuropraxia is paresthesia, but axonotmesis may also occur if the compression lasts long enough. In these cases, the recovery phase can take up to 1 year.^[8,9]

In this case, it seems that osseous remodeling in cortical mandibular borders of IAC caused narrowing in the canal. It seems that this progressive narrowing in canal compresses IAN bundle that leads to lower lip numbness in this patient.

REFERENCES

1. Juodzbalsys G, Wang HL, Sabalys G. Anatomy of mandibular vital structures. Part I: Mandibular canal and inferior alveolar neurovascular bundle in relation with dental implantology. *J Oral Maxillofac Res* 2010;1:e2.
2. Bagheri SC, Meyer RA. Management of mandibular nerve injuries from dental implants. *Atlas Oral Maxillofac Surg Clin North Am* 2011;19:47-61.
3. Szalma J, Lempel E, Jeges S, Olasz L. Digital versus conventional panoramic radiography in predicting inferior alveolar nerve injury after mandibular third molar removal. *J Craniofac Surg* 2012;23:e155-8.
4. Misch CE, Resnik R. Mandibular nerve neurosensory impairment after dental implant surgery: Management and protocol. *Implant Dent* 2010;19:378-86.
5. Park YT, Kim SG, Moon SY. Indirect compressive injury to the inferior alveolar nerve caused by dental implant placement. *J Oral Maxillofac Surg* 2012;70:e258-9.
6. Fukuda K, Ichinohe T, Kaneko Y. Pain management for nerve injury following dental implant surgery at Tokyo dental college hospital. *Int J Dent* 2012;2012:209474.
7. Seddon HJ. Three types of nerve injury. *Brain J Neurol* 1943;66:237-88.
8. Marques TM, Gomes JM. Decompression of inferior alveolar nerve: Case report. *J Can Dent Assoc* 2011;77:b34.
9. Rodríguez-Lozano FJ, Sanchez-Pérez A, Moya-Villaescusa MJ, Rodríguez-Lozano A, Sáez-Yuguero MR. Neuropathic orofacial pain after dental implant placement: Review of the literature and case report. *Oral Surg Oral Med Oral Pathol Oral Radiol Endod* 2010;109:e8-12.

How to cite this article: Shamloo N, Safi Y, Fathpour K, Yaghmaei M, Bahemmat N. Lower lip numbness due to the mandibular canal narrowing after dental reimplantation: A case report. *Dent Res J* 2015;12:386-8.

Source of Support: Nil. **Conflicts of Interest:** The authors of this manuscript declare that they have no conflicts of interest, real or perceived, financial or nonfinancial in this article.