



Since January 2020 Elsevier has created a COVID-19 resource centre with free information in English and Mandarin on the novel coronavirus COVID-19. The COVID-19 resource centre is hosted on Elsevier Connect, the company's public news and information website.

Elsevier hereby grants permission to make all its COVID-19-related research that is available on the COVID-19 resource centre - including this research content - immediately available in PubMed Central and other publicly funded repositories, such as the WHO COVID database with rights for unrestricted research re-use and analyses in any form or by any means with acknowledgement of the original source. These permissions are granted for free by Elsevier for as long as the COVID-19 resource centre remains active.

Feline Coronavirus Infection

Jane E. Sykes



Overview of Feline Coronavirus Infections

First Described: 1963¹; a viral etiology was not identified until the 1970s.

Cause: Feline coronavirus (Family Coronaviridae, genus *Coronavirus*)

Affected Hosts: Cats and wild felids, especially cheetahs

Mode of Transmission: Fecal-oral

Geographic Distribution: Worldwide

Major Clinical Signs: Fever, lethargy, inappetence, vomiting, diarrhea, dehydration, icterus, tachypnea, uveitis, neurologic signs, abdominal distention due to ascites.

Differential Diagnoses: Toxoplasmosis, congestive heart failure, carcinomatosis, lymphoma, pancreatitis, rabies, cryptococcosis, bacterial peritonitis, pyothorax, bacterial meningitis, chronic stomatitis, multiple myeloma, infection with FeLV or FIV.

Human Health Significance: Feline coronaviruses do not infect humans.

Etiology and Epidemiology

Coronaviruses are large, enveloped, single-stranded RNA viruses with club-shaped spikes on their outer surface (see Figure 14-1, B). They have the largest RNA genomes of all known viruses. Feline coronaviruses (FCoV), like canine enteric coronavirus, belong to the Group 1a coronaviruses (see Box 17-1). In fact, even canine enteric coronavirus has the potential to infect cats and cause diseases similar to those caused by FCoV.² Among FCoVs, there are two different serotypes, type I and type II, which use different receptors for cellular entry *in vitro*^{3,4} but cause the same clinical manifestations. Type I strains predominate worldwide.⁵⁻⁷ Type II strains, which are thought to have evolved from genetic recombination between canine enteric coronavirus and FCoV, are more readily grown in culture and so have been more extensively studied; they possess a spike protein that resembles that of canine enteric coronavirus.

FCoVs cause enteric disease in cats as well as feline infectious peritonitis (FIP), a serious systemic pyogranulomatous to granulomatous disease that progresses over a period of weeks to months and, once it occurs, is ultimately always fatal. FIP is a major cause of death in young and young adult cats, especially cats from multicat environments such as purebred catteries and shelters. Wild cats, especially cheetahs, are also susceptible.⁸ The vast majority of domestic cats that develop FIP are

3 months to 3 years of age, with at least 50% of affected cats aged 12 months or younger (Figure 20-1). However, FIP can occur at any age, and there is a secondary peak of incidence in geriatric cats (>10 years of age), possibly as a result of sub-optimal immune function. Males and sexually intact cats have been predisposed in some studies,⁹⁻¹¹ and a disease peak may exist in the fall and winter.¹² Although the disease occurs in all breeds, purebred cats are more susceptible; Abyssinians, Australian mist, Bengals, birmans, Burmese, British shorthairs, Himalayans, ragdolls, rexes, and possibly Scottish folds may be predisposed.⁹⁻¹⁴ Breed predispositions may vary geographically and temporally depending on the preferences of breeders in a region, and specific lines may be more predisposed than the breeds themselves.⁶ The molecular basis of genetic susceptibility to FIP is currently unclear. Siblings of cats that die of FIP may be at increased risk for FIP.¹⁵

In multiple-cat household situations, cats are repeatedly infected, shed virus, and recover, but some cats remain persistently infected and chronically shed FCoV in the absence of clinical signs (Figure 20-2). More than half, and as many as 100% of cats in environments with more than six cats, become infected with FCoVs.⁶ The seroprevalence is lower in cats from single-cat households and among feral cats.¹⁶ However, even though the prevalence of infection in multicat households is high, fewer than 10% of cats from large, multicat households ultimately develop FIP. Thus, although the incidence of *infection* is high, the incidence of *disease* in single- or two-cat households is only around 1 in 5000; in catteries it is around 5% to 10%.^{17,18} Provided they are unrelated by birth, cats in households with a history of FIP are not more likely to develop FIP than cats in households without FIP.¹⁹ Thus, FIP is usually a sporadic disease that does not spread from one cat to another. However, every few years, epidemics of disease can occur in catteries or shelters, with mortality rates that exceed 10%.¹² Because it is an enveloped virus, FCoV is readily inactivated by disinfectants and generally survives less than a day or two at room temperature. However, the possibility of prolonged survival (up to 7 weeks) in the environment under certain conditions has been suggested.^{15,20} In this situation, fomites might play an important role in transmission.

The epidemiology and pathogenesis of FIP has both fascinated and confused veterinary virologists worldwide for decades. The most widely accepted theory (the “internal mutation hypothesis”) is that cats are initially infected with a low-pathogenicity coronavirus after oronasal exposure, which results either in no signs, or mild enteric disease. This low-pathogenicity virus has been referred to as *feline enteric coronavirus* in some publications in order to distinguish it from virulent FIP virus. The use of this name has been controversial, because although the virus is primarily confined to the gastrointestinal tract (and especially colonic epithelial cells), FCoV RNA can also be found in blood

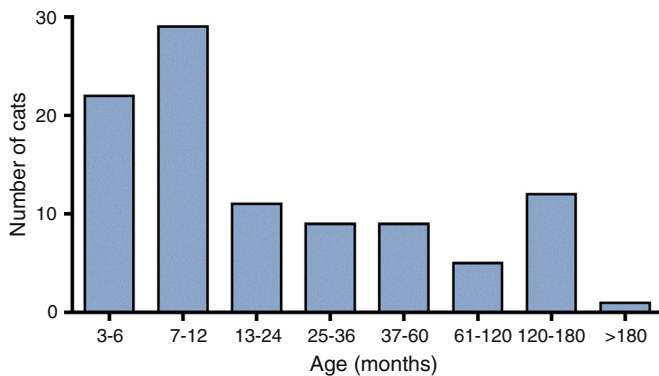


FIGURE 20-1 Age distribution of 99 cats with necropsy-confirmed FIP at the UC Davis VMTH. An additional six cats were reported to be “juvenile” or kittens. There were 38 females (17 intact) and 66 males (22 intact).

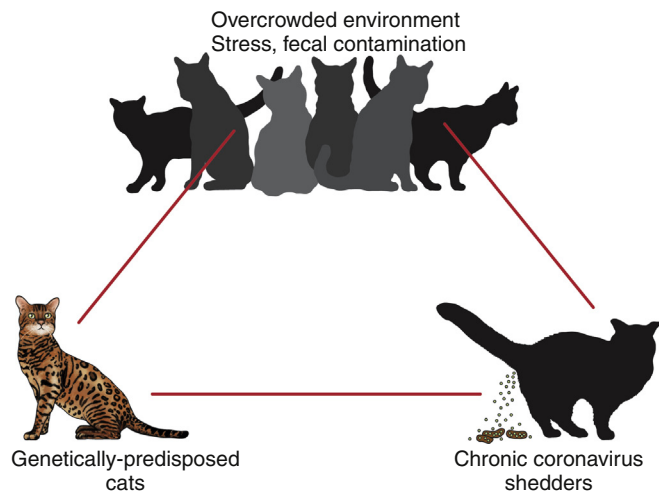


FIGURE 20-2 Interplay between genetics, virus shedding, and environment in feline coronavirus infections and FIP.

and tissue macrophages of cats that do not have FIP.^{21,22} In some infected cats, the low-pathogenicity virus is believed to mutate to a virulent strain that can multiply within macrophages without hindrance by the immune system and incite a systemic pyogranulomatous vasculitis. The mutation may occur shortly after initial infection, or years later, which may explain why some indoor cats from single-cat households develop FIP several years after they are acquired. Virulent strains may not be able to replicate effectively within the gut,²³ which may be the reason why cat-to-cat transmission of FIP does not occur, yet the disease can be transmitted effectively by inoculating naïve cats with effusion from a cat with FIP. Factors that contribute to immunosuppression, such as concurrent viral infection, stress due to overcrowding, surgery, or transport, and especially genetic factors may allow viral replication and mutation to proceed unchecked. Simultaneous immune compromise of a large number of cats, such as in a shelter situation, may explain epidemics of FIP. Other risk factors for FIP include regular introduction of new cats to a cattery and the proportion of cats in a cattery that shed coronavirus chronically.¹² There is no distinct mutation that allows avirulent FCoV strains to be differentiated from virulent strains, and therefore no diagnostic test exists that distinguishes FIP from benign

FCoV strains. However, mutations in the spike protein gene,^{24,25} membrane protein gene,²⁶ and the nonstructural 3c and 7b genes^{23,27-29} may play a role. In particular, the 3c gene appears to be disrupted in many (but not all) virulent FCoV strains.

The other hypothesis proposed to explain the pathogenesis of FIP is that distinct circulating virulent and avirulent FCoV strains exist, and the combination of infection with a virulent FCoV and an individual cat's genetic and environmental predispositions leads to FIP.²⁵ It has also been suggested that both hypotheses may play a role.³⁰

Clinical Features

Signs and Their Pathogenesis

Cats are usually infected with FCoV by oronasal exposure to virus in feces or fomites contaminated with fecal material. Shared litter boxes are thought to play a major role in transmission.¹⁵ Replication of low-pathogenicity strains of FCoV in epithelial cells at the tips of intestinal villi may be associated with no signs, or acute or chronic, persistent or intermittent small-bowel diarrhea, and less commonly, vomiting and/or inappetence. Transient upper respiratory signs have been reported in some cats on initial infection with FCoV.¹⁵ Virus is shed in the feces from 1 week after infection. Some cats then shed large quantities of virus continuously for life.^{12,22,31-33}

Both serotype I and serotype II strains appear to enter macrophages via a lectin receptor known as fDC-SIGN (feline dendritic cell-specific intercellular adhesion molecule grabbing non-integrin receptor).^{3,34} Replication of virulent FCoV strains within macrophages results in two forms of disease, which reflect the immune response mounted by the host. FIP is an immune complex disease. *Noneffusive* (“dry”) FIP occurs in cats that mount a partial CMI response and is characterized by pyogranulomatous to granulomatous inflammation within a variety of organs, but especially the mesenteric lymph nodes, kidneys, liver, lungs, brain, and eye. Solitary or multifocal granulomas of the intestinal wall also occasionally develop, especially in the region of the ileocecal junction (Figure 20-3).¹⁵ *Effusive* (“wet”) FIP occurs in cats that are unable to mount an immune response and is characterized by accumulation of high protein exudates in the thorax and/or abdomen, which typically contain low numbers of cells. Production of vascular endothelial growth factor by infected monocytes may lead to increased vascular permeability and contribute to cavitory effusion.³⁵ Many cats have a mixture of both forms of the disease, and noneffusive disease may progress to effusive disease. Infection itself results in immune dysregulation, with a profound, virus-induced depletion of CD4+ and CD8+ cells; production of TNF- α , granulocyte-macrophage colony stimulating factor (GM-CSF), and granulocyte colony-stimulating factor (G-CSF) by infected macrophages; impaired IFN- γ production; and hypergammaglobulinemia.³⁶⁻³⁸ The mechanism of T-cell depletion is not clear, as the virus does not infect lymphocytes, only monocytes and macrophages. Infection of antigen-presenting cells, specifically dendritic cells, has been hypothesized to lead to T-cell apoptosis. Progressive immune system failure may be associated with a conversion to predominantly effusive disease manifestations. Despite the profound T-cell deficiency that accompanies FIP, opportunistic infections are rarely reported. Nevertheless, concurrent infections with retroviruses and *Toxoplasma gondii* and opportunistic bacterial infections can occur;⁶ the author is aware of one cat that was co-infected with *Sporothrix schenckii*.

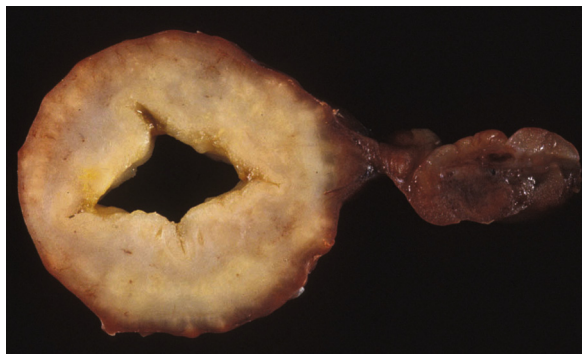

FIGURE 20-3 Colonic mass removed at surgery from a 7-month-old female spayed domestic shorthair with anorexia and hematochezia. Histopathology showed severe, multifocal coalescing pyogranulomatous colitis and lymphadenitis. (Courtesy of the University of California, Davis Veterinary Anatomic Pathology service.)

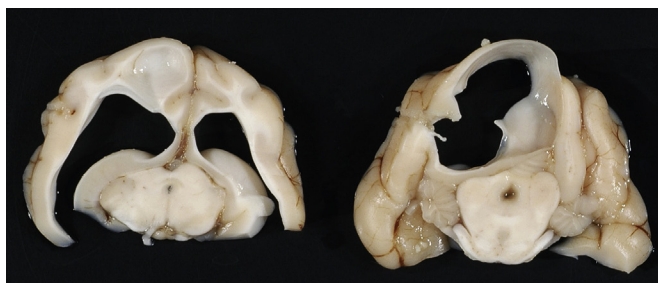


FIGURE 20-4 Obstructive hydrocephalus in an 8-month-old male neutered exotic shorthair cat that developed ataxia and head tremors. Hydrocephalus and secondary cerebellar herniation were found at necropsy. Histopathology revealed severe, multifocal pyogranulomatous meningoencephalitis, choroiditis, and ventriculitis, and pyogranulomatous inflammatory lesions were also found throughout the thoracic and abdominal viscera. (Courtesy of the University of California, Davis Veterinary Anatomic Pathology service.)

The incubation period for FIP is highly variable. Kittens usually become infected at 4 to 8 weeks of age, when maternal antibody begins to wane, but infections have been reported in kittens as young as 2 weeks of age.²⁰ Disease may occur a few weeks after infection or years later, but most often it occurs 6 to 18 months after initial infection.¹⁹ Even after the onset of systemic pyogranulomatous inflammatory disease, clinical signs may not be apparent for months. In support of this, lesions consistent with FIP have been found incidentally in cats during abdominal surgery such as ovariohysterectomy.²⁰

The clinical signs of FIP often change over time and depend on the organs affected and the relative predominance of inflammatory versus effusive disease manifestations. The most common signs are lethargy and inappetence, as well as a fluctuating fever that does not respond to antibacterial drug treatment. Nevertheless, many cats are bright, appetent, and in good body condition early in the course of illness. Some cats have increased thirst and urination, possibly secondary to pyrexia. Ultimately, weight loss develops, but owners of cats that develop abdominal distention may mistake the distention for weight gain or pregnancy. Stunted growth may occur in affected kittens. Pleural effusion may be associated with tachypnea and respiratory distress. Testicular enlargement may occur in cats with serositis that involves the tunica vaginalis. FIP is responsible for approximately 10% of pericardial effusions in cats, the third most common cause of pericardial effusion after cardiomyopathy and

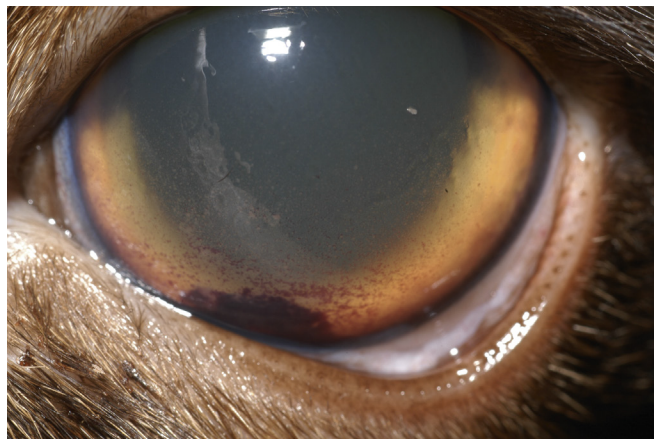


FIGURE 20-5 Keratic precipitates in a 5-year-old intact male Burmese cat with FIP. (Courtesy of the University of California, Davis Veterinary Ophthalmology service.)

neoplasia.³⁹ Rarely, pericardial effusion results in cardiac tamponade. Pyogranulomatous or granulomatous inflammation may lead to mesenteric lymphadenomegaly, irregular renomegaly, intestinal masses, hepatomegaly, icterus, pneumonia, uveitis, chorioretinitis, and, rarely, nodular skin lesions. Neurologic signs, which can include focal or generalized seizures, occur in at least 10% of cats with FIP and result primarily from meningoencephalitis, meningomyelitis, ependymitis, choroiditis, and obstructive hydrocephalus. Obstructive hydrocephalus occurs secondary to choroiditis and ependymitis (Figure 20-4). In one study, FIP was responsible for almost half of all neurologic disease in 97 cats due to infectious or inflammatory causes.⁴⁰ Occasionally profound anemia occurs secondary to immune-mediated hemolysis^{13,14} or possibly microangiopathic damage, whereby erythrocytes are lysed as they travel through inflamed blood vessels. Immune-mediated glomerulonephritis has also been reported, and FIP should always be considered in cats with protein-losing nephropathy, which is otherwise rare in cats.⁴¹ Uncommonly, lameness occurs as a result of synovitis.⁶

Physical Examination Findings

Physical examination findings in cats with FIP reflect the type of disease present (effusive versus noneffusive) and the location where lesions occur. Cats with respiratory tract involvement may show tachypnea, and if there is pleural effusion, a rapid, shallow breathing pattern and muffled heart and lung sounds may be present. Other signs include pyrexia, dehydration, mucosal pallor or icterus, a thin body condition, and evidence of ascites. Abdominal palpation may reveal hepatomegaly, irregular renomegaly, and/or abdominal mass lesions that result from mesenteric lymphadenomegaly or intestinal pyogranulomas. Sometimes pain is appreciated on abdominal palpation, which may reflect pancreatic involvement in some cats. Testicular enlargement may be detected in intact male cats. A wide range of neurologic signs may be present, such as obtundation, twitching, tremors, behavioral changes, nystagmus, hyperesthesia, exaggerated segmental reflexes, ataxia, urinary incontinence, or cranial nerve defects. Ocular signs include conjunctivitis, mucopurulent ocular discharge, thickening and hyperemia of the nictitans, uveitis with dyscoria or anisocoria, aqueous flare, keratic precipitates, hypopyon, hyphema, chorioretinitis, perivascular infiltrates, retinal detachment, or blindness (Figure 20-5).

TABLE 20-1

Complete Blood Count Findings at Admission in 38 Cats with Necropsy-Confirmed Feline Infectious Peritonitis at the UC Davis VMTH

| Test | Reference Range | Percent below the Reference Range | Percent within the Reference Range | Percent above the Reference Range | Range for Cats with FIP | Number Tested |
|---------------------------------------|-----------------|-----------------------------------|------------------------------------|-----------------------------------|-------------------------|-----------------|
| Hematocrit (%) | 30-50 | 68 | 32 | 0 | 17-53 | 38 |
| MCV (fL) | 65-75 | 18 | 82 | 0 | 36-52 | 38 |
| MCHC (g/dL) | 33-36 | 5 | 58 | 37 | 28-36 | 38 |
| RDW (%) | 14-18 | 0 | 30 | 70 | 14-33 | 27 |
| Neutrophils* (cells/ μ L) | 2000-9000 | 3 | 26 | 71 | 416-49,313 | 38 |
| Band neutrophils* (cells/ μ L) | 0-rare | 0 | 50 | 50 | 0-3251 | 38 |
| Metamyelocytes (cells/ μ L) | 0 | 0 | 95 | 5 | 0-276 | 38 |
| Monocytes (cells/ μ L) | 50-600 | 5 | 71 | 24 | 0-820 | 38 |
| Lymphocytes (cells/ μ L) | 1000-7000 | 58 | 42 | 0 | 89-6886 | 38 |
| Eosinophils (cells/ μ L) | 150-1100 | 71 | 29 | 0 | 0-770 | 38 |
| Platelets (cells/ μ L) | 180,000-500,000 | 37 | 44 | 19 | 30,000-874,000 | 27 [†] |

FIP, Feline infectious peritonitis; RDW, red cell distribution width.

*22 (58%) had evidence of toxic neutrophils.

[†]A smear was evaluated manually for 37 of the 38 cats. The presence of macroplatelets were reported for 18 (49%) of cats.

Diagnosis

Currently, definitive diagnosis of FIP is made only by immunohistochemical staining for coronavirus antigen within lesions characterized by pyogranulomatous or granulomatous vasculitis. Because it can be difficult or impossible to safely obtain biopsy specimens from cats with FIP, antemortem diagnosis is often only suspected on the basis of history, signalment, and clinical and laboratory findings, and by ruling out other causes of disease. Provided it is correctly performed and interpreted, immunocytochemistry may be helpful. Because the presence of the characteristic effusion is most helpful for antemortem diagnosis, efforts should be always made to identify and analyze any fluid that is present in body cavities. When owner funds are limited, laboratory analysis of effusion, rather than blood, may be the most economic diagnostic approach. Unfortunately, the lack of a definitive noninvasive diagnostic assay for FIP and the extremely poor prognosis sometimes leads clinicians to perform large numbers of diagnostic tests in the hope that an answer will appear. In other situations, the diagnosis of FIP is made too hastily, and euthanasia is performed without sufficient clinical and laboratory justification.

Laboratory Abnormalities

Complete Blood Count

A mild, nonregenerative anemia is often present in cats with FIP, and sometimes severe anemia occurs, which is usually poorly

regenerative or nonregenerative (Table 20-1). Microcytosis may be present. Examination of erythrocyte morphology occasionally reveals schistocytosis, mild normoblastosis, or agglutination. There may be a leukocytosis due to a neutrophilia and monocytosis, or leukopenia. Lymphopenia occurs in more than 50% of affected cats, and eosinopenia is also common. In some cats, a left shift and evidence of toxic neutrophils are seen. Mild to moderate thrombocytopenia is common in cats with noneffusive disease and may reflect the presence of disseminated intravascular coagulation or immune-mediated platelet destruction. However, thrombocytosis can also occur.

Serum Biochemical Tests

Many cats with FIP have hyperproteinemia due to hyperglobulinemia, which results from a polyclonal gammopathy (Figure 20-6). Rarely, a monoclonal gammopathy can occur.⁴² Total protein concentrations may be as high as 12 g/dL (Table 20-2).²⁰ In one study, hyperglobulinemia was present in 50% of cats with effusion and 70% of cats without effusion.⁴³ Globulin concentration may decrease terminally, so cats with advanced disease may have protein concentrations that are within the reference range.¹⁴ Hypoalbuminemia is often present because of liver involvement, leakage from damaged vessels, urinary loss in cats with glomerulonephritis, or inflammation (albumin is a negative acute-phase reactant protein). Thus, the serum albumin:globulin ratio

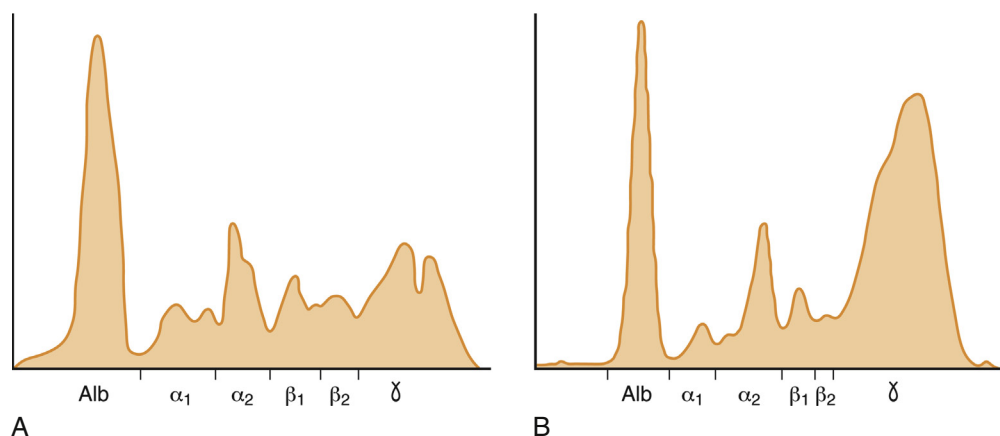


FIGURE 20-6 A, Densitometric scan of serum protein electrophoresis of normal feline serum. B, Scan from a 9-month-old male neutered domestic shorthair cat with FIP. There is a polyclonal gammopathy, represented by a broad peak in the γ -globulin region, with a mild decrease in the albumin and mild increases in the α_2 and β_1 fractions. (A redrawn from Baker RJ, Valli VE. Electrophoretic and immunoelectrophoretic analysis of feline serum proteins. *Am J Vet Res* 1988;52[3]:308-304.)

TABLE 20-2

Findings on Serum Biochemistry Analysis in 36 Cats with Necropsy-Confirmed Feline Infectious Peritonitis at the UC Davis VMTH

| Test | Reference Range | Percent below the Reference Range | Percent within the Reference Range | Percent above the Reference Range | Range for cats with FIP | Number of Cats Tested |
|-------------------------|-----------------|-----------------------------------|------------------------------------|-----------------------------------|-------------------------|-----------------------|
| Sodium (mmol/L) | 151-158 | 94 | 6 | 0 | 129-152 | 35 |
| Potassium (mmol/L) | 3.6-4.9 | 26 | 74 | 0 | 2.2-5.4 | 35 |
| Chloride (mmol/L) | 117-126 | 91 | 9 | 0 | 94-121 | 35 |
| Bicarbonate (mmol/L) | 15-21 | 8 | 75 | 17 | 12-25 | 36 |
| Calcium (mg/dL) | 9.0-10.9 | 56 | 44 | 0 | 6.6-10.6 | 36 |
| Phosphorus (mg/dL) | 3.2-6.3 | 8 | 69 | 22 | 1.9-8.4 | 36 |
| Creatinine (mg/dL) | 1.1-2.2 | 69 | 28 | 3 | 0.4-2.8 | 36 |
| BUN (mg/dL) | 18-33 | 56 | 31 | 14 | 10-58 | 36 |
| Glucose (mg/dL) | 63-118 | 0 | 47 | 53 | 63-381 | 36 |
| Total protein (g/dL) | 6.6-8.4 | 31 | 28 | 42 | 4.1-11.9 | 36 |
| Albumin (g/dL) | 2.2-4.6 | 50 | 50 | 0 | 0.9-3.6 | 36 |
| Globulin (g/dL) | 2.8-5.4 | 3 | 42 | 56 | 2.5-9.4 | 36 |
| Cholesterol (mg/dL) | 89-258 | 17 | 83 | 0 | 56-247 | 36 |
| Total bilirubin (mg/dL) | 0-0.2 | 0 | 40 | 60 | 0-5.3 | 36 |
| ALT (U/L) | 27-101 | 50 | 25 | 25 | 18-648 | 36 |
| AST (U/L) | 17-58 | 6 | 43 | 51 | 0-1554 | 36 |
| ALP (U/L) | 14-71 | 28 | 61 | 11 | 0-161 | 36 |
| GGT (U/L) | 0-4 | 0 | 96 | 4 | 0-5 | 23 |

FIP, feline infectious peritonitis.

may be more useful than the globulin alone for diagnosis; ratios less than 0.8 are uncommon (but not impossible) in cats with FIP, so they help to rule out (but not to rule in) a diagnosis of FIP.^{44,45} Other variable findings include hyponatremia, hypokalemia, hypochloremia, hyperglycemia, azotemia, increased liver enzyme activities, hypocholesterolemia, and hyperbilirubinemia. The cause of hyperbilirubinemia is

not clear, but it may result from hemolysis, hepatic necrosis, and/or cholestasis.

Measurement of α_1 -acid glycoprotein (an acute phase protein) has been suggested for diagnosis, because serum concentrations often exceed 1500 $\mu\text{g}/\text{mL}$ in cats with FIP.^{20,46,47} However, α_1 -acid glycoprotein concentrations also increase with other inflammatory diseases.²⁰

TABLE 20-3

Composition of Body Cavity Effusions from 21 Cats with Necropsy-Confirmed Feline Infectious Peritonitis at the UC Davis VMTH

| Test | Range | Mean \pm SD | Number of Cats Tested |
|----------------------|-------------|-----------------|-----------------------|
| Total protein (g/dL) | 2.9-8.1 | 5.1 \pm 1.8 | 21 |
| RBC (cells/ μ L) | <100-38,600 | ND | 18 |
| TNC (cells/ μ L) | 200-13,200 | 3683 \pm 3474 | 19 |
| Neutrophils (%) | 3-97 | 61 \pm 28 | 21 |
| Lymphocytes (%) | 0-22 | 6 \pm 6 | 21 |
| Monocytes (%) | 1-96 | 33 \pm 26 | 21 |

Nineteen specimens were abdominal and two were pleural effusions. ND, Not determined; SD, standard deviation; TNC, total neutrophil count.

Urinalysis

The urinalysis in cats with FIP may be unremarkable or contain protein due to glomerular or tubular damage. Hematuria and, less commonly, pyuria and cylindruria may be present. Bilirubinuria may be detected in cats with liver injury.

Coagulation Profile

In addition to thrombocytopenia, abnormalities of coagulation in cats with FIP include prolonged prothrombin time and partial thromboplastin time as a result of severe liver injury, and increased fibrin degradation product or D-dimer concentrations.¹⁵

Analysis of Effusion Fluid

The “classic” FIP effusion fluid is a high-protein (greater than 3.5 g/dL) exudate that contains a low number of nucleated cells (<5000 cells/ μ L), usually nondegenerate to mildly degenerate neutrophils and macrophages (Table 20-3). Erythrophagocytosis, leukophagia, and reactive mesothelial cells can be observed in the fluid from some cats. Grossly, the fluid has a yellow appearance and may contain fibrin clots. However, the total protein content and cell counts of abdominal and pleural effusions vary considerably, which complicates the diagnosis for some cats with effusive disease. Very rarely, chylous effusions occur.⁴⁸ An effusion albumin/globulin ratio below 0.4 is suggestive of FIP.⁴⁹

The *Rivalta test* is a simple test that can differentiate between transudates and exudates. In this test, a drop of 98% glacial acetic acid is mixed with 7 to 8 mL of distilled water in a transparent 10-mL tube. A drop of effusion is then added to the tube, and if it dissipates in the solution, the test is negative. If it retains its shape, stays attached to the surface, or moves slowly down in the solution, then the test is positive.²⁰ In a study of cats with effusion, 35% of which had FIP and a conclusive Rivalta test, the positive predictive value of this test for the diagnosis of FIP was 58% (58% chance that a cat that tests positive truly has FIP), and the negative predictive value was 93% (93% chance that a cat that tests negative does not have FIP).⁵⁰ In

TABLE 20-4

Composition of Cerebrospinal Fluid from 10 Cats with Necropsy-Confirmed Feline Infectious Peritonitis at the UC Davis VMTH

| Test | Range | Median | Reference Range | Number of Cats Tested |
|-----------------------|---------|--------|-----------------|-----------------------|
| Total protein (mg/dL) | 44-4079 | 639 | <25 | 4* |
| RBC (cells/ μ L) | 3-850 | 340 | 0 | 9 |
| TNC (cells/ μ L) | 26-2637 | 303 | 0-2 | 10 |
| Neutrophils (%) | 4-90 | 73 | | 10 |
| Lymphocytes (%) | 5-89 | 19 | | 10 |
| Monocytes (%) | 0-20 | 7 | | 10 |

TNC, total neutrophil count.

*Insufficient quantity available from some cats for determination of protein concentration.

younger cats, the positive predictive value of the test is higher, because diseases such as lymphoma and bacterial peritonitis are less common. Positive test results indicate only the presence of an exudate, so cytologic examination of the fluid must still be performed.

Cerebrospinal Fluid Analysis

The cerebrospinal fluid (CSF) of cats with neurologic FIP often has increased protein content (30 to more than 1000 mg/dL, reference range less than 25 mg/dL) and increased total nucleated cell count (20 to 10,000 cells/ μ L), usually consisting of a mixed but predominantly neutrophilic cellular pleocytosis (Table 20-4). In some cats, protein content and leukocyte counts are normal.^{51,52}

Diagnostic Imaging

Plain Radiography

Plain thoracic radiography may reveal pleural effusion, enlargement of the cardiac silhouette in cats with pericardial effusion, and pulmonary nodular or peribronchial infiltrates in cats with pyogranulomatous pneumonia (Figure 20-7). Abdominal radiographs may show loss of peritoneal or retroperitoneal detail due to peritoneal effusion, hepatomegaly, splenomegaly, renomegaly, or mass lesions associated with the gastrointestinal tract or abdominal lymph nodes.

Sonographic Findings

Abdominal ultrasound findings in FIP include the presence of anechoic or mildly echogenic peritoneal fluid; hyperechogenicity and “clumping” of the mesentery; enlarged and hypoechoic abdominal lymph nodes (Figure 20-8, A); enlargement and diffuse or focal hypoechoic of the liver and spleen;⁵³ renal asymmetry with increased cortical echogenicity, hypoechoic nodules, subcapsular fluid accumulation, or loss of corticomedullary distinction (see Figure 20-8, B); and/or thickening of all intestinal wall layers or intestinal mass lesions. Pleural effusion or comet-tail artifacts (due to pulmonary infiltrates) may be seen through the diaphragm.

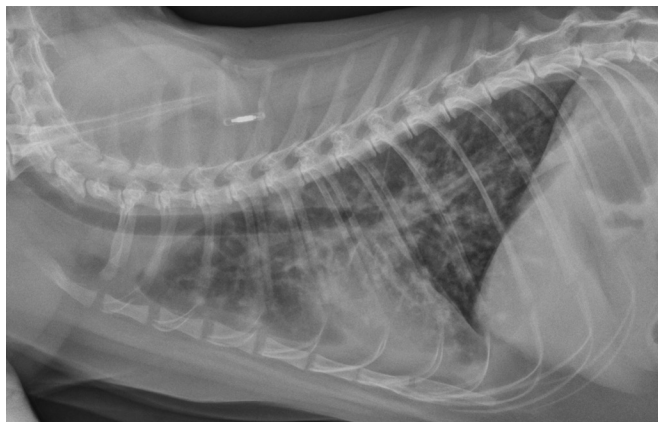

FIGURE 20-7 Lateral thoracic radiograph from a 9-month-old male neutered domestic shorthair cat with FIP and pyogranulomatous pneumonia. There is a severe, diffuse, patchy alveolar and nodular interstitial pattern with thickening of the bronchial walls and mild pleural effusion.

Magnetic Resonance Imaging of the Central Nervous System

Findings on MRI that suggest FIP consist of ventricular dilatation and variable contrast enhancement of the periventricular regions, choroid, and meninges. In some cats, MRI findings are unremarkable.

Microbiologic Tests

Serologic Diagnosis

Detection of antibodies to FCoV can be performed using immunofluorescent antibody testing, ELISA, or virus neutralization.⁵⁴ The methods used, as well as the titers themselves, vary considerably between laboratories. For example, some laboratories use related coronaviruses as a source of antigen for the test, rather than FCoV.¹⁵ Use of a reliable laboratory that reports quantitative titers (to the endpoint dilution, as well as down to 1:100) is critical. Even when performed correctly, a positive FCoV antibody titer is not diagnostic for FIP, because cats that have been exposed to avirulent FCoV strains or even other related coronaviruses are also seropositive. Therefore, serology is a “coronavirus antibody test” and not an “FIP test.” It has been suggested that more cats have been killed as a result of misinterpretation of FCoV antibody tests than by the disease itself.²⁰ Certainly a diagnosis of FIP should *never* be made based on the presence of nonspecific clinical or laboratory abnormalities such as fever or leukocytosis and a positive coronavirus antibody test. Occasionally (up to 10% of the time), cats with advanced disease are seronegative, because of failure of antibody production with severe immunosuppression, or the complexing of antibody by the large quantities of virus present. In one study, titers of 1:1600 or higher were highly suggestive (94% chance) of FIP in the presence of compatible clinical signs.⁴⁴ In addition, strong positive titers (e.g., $\geq 1:6400$) in cats with consistent signs and laboratory abnormalities support a diagnosis of FIP if a cat resides in a household that contains only one or two cats, because cats often become seronegative within a few months once they are removed from households that contain large numbers of cats.

Other body fluids can also be analyzed for antibodies to FCoV. In one study, positive antibody titers in effusion had a positive predictive value of 90% and a negative predictive value of 79%, but the magnitude of the titer did not correlate with the diagnosis of FIP.⁴⁴ The presence of anti-FCoV

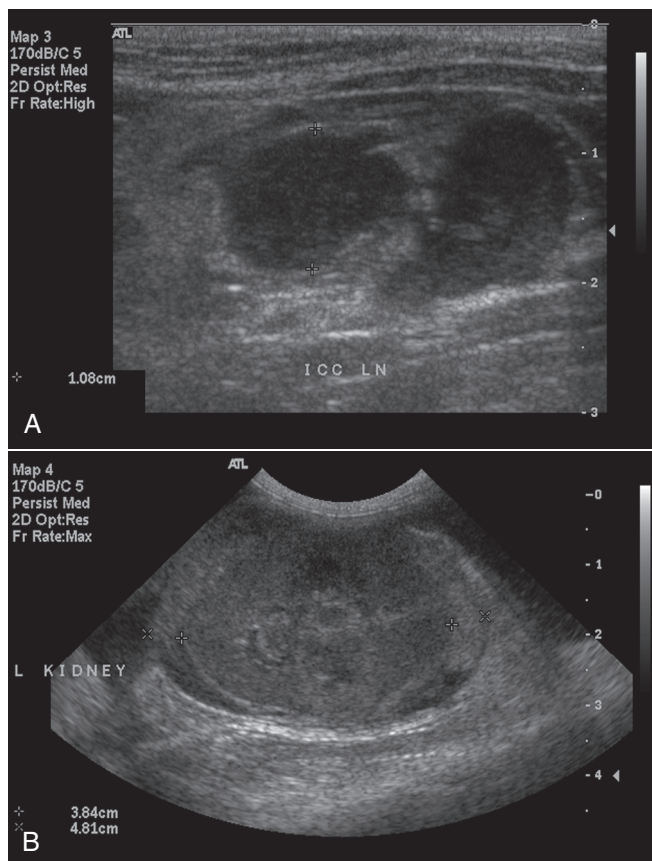


FIGURE 20-8 **A**, Abdominal ultrasound image from a 9-month-old male neutered domestic shorthair cat with FIP and ileoceocolic lymphadenopathy. The lymph nodes are enlarged and hypoechoic. **B**, Abdominal ultrasound image from a 1-year-old male intact Scottish fold with FIP. There is renal irregularity and subcapsular fluid, as well as moderate peritoneal effusion.

antibody in the CSF correlated well with a diagnosis of FIP in one study,⁵² but not in another study.⁵¹ In addition, the presence of sufficient quantities of CSF for serology are frequently not available.

Molecular Diagnosis Using the Polymerase Chain Reaction

Real-time reverse transcriptase–PCR (RT-PCR) assays have been developed for detection of FCoV, but these do not differentiate between virulent and avirulent strains. In addition, avirulent strains can be found in the blood and tissues of cats that do not have FIP,^{21,22} so the finding of virus in locations other than the gastrointestinal tract is not helpful for diagnosis. False-negative test results can occur when there are low quantities of virus present or if degradation of RNA occurs during specimen transport. Some RT-PCR assays do not detect all strains of FCoV. Positive RT-PCR results in blood or effusion fluid from cats with other clinical abnormalities that suggest FIP do indicate the presence of a coronavirus and, in that respect, may help to support the diagnosis made, provided the limitations of the test are recognized.

Immunostaining of FCoV Antigen

FCoV antigen can be detected in macrophages with immunocytochemistry or immunohistochemistry (Figure 20-9). Either fluorescent antibody or immunoperoxidase methods

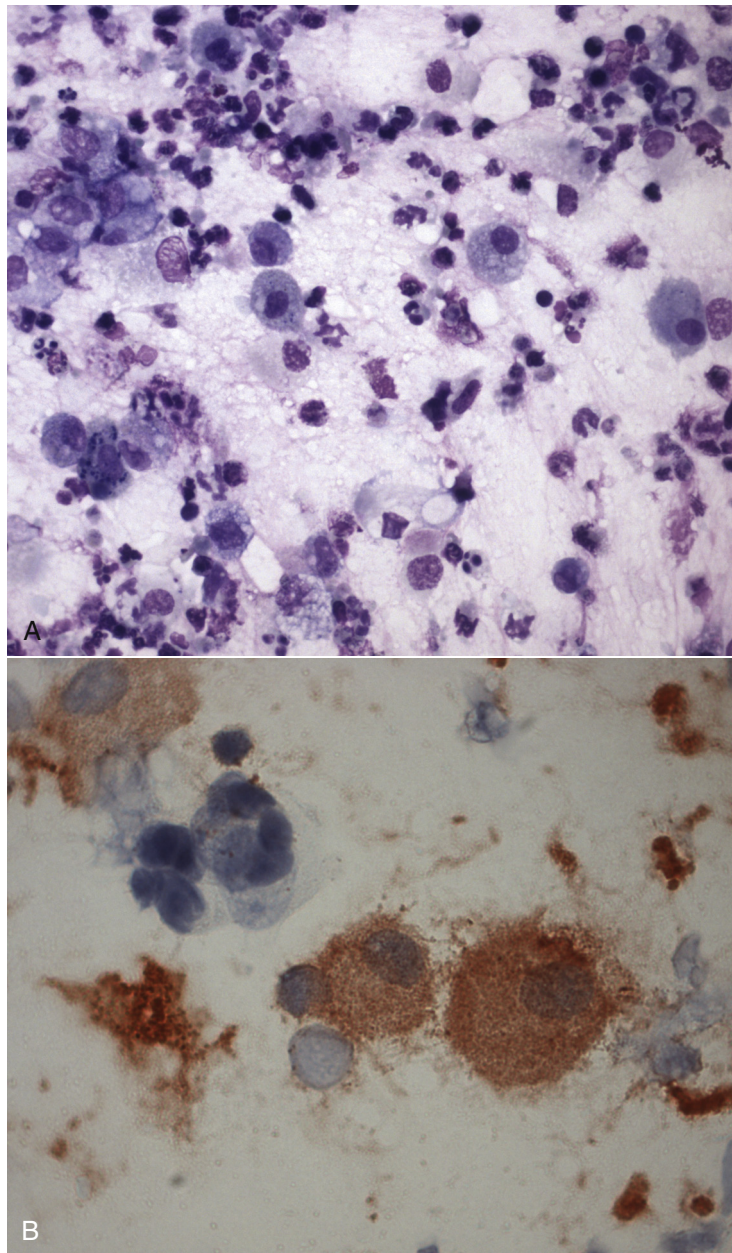


FIGURE 20-9 **A**, Cytospin preparation of a tracheobronchial lavage from the cat in Figure 20-7. The specimen was highly cellular (4400 cells/ μ L) and the cells consisted of 42% degenerate and nondegenerate neutrophils, 5% lymphocytes, and 53% macrophages. **B**, Immunocytochemistry stain on the same specimen for coronavirus antigen showing positive staining in association with macrophages.

may be used (Table 20-5). When antigen tests are positive, provided the test is performed and interpreted properly (with use of positive and negative control slides), studies suggest that only cats with FIP have positive test results.^{44,55} False-negative results occur when there are insufficient numbers of infected cells, when low quantities of virus are present, or when antigen is unavailable for detection because of complexing by antibody.

Pathologic Findings

Gross Pathologic Findings

At necropsy, gross findings in cats with FIP include variable quantities of pleural, pericardial, and peritoneal effusion (Figure 20-10, A). Fibrin adhesions may be present and the mesentery

may be clumped. Abdominal organs may be enlarged or irregular. Granulomas appear as variably sized multifocal white, cream, tan, or yellow nodular lesions on serosal surfaces and within the parenchyma of organs such as the lungs, spleen, kidneys, pancreas, and liver (see Figure 20-10, B). Lesions have also been described within the nasal cavity and sinuses. Pyogranulomas may be visible grossly as miliary lesions, or they may be several centimeters in diameter. Thoracic and/or abdominal lymphadenomegaly is a common finding. Diffuse or focal thickening of the intestinal wall or intestinal mass lesions may be present. Examination of the brain can reveal fibrinous exudate in association with the meninges, with or without ventricular dilation and hydrocephalus (see Figure 20-4). Thymic involution may also be present.

TABLE 20-5

Assays Available for Diagnosis of Feline Infectious Peritonitis

| Assay | Specimen Type | Target | Performance |
|---|---|--|---|
| Fluorescent or immunoperoxidase antibody staining | Wash or effusion specimens, tissue aspirates, tissues obtained at biopsy or necropsy | FCoV | Gold standard for diagnosis. False negatives can occur in specimens that contain low numbers of macrophages or virus particles, or when virus is complexed by antibody. Immunofluorescence is more sensitive than immunoperoxidase methods. Non-specific staining may be interpreted as positive results by untrained personnel. |
| Serology | Blood, CSF, aqueous humor, effusion fluid | FCoV antibody | Positive antibody titers reflect only antibodies to a coronavirus and are not specific for a diagnosis of FIP. Most cats in multicat households test positive. Negative titers can occur in cats with advanced FIP. High titers in cats that do not reside in multicat households and that have signs suggestive of FIP may support the diagnosis. Interlaboratory variation in methodology and titer reporting occurs. |
| RT-PCR | Blood, wash or effusion specimens, tissue aspirates, tissues obtained at biopsy or necropsy | FCoV RNA | Does not differentiate between virulent and avirulent FCoV strains, and avirulent strains may be found in tissues and blood. Sensitivity and specificity can vary depending on assay design. False negative results occur when virus levels are low, when variant virus strains are present, or as a result of degradation of viral nucleic acid during specimen transport. |
| Histopathology | Usually necropsy specimens, but also biopsies | Inflammatory lesions induced by FCoV (pyogranulomatous vasculitis) | Biopsy is often not feasible antemortem as a result of critical illness and coagulopathies. |

FCoV, feline coronavirus; FIP, feline infectious peritonitis; RT-PCR, reverse transcriptase–polymerase chain reaction.

Histopathologic Findings

The characteristic histopathologic findings of FIP are systemic perivascular, multifocal to coalescing pyogranulomatous or granulomatous inflammatory lesions (Figure 20-11). Lesions predominantly contain macrophages and neutrophils, with lesser numbers of lymphocytes and plasma cells, although occasionally the histiocytic or the lymphoplasmacytic component of the inflammatory response is more florid. Necrosis may be present within the lesions. Lesions in the central nervous system consist of pyogranulomatous meningoencephalomyelitis and choroiditis. Other findings that may be identified include lymphoid depletion, which results from apoptosis, and membranous glomerulonephritis.

Treatment and Prognosis

Currently, no cure for FIP exists; it is a progressive, invariably fatal disease. The goal of treatment is to prolong life span and improve quality of life through reduction of inflammation and supportive care. The most effective treatment known is prednisolone, administration of which results in temporary remissions in some cats (Table 20-6). Other immunosuppressive drugs, such as chlorambucil and cyclophosphamide, have been used in addition to prednisolone, but whether these drugs improve outcome is unknown, and they have the potential to be toxic. A variety of immunomodulators and antiviral drugs have been tried, such as ribavirin and oral and parenteral human

recombinant IFN- α , but none have convincingly shown benefit in vivo. Prolonged remissions were reported in several cats treated with a combination of glucocorticoids and feline IFN- ω ,⁵⁶ but a randomized, placebo-controlled clinical trial reported no effect of feline IFN- ω .⁵⁷ Other drugs used to treat cats with FIP include the immunomodulatory drugs pentoxifylline and Polyprenyl Immunostimulant (see Chapter 7)⁵⁸; ozagrel hydrochloride, a thromboxane synthetase inhibitor⁵⁹; and the antiviral drug nelfinavir.^{14,60} Controlled clinical trials are required to assess the efficacy and safety of these treatments. Because FIP is an immune-mediated disease, nonspecific immune stimulation has the potential to cause harm. The use of small interfering RNA molecules, which bind viral RNA and prevent viral replication, has recently shown promising results in vitro.⁶¹ Cyclosporin inhibits FIPV replication in vitro;⁶² studies are required to determine if cyclosporin treatment benefits infected cats or whether harm results from immunosuppression.

Supportive treatments that may be required include subcutaneous fluid therapy and nutritional support. Inappetent cats can benefit from enteral nutrition through a feeding tube. The use of broad-spectrum antimicrobial drugs to treat cats with FIP is controversial; it may only promote opportunistic infections with resistant bacteria.

The prognosis for cats with FIP is generally grave. Almost all cats with effusion at the time of diagnosis die within weeks. Very rarely, more prolonged survival times (1 to 2 years) have been documented after glucocorticoid treatment (see Case Example).

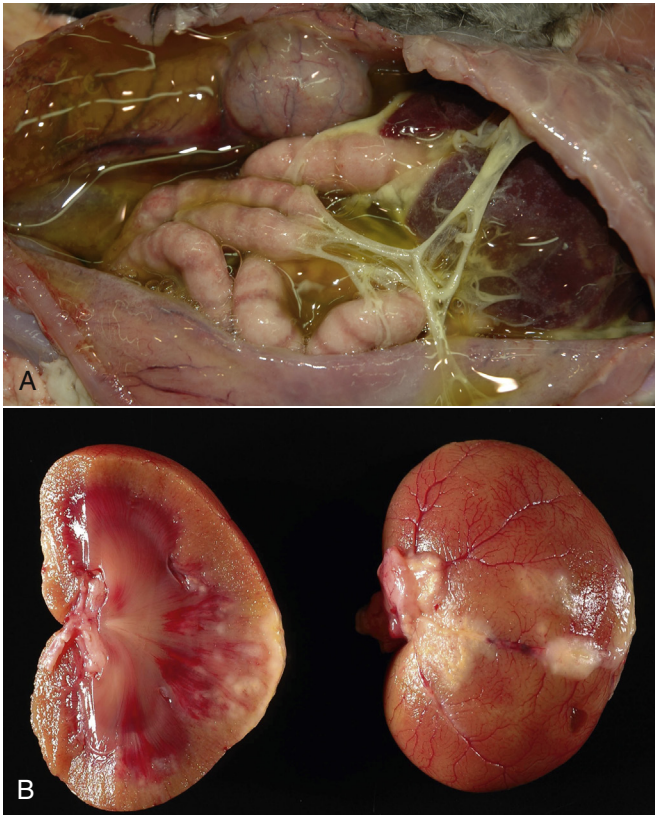

FIGURE 20-10 **A**, Gross necropsy findings in a 10-month-old male intact domestic shorthair cat with effusive FIP. Approximately 1.2 liters of yellow fluid was present in the abdomen, and there are abundant fibrin strands adherent to the visceral and parietal peritoneal surfaces. **B**, Kidneys of the cat in Figure 20-8. Multiple, pale tan firm nodules expand the renal cortices and protrude from the cortical surfaces. (Courtesy of the University of California, Davis Veterinary Anatomic Pathology service, D. Gasper and M. Jones.)

The median survival time in one study of 37 cats was 9 days (range, 3 to 200 days).⁵⁷ In another it was 21 days (range, 1 to 99 days) for 30 cats with effusive disease, 38 days (range, 1 to 171 days) for 12 cats with noneffusive disease, and 111 days (range, 7 to 477 days) for 9 cats with mixed effusive and noneffusive disease.¹⁴ Hyperbilirubinemia, the presence of effusion, and lymphopenia are negative prognostic factors²⁰; in one study, the hematocrit, lymphocyte count, and serum albumin, potassium, sodium, and globulin concentrations decreased as disease progressed, and total bilirubin concentration and serum liver enzyme activities increased.¹⁴ Euthanasia should be considered for cats with severe illness that fail to respond to treatment within a 3-day period.²⁰

Immunity and Vaccination

Although antibodies to the spike protein can neutralize virus, antibodies are required for FIP to occur, because FIP is an immune complex disease. Cell-mediated immunity is important for protection,⁶ but if immunity is incomplete, granulomatous or pyogranulomatous disease results.

The development of vaccines for FIP has been complicated by the fact that stimulation of antibody production against FCoV can accelerate the disease, should FIP develop after vaccination has been performed. Antibodies may bind to Fc receptors on macrophages and accelerate virus uptake in a phenomenon

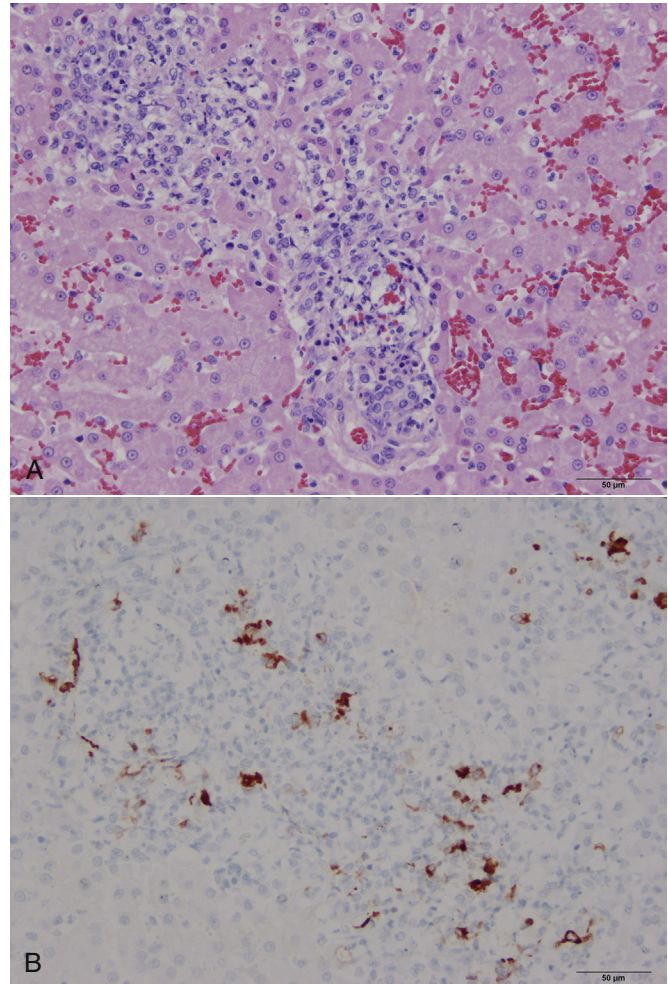


FIGURE 20-11 **A**, Histopathology of the liver of a cat with FIP. There is pyogranulomatous hepatitis. Hematoxylin and eosin stain. **B**, Macrophages stain strongly positive for feline coronavirus antigen with immunohistochemistry. (Courtesy Dr. Patricia Pesavento, University of California, Davis Veterinary Anatomic Pathology service.)

TABLE 20-6

Suggested Drug Dosages for Treatment of Feline Infectious Peritonitis

| Drug | Dose (mg/kg) | Route | Interval (hours) |
|---------------|--------------|-------|------------------|
| Prednisolone | 1-2 | PO | 12-24 |
| Chlorambucil* | 2 mg/cat | PO | 48-72 |

*Monitor the CBC during treatment.

known as *antibody-dependent disease enhancement* (ADDE). Currently, an intranasal, temperature-sensitive mutant serotype II FIP virus vaccine is available on the market, but its use has been controversial. The vaccine virus replicates in the lower temperatures found in the respiratory tract. It is licensed for administration from 16 weeks of age, by which time most kittens have already been exposed to FCoV. The vaccine does not appear to cause ADDE,⁶³⁻⁶⁵ but its efficacy and ability to induce

immunity against heterologous strains is controversial. In a study of 138 cats that belonged to 15 different cat breeders, virtually all of which were seropositive, there was no difference in prevalence of FIP in vaccinated versus placebo-treated cats.⁶³ A slight reduction in the prevalence of FIP occurred when the vaccine was used in cats that had not been exposed to FCoV before vaccination, but protection was not convincing based on the small numbers of cats that developed the disease in each group.^{6,65}

Prevention

In households that contain only one or a few cats, young cats that develop FIP likely become infected with FCoV before they are acquired. They may or may not have FIP at the time of acquisition. When a cat from a single-cat household dies with FIP, it is suggested that the owner wait at least 2 months before a new cat is obtained, so that any virus in the environment becomes inactivated.²⁰ Selection of a new cat from a different genetic background than the previous cat should be considered, and if possible, the breeder should be informed if a purebred cat develops FIP. If a low number of other cats remain in the household, they may or may not continue to shed virus. These cats often have a positive antibody titer, but this in no way predicts that they will develop FIP. Before a new cat is introduced to a household that has a history of FIP, factors that could reduce stress and overcrowding should be identified and addressed.

The risk of transmission and disease can be reduced through attention to hygiene, prevention of overcrowding, maintenance of a larger ratio of adult to juvenile cats, and ensuring that cats are in stable groups of three or fewer per room. Cats should have sufficient numbers of regularly cleaned litter trays located in a different area from where they are fed. Methods to control FIP in cattery situations, such as identification and removal of

chronic shedders with serial fecal RT-PCR assays and removal of kittens from the queen followed by isolation at 5 to 6 weeks of age (before maternal antibody has declined), have limitations and are difficult to achieve properly in large catteries.²⁰ For example, cats that do not shed FCoV may still be infected with avirulent FCoV strains, and shedding may recommence at a later date.²² Isolation of kittens may be useful if reexposure is prevented until after they are 16 weeks of age, when their immune system is more mature.⁶ In shelter situations, FIP may be reduced when overcrowding and prolonged stays are minimized, especially during kitten season.⁶ If possible, owners that adopt cats from shelter environments should be provided with a handout that provides basic information on the disease (and other major infectious diseases of shelter cats such as retrovirus infections, bartonellosis, and feline upper respiratory tract disease) and the ubiquitous nature of infection.

Further understanding of genetic factors that contribute to FIP is required, because selective breeding may reduce the risk of the disease. In the meantime, the breeding of cats that produce litters that succumb to FIP should be avoided. This is especially true for male cats, because a single male cat can have an effect on far more kittens and litters than a single queen. It is recommended that no more than six breeding animals be maintained if possible.⁶

Public Health Aspects

There is no evidence that humans can become infected with FCoV. The closest human coronavirus relative is the severe acute respiratory syndrome (SARS) coronavirus. Other coronaviruses cause FIP-like disease in nonfelids such as ferrets and mice. If a coronavirus emerged that could cause similar clinical manifestations and outcomes in humans as FIPV can in cats, it would represent a major threat to humans and would be the subject of intense research.

CASE EXAMPLE

Signalment: “Ricky”, a 9-month-old male castrated domestic shorthair from Sacramento, CA

History: Ricky was brought to a local veterinary clinic because of increased thirst and urination. A serum chemistry panel showed hyperglobulinemia (7.7 mg/dL), and urinalysis showed a specific gravity (SGr) of 1.025 with an inactive sediment; aerobic bacterial urine culture was negative. Three days later, Ricky became inappetent and was returned to the local veterinary clinic. Laboratory abnormalities included mature neutrophilia (11,904 cells/ μ L), lymphocytosis (5104 cells/ μ L), eosinophilia (1536 cells/ μ L), hyperglobulinemia (6.9 mg/dL), and hypoalbuminemia (2.4 mg/dL). A feline coronavirus antibody titer was 1:400. Serology for *Toxoplasma gondii* was negative. Plain thoracic radiographs showed a mild interstitial pattern. Abdominal ultrasound showed mesenteric lymphadenomegaly, and an aspirate of the lymph nodes showed lymphoid reactivity. Treatment with cyproheptadine was initiated, and Ricky’s appetite recovered,

after which treatment was discontinued. For the 3 weeks that followed, the cat had been appetent and energetic, but occasional soft feces had been noticed in the litter box. The owners were concerned about the possibility of FIP.

Ricky was obtained at 3 months of age from a rescue group, who rescued him as an 8-week-old stray kitten. As a kitten he had multiple upper respiratory tract infections, but since adoption he had been healthy and shared a household with one other cat. He was an indoor cat that was sometimes walked briefly outdoors. He was fed commercial dry and wet cat food.

Physical Examination:

Body Weight: 4.2 kg

General: Bright, alert and responsive, hydrated. T = 103°F (39.4°C), HR = 200 beats/min, eupneic.

All Systems: No clinically significant abnormalities of any body system were detected. Body condition score was 5/9.

Laboratory Findings:

CBC:

HCT 27.3% (30%-50%)

MCV 42.1 fL (42-53 fL)

MCHC 34.1 g/dL (30-33.5 g/dL)
 WBC 24,950 cells/ μ L (4500-14,000 cells/ μ L)
 Neutrophils 17,141 cells/ μ L (2000-9000 cells/ μ L)
 Lymphocytes 6886 cells/ μ L (1000-7000 cells/ μ L)
 Monocytes 724 cells/ μ L (50-600 cells/ μ L)
 Eosinophils 200 cells/ μ L (150-1100 cells/ μ L)
 Basophils 25 cells/ μ L (0-50 cells/ μ L)
 Platelets 518,000/ μ L (180,000-500,000 platelets/ μ L).

Serum Chemistry Profile:

Sodium 147 mmol/L (151-158 mmol/L)
 Potassium 4.5 mmol/L (3.6-4.9 mmol/L)
 Chloride 116 mmol/L (117-126 mmol/L)
 Bicarbonate 18 mmol/L (15-21 mmol/L)
 Phosphorus 6.4 mg/dL (3.2-6.3 mg/dL)
 Calcium 9.5 mg/dL (9.0-10.9 mg/dL)
 BUN 22 mg/dL (18-33 mg/dL)
 Creatinine 1.1 mg/dL (1.1-2.2 mg/dL)
 Glucose 83 mg/dL (63-118 mg/dL)
 Total protein 10.7 g/dL (6.6-8.4 g/dL)
 Albumin 2.6 g/dL (2.2-4.6 g/dL)
 Globulin 8.1 g/dL (2.8-5.4 g/dL)
 ALT 31 U/L (27-101 U/L)
 AST 17 U/L (17-58 U/L)
 ALP 35 U/L (14-71 U/L)
 Gamma GT <3 U/L (0-4 U/L)
 Cholesterol 143 mg/dL (89-258 mg/dL)
 Total bilirubin <0.1 mg/dL (0-0.2 mg/dL).

Serum Protein Electrophoresis: A polyclonal gammopathy with a mild decrease in albumin concentration and mild increases in the α_2 and β_1 fractions was present (see Figure 20-4). These changes were consistent with the acute-phase inflammatory response.

Imaging Findings: Abdominal ultrasound: The spleen was moderately enlarged. There was diffuse mesenteric lymphadenopathy (see Figure 20-8, B).

Mesenteric Lymph Node Aspirate Cytology: Intact nucleated cells were composed of a heterogeneous population of lymphocytes, predominated by small, mature lymphocytes. Lower numbers of intermediate and large reactive lymphocytes, moderate numbers of mildly degenerate neutrophils, and scattered plasma cells and histiocytes were noted. Immunocytochemistry using two different monoclonal antibodies against FCoV was negative, but macrophages were low in number.

Microbiologic Testing: FeLV antigen and FIV antibody serology: negative

Serology (IFA) and blood culture for *Bartonella clarridgeiae* and *Bartonella henselae*: negative

Serology (IFA) for vector-borne diseases: negative for antibodies to *Ehrlichia canis*, *Neorickettsia risticii*, *Anaplasma* spp., and *Rickettsia* spp.

PCR for FCoV (whole blood): negative

PCR panel for other bloodborne pathogens (*Anaplasma phagocytophilum*, *Anaplasma platys*, *Bartonella* spp., *E. canis*, *N. risticii*, *Mycoplasma haemofelis*): negative

Aerobic and anaerobic bacterial culture of mesenteric lymph node aspirate: negative

Serology for FCoV: positive at 1:102,400

Diagnosis: A tentative diagnosis of FIP was made on the basis of Ricky's background, the marked polyclonal gammopathy, and the strongly positive coronavirus titer.

Treatment and Outcome: Biopsy of the enlarged mesenteric node was offered, but the owners declined. Ricky was treated with prednisolone (5 mg PO q12h for 7 days, followed by 5 mg PO q24h thereafter), chlorambucil (2 mg PO every 3 days), and pentoxifylline (50 mg PO q8h). Six weeks later, the cat was well and CBC variables within reference ranges. Serum total protein concentration was 8.5 g/dL, with a globulin concentration of 4.5 g/dL. Abdominal ultrasound examination showed persistent but mild mesenteric lymphadenomegaly (0.5 to 0.75 cm in diameter). A feline coronavirus titer was 1:25,600. Treatment with feline interferon- ω was commenced (4.5 million units SC once weekly). Ricky was seen again 3 months later, at which time he continued to be playful and appetent, with a stable body weight of 4.5 kg. A CBC showed mild anemia (HCT 29%), a neutrophil count of 4439 cells/ μ L, and lymphopenia (468 cells/ μ L). A chemistry panel and abdominal ultrasound showed no abnormalities. Chlorambucil and interferon- ω were discontinued. The next time the cat was reexamined was 12 months after the onset of illness, at which time he continued to be apparently healthy. CBC findings were unchanged, and the serum globulin concentration was 4.7 g/dL. The prednisolone dose was decreased to 5 mg q48h and pentoxifylline treatment was discontinued. One month later, albumin and globulin concentrations were 3.3 and 5.1 g/dL, respectively, and the prednisolone dose was reduced to 2.5 mg q48h. At the next 1-month recheck, a CBC was unremarkable but globulin was 5.7 g/dL. Abdominal ultrasound showed mildly enlarged mesenteric lymph nodes, and the serum coronavirus antibody titer was 1:409,600. The prednisolone dose was increased to 5 mg PO q24h; 1 month later, the serum globulin concentration was 4.9 g/dL. One and a half years after the onset of illness, Ricky was still apparently healthy according to the owner, but a midabdominal mass was palpated on physical examination, and the serum globulin concentration had increased again (5.6 g/dL). Abdominal ultrasound showed several moderately enlarged and hypoechoic lymph nodes in the ileocolic region, the largest of which was 0.9 cm in diameter. The surrounding mesentery was focally hyperechoic. There was also focal hyperechoic retroperitoneal tissue surrounding the right kidney with scant retroperitoneal fluid. Attempts to obtain aspirates from the lymph nodes were unsuccessful. The prednisolone dose was increased to 5mg PO q12h, and treatment with chlorambucil and pentoxifylline was reinstated.

One week later, Ricky developed lethargy and inappetence. A CBC showed macrocytic anemia (HCT 24.3%, MCV 57.2 fL) and lymphopenia (782 cells/ μ L). A serum chemistry panel showed only hyperglobulinemia (5.8 g/dL). FeLV and FIV serology was repeated and was again negative, and the coronavirus antibody titer was 1:25,600. Treatment with cyproheptadine was initiated and the chlorambucil and pentoxifylline discontinued. However, inappetence continued, and persistent pyrexia (103.4° to 104°F), hematochezia, and tachypnea developed over the next few days. The hematocrit dropped to 16.5%, and hypokalemia, hyponatremia, and hypochloremia were identified. Ricky was hospitalized and treated with 1 unit of packed RBC, IV crystalloids, and parenteral antimicrobial drugs. Thoracic radiographs showed a severe, diffuse, patchy alveolar and nodular interstitial pattern with thickening of the bronchial walls and mild pleural effusion (see Figure 20-7). A tracheobronchial

lavage showed marked mixed, predominantly pyogranulomatous inflammation with moderate epithelial hyperplasia and some degenerate neutrophils (see Figure 20-9). Immunocytochemistry with an anti-FCoV antibody was strongly positive in macrophages. Aerobic and anaerobic bacterial cultures of the wash specimen were negative. The cat subsequently seized and was euthanized.

Necropsy Findings: Necropsy showed moderate to severe, multifocal to coalescing pyogranulomatous capsulitis and serositis that involved the spleen, liver, kidney, intestines, diaphragm, thoracic and abdominal walls, and pericardium. There was also multifocal pyogranulomatous splenitis, hepatitis, nephritis, meningoencephalitis, and pneumonia with necrosis. Straw-colored effusion was present in the abdominal cavity, thoracic cavity, and pleural space. Immunohistochemistry was strongly positive for FCoV antigen (see Figure 20-11).

Comments: The course of disease and survival time (587 days) in this cat was unusually prolonged for FIP, and on many occasions the diagnosis was questioned. However, the persistently increased FCoV antibody titer in a cat that lived with only one other cat raised suspicion for the disease. Chronic, smoldering FIP may be more common than recognized.⁶ The initial clinical signs in this cat were mild and may have been overlooked by some owners. Although the cat appeared to respond to prednisolone treatment, it was not known whether the other medications used had any effect. Ultimately, disease progressed, and a diagnosis of FIP was confirmed with immunocytochemistry on the tracheobronchial lavage specimen. Although effusion developed, the amount was too low to permit collection of the fluid for analysis. The initial negative PCR and immunocytochemistry results may have reflected the presence of low quantities of virus.

SUGGESTED READINGS

- Addie D, Belak S, Boucraut-Baralon C, et al. Feline infectious peritonitis. ABCD guidelines on prevention and management. *J Feline Med Surg.* 2009;11:594-604.
- Brown MA. Genetic determinants of pathogenesis by feline infectious peritonitis virus. *Vet Immunol Immunopathol.* 2011;143:265-268.
- Pedersen NC. A review of feline infectious peritonitis virus infection: 1963-2008. *J Feline Med Surg.* 2009;11:225-258.

REFERENCES

- Holzworth J. Some important disorders of cats. *Cornell Vet.* 1963;53:157-160.
- McArdle F, Bennett M, Gaskell RM, et al. Induction and enhancement of feline infectious peritonitis by canine coronavirus. *Am J Vet Res.* 1992;53:1500-1506.
- Van Hamme E, Desmarests L, Dewerchin HL, et al. Intriguing interplay between feline infectious peritonitis virus and its receptors during entry in primary feline monocytes. *Virus Res.* 2011;160:32-39.
- Tekes G, Hofmann-Lehmann R, Stallkamp I, et al. Genome organization and reverse genetic analysis of a type I feline coronavirus. *J Virol.* 2008;82:1851-1859.
- Pedersen NC, Black JW, Boyle JF, et al. Pathogenic differences between various feline coronavirus isolates. *Adv Exp Med Biol.* 1984;173:365-380.
- Pedersen NC. A review of feline infectious peritonitis virus infection: 1963-2008. *J Feline Med Surg.* 2009;11:225-258.
- Hohdatsu T, Okada S, Ishizuka Y, et al. The prevalence of types I and II feline coronavirus infections in cats. *J Vet Med Sci.* 1992;54:557-562.
- Heeney JL, Evermann JF, McKeirman AJ, et al. Prevalence and implications of feline coronavirus infections of captive and free-ranging cheetahs (*Acinonyx jubatus*). *J Virol.* 1990;64:1964-1972.
- Rohrbach BW, Legendre AM, Baldwin CA, et al. Epidemiology of feline infectious peritonitis among cats examined at veterinary medical teaching hospitals. *J Am Vet Med Assoc.* 2001;218:1111-1115.
- Pesteanu-Somogyi LD, Radzai C, Pressler BM. Prevalence of feline infectious peritonitis in specific cat breeds. *J Feline Med Surg.* 2006;8:1-5.
- Worthing KL, Wigney DI, Dhand NK, et al. Risk factors for feline infectious peritonitis in Australia. *J Fel Med Surg.* 2012;14:405-412.
- Foley JE, Poland A, Carlson J, et al. Risk factors for feline infectious peritonitis among cats in multiple-cat environments with endemic feline enteric coronavirus. *J Am Vet Med Assoc.* 1997;210:1313-1318.
- Norris JM, Bosward KL, White JD, et al. Clinicopathological findings associated with feline infectious peritonitis in Sydney, Australia: 42 cases (1990-2002). *Aust Vet J.* 2005;83:666-673.
- Tsai HY, Chueh LL, Lin CN, et al. Clinicopathological findings and disease staging of feline infectious peritonitis: 51 cases from 2003 to 2009 in Taiwan. *J Feline Med Surg.* 2011;13:74-80.
- Hartmann K. Feline infectious peritonitis. *Vet Clin North Am Small Anim Pract.* 2005;35:39-79, vi.
- Bell ET, Toribio JA, White JD, et al. Seroprevalence study of feline coronavirus in owned and feral cats in Sydney, Australia. *Aust Vet J.* 2006;84:74-81.
- Pedersen NC. Serologic studies of naturally occurring feline infectious peritonitis. *Am J Vet Res.* 1976;37:1449-1453.
- Addie DD, Jarrett O. A study of naturally occurring feline coronavirus infections in kittens. *Vet Rec.* 1992;130:133-137.
- Addie DD, Toth S, Murray GD, et al. Risk of feline infectious peritonitis in cats naturally infected with feline coronavirus. *Am J Vet Res.* 1995;56:429-434.
- Addie D, Belak S, Boucraut-Baralon C, et al. Feline infectious peritonitis. ABCD guidelines on prevention and management. *J Feline Med Surg.* 2009;11:594-604.
- Gunn-Moore DA, Gruffydd-Jones TJ, Harbour DA. Detection of feline coronaviruses by culture and reverse transcriptase-polymerase chain reaction of blood samples from healthy cats and cats with clinical feline infectious peritonitis. *Vet Microbiol.* 1998;62:193-205.
- Kipar A, Meli ML, Baptiste KE, et al. Sites of feline coronavirus persistence in healthy cats. *J Gen Virol.* 2010;91:1698-1707.
- Chang HW, de Groot RJ, Egberink HF, et al. Feline infectious peritonitis: insights into feline coronavirus pathobiogenesis and epidemiology based on genetic analysis of the viral 3c gene. *J Gen Virol.* 2010;91:415-420.
- Rottier PJ, Nakamura K, Schellen P, et al. Acquisition of macrophage tropism during the pathogenesis of feline infectious peritonitis is determined by mutations in the feline coronavirus spike protein. *J Virol.* 2005;79:14122-14130.
- Chang HW, Egberink HF, Halpin R, et al. Spike protein fusion peptide and feline coronavirus virulence. *Emerg Infect Dis.* 2012;18(7):1089-1095.
- Brown MA, Troyer JL, Pecon-Slattey J, et al. Genetics and pathogenesis of feline infectious peritonitis virus. *Emerg Infect Dis.* 2009;15:1445-1452.
- Vennema H, Poland A, Foley J, et al. Feline infectious peritonitis viruses arise by mutation from endemic feline enteric coronaviruses. *Virology.* 1998;243:150-157.

28. Pedersen NC, Liu H, Dodd KA, et al. Significance of coronavirus mutants in feces and diseased tissues of cats suffering from feline infectious peritonitis. *Viruses*. 2009;1:166-184.
29. Takano T, Tomiyama Y, Katoh Y, et al. Mutation of neutralizing/antibody-dependent enhancing epitope on spike protein and 7b gene of feline infectious peritonitis virus: influences of viral replication in monocytes/macrophages and virulence in cats. *Virus Res*. 2011;156:72-80.
30. Brown MA. Genetic determinants of pathogenesis by feline infectious peritonitis virus. *Vet Immunol Immunopathol*. 2011;143:265-268.
31. Addie DD, Schaap IA, Nicolson L, et al. Persistence and transmission of natural type I feline coronavirus infection. *J Gen Virol*. 2003;84:2735-2744.
32. Addie DD, Jarrett O. Use of a reverse-transcriptase polymerase chain reaction for monitoring the shedding of feline coronavirus by healthy cats. *Vet Rec*. 2001;148:649-653.
33. Pedersen NC, Allen CE, Lyons LA. Pathogenesis of feline enteric coronavirus infection. *J Feline Med Surg*. 2008;10:529-541.
34. Regan AD, Ousterout DG, Whittaker GR. Feline lectin activity is critical for the cellular entry of feline infectious peritonitis virus. *J Virol*. 2010;84:7917-7921.
35. Takano T, Ohyama T, Kokumoto A, et al. Vascular endothelial growth factor (VEGF), produced by feline infectious peritonitis (FIP) virus-infected monocytes and macrophages, induces vascular permeability and effusion in cats with FIP. *Virus Res*. 2011;158:161-168.
36. Kiss I, Poland AM, Pedersen NC. Disease outcome and cytokine responses in cats immunized with an avirulent feline infectious peritonitis virus (FIPV)-UCD1 and challenge-exposed with virulent FIPV-UCD8. *J Feline Med Surg*. 2004;6:89-97.
37. Takano T, Azuma N, Satoh M, et al. Neutrophil survival factors (TNF-alpha, GM-CSF, and G-CSF) produced by macrophages in cats infected with feline infectious peritonitis virus contribute to the pathogenesis of granulomatous lesions. *Arch Virol*. 2009;154:775-781.
38. de Groot-Mijnes JD, van Dun JM, van der Most RG, et al. Natural history of a recurrent feline coronavirus infection and the role of cellular immunity in survival and disease. *J Virol*. 2005;79:1036-1044.
39. Davidson BJ, Paling AC, Lahmers SL, et al. Disease association and clinical assessment of feline pericardial effusion. *J Am Anim Hosp Assoc*. 2008;44:5-9.
40. Bradshaw JM, Pearson GR, Gruffydd-Jones TJ. A retrospective study of 286 cases of neurological disorders of the cat. *J Comp Pathol*. 2004;131:112-120.
41. Hayashi T, Ishida T, Fujiwara K. Glomerulonephritis associated with feline infectious peritonitis. *Nihon Juigaku Zasshi*. 1982;44:909-916.
42. Taylor SS, Tappin SW, Dodkin SJ, et al. Serum protein electrophoresis in 155 cats. *J Feline Med Surg*. 2010;12:643-653.
43. Sparkes AH, Gruffydd-Jones TJ, Harbour DA. Feline infectious peritonitis: a review of clinicopathological changes in 65 cases, and a critical assessment of their diagnostic value. *Vet Rec*. 1991;129:209-212.
44. Hartmann K, Binder C, Hirschberger J, et al. Comparison of different tests to diagnose feline infectious peritonitis. *J Vet Intern Med*. 2003;17:781-790.
45. Jeffery U, Dietz K, Hostetter S. Positive predictive value of albumin:globulin ratio for feline infectious peritonitis in a mid-western referral hospital population. *J Fel Med Surg*. 2012;14:903-905.
46. Duthie S, Eckersall PD, Addie DD, et al. Value of alpha 1-acid glycoprotein in the diagnosis of feline infectious peritonitis. *Vet Rec*. 1997;141:299-303.
47. Giori L, Giordano A, Giudice C, et al. Performances of different diagnostic tests for feline infectious peritonitis in challenging clinical cases. *J Small Anim Pract*. 2011;52:152-157.
48. Savary KC, Sellon RK, Law JM. Chylous abdominal effusion in a cat with feline infectious peritonitis. *J Am Anim Hosp Assoc*. 2001;37:35-40.
49. Shelly SM, Scarlett-Kranz J, Blue JT. Protein electrophoresis on effusions from cats as a diagnostic test for feline infectious peritonitis. *J Am Anim Hosp Assoc*. 1988;24:495-500.
50. Fischer Y, Sauter-Louis C, Hartmann K. Diagnostic accuracy of the Rivalta test for feline infectious peritonitis. *Vet Clin Pathol*. 2012;41:558-567.
51. Boettcher IC, Steinberg T, Matiasek K, et al. Use of anti-coronavirus antibody testing of cerebrospinal fluid for diagnosis of feline infectious peritonitis involving the central nervous system in cats. *J Am Vet Med Assoc*. 2007;230:199-205.
52. Foley JE, Lapointe JM, Koblik P, et al. Diagnostic features of clinical neurologic feline infectious peritonitis. *J Vet Intern Med*. 1998;12:415-423.
53. Lewis KM, O'Brien RT. Abdominal ultrasonographic findings associated with feline infectious peritonitis: a retrospective review of 16 cases. *J Am Anim Hosp Assoc*. 2010;46:152-160.
54. Pratelli A. Comparison of serologic techniques for the detection of antibodies against feline coronaviruses. *J Vet Diagn Invest*. 2008;20:45-50.
55. Tammer R, Evensen O, Lutz H, et al. Immunohistological demonstration of feline infectious peritonitis virus antigen in paraffin-embedded tissues using feline ascites or murine monoclonal antibodies. *Vet Immunol Immunopathol*. 1995;49:177-182.
56. Ishida T, Shibana A, Tanaka S, et al. Use of recombinant feline interferon and glucocorticoid in the treatment of feline infectious peritonitis. *J Feline Med Surg*. 2004;6:107-109.
57. Ritz S, Egberink H, Hartmann K. Effect of feline interferon-omega on the survival time and quality of life of cats with feline infectious peritonitis. *J Vet Intern Med*. 2007;21:1193-1197.
58. Legendre AM, Bartges JW. Effect of Polyprenyl Immunostimulant on the survival times of three cats with the dry form of feline infectious peritonitis. *J Feline Med Surg*. 2009;11:624-626.
59. Watari T, Kaneshima T, Tsujimoto H, et al. Effect of thromboxane synthetase inhibitor on feline infectious peritonitis in cats. *J Vet Med Sci*. 1998;60:657-659.
60. Hsieh LE, Lin CN, Su BL, et al. Synergistic antiviral effect of *Galanthus nivalis* agglutinin and nelfinavir against feline coronavirus. *Antiviral Res*. 2010;88:25-30.
61. McDonagh P, Sheehy PA, Norris JM. In vitro inhibition of feline coronavirus replication by small interfering RNAs. *Vet Microbiol*. 2011;150:220-229.
62. Tanaka Y, Sato Y, Osawa S, et al. Suppression of feline coronavirus replication in vitro by cyclosporin A. *Vet Res*. 2012;41-43.
63. Fehr D, Holzngel E, Bolla S, et al. Placebo-controlled evaluation of a modified live virus vaccine against feline infectious peritonitis: safety and efficacy under field conditions. *Vaccine*. 1997;15:1101-1109.
64. Postorino Reeves NC, Pollock RV, Thurber ET. Long-term follow-up study of cats vaccinated with a temperature-sensitive feline infectious peritonitis vaccine. *Cornell Vet*. 1992:82.
65. Postorino Reeves NC. Vaccination against naturally-occurring FIP in a single large cat shelter. *Feline Pract*. 1995;23:81-82.