


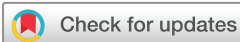ORIGINAL RESEARCH

Subchondral bone attenuation coefficient utility of the sacroiliac margins to differentiate spondyloarthritis and osteitis condensans ilii

Alexandre Terrier,¹ Olivier Fakh, ² Mickaël Chouk, ² Clément Prati, ^{2,3} Daniel Wendling, ^{2,4} Sébastien Aubry, ^{1,5} Frank Verhoeven ^{2,3}

To cite: Terrier A, Fakh O, Chouk M, *et al.* Subchondral bone attenuation coefficient utility of the sacroiliac margins to differentiate spondyloarthritis and osteitis condensans ilii. *RMD Open* 2022;**8**:e002275. doi:10.1136/rmdopen-2022-002275

Received 9 February 2022
Accepted 19 April 2022



© Author(s) (or their employer(s)) 2022. Re-use permitted under CC BY-NC. No commercial re-use. See rights and permissions. Published by BMJ.

¹Musculo Skeletal Imaging, CHU Besançon, Besançon, France

²Department of Rheumatology, CHU Besançon, Besançon, France

³EA 4267 "PEPITE", UFR Santé, Franche-Comté University, 19 rue Ambroise Paré, 25030 Besançon cedex, France

⁴EA 4266 "EPILAB", UFR Santé, Franche-Comté University, 19 rue Ambroise Paré, 25030 Besançon cedex, France

⁵EA4662 Nanomedicine laboratory, UFR Santé, Franche-Comté university, 19 rue Ambroise Paré, 25030 Besançon cedex, France

Correspondence to

Dr Frank Verhoeven;
fverhoeven@chu-besancon.fr

ABSTRACT

Introduction Differentiating ankylosing spondylitis (AS) from osteitis condensans ilii (OCI) remains challenging for clinicians. The aim of this study was to determine whether Subchondral Bone Attenuation Coefficient of the Sacroiliac margins (SBAC-SI) is different in AS, OCI and diffuse idiopathic skeletal hyperostosis (DISH).

Methods A monocentric retrospective observational study was performed at the University Hospital of Besançon. Patients included were followed for AS, DISH or OCI and underwent CT scan including sacroiliac joint. Patients with tumour lesion of bone or a history of pelvic radiotherapy were excluded. AS and OCI patients were matched with a control of the same age and sex. SBAC-SI was evaluated by the sum of 24 identical circular regions of interest, 8 per slice (anterior, middle and posterior).

Results Thirty AS and AS controls, 31 DISH, 29 OCI and OCI controls were included. SBAC-SI score was 9727 (\pm 2430) in the OCI group ($p < 0.001$), 3563 (\pm 1860) in the AS group, 3899 (\pm 1937) in the DISH group, 4224 (\pm 1693) in the AS control group and 5445 (\pm 1205) in the OCI control group. A threshold of 7500 HU had the best discriminative value between OCI and AS (youden index: 0.89). In AS, disease duration is negatively associated with SBAC-SI ($r: -0.623$; $p < 0.01$) and HLA B27 is associated with lower SBAC-SI (6523 (5198; 7137) vs 2809 (1568; 3371); $p < 0.001$).

Conclusion SBAC-SI is significantly different between AS and OCI and could help to distinguish these two diseases.

INTRODUCTION

Axial spondyloarthritis (axSpA) is a chronic inflammatory rheumatic disease characterised by inflammatory back pain and potential extra-articular manifestations.¹ The ASAS classification criteria for axSpA include an important imaging component (either MRI sacroiliitis or radiographic sacroiliitis).² However, there are several limitations: first, the MRI criteria were developed in a defined cross-sectional study population (age <45 years and with back pain

WHAT IS ALREADY KNOWN ON THIS TOPIC?

- ⇒ Osteitis condensans ilii (OCI) is often associated with bone marrow oedema of the sacroiliac joints.
- ⇒ Differentiating ankylosing spondylitis (AS) from OCI remains challenging for clinicians.

WHAT THIS STUDY ADDS?

- ⇒ Subchondral Bone Attenuation Coefficient of the Sacroiliac margins (SBAC-SI) is different between AS and OCI.
- ⇒ A threshold of 7500 HU had the best discriminative value (youden index: 0.89) between OCI and AS.

HOW THIS STUDY MIGHT AFFECT RESEARCH, PRACTICE OR POLICY?

- ⇒ SBAC-SI could be useful to distinguish AS and OCI.

for at least 3 months), so for older patients, MRI criteria are not validated. Then, MRI can be a source of several false positives results.³⁻⁵ Indeed, several authors have recently demonstrated that subchondral bone marrow oedema can also occur in healthy volunteers,^{6,7} in athletes⁸ and in osteitis condensans ilii (OCI)⁹ and in post-partum women.¹⁰ OCI is a complex differential diagnosis with inflammatory sacroiliitis. Indeed, a recent series showed a high prevalence of osteitis on MRI in OCI.¹¹ Thus, differentiating axSpA from OCI remains challenging for clinicians.

CT of sacroiliac joints (SIJ) is sensitive and considered as a gold standard of structural damage detection (erosions, sclerosis and ankylosis). This imaging procedure enables to measure attenuation coefficients, that is, to measure how easily a material can be penetrated by X-rays,¹² of the subchondral bone, where the sclerosis occurs in OCI, diffuse idiopathic skeletal hyperostosis (DISH), ankylosing spondylitis (AS) and osteoarthritis. The subchondral

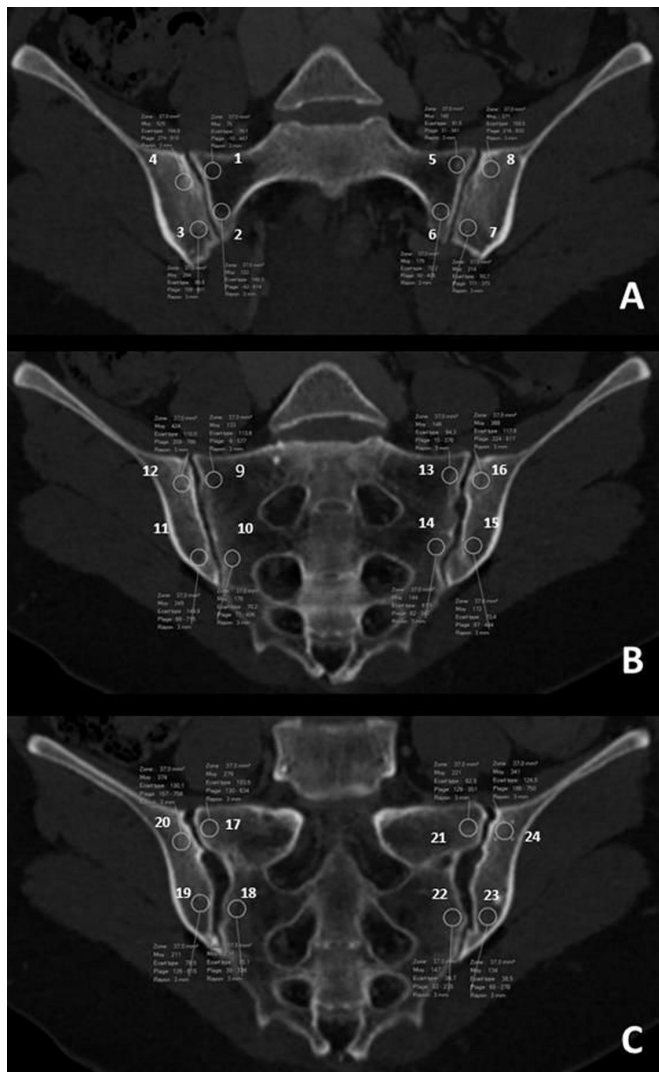


Figure 1 Definition of the 24 ROI in the anterior (A), middle (B) and posterior (C) slices in the coronal oblique plane of the sacroiliac joints. ROI, region of interest.

bone attenuation coefficient corresponded to the average bone mineral density, in Hounsfield units (HU), of a region of interest (ROI), drawn in the trabecular bone, avoiding cortical bone. Recent studies showed that subchondral bone attenuation coefficient of the first lumbar vertebra was useful for identifying osteoporosis.^{13 14} Ulano *et al*¹⁵ demonstrated that CT attenuation measurements can be used to distinguish untreated osteoblastic metastases from enostoses.¹⁶

The aim of our study was to determine whether Subchondral Bone Attenuation Coefficient of the Sacroiliac margins (SBAC-SI) is different in AS, OCI, DISH and thus enable to differentiate AS from OCI.

METHODS

Study design and characteristics of the patients

A retrospective monocentric observational study was performed using the medical records of the rheumatology department of the University Hospital of Besançon. The patients included were known for AS meeting the ASAS 2009 criteria¹ and New York modified criteria, DISH, OCI and had

Table 1 Patients characteristics

	AS (30)	Control AS (30)	OCI (29)	Control OCI (29)	DISH (31)
Age (years)	63.4±1.5	60.3±3.4	37.9±1.5	37.6±1.4	76.9±1.7
Male (%)	50 %	50 %	0 %	0 %	52 %
Disease duration (years)	19.88±13	-	-	-	-
HLA B27 (%)	77 %	-	-	-	-
Sacroiliac ankylosis	23 %	0 %	0 %	0 %	0 %
Physical work smoker	56 %				
	57 %				

AS, ankylosing spondylitis; DISH, diffuse idiopathic skeletal hyperostosis; OCI, osteitis condensans ilii.

realised a CT-scan including the SIJ in its entirety. A query was then carried out in the hospital's picture archiving and communication system to identify patients with AS, OCI and DISH, who had undergone any CT exam which included the SIJ in their entirety. AS and OCI patients were then matched with a control of the same age and sex, recruited through the hospital's picture archiving and communication system. For patients with AS, we searched for HLA B27 and active smoking given their impact on bone mineral density and the radiographic progression in spondyloarthritis.^{17 18} Non-inclusion criteria were the existence of tumour lesion of bone or a history of pelvic radiotherapy.

Attenuation coefficient acquisition and scoring system

All scans were acquired on the same CT-scan unit (Somatom 64 definition AS+, Siemens Healthineers, Erlangen, Germany), with a slice thickness of 0.625 mm. In the coronal oblique plane of the SIJ, three slices (anterior, middle and posterior) and four quadrants per slice were defined (figure 1). Twenty-four identical circular ROIs (30 mm²), eight per slice, were manually placed separately subcortical to the SIJ, four on the sacral side and four on the iliac side. The distance between the circle of the ROI and the cortical bone was 2–3 mm. An overall score was obtained from the sum of all ROIs. For every ROI, an attenuation coefficient was measured and expressed in HU. The total SBAC-SI score was the sum of the 24 ROI. The sacral and iliac SBAC-SI

Table 2 Subchondral bone attenuation coefficient of the sacroiliac margins

	AS	Control AS	OCI	Control OCI	DISH
Total score (Mean±SD)	3563 (±1860)	4224 (±1693)	9727 (±2430)*	5445 (±1205)	3899 (±1937)
Sacral score (Mean±SD)	1283 (±883)	1388 (±643)	3085 (±1066)*	2019 (±486)	1273 (±661)
Iliac score (Mean±SD)	2386 (±1190)	2824 (±1123)	6540 (±1801)*	3495 (±759)	2770 (±1330)

Values are expressed in Hounsfield unit.

*P<0.001 vs AS.

AS, ankylosing spondylitis; DISH, diffuse idiopathic skeletal hyperostosis; OCI, osteitis condensans ilii.

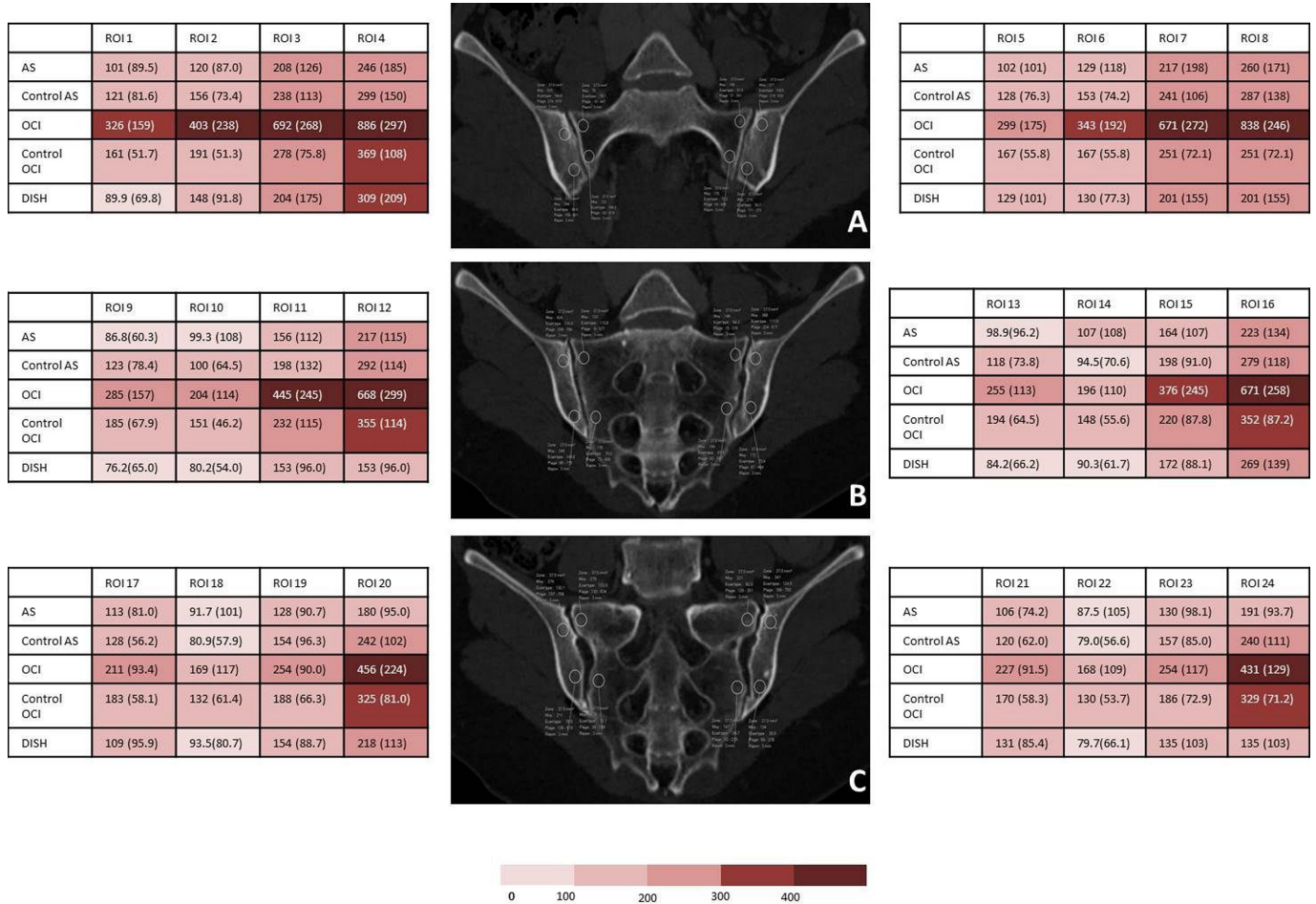


Figure 2 Distribution of the Subchondral Bone Attenuation Coefficients of the Sacroiliac Margins of the 24 ROI in the anterior (A), middle (B) and posterior (C) slices in the coronal oblique plane of the sacroiliac joints. Values are expressed in Hounsfield unit. AS, ankylosing spondylitis; DISH, diffuse idiopathic skeletal hyperostosis; OCI, osteitis condensans ilii; ROI, region of interest.

scores were the sum of the sacral or the iliac ROI. The intra-observer correlation was evaluated on the 10 first patients with a kappa coefficient.

Statistical analysis

Quantitative variables were expressed as mean±SD and were compared using Student's t-test and Mann-Whitney U test. Qualitative variables were expressed as numbers and percentages and were compared using the χ^2 test. The Kruskal-Wallis test was used to evaluate the anatomic distribution of the different lesions. A value of $p < 0.05$ was considered significant. Analyses were performed using Graphpad Prism software (V.5.0).

RESULTS

Patients

Thirty AS, 29 OCI, 31 DISH, 29 OCI controls and 30 AS controls were included (table 1). The mean age was 63.4±1.5 years in the AS group with 50% males, 60.3±3.4 years in the AS control group with 50% males, 76.9±1.7 years in the DISH group with 52% males, 37.9±1.5 years in the OCI group with 100% females and 37.6±1.4 years in the OCI control group with 100% females. In the AS

group, 77% were HLA-B27 positive, 56% were physical workers and 57% were tobacco users. The mean disease duration of AS was 19.88±13 years and 7 (23%) patients had sacroiliac ankylosis.

Attenuation coefficient acquisition and scores

The intraobserver correlation was excellent with a kappa coefficient at 0.92. The overall score was 9727 (±2430) in the OCI group ($p < 0.001$; in comparison with other groups), 3563 (±1860) in the AS group, 3899 (±1937) in the DISH group, 4224 (±1693) in the AS control group and 5445 (±1205) in the OCI control group. Only the OCI group was different from the other groups. There was no difference between DISH and AS and no difference with the control groups. The sacral and iliac scores showed the same significant differences (table 2). The anterior slice shows the highest attenuation coefficients per ROI (figure 2). Moreover, this slice shows the most difference between the OCI group and the other groups and seemed to be the most discriminative slice. For each ROI, the attenuation coefficient is statistically greater in the OCI group compared with the other pathologies (figures 3 and 4).

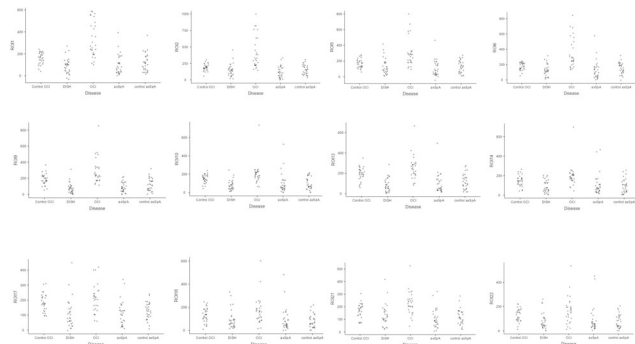


Figure 3 Distribution of the subchondral bone attenuation coefficients of the 12 sacral ROI in the anterior (first line), middle (second line) and posterior (third line) slices in the coronal oblique plane of the sacroiliac joints. ROI, region of interest.

Using the analysis of the ROC (receiver operating characteristic) curve, we showed that a threshold of 7500 HU had the best discriminative value between OCI and AS with a sensitivity of 89% and a specificity of 100% (youden index: 0.89). Finally, in AS group, the disease duration is negatively associated with SBAC-SI ($r: -0.623$; $p < 0.01$) and HLA B27 is associated with lower SBAC-SI (6523 (5198; 7137) vs 2809 (1568; 3371); $p < 0.001$).

DISCUSSION

Our study is the first to show that SBAC-SI can be useful to differentiate OCI from AS. It is also the first to assess the discriminatory capacity of this simple measurement.

The comparison between the AS and OCI groups shows a significant difference. However, the two groups are not comparable in age and gender. The comparison of the SBAC-SI between these two control groups did not show any significant difference. In addition, we compared the SBAC-SI of men and women in the AS group. This analysis did not reveal any significant gender differences.

A surprising result is the lack of clear condensation in the AS group. This is partly explained by the age of the patients in the AS group and the high proportion of SIJ

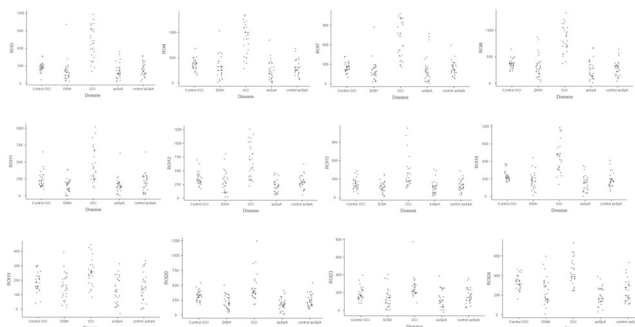


Figure 4 Distribution of the subchondral bone attenuation coefficients of the 12 iliac ROI in the anterior (first line), middle (second line) and posterior (third line) slices in the coronal oblique plane of the sacroiliac joints. ROI, region of interest.

ankylosis. SIJ ankylosis reduces stress on the bone and thus reduces bone condensation.

The SBAC-SI score has not been assessed in non-radiographic axSpA and may be of interest. Nevertheless, the usefulness of our score is to differentiate between two pathologies with structural damage. In case of absence of structural damage, as in non-radiographic axSpA, this analysis loses its interest.

The assessment of the overall score is time-consuming in daily practice and this represents a significant limitation of this score. Nevertheless, we have shown that each ROI allows us to discriminate between AS and OCI. Moreover, the anterior slice showed the most marked difference. Thus, it seems reasonable to favour the anterior slice for measuring ROI in daily practice.

Our study suffers from several limitations. First, the small number of patients in each group and the retrospective nature is a major limitation. Nevertheless, we chose to do a monocentric study to avoid possible technical differences with the use of two different CT scanners.

Second, important clinical elements are missing, such as disease activity in spondyloarthritis, treatment of patients, body mass index, physical activity and number of gestation and time since last pregnancy for women.

In addition, the manual positioning of ROIs represents a technical limitation. Nevertheless, we have evaluated the intraobserver reproducibility, which is very good and limits this bias.

Finally, as mentioned above, the different groups are not comparable in terms of age and sex ratio. Nevertheless, we repeated the analyses by pooling the control groups and found, using linear regression, a correlation between age and the SBAC-SI total score (correlation coefficient: -0.696 (-0.808 ; -0.535); $p < 0.001$) but not with the gender.

In conclusion, our study shows that SBAC-SI is significantly different between AS and OCI and could be used to distinguish these two diseases. Larger studies with younger AS are needed to confirm these first data.

Twitter Frank Verhoeven @fverhoeven

Contributors Each individual named as an author meets the Uniform Requirements for Manuscripts Submitted to Biomedical Journals criteria for authorship. All authors have read and approved submission of the manuscript. FV is responsible for the overall content as guarantor

Funding The authors have not declared a specific grant for this research from any funding agency in the public, commercial or not-for-profit sectors.

Competing interests None declared.

Patient consent for publication Not applicable.

Ethics approval Patients and controls were informed about the use of their medical data and did not object to the study, according to Good Clinical Practice guidelines, before the start of the study. This was not an interventional study and therefore no ethics committee was required. This study was performed in compliance with the Declaration of Helsinki and French legislation for the protection of personal data.

Provenance and peer review Not commissioned; externally peer reviewed.

Data availability statement All data relevant to the study are included in the article or uploaded as online supplemental information.

Open access This is an open access article distributed in accordance with the Creative Commons Attribution Non Commercial (CC BY-NC 4.0) license, which permits others to distribute, remix, adapt, build upon this work non-commercially,

and license their derivative works on different terms, provided the original work is properly cited, appropriate credit is given, any changes made indicated, and the use is non-commercial. See: <http://creativecommons.org/licenses/by-nc/4.0/>.

ORCID iD

Frank Verhoeven <http://orcid.org/0000-0003-2708-2918>

REFERENCES

- 1 Sieper J, Poddubnyy D. Axial spondyloarthritis. *Lancet* 2017;390:73–84.
- 2 Rudwaleit M, van der Heijde D, Landewé R, *et al*. The development of assessment of spondyloarthritis International Society classification criteria for axial spondyloarthritis (part II): validation and final selection. *Ann Rheum Dis* 2009;68:777–83.
- 3 Weber U, Lambert RGW, Østergaard M, *et al*. The diagnostic utility of magnetic resonance imaging in spondylarthritis: an international multicenter evaluation of one hundred eighty-seven subjects. *Arthritis Rheum* 2010;62:3048–58.
- 4 Arnbak B, Grethe Jurik A, Hørslev-Petersen K, *et al*. Associations between spondyloarthritis features and magnetic resonance imaging findings: a cross-sectional analysis of 1,020 patients with persistent low back pain. *Arthritis Rheumatol* 2016;68:892–900.
- 5 Lambert RGW, Bakker PAC, van der Heijde D, *et al*. Defining active sacroiliitis on MRI for classification of axial spondyloarthritis: update by the ASAS MRI Working group. *Ann Rheum Dis* 2016;75:1958–63.
- 6 Baraliakos X, Richter A, Feldmann D, *et al*. Frequency of MRI changes suggestive of axial spondyloarthritis in the axial skeleton in a large population-based cohort of individuals aged <45 years. *Ann Rheum Dis* 2020;79:186–92.
- 7 de Winter J, de Hooge M, van de Sande M, *et al*. Magnetic resonance imaging of the Sacroiliac joints indicating sacroiliitis according to the assessment of spondyloarthritis International Society definition in healthy individuals, runners, and women with postpartum back pain. *Arthritis Rheumatol* 2018;70:1042–8.
- 8 Weber U, Jurik AG, Zejden A, *et al*. Frequency and anatomic distribution of magnetic resonance imaging features in the Sacroiliac joints of young athletes. *Arthritis Rheumatol* 2018;70:736–45.
- 9 Ma L, Gao Z, Zhong Y, *et al*. Osteitis condensans ilii may demonstrate bone marrow edema on sacroiliac joint magnetic resonance imaging. *Int J Rheum Dis* 2018;21:299–307.
- 10 Renson T, Depicker A, De Craemer A-S, *et al*. High prevalence of spondyloarthritis-like MRI lesions in postpartum women: a prospective analysis in relation to maternal, child and birth characteristics. *Ann Rheum Dis* 2020;79:929–34.
- 11 Poddubnyy D, Weineck H, Diekhoff T, *et al*. Clinical and imaging characteristics of osteitis condensans ilii as compared with axial spondyloarthritis. *Rheumatology* 2020;59:3798–806.
- 12 Hounsfield GN. Computed medical imaging. Nobel lecture, Decemberr 8, 1979. *J Comput Assist Tomogr* 1980;4:665–74.
- 13 Pickhardt PJ, Pooler BD, Lauder T, *et al*. Opportunistic screening for osteoporosis using abdominal computed tomography scans obtained for other indications. *Ann Intern Med* 2013;158:588–95.
- 14 Fauny M, Verhoeven F, Allado E, *et al*. Relationship between spinal structural damage on radiography and bone fragility on CT in ankylosing spondylitis patients. *Sci Rep* 2021;11:9342.
- 15 Ulano A, Bredella MA, Burke P, *et al*. Distinguishing untreated osteoblastic metastases from Enostoses using CT attenuation measurements. *AJR Am J Roentgenol* 2016;207:362–8.
- 16 Sala F, Dapoto A, Morzenti C, *et al*. Bone islands incidentally detected on computed tomography: frequency of enostosis and differentiation from untreated osteoblastic metastases based on CT attenuation value. *Br J Radiol* 2019;92:20190249.
- 17 Yuan S, Michaëlsson K, Wan Z, *et al*. Associations of smoking and alcohol and coffee intake with fracture and bone mineral density: a Mendelian randomization study. *Calcif Tissue Int* 2019;105:582–8.
- 18 Villaverde-García V, Cobo-Ibáñez T, Candelas-Rodríguez G, *et al*. The effect of smoking on clinical and structural damage in patients with axial spondyloarthritis: a systematic literature review. *Semin Arthritis Rheum* 2017;46:569–83.