

# Treatment outcome and long-term stability of skeletal changes following maxillary distraction in adult subjects of cleft lip and palate

SATINDER PAL SINGH, ASHOK KUMAR JENA, VIDYA RATTAN<sup>1</sup>, ASHOK KUMAR UTREJA

## Abstract

**Aim:** To evaluate the treatment outcome and long-term stability of skeletal changes following maxillary advancement with distraction osteogenesis in adult subjects of cleft lip and palate. **Materials and Methods:** Total 12 North Indian adult patients in the age range of 17-34 years with cleft lip and palate underwent advancement of maxilla by distraction osteogenesis. Lateral cephalograms recorded prior to distraction, at the end of distraction, 6 months after distraction, and at least 24 months (mean  $25.5 \pm 1.94$  months) after distraction osteogenesis were used for the evaluation of treatment outcome and long-term stability of the skeletal changes. Descriptive analysis, ANOVA, and post-hoc test were used, and  $P$ -value 0.05 was considered as a statistically significant level. **Results:** Maxillary distraction resulted in significant advancement of maxilla ( $P < 0.001$ ). Counterclockwise rotation of the palatal plane took place after maxillary distraction. The position of the mandible and facial heights were stable during distraction. During the first 6 months of the post-distraction period, the maxilla showed relapse of approximately 30%. However, after 6 months post distraction, the relapse was very negligible. **Conclusions:** Successful advancement of maxilla was achieved by distraction osteogenesis in adult subjects with cleft lip and palate. Most of the relapse occurred during the first 6 months of post-distraction period, and after that the outcomes were stable.

**Keywords:** Cleft palate, long-term stability, maxillary distraction

## Introduction

Maxillary hypoplasia is a common deformity in subjects with repaired cleft lip and palate. About 25% of these subjects require orthognathic surgery for the correction of this deformity.<sup>[1,2]</sup> Distraction osteogenesis of maxilla is a widely accepted, predictable, and stable technique for the correction of severe maxillary hypoplasia in subjects with cleft lip and palate.<sup>[3-15]</sup> Maxillary distraction allows global improvement of facial esthetics, allows advancement of maxilla even during the period of mixed dentition, and also allows better velopharyngeal function.<sup>[16]</sup> Distraction of the maxilla in most of the cleft lip and palate subjects is usually carried out in the growing period.<sup>[17]</sup> The major problem of considering maxillary distraction in growing subjects is the prediction

of over-correction. In adult subjects in whom growth of craniofacial structures is complete, the over-correction is usually predictable. Although many studies are there in the literature mentioning the effects of maxillary distraction in growing subjects with cleft lip and palate,<sup>[3-10]</sup> there are only few studies mentioning the effects of maxillary distraction in adult subjects with cleft lip and palate.<sup>[11,15,18,19]</sup> In all the previous studies,<sup>[11,15,18,19]</sup> the long-term stability of maxillary distraction was highly variable; thus, the present study was conducted to find out the treatment outcomes and long-term stability of skeletal changes following maxillary distraction in adult subjects with cleft lip and palate.


## Materials and Methods

The study was conducted on 12 (M=7, F=5) North Indian adult subjects in the age range of 17–34 years with complete cleft lip and palate who underwent advancement of maxilla by distraction osteogenesis. Among 12 subjects, 8 were with unilateral cleft lip and palate and 4 with bilateral cleft lip and palate. None of the subjects had received alveolar bone grafting. All the subjects had severe anteroposterior maxillary hypoplasia with Class III malocclusion and reverse overjet.

In all the subjects, maxillary arch was prepared by multibonded fixed orthodontic appliance prior to distraction. After the preparation of maxillary arch, the multibonded appliance was removed and an alginate impression was made for splint fabrication. High Le Fort I osteotomy with septal and pterygomaxillary disjunction was carried out. The splint was cemented to the maxillary arch with glass ionomer cement and the customized distractor was fixed.

*Units of Orthodontics and <sup>1</sup>Oral and Maxillofacial Surgery, Oral Health Sciences Centre, Post Graduate Institute of Medical Education and Research, Chandigarh, India*

**Correspondence:** Dr. Satinder Pal Singh, Unit of Orthodontics, Oral Health Sciences Centre, Post Graduate Institute of Medical Education and Research, Sector-12, Chandigarh, India.  
E-mail: drspsingh\_chd@yahoo.com

Access this article online	
Quick Response Code:	Website: <a href="http://www.contempclindent.org">www.contempclindent.org</a>
	DOI: 10.4103/0976-237X.96827

After latency period of 4–6 days, distraction was started at the rate of approximately 1 mm per day by adjusting the screws attached to the traction wires of the intraoral splint. The distraction vector was parallel and along the occlusal plane. All the subjects were followed up weekly and active distraction was continued until 5–8 mm of positive overjet was achieved. After the consolidation period of approximately 6–8 weeks, the distractor and occlusal splints were removed. The fixed orthodontic appliance was again bonded and the correction was retained by Class III elastic traction ( $\frac{1}{4}$ ", 6 oz force). The same oral surgeon (VR) carried out the procedures in all the patients.

### The distractor

The rigid extraoral distractor device consists of a cranial fixation component (the haloframe), a distractor, a vertical rod connecting the haloframe and distractor, and an intraoral splint [Figure 1]. The intraoral splint was consisting of a rigid metallic wire framework, i.e., a face bow consisting of 0.045" diameter inner bow and 0.055" diameter outer bow. The inner bow of the face bow was adapted on to the plaster dental cast. Then, the framework was covered with self-cure acrylic to make the splint. The height of the acrylic splint was adjusted to keep 2–3 mm of interincisal clearance. The outer bow was bent as traction wire to fit to the distractor screw [Figure 2].

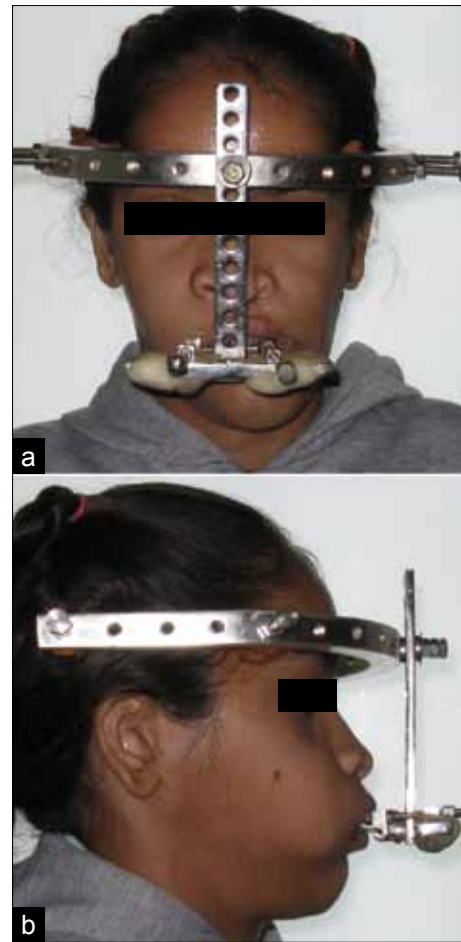
The lateral cephalograms were recorded at the beginning of treatment, before distraction procedure ( $T_0$ ), at the end of distraction ( $T_1$ ), 6 months after the end of distraction ( $T_2$ ), and at least 24 months after the distraction osteogenesis ( $T_3$ ). The mean time interval between the  $T_2$  and  $T_3$  was  $25.5 \pm 1.94$  months. A few cephalograms were recorded in a different machine, but the magnifications were adjusted accordingly.

For the evaluation of skeletal and soft tissue changes, lateral cephalograms recorded at  $T_0$ ,  $T_1$ ,  $T_2$ , and  $T_3$  were traced manually and considered for analysis. All the cephalograms were traced and analyzed by the same investigator (AKJ). All the linear and angular variables were measured twice and the mean was considered for statistical analysis. Various cephalometric landmarks and linear and angular parameters for the evaluation of changes in the skeletal tissue are shown in Figure 3.

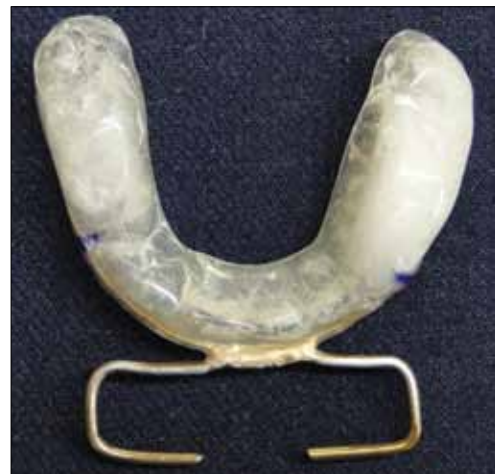All the statistical analyses were performed with SPSS software. The data were subjected to descriptive analysis for mean, range, and standard deviation of all variables. ANOVA and post-hoc test were used and probability value ( $P$ -value) of 0.05 was considered as a statistically significant level.

## Results

The results of all cephalometric measurements at various time intervals are described in Table 1. The mean age of the subjects at the beginning of the maxillary distraction was

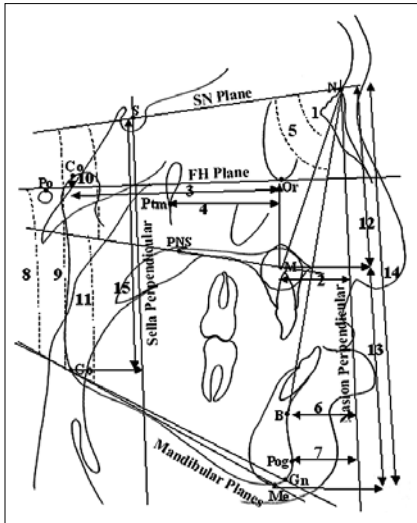


**Figure 1:** The custom-made rigid extraoral distractor device fixed in the patient. (a) Front view, (b) Lateral view



**Figure 2:** The intraoral splint

$23.39 \pm 4.39$  years. Significant improvements in the skeletal relationships were found at the end of maxillary distraction ( $T_1$ ) and 70% of the improvements remained stable after 2 years of distraction. The maxilla (M-point) was advanced approximately 12 mm from the pterygomaxillary fissure (Ptm-M), Nasion perpendicular (Nper-M), and Condylion (Co-



**Figure 3:** Cephalometric landmarks and various linear and angular parameters for the evaluation of skeletal changes at various time intervals of maxillary distraction. **Landmarks.** S: Sella; N: Nasion; Co: Condylion; Po: Porion; Or: Orbitale; M: Center of the pre-maxilla; Ptm: Pterygomaxillary fissure; PNS: Posterior nasal spine; Go: Gonion; B: Point-B; Gn: Gnathion; Me: Menton. **Reference planes.** SN plane: Line joining 'S' and 'N'; FH plane: Line joining 'Po' and 'Or'; Nasion perpendicular (Nper): Perpendicular plane on FH plane at 'N'; Sella perpendicular: Perpendicular plane on FH plane at 'S'. **Linear and angular parameters.** 1. SNM: The angle between 'S', 'N' and 'M' points; 2. Nper-M: Smallest linear distance from point 'M' to Nasion perpendicular; 3. Co-M: Linear distance between the perpendiculars drawn from 'Co' and 'M' points on FH plane; 4. Ptm-M: Linear distance between the perpendiculars drawn from 'Ptm' and 'M' points on FH plane; 5. SNB: The angle between 'S', 'N' and 'B' points; 6. Nper-B: Smallest linear distance from 'B' point to Nasion perpendicular; 7. Nper-Pog: Smallest linear distance from 'Pog' point to Nasion perpendicular; 8. FMA: The angle between FH plane and Mandibular plane (Go-Me); 9. SN-GoGn: The angle between SN plane and mandibular plane (Go-Gn); 10. S-N × M-PNS: The angle between SN plane and palatal plane (M-PNS); 11. M-PNS × Go-Mn: The angle between palatal plane (M-PNS) and mandibular plane (Go-Me); 12. N-M: Linear distance from 'N' point to the perpendicular drawn from 'M' point on the Nasion perpendicular and it represents the upper anterior facial height; 13. M-Me: Linear distance between the perpendiculars drawn from 'M' point and 'Me' point on Nasion perpendicular and it represents as lower anterior facial height; 14. N-Me: Linear distance from 'N' point to the perpendicular drawn from 'Me' point on the Nasion perpendicular and it represents the total anterior facial height; 15. S-Go: Linear distance from 'S' point to the perpendicular drawn from 'Go' point on the Sella perpendicular and it represents the total posterior facial height.

M) at the end of distraction ( $T_0$ ), but relapse of approximately 4 mm (30%) took place at the end of 6 months of distraction ( $T_2$ ). The pre-distraction ( $T_0$ ) value of SNM, Nper-M, Co-M, and Ptm-M were increased significantly at  $T_1$ ,  $T_2$ , and  $T_3$ . During  $T_1$  and  $T_2$  period, these values were reduced by approximately 30%, and during the period of  $T_2$  and  $T_3$  the changes were

very minimum. The S-N × M-PNS value was decreased and M-PNS × Go-Mn value was increased at  $T_1$ , but the differences were not significant statistically. The SNB, Nper-B, Nper-Pog values were comparable at various time intervals of maxillary distraction. The FMA and SN-GoGn values were slightly increased by the maxillary distraction but were comparable. The anterior and posterior facial heights were also increased by the maxillary distraction but the difference among them at various time intervals was very less and not significant statistically.

## Discussion

Distraction osteogenesis was found to be a successful method for maxillary advancement in adult subjects with cleft lip and palate. The maxillary distraction osteogenesis improved the skeletal relationship significantly, and 70% of the improvements remained stable in the long-term follow-up. The distraction osteogenesis allowed skeletal changes, achieved by callus manipulation inducing tissue regeneration, and the expansion of the investing soft tissue functional matrix had the great benefit of the regeneration procedure.<sup>[20,21]</sup> In our patients, an average of 12 mm advancement of the maxilla took place. Similar to our result, Saito *et al.* also reported 11.1 mm forward advancement of the maxilla at point A from the pterygomaxillary fissure.<sup>[22]</sup> However, Aksu *et al.* reported 8 mm improvement in the effective maxillary length.<sup>[15]</sup> In two separate meta-analyses, Swennen *et al.*<sup>[23]</sup> and Cheung and Chua<sup>[17]</sup> noted that the most common range of maxillary advancement were in the range of 1–17 mm and 3–9 mm, respectively, by distraction osteogenesis with rigid external devices. The wide range of maxillary distraction could be because the degree of maxillary advancement depends on the severity of maxillary retrusion, and the more severe the retrusion the more was the advancement.<sup>[19]</sup> In our cases, we advanced the maxilla to a greater extent for overcoming the relapse.

Rotation of the maxilla during distraction is an important issue to be considered. In the present study, distraction caused counterclockwise rotation of the palatal plane. Many previous studies also reported counterclockwise rotation of the palatal plane during maxillary distraction osteogenesis.<sup>[15,24]</sup> As the distraction vector was below the center of resistance (CR) of maxilla and in forward direction along the occlusal plane, it resulted in counterclockwise rotation of the palatal plane. Gateno *et al.* noted a clockwise rotation of the maxilla if distraction force was applied above the CR of maxilla, and if the same force was applied below the CR of maxilla a counterclockwise rotation occurred.<sup>[25]</sup>

We observed almost stable anteroposterior and vertical position of the mandible after maxillary distraction osteogenesis. There was only 2.83° and 2.92° increase in the FMA and SN-GoGn, respectively, immediately after maxillary distraction, and they returned to the pre-distraction values

**Table-1: Treatment changes for all skeletal measurements before and at various time intervals after distraction osteogenesis of maxilla**

Variables	Pre- Post-Distraction (T <sub>0</sub> )	Immediate Post-Distraction (T <sub>1</sub> )	6-months Post-Distraction (T <sub>2</sub> )	Long-term Post-Distraction (T <sub>3</sub> )	P-value	Comparison
						T <sub>0</sub> -T <sub>1</sub> /T <sub>0</sub> -T <sub>2</sub> /T <sub>0</sub> -T <sub>3</sub> /T <sub>1</sub> -T <sub>2</sub> /T <sub>1</sub> -T <sub>3</sub> /T <sub>2</sub> -T <sub>3</sub>
	Mean ± SD	Mean ± SD	Mean ± SD	Mean ± SD		
SNM (°)	65.16 ± 4.26	78.5 ± 6.85	74.41 ± 4.64	73.33 ± 4.88	0.000	***/***/NS/NS/NS
Nper-M (mm)	-16.77 ± 4.65	-4.73 ± 6.27	-8.10 ± 4.54	-9.29 ± 3.78	0.000	***/***/NS/NS/NS
Co-M (mm)	69.90 ± 5.22	82.28 ± 2.97	79.00 ± 2.80	77.58 ± 3.37	0.000	***/***/NS/*/NS
Ptm-M (mm)	37.32 ± 3.47	49.39 ± 2.94	45.84 ± 2.78	43.77 ± 3.07	0.000	***/***/**/*/**/NS
S-N × M-PNS (°)	11.75 ± 5.75	6.00 ± 5.98	8.16 ± 4.74	9.41 ± 5.08	0.084	NS/NS/NS/NS/NS/NS
M-PNS × Go-Mn (°)	24.83 ± 6.14	29.66 ± 4.39	27.58 ± 4.75	27.75 ± 5.04	0.160	NS/NS/NS/NS/NS/NS
SNB (°)	80.58 ± 5.61	79.66 ± 4.71	79.91 ± 5.07	80.16 ± 5.23	0.976	NS/NS/NS/NS/NS/NS
Nper-B (mm)	-8.01 ± 6.60	-7.23 ± 7.13	-7.46 ± 7.00	-6.33 ± 6.92	0.946	NS/NS/NS/NS/NS/NS
Nper-Pog (mm)	-5.70 ± 7.22	-4.97 ± 8.32	-4.42 ± 7.98	-4.01 ± 8.31	0.959	NS/NS/NS/NS/NS/NS
FMA (°)	27.83 ± 5.52	30.66 ± 5.38	29.00 ± 4.93	28.44 ± 5.65	0.609	NS/NS/NS/NS/NS/NS
SN-GoGn (°)	31.33 ± 5.14	34.25 ± 4.71	32.83 ± 5.16	32.61 ± 5.12	0.572	NS/NS/NS/NS/NS/NS
N-M (mm)	53.51 ± 3.30	54.70 ± 3.49	54.00 ± 2.91	54.06 ± 2.87	0.837	NS/NS/NS/NS/NS/NS
M-Me (mm)	70.93 ± 4.79	72.71 ± 4.72	71.85 ± 4.71	71.52 ± 4.87	0.833	NS/NS/NS/NS/NS/NS
N-Me (mm)	124.45 ± 5.42	127.36 ± 6.92	125.88 ± 6.75	125.65 ± 6.44	0.741	NS/NS/NS/NS/NS/NS
S-Go (mm)	82.22 ± 6.14	83.36 ± 5.85	82.02 ± 5.73	82.44 ± 6.09	0.948	NS/NS/NS/NS/NS/NS

NS = Non-significant, \* $P < 0.05$ , \*\* $P < 0.01$  and \*\*\* $P < 0.001$

at the end of 6 months of distraction. In agreement with our result, many previous studies also reported a similar amount of opening of the mandibular plane angle after maxillary distraction with rigid external distraction (RED) devices in growing and adult cleft lip and palate subjects.<sup>[6,14,15,26]</sup> The upper anterior facial height (N-M) remained stable after maxillary distraction but the lower anterior facial height (M-Me) was increased marginally after immediate maxillary distraction. As the maxilla rotated in counterclockwise direction during distraction osteogenesis, the posterior aspect of the maxilla moved downward and caused slightly downward and backward rotation of the mandible, thus increasing the lower anterior facial height. The total anterior facial height (N-Me) was also marginally increased after maxillary distraction and was mainly contributed by the increased lower anterior facial height. The posterior facial height (S-Go), however, remained stable after maxillary distraction osteogenesis. Thus, the present study suggested that the maxillary distraction osteogenesis with customized distractor in adult subjects with cleft lip and palate had no deleterious effects on the other craniofacial structures and facial heights.

Advancing the maxilla is usually met with resistance from the soft tissue, musculature, and lip scar, thus causing relapse. Many previous studies noticed significant amount of relapse following maxillary distraction in patients with cleft lip and palate.<sup>[4,7,11,15]</sup> In the present study, we also noticed

relapse at the end of 6 months of maxillary distraction. The relapse tendency after distraction osteogenesis opposed the view that “expansion of the soft tissue functional matrix by distraction” could enhance the growth of maxilla as suggested by Swennen *et al.* in 2000.<sup>[18]</sup> The lack of active growth could be responsible for the lack of “expansion of the soft tissue functional matrix by distraction.” We noticed relapse of approximately 30% of the total advancement of maxilla during the 0–6 month follow-up period. Suzuki *et al.* also observed significant relapse during the first 6–months of post-distraction period, and after that the relapse was very less.<sup>[26]</sup> Cho and Kyung,<sup>[19]</sup> Aksu *et al.*<sup>[15]</sup> and Baek *et al.*<sup>[24]</sup> reported 23%, 22%, and 21%, respectively, relapse during post-distraction period in adult cleft lip and palate subjects. However, Kanno *et al.*<sup>[11]</sup> reported only 8% relapse over the 2.8-year follow-up period. The lack of growth in the soft tissue and delayed adaptation could be the factors causing more relapse in our patients when maxillary distraction was carried out in adult subjects with cleft lip and palate. The magnitude of maxillary advancement could also be considered as another factor causing more relapse in our patients because many previous studies also found a positive correlation between the magnitudes of relapse with the magnitude of advancement.<sup>[26,27]</sup> Kusmoto *et al.*<sup>[28]</sup> noted appearance of bone trabeculae in the pterygoid region after 6 weeks of maxillary distraction osteogenesis with RED devices and concluded that prolonged consolidation period was important for attaining stable skeletal results with the goal of preventing relapse.

Also, the preservation of the periosteum was important for bone regeneration process during and after distraction osteogenesis.<sup>[20,28,29]</sup>

## Conclusion

Thus, the present study showed that maxillary distraction with customized distractor was efficient in the correction of midface deficiency in adult subjects with cleft lip and palate. The results were stable in the long-term basis; however, 30% over-correction should be considered to match the relapse.

## References

- Precious DS. Treatment of retruded maxilla in cleft lip and palate-orthognathic surgery versus distraction osteogenesis: the case for orthognathic surgery. *J Oral Maxillofac Surg* 2007;65:758-61.
- Ross RB. Treatment variables affecting facial growth in complete unilateral cleft lip and palate. *Cleft Palate J* 1987;24:5-77.
- Cohen SR, Burstein FD, Stewart MB, Rathburn MA. Maxillary-midface distraction in children with cleft lip and palate: a preliminary report. *Plast Reconstr Surg* 1997;99:1421-8.
- Huang CS, Harikrishnan P, Liao YF, Ko EW, Liou EJ, Chen PK. Long-term follow-up after maxillary distraction osteogenesis in growing children with cleft lip and palate. *Cleft Palate Craniofac J* 2007;44:274-7.
- Harada K, Baba Y, Ohyama K, Omura K. Soft tissue profile changes of the midface in patients with cleft lip and palate following maxillary distraction osteogenesis: A preliminary study. *Oral Surg Oral Med Oral Pathol Oral Radiol Endod* 2002;94:673-7.
- Wen-Ching Ko E, Figueroa AA, Polley JW. Soft tissue profile changes after maxillary advancement with distraction osteogenesis by use of a rigid external distraction device: a 1-year follow-up. *J Oral Maxillofac Surg* 2000;58:959-69; discussion 969-70.
- Harada K, Sato M, Omura K. Long-term maxillomandibular skeletal and dental changes in children with cleft lip and palate after maxillary distraction. *Oral Surg Oral Med Oral Pathol Oral Radiol Endod* 2006;102:292-9.
- Sari E, Ucar C, Turk O, Kurtulmus H, Altug HA, Pocan S. Treatment of a patient with cleft lip and palate using an internal distraction device. *Cleft Palate Craniofac J* 2008;45:552-60.
- Tae KC, Gong SG, Min SK, Oh SW. Use of distraction osteogenesis in cleft palate patients. *Angle Orthod* 2003;73:602-7.
- Harada K, Sato M, Omura K. Long term skeletal and dental changes in patients with cleft lip and palate after maxillary distraction: a report of three cases treated with rigid external distraction device. *Cranio* 2005;23:152-7.
- Kanno T, Mitsugi M, Hosoe M, Sukegawa S, Yamauchi K, Furuki Y. Long-term skeletal stability after maxillary advancement with distraction osteogenesis in nongrowing patients. *J Oral Maxillofac Surg* 2008;66:1833-46.
- Polley JW, Figueroa AA. Rigid external distraction: its application in cleft maxillary deformities. *Plast Reconstr Surg* 1998;102:1360-72; discussion 1373-4.
- Wiltfang J, Hirschfelder U, Neukam FW, Kessler P. Long-term results of distraction osteogenesis of the maxilla and midface. *Br J Oral Maxillofac Surg* 2002;40:473-9.
- Figueroa AA, Polley JW, Friede H, Ko EW. Long-term skeletal stability after maxillary advancement with distraction osteogenesis using rigid external distraction device in cleft maxillary deformities. *Plast Reconstr Surg* 2004;114:1382-92; discussion 1393-4.
- Aksu M, Saglam-Aydinatay B, Akcan CA, El H, Taner T, Kocadereli I, *et al.* Skeletal and dental stability after maxillary distraction with a rigid external device in adult cleft lip and palate patients. *J Oral Maxillofac Surg* 2010;68:254-9.
- Scolozzi P. Distraction osteogenesis in the management of severe maxillary hypoplasia in cleft lip and palate patients. *J Craniofac Surg* 2008;19:1199-214.
- Cheung LK, Chua HD. A meta-analysis of cleft maxillary osteotomy and distraction osteogenesis. *Int J Oral Maxillofac Surg* 2006;35:14-24.
- Swennen G, Dujardin T, Goris A, De May A, Malevez C. Maxillary distraction osteogenesis: a method with skeletal anchorage. *J Craniofac Surg* 2000;11:120-7.
- Cho BC, Kyung HM. Distraction osteogenesis of the hypoplastic midface using a rigid external distraction system: the results of a one- to six-year follow-up. *Plast Reconstr Surg* 2006;118:1201-12.
- Rachmiel A, Rozen N, Peled M, Lewinson D. Characterization of midface maxillary membranous bone formation during distraction osteogenesis. *Plast Reconstr Surg* 2002;109:1611-20.
- Kanno T, Takahashi T, Tsujisawa T, Ariyoshi W, Nishihara T. Mechanical stress-mediated Runx2 activation is dependant on Ras/ERK1/2 MAPK signaling in osteoblasts. *J Cell Biochem* 2007;101:1266-77.
- Saito K, Ono T, Mochida M, Ohyama K. Changes in nasorespiratory function in association with maxillary distraction osteogenesis in subjects with cleft lip and palate. *Cleft Palate Craniofacial J* 2006;43:75-83.
- Swennen G, Schliephake H, Dempf R, Schierle H, Malevez C. Craniofacial distraction osteogenesis: a review of the literature. Part-I: clinical studies. *Int J Oral Maxillofac Surg* 2001;30:89-103.
- Baek SH, Lee JK, Lee JH, Kim MJ, Kim JR. Comparison of treatment outcome and stability between distraction osteogenesis and Le Fort I osteotomy in cleft patients with maxillary hypoplasia. *J Craniofac Surg* 2007;18:1209-15.
- Gateno J, Engel ER, Teichraeber JF, Yamaji KE, Xia JJ. A new Le Fort I internal distraction device in the treatment of severe maxillary hypoplasia. *J Oral Maxillofac Surg* 2005;63:148-54.
- Suzuki EY, Motohashi N, Ohyama K. Longitudinal dento-skeletal changes in UCLP patients following maxillary distraction osteogenesis using RED system. *J Med Dent Sci* 2004;51:27-33.
- Louis PJ, Waite PD, Austin RB. Long-term skeletal stability after rigid fixation of Le Fort I osteotomies with advancements. *Int J Oral Maxillofac Surg* 1993;22:82-6.
- Kusnoto B, Figueroa AA, Polley JW. Radiographic evaluation of bone formation in the pterygoid region after maxillary distraction with rigid external distraction (RED) device. *J Craniofac Surg* 2001;12:109-17; discussion 118.
- Kanno T, Takahashi T, Ariyoshi W, Tsujisawa T, Haga M, Nishihara T. Tensile mechanical strain up-regulates Runx2 and osteogenic factor expression in human periosteal cells: Implications for distraction osteogenesis. *J Oral Maxillofac Surg* 2005;63:499-504.

**How to cite this article:** Singh SP, Jena AK, Rattan V, Utreja AK. Treatment outcome and long-term stability of skeletal changes following maxillary distraction in adult subjects of cleft lip and palate. *Contemp Clin Dent* 2012;3:188-92.

**Source of Support:** Nil. **Conflict of Interest:** None declared.