



CASE REPORT

Case Report: The first probable Hong Kong Chinese case of *LPIN1*-related acute recurrent rhabdomyolysis in a boy with two novel variants [version 1; peer review: 2 approved]

Sau Wing Yim^{1,2}, Tina Yee Ching Chan³, Kiran M. Belaramani^{1,2}, Sze Shun Man^{1,2}, Felix Chi Kin Wong⁴, Sammy Pak Lam Chen^{3,5}, Hencher Han Chih Lee³, Chloe Miu Mak^{2,3}, Chor Kwan Ching³

¹Department of Paediatrics and Adolescent Medicine, Tuen Mun Hospital, Tuen Mun, Hong Kong

²Chemical Pathology Laboratory, Department of Pathology, Hong Kong Children's Hospital, Kowloon Bay, Hong Kong

³Kowloon West Cluster Laboratory Genetic Service, Chemical Pathology Laboratory, Department of Pathology, Princess Margaret Hospital, Hong Kong, Laichikok, Hong Kong

⁴Department of Chemical Pathology, Prince of Wales Hospital, Shatin, Hong Kong

⁵Chemical Pathology Laboratory, Department of Pathology, Queen Elizabeth Hospital, Kowloon, Hong Kong

v1 First published: 02 Sep 2019, 8:1566 (<https://doi.org/10.12688/f1000research.20343.1>)

Latest published: 02 Sep 2019, 8:1566 (<https://doi.org/10.12688/f1000research.20343.1>)

Abstract

Recurrent rhabdomyolysis is frequently ascribed to fatty acid β -oxidation defects, mitochondrial respiratory chain disorders and glycogen storage-related diseases. In recent years, autosomal recessive *LPIN1* mutations have been identified as a prevailing cause of severe rhabdomyolysis in children in Western countries. We report the first probable Hong Kong Chinese case of recurrent severe rhabdomyolysis in early childhood caused by *LPIN1* variants. Compound heterozygous novel variants

NM_145693.2(LPIN1):c.[1949_1967dupGTGTCACCACGCAGTACCA];[2410G>C] (p.[Gly657Cysfs*12];[Asp804His]) were detected. The former variant was classified as likely pathogenic while the latter variant was classified as a variant of uncertain significance (VUS) based on the guideline published by the American College of Medical Genetics and Genomics (ACMG) in 2015. Although the genetic findings were inconclusive, the patient's presentation was compatible with *LPIN1*-related acute recurrent rhabdomyolysis, and the patient was treated as such. The early recognition, timely diagnosis and management of this condition are important to avoid fatal consequences. To our knowledge, there has been no previous report in the English-language literature of a child with Chinese ethnicity and *LPIN1*-related acute recurrent rhabdomyolysis (MIM #268200). Functional characterization of the novel variants detected in this study are warranted in future studies.

Keywords

Hong Kong Chinese, *LPIN1*, Rhabdomyolysis, Novel variants

Open Peer Review

Reviewer Status

	Invited Reviewers	
	1	2
version 1 published 02 Sep 2019	 report	 report

1 **Michael F. Buckley**, Prince of Wales Hospital, Randwick, Australia

2 **Brian N. Finck** , Washington University in St. Louis, St Louis, USA

Any reports and responses or comments on the article can be found at the end of the article.

Corresponding author: Chor Kwan Ching (chingck2@ha.org.hk)

Author roles: **Yim SW:** Conceptualization, Investigation, Writing – Original Draft Preparation; **Chan TYC:** Writing – Original Draft Preparation; **Belaramani KM:** Investigation; **Man SS:** Investigation; **Wong FCK:** Writing – Review & Editing; **Chen SPL:** Supervision; **Lee HHC:** Supervision; **Mak CM:** Supervision; **Ching CK:** Conceptualization, Investigation, Methodology, Supervision, Writing – Review & Editing

Competing interests: No competing interests were disclosed.

Grant information: The author(s) declared that no grants were involved in supporting this work.

Copyright: © 2019 Yim SW *et al.* This is an open access article distributed under the terms of the [Creative Commons Attribution License](#), which permits unrestricted use, distribution, and reproduction in any medium, provided the original work is properly cited.

How to cite this article: Yim SW, Chan TYC, Belaramani KM *et al.* **Case Report: The first probable Hong Kong Chinese case of LPIN1-related acute recurrent rhabdomyolysis in a boy with two novel variants [version 1; peer review: 2 approved]** F1000Research 2019, **8**:1566 (<https://doi.org/10.12688/f1000research.20343.1>)

First published: 02 Sep 2019, **8**:1566 (<https://doi.org/10.12688/f1000research.20343.1>)

Introduction

Rhabdomyolysis is an uncommon but potentially fatal condition. It results from an acute muscle fiber breakdown resulting in the release of intracellular muscle constituents into the circulation. There are multiple causes for rhabdomyolysis. However, recurrent rhabdomyolysis is frequently attributed to metabolic myopathies. The differential diagnoses include fatty acid β -oxidation defects (FAOD), mitochondrial respiratory chain disorders and glycogen storage diseases. When initial investigations including biochemical metabolic work-up are unremarkable, muscle biopsies for histological and enzymatic studies are commonly performed. In recent years, autosomal recessive mutations in *LPIN1* are being increasingly recognized as an important cause of acute recurrent rhabdomyolysis in childhood in the Western population, after the exclusion of FAOD, mitochondrial respiratory chain disorders and glycogen storage diseases. Lipin 1 (LPIN1), encoded by *LPIN1* gene, belongs to the LPIN gene family which also include *LPIN2* and *LPIN3*. Lipin 1 is predominantly expressed in skeletal muscle and adipose tissue¹⁻³. Among lipins 1, 2 and 3, lipin 1 is the only lipin which is expressed significantly in muscles^{2,4}. Lipin 1 is a Mg^{2+} -dependent phosphatidic acid phosphohydrolase (PAP) that catalyzes the dephosphorylation of phosphatidic acid to yield diacylglycerol and inorganic phosphate⁵. It has also been found to exert transcriptional co-regulator activity^{6,7}. The human *LPIN1* gene is mapped to chromosome 2p25.1 and contains 20 exons. Apart from acute recurrent rhabdomyolysis, *LPIN1* variants have also been found in adults with statin-induced myopathy, metabolic syndrome and type 2 diabetes mellitus⁸⁻¹¹. We hereby report the first probable Hong Kong Chinese case of acute recurrent rhabdomyolysis in a boy with compound heterozygous *LPIN1* variants who presented with recurrent rhabdomyolysis since the age of 15 months.

Case report

A 15-month-old boy was brought to the hospital complaining of coryzal symptoms for three days, and dyspnea and fever for one day. He was seen by a general practitioner a day prior to the admission and was given an intramuscular injection of an uncertain drug for his illness. After the injection, he complained of passing dark-colored urine twice. Physical examination showed good perfusion and the patient's blood pressure was 113/65 mmHg. His body weight and height were at the 75th percentile and 50th percentile, respectively, for his age and sex. Respiratory examination revealed bilateral wheezes and the initial impression was acute bronchiolitis. Creatine kinase (CK) was markedly elevated to 127,494 U/L (reference interval: 39–308 U/L). Urine dipstick was positive for hemoglobin. After centrifugation of the urine through a 30 kDa microconcentrator membrane, urine dipstick for hemoglobin remained positive, confirming that the positive urine dipstick result without ultrafiltration was likely due to the presence of myoglobin, which cross-reacts with the peroxidase reaction employed by the urine dipstick for hemoglobin testing. Plasma creatinine and potassium were normal. Liver function tests revealed an elevated alanine aminotransferase (ALT) of 658 U/L (reference interval: 9–25 U/L) on the first day of admission; the value peaked on the second day of admission with a reading of 1,418 U/L. Apart from CK, lactate dehydrogenase (LDH) level

was also raised to 9,154 U/L (reference interval: <350 U/L) and it peaked on the second day of admission at a value of 11,409 U/L. Cardiac troponin-I level was normal and electrocardiogram (ECG) did not show any abnormalities. A diagnosis of rhabdomyolysis was made.

Intravenous fluid was given in view of poor appetite and later tapered off as diet was better tolerated. CK came down to 10,909 U/L on the fourth day of admission. The boy had good urine output and there was no more passage of dark-colored urine since day three of the admission. Nasopharyngeal swab taken during admission was positive for respiratory syncytial virus. Dyspnea gradually resolved. On day five of illness, the CK, ALT and LDH had markedly improved. Repeated urine myoglobin and hemoglobin testing were negative. He was followed up two weeks later and was well then. There was no more passage of dark-colored urine.

Thereafter, he defaulted follow up and presented to us again at six years of age. This time, he complained of bilateral calf pain with antalgic gait associated with coryzal symptoms and fever. The episode was not preceded by any injuries nor excessive exercises. There was also no preceding administration of any intramuscular injection. Upon detailed history taking, the patient revealed that he frequently got muscle cramps after exercise. There was no family history of recurrent rhabdomyolysis, malignant hyperthermia or musculoskeletal diseases. The parents were both Chinese and non-consanguineous.

Physical examination revealed bilateral calf tenderness in the absence of weakness. There was no associated hepatosplenomegaly. He was well built with a weight and height at the 50th and 75th percentile, respectively, for his age and sex. Investigations during this admission again revealed an elevated CK (27,442 U/L), LDH (658 U/L) and ALT (138 U/L). Urine for myoglobin and hemoglobin (analyzed by same methods as before) were both positive. Plasma creatinine and potassium were normal. Hydration was instituted and the CK levels normalized 10 days later. Due to the recurrent episodes of rhabdomyolysis, further investigations were undertaken including blood gas, plasma lactate and ammonia but they were all unremarkable. Metabolic screening was performed and showed a normal pattern of plasma amino acids, serum acylcarnitine profile and urine organic acid profile. Genetic analysis of all coding exons of *LPIN1* reviewed two heterozygous novel mutations: NM_145693.2(LPIN1):c.[1949_1967dupGTGTCACCACGCAGTACCA]; [2410G>C] (p.[Gly657Cysfs*12];[Asp804His]) (Figure 1). The parents also underwent genetic tests for *LPIN1*. Each of the parents was a heterozygous carrier of one of the patient's variants, which confirmed compound heterozygosity of the variants in the patient. The former variant was classified as likely pathogenic while the latter variant was classified as a variant of uncertain significance (VUS). Although the genetic findings were inconclusive, the patient's clinical presentation was compatible with LPIN1-related acute recurrent rhabdomyolysis, and muscle biopsy was not done.

In spite of the uncertainty in the genetic findings, the likely diagnosis of LPIN-related acute recurrent rhabdomyolysis

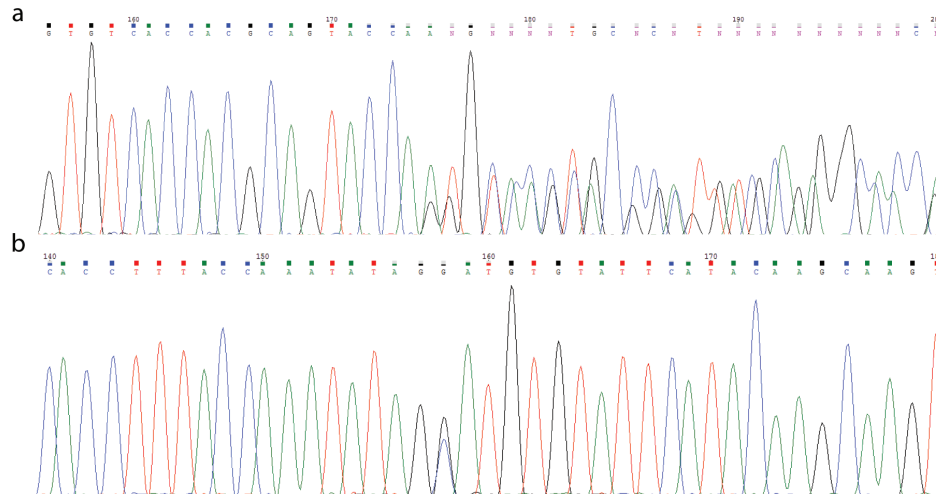


Figure 1. Electrophoretograms of the two novel *LPINI* variants. (a) NM_145693.2(*LPINI*):c.[1949_1967dupGTGTCACCACGCAGTACCA] p.[Gly657Cysfs*12]. (b) NM_145693.2(*LPINI*):c.[2410G>C] p.[Asp804His].

was conveyed to the family with proper genetic counseling conducted. Advice to avoid recurrent episodes of rhabdomyolysis, which include limiting strenuous exercise, ample hydration during exercise and prompt medical consultation in case of myalgia, was given. One year after the genetic diagnosis, he has been growing well and did not complain of passing any dark-colored urine, even during febrile illness.

The parents decided to have another baby and opted not for prenatal testing for *LPINI* variants. Prenatal testing carries intrinsic risk to the fetus and, in our opinion, is not recommended for this disease which is amendable to treatment and not debilitating. Post-natal genetic test on the younger sister confirmed that she also carried the two familial heterozygous variants; upon this finding, counselling was given to the parents.

Discussion

LPINI mutations resulting in recurrent rhabdomyolysis was first described in three patients by Zeharia *et al.* in 2008¹². In less than a decade since it was first described, there has been an increasing evidence in the literature that *LPINI* mutations are one of the most frequent causes of recurrent rhabdomyolysis in childhood. Michot *et al.* reported that after excluding primary fatty acid oxidation disorders, recessive *LPINI* gene mutations were found in 59% of the patients who exhibited severe recurrent rhabdomyolysis in childhood. The male to female ratio was reported to be 0.89. Out of the 17 cases described by Michot *et al.*, more than half of them were Caucasian and the others were of African, Asian (Vietnamese) and Maghrebi ethnicity¹³. Due to its relative novelty, the prevalence of the disease is still unknown. To our knowledge, there has been no previous report in the English-language literature of a child with Chinese ethnicity and *LPINI*-related acute recurrent rhabdomyolysis (MIM #268200).

The pathophysiology of *LPINI*-related recurrent rhabdomyolysis is not fully understood. Accumulation of lipid droplets is a

common finding in muscle biopsy¹⁴. The loss of PAP enzymatic activity, rather than a loss in transcription co-regulator activity, plays a major role in the pathogenesis of this disease as the loss of the PAP activity alone without a loss in transcription co-regulator activity was sufficient to cause rhabdomyolysis¹⁵. Apart from the PAP activity responsible for triacylglycerol and phospholipid biosynthesis, it also serves as a transcriptional co-activator together with peroxisome proliferator activated receptor coactivator-1 α (*PPARA*) and peroxisome proliferator activated receptor gamma coactivator-1 alpha (*PGC-1 α*) to regulate genes encoding fatty acid oxidation and respiratory chain enzymes^{6,7}. Multiple genes are either up-regulated or down-regulated in myoblasts of lipin-1-deficient patients¹⁶. Furthermore, various inflammatory inducers including lipopolysaccharides, zymosan and proinflammatory cytokines have been shown to repress *LPINI* expression in adipose tissue and muscular tissue^{17,18}. Inflammatory inducers are usually produced when the body is under catabolic stress and the resulting suppressed lipin 1 activity may lead to rhabdomyolysis. This hypothesis might explain the fact that the majority of the severe episodes are associated with catabolic states such as a preceding illness¹³. Lipin 1 was also found to play a role in autophagy of mitochondria as PAP activity is required for the maturation of autolysosomes and lipin 1 deficiency leads to accumulation of aberrant mitochondria¹⁹. This may explain the finding of mitochondrial aggregates on ultrastructural examination of muscle tissue in some patients¹⁴. Sarcoplasmic reticulum stress response was recently identified to be an important player in the pathogenesis of this disease by contributing to catastrophic *de novo* lipogenesis of both phospholipids and neutral lipids²⁰.

Disease-causing *LPINI* mutations are scattered throughout the coding region¹⁴. An intragenic deletion (c.2295-863_2410-27del) is frequently seen in Caucasian patients, possibly representing a founder effect^{13,14}. In our patient, two heterozygous novel variants of *LPINI* gene are detected: the

19-nucleotide duplication NM_145693.2(*LPINI*):c.[1949_1967dupGTGTACCACGCAGTACCA] (p.[Gly657Cysfs*12]) causes a frameshift with a premature termination codon and hence has deleterious effect; the novel missense variant, NM_145693.2(*LPINI*):c.[2410G>C] (p.[Asp804His]), is found in the highly conserved LNS2 (Lipin/Ned1/Smp2) domain near the C terminus of lipin 1, which contains an important Mg²⁺-dependent catalytic site responsible for the PAP activity²¹. This amino acid residue is highly conserved. The variant is predicted to be deleterious (SIFT), damaging (PROVEAN) and probably damaging (Polyphen-2) by *in silico* analyses. At the time of reporting, both variants are absent from controls in the Exome Sequencing Project, 1000 Genomes Project, Exome Aggregation Consortium and Genome Aggregation databases. NM_145693.2(*LPINI*):c.[1949_1967dupGTGTACCACGCAGTACCA] (p.[Gly657Cysfs*12]) was classified as a likely pathogenic variant (Criteria: PVS1 and PM2) and NM_145693.2(*LPINI*):c.[2410G>C] (p.[Asp804His]) was classified as a variant of uncertain significance (VUS)(Criteria: PM2, PM3 and PP3) based on the American College of Medical Genetics and Genomics (ACMG) guideline published in 2015²². Functional characterization of the two detected variants is warranted to confirm their pathogenicity.

All patients with *LPINI* mutations present with recurrent rhabdomyolysis triggered by febrile illness, prolonged fasting or anesthesia^{12,13}. Michot *et al.* reviewed 29 cases with recurrent rhabdomyolysis, in which 17 patients were confirmed to harbor *LPINI* mutations. For the patients who harbor *LPINI* mutations, the first episodes of rhabdomyolysis occurred before the age of five years. The mean age of presentation was 21 months old and the earliest age of presentation was at five months of age. The number of recurrent episodes ranged from one to ten per patient¹³. Our patient presented at 15 months of age and has so far experienced two episodes of rhabdomyolysis. As more than 50% of patients with recurrent rhabdomyolysis were found to have *LPINI* mutations after exclusion of FAOD¹³, genetic testing for *LPINI* mutations should be performed prior to muscle biopsy if metabolic investigations are unremarkable. Muscle biopsy is an invasive procedure and require general anesthesia which may trigger rhabdomyolysis.

Michot *et al.* also noted that among the 29 cases of unexplained rhabdomyolysis they studied, all cases eventually confirmed to have *LPINI* mutations had a CK level of >10,000 U/L¹³. In our patient, the CK levels were 127,494 U/L and 27,442 U/L during the first and second episodes of rhabdomyolysis, respectively. This is in line with Michot's findings. Therefore, one should be vigilant to look for *LPINI* mutations in any young children presenting with rhabdomyolysis with a CK level of >10,000 U/L.

The management of rhabdomyolysis is mostly supportive by providing aggressive fluid replacement therapy to protect the renal function. Besides, close monitoring is also indispensable during fasting and anesthesia. As rhabdomyolysis episodes could be fatal, prevention of such events is of utmost importance. Parents should be well educated on the symptoms and precipitating factors of rhabdomyolysis. They should also be given an

action plan when the child exhibits muscle pain or fever. In our case, proper education of the parents at diagnosis has helped in preventing further episodes of rhabdomyolysis. In a group of five patients with biallelic *LPIN* mutations, Pichler *et al.* proposed that high-caloric intake at periods of stress and intravenous glucose during episodes of rhabdomyolysis may decrease the number of rhabdomyolysis episodes and the duration of each episode by preventing catabolism²². Further studies are required to confirm the efficacy and safety of this approach.

For *LPINI*-related acute recurrent rhabdomyolysis, it was reported that mortality was as high as 30% during an acute episode of severe rhabdomyolysis¹⁴. Between episodes, these patients thrived well. Intellectual disability was reported in one case at the age of nine years¹². Our patient has been normal between the episodes apart from frequent muscle cramps after exercise and there is no evidence of intellectual disability. However, further observation is needed in view of the young age of our patient. The long-term prognosis of this condition has been reported in a 25-year-old female with *LPINI*-related recurrent rhabdomyolysis, who had bilateral common peroneal neuropathies in addition to a background residual distal myopathy detected one year following discharge from intensive care. It was uncertain whether the neuropathies were a result of critical illness, compression and/or severe weight loss during the admission or intrinsic to the underlying genetic lipin 1 deficiency²³.

Genetic confirmation of *LPINI* mutations not only helps the patient but also their family members. In our case, the younger sister had genetic testing done soon after birth. This has raised the parents' awareness of the disease and its preventive measures. The younger sister has been growing well and has had no episodes of rhabdomyolysis at the time of reporting at one year of age.

Conclusion

This is the first probable reported case of *LPINI*-related rhabdomyolysis in the Hong Kong Chinese population. It has been shown that *LPINI*-related rhabdomyolysis is a major cause of severe rhabdomyolysis in early childhood so we should be vigilant of this condition. Screening for *LPINI* mutations should be undertaken at an early stage in the work up of childhood rhabdomyolysis. As rhabdomyolysis in children has a high mortality rate, early recognition of the symptoms, timely diagnosis and proactive management are essential. Regarding prognosis, more observations and longitudinal studies are warranted to determine the long-term outcomes of this condition.

Data availability

NCBI ClinVar: NM_145693.2(*LPINI*):c.[1949_1967dupGTGTACCACGCAGTACCA] (p.[Gly657Cysfs*12]). Accession number [SCV000965694](#).

NCBI ClinVar: NM_145693.2(*LPINI*):c.[2410G>C] (p.[Asp804His]). Accession number [SCV000965695](#).

Consent

Written informed consent for publication of the clinical details was obtained from the parents of the patient.

References

1. Péterfy M, Phan J, Xu P, *et al.*: **Lipodystrophy in the *fld* mouse results from mutation of a new gene encoding a nuclear protein, lipin.** *Nat Genet.* 2001; **27**(1): 121–124.
[PubMed Abstract](#) | [Publisher Full Text](#)
2. Donkor J, Sariyahmetoglu M, Dewald J, *et al.*: **Three mammalian lipins act as phosphatidate phosphatases with distinct tissue expression patterns.** *J Biol Chem.* 2007; **282**(6): 3450–3457.
[PubMed Abstract](#) | [Publisher Full Text](#)
3. Donkor J, Zhang P, Wong S, *et al.*: **A conserved serine residue is required for the phosphatidate phosphatase activity but not the transcriptional coactivator functions of lipin-1 and lipin-2.** *J Biol Chem.* 2009; **284**(43): 29968–29978.
[PubMed Abstract](#) | [Publisher Full Text](#) | [Free Full Text](#)
4. Melé M, Ferreira PG, Reverter F, *et al.*: **Human genomics. The human transcriptome across tissues and individuals.** *Science.* 2015; **348**(6235): 660–665.
[PubMed Abstract](#) | [Publisher Full Text](#) | [Free Full Text](#)
5. Han GS, Wu WI, Carman GM: **The *Saccharomyces cerevisiae* Lipin homolog is a Mg²⁺-dependent phosphatidate phosphatase enzyme.** *J Biol Chem.* 2006; **281**(14): 9210–9218.
[PubMed Abstract](#) | [Publisher Full Text](#) | [Free Full Text](#)
6. Finck BN, Gropler MC, Chen Z, *et al.*: **Lipin 1 is an inducible amplifier of the hepatic PGC-1alpha/PPARalpha regulatory pathway.** *Cell Metab.* 2006; **4**(3): 199–210.
[PubMed Abstract](#) | [Publisher Full Text](#)
7. Zhang P, Takeuchi K, Csaki LS, *et al.*: **Lipin-1 phosphatidic phosphatase activity modulates phosphatidate levels to promote peroxisome proliferator-activated receptor γ (PPAR γ) gene expression during adipogenesis.** *J Biol Chem.* 2012; **287**(5): 3485–3494.
[PubMed Abstract](#) | [Publisher Full Text](#) | [Free Full Text](#)
8. Zhang R, Jiang F, Hu C, *et al.*: **Genetic variants of *LPIN1* indicate an association with Type 2 diabetes mellitus in a Chinese population.** *Diabet Med.* 2013; **30**(1): 118–122.
[PubMed Abstract](#) | [Publisher Full Text](#)
9. Loos RJ, Rankinen T, Pérusse L, *et al.*: **Association of *lipin 1* gene polymorphisms with measures of energy and glucose metabolism.** *Obesity (Silver Spring).* 2007; **15**(11): 2723–2732.
[PubMed Abstract](#) | [Publisher Full Text](#)
10. Wiedmann S, Fischer M, Koehler M, *et al.*: **Genetic variants within the *LPIN1* gene, encoding lipin, are influencing phenotypes of the metabolic syndrome in humans.** *Diabetes.* 2008; **57**(1): 209–217.
[PubMed Abstract](#) | [Publisher Full Text](#)
11. Fawcett KA, Grimsey N, Loos RJ, *et al.*: **Evaluating the role of *LPIN1* variation in insulin resistance, body weight, and human lipodystrophy in U.K. Populations.** *Diabetes.* 2008; **57**(9): 2527–2533.
[PubMed Abstract](#) | [Publisher Full Text](#) | [Free Full Text](#)
12. Zeharia A, Shaag A, Houtkooper RH, *et al.*: **Mutations in *LPIN1* cause recurrent acute myoglobinuria in childhood.** *Am J Hum Genet.* 2008; **83**(4): 489–494.
[PubMed Abstract](#) | [Publisher Full Text](#) | [Free Full Text](#)
13. Michot C, Hubert L, Brivet M, *et al.*: ***LPIN1* gene mutations: a major cause of severe rhabdomyolysis in early childhood.** *Hum Mutat.* 2010; **31**(7): E1564–1573.
[PubMed Abstract](#) | [Publisher Full Text](#)
14. Michot C, Hubert L, Romero NB, *et al.*: **Study of *LPIN1*, *LPIN2* and *LPIN3* in rhabdomyolysis and exercise-induced myalgia.** *J Inherit Metab Dis.* 2012; **35**(6): 1119–1128.
[PubMed Abstract](#) | [Publisher Full Text](#)
15. Schweitzer GG, Collier SL, Chen Z, *et al.*: **Rhabdomyolysis-Associated Mutations in Human *LPIN1* Lead to Loss of Phosphatidic Acid Phosphohydrolase Activity.** *JIMD Rep.* 2015; **23**: 113–122.
[PubMed Abstract](#) | [Publisher Full Text](#) | [Free Full Text](#)
16. Michot C, Mamoune A, Vamecq J, *et al.*: **Combination of lipid metabolism alterations and their sensitivity to inflammatory cytokines decrease lipin-1-deficient myoblasts.** *Biochim Biophys Acta.* 2013; **1832**(12): 2103–2114.
[PubMed Abstract](#) | [Publisher Full Text](#) | [Free Full Text](#)
17. Feingold KR, Moser A, Patzek SM, *et al.*: **Infection decreases fatty acid oxidation and nuclear hormone receptors in the diaphragm.** *J Lipid Res.* 2009; **50**(10): 2055–2063.
[PubMed Abstract](#) | [Publisher Full Text](#) | [Free Full Text](#)
18. Lu B, Lu Y, Moser AH, *et al.*: **LPS and proinflammatory cytokines decrease lipin-1 in mouse adipose tissue and 3T3-L1 adipocytes.** *Am J Physiol Endocrinol Metab.* 2008; **295**(6): E1502–E1509.
[PubMed Abstract](#) | [Publisher Full Text](#) | [Free Full Text](#)
19. Zhang P, Verity MA, Reue K: **Lipin-1 regulates autophagy clearance and intersects with statin drug effects in skeletal muscle.** *Cell Metab.* 2014; **20**(2): 267–279.
[PubMed Abstract](#) | [Publisher Full Text](#) | [Free Full Text](#)
20. Rashid T, Nemazany I, Paolini C, *et al.*: **Lipin1 deficiency causes sarcoplasmic reticulum stress and chaperone-responsive myopathy.** *EMBO J.* 2019; **38**(1): pii: e99576.
[PubMed Abstract](#) | [Publisher Full Text](#) | [Free Full Text](#)
21. Burroughs AM, Allen KN, Dunaway-Mariano D, *et al.*: **Evolutionary genomics of the HAD superfamily: understanding the structural adaptations and catalytic diversity in a superfamily of phosphoesterases and allied enzymes.** *J Mol Biol.* 2006; **361**(5): 1003–1034.
[PubMed Abstract](#) | [Publisher Full Text](#)
22. Pichler K, Scholl-Buergi S, Birnbacher R, *et al.*: **A novel therapeutic approach for *LPIN1* mutation-associated rhabdomyolysis--The Austrian experience.** *Muscle Nerve.* 2015; **52**(3): 437–439.
[PubMed Abstract](#) | [Publisher Full Text](#)
23. Stepien KM, Schmidt WM, Bittner RE, *et al.*: **Long-term outcomes in a 25-year-old female affected with lipin-1 deficiency.** *JIMD Rep.* 2019; **46**(1): 4–10.
[PubMed Abstract](#) | [Free Full Text](#)

Open Peer Review

Current Peer Review Status:  

Version 1

Reviewer Report 31 October 2019

<https://doi.org/10.5256/f1000research.22354.r54678>

© 2019 Finck B. This is an open access peer review report distributed under the terms of the [Creative Commons Attribution License](#), which permits unrestricted use, distribution, and reproduction in any medium, provided the original work is properly cited.



Brian N. Finck 

Washington University in St. Louis, St Louis, MI, USA

Lipin 1 plays important roles in regulating intermediary metabolism by acting as a lipid phosphatase to synthesize diacylglycerol from phosphatidic acid. This is an important step in glycerolipid synthesis and a metabolic branch point. Mutations in lipin 1 in people lead to severe, recurrent rhabdomyolysis that can be debilitating or fatal. While these mutations are rare in the general population, they account for a significant proportion of acute paediatric rhabdomyolysis cases. In this case report, Yim and colleagues detail the identification of novel mutations in LPIN1 that are associated with rhabdomyolysis in a boy in Hong Kong. The report is well done and complete. The authors have done a good job of detailing the important literature on the topic. No changes are requested.

Is the background of the case's history and progression described in sufficient detail?

No

Are enough details provided of any physical examination and diagnostic tests, treatment given and outcomes?

Yes

Is sufficient discussion included of the importance of the findings and their relevance to future understanding of disease processes, diagnosis or treatment?

Yes

Is the case presented with sufficient detail to be useful for other practitioners?

Yes

Competing Interests: No competing interests were disclosed.

Reviewer Expertise: Intermediary metabolism

I confirm that I have read this submission and believe that I have an appropriate level of expertise to confirm that it is of an acceptable scientific standard.

Reviewer Report 16 September 2019

<https://doi.org/10.5256/f1000research.22354.r53286>

© 2019 Buckley M. This is an open access peer review report distributed under the terms of the [Creative Commons Attribution License](#), which permits unrestricted use, distribution, and reproduction in any medium, provided the original work is properly cited.



Michael F. Buckley

New South Wales Health Pathology, Prince of Wales Hospital, Randwick, NSW, Australia

This is the initial description of compound heterozygous variants in *LPIN1* as a cause of rhabdomyolysis in a person of Chinese ethnicity.

The sequencing data provided is robust, the nomenclature used is correct and the ACMG classification for the missense change is conservative.

There is little in the way of improvements to the manuscript that I could suggest. The categorical statement "The human *LPIN1* gene is mapped to chromosome 2p25.1 and contains 20 exons" isn't correct as this gene has multiple transcription isoforms with different numbers and combinations of exons. The isoform used in this discussion certainly has 20 exons but other isoforms range up to 22 exons.

Is the background of the case's history and progression described in sufficient detail?

Yes

Are enough details provided of any physical examination and diagnostic tests, treatment given and outcomes?

Yes

Is sufficient discussion included of the importance of the findings and their relevance to future understanding of disease processes, diagnosis or treatment?

Yes

Is the case presented with sufficient detail to be useful for other practitioners?

Yes

Competing Interests: No competing interests were disclosed.

Reviewer Expertise: Clinical genomics.

I confirm that I have read this submission and believe that I have an appropriate level of expertise to confirm that it is of an acceptable scientific standard.

The benefits of publishing with F1000Research:

- Your article is published within days, with no editorial bias
- You can publish traditional articles, null/negative results, case reports, data notes and more
- The peer review process is transparent and collaborative
- Your article is indexed in PubMed after passing peer review
- Dedicated customer support at every stage

For pre-submission enquiries, contact research@f1000.com

F1000Research