

Incidence and Clinical Impact of Stent Fracture After the Nobori Biolimus-Eluting Stent Implantation

Shoichi Kuramitsu, MD; Masashi Iwabuchi, MD; Hiroyoshi Yokoi, MD; Takenori Domei, MD; Shinjo Sonoda, MD; Takashi Hiromasa, MD; Takashi Morinaga, MD; Yohei Kobayashi, MD; Kensuke Ohe, MD; Kaoru Goya, MD; Kyohei Yamaji, MD; Makoto Hyodo, MD; Yoshimitsu Soga, MD; Katsuhiko Kondo, MD; Shinichi Shirai, MD; Kenji Ando, MD; Koyu Sakai, MD; Masakiyo Nobuyoshi, MD

Background—Stent fracture (SF) after drug-eluting stent implantation has become an important concern. The aim of this study was to assess the incidence, predictors, and clinical impact of SF after biolimus-eluting stent.

Methods and Results—A total of 1026 patients with 1407 lesions undergoing the Nobori biolimus-eluting stent implantation and follow-up angiography within 9 months after index procedure were analyzed. SF was defined as complete or partial separation of the stent, as assessed by using plain fluoroscopy, intravascular ultrasound, or optical coherence tomography during the follow-up. We assessed the rate of SF and the cumulative incidence of clinically driven target lesion revascularization and definite stent thrombosis within 9 months. SF was observed in 58 (4.1%) of 1407 lesions and 57 (5.5%) of 1026 patients. Lesions with hinge motion (OR 8.90, 95% CI 3.84 to 20.6, $P<0.001$), tortuosity (OR 4.16, 95% CI 1.75 to 9.88, $P=0.001$), and overlapping stents (OR 2.41, 95% CI 0.95 to 6.10, $P=0.06$) were predictors of SF. Cumulative incidence of clinically driven target lesion revascularization within 9 months was numerically higher in the SF group than that in the non-SF group (12.0% versus 1.0%). Cumulative incidence of definite stent thrombosis within 9 months tended to be higher in the SF group than that in the non-SF group (1.7% versus 0.5%).

Conclusions—SF after biolimus-eluting stent occurs in 4.1% of lesions and appears to be associated with clinically driven target lesion revascularization. (*J Am Heart Assoc.* 2014;3:e000703 doi: 10.1161/JAHA.113.000703)

Key Words: biolimus-eluting stent • drug-eluting stent fracture • in-stent restenosis • percutaneous coronary intervention

Drug-eluting stents (DES) have dramatically reduced the rates of in-stent restenosis (ISR) and subsequent target lesion revascularization (TLR) compared with bare-metal stents.^{1,2} However, widespread use of first-generation DES has drawn attention to several unresolved, clinically relevant issues. Particular concerns have been raised about the risks of DES, especially stent thrombosis (ST).^{3,4} Stent fracture (SF) after DES implantation has become an important concern because of its potential association with ISR, TLR, and ST.⁵ The incidence of SF in a clinical setting has been reported to be 0.84% to 8.4% in first-generation DES.^{6,7} In particular,

sirolimus-eluting stent (SES) is more likely to cause SF due to the closed-cell design and being made of stainless steel with low flexibility and conformability.⁸ The cobalt chromium everolimus-eluting stent (CoCr-EES) is a second-generation DES and features a thin-strut, flexible, cobalt-chromium platform.⁹ We previously reported SF after CoCr-EES implantation occurs in 2.9% of lesions, and it is associated with higher rate of major adverse cardiac events (MACE), driven by higher TLR and ST.¹⁰ Therefore, SF remains an unresolved, clinically relevant issue, even in the newer-generation DES era.

The Nobori Biolimus-eluting stent (BES) (Terumo, Tokyo, Japan) is a newer-generation DES that consists of stainless steel platform with relatively thick strut (120 μm) using an albumin-coated biodegradable polymer (polylactic acid) eluting biolimus A9, a highly lipophilic analogue of sirolimus. Recent pivotal clinical trials showed that clinical outcome after biodegradable polymer BES implantation was noninferior to that after biocompatible durable polymer EES.^{11,12} Furthermore, the NOBORI 2 study demonstrated the good and sustained clinical performance of Nobori BES in high-risk patients with significant comorbidities and complex lesions.¹³ However, the incidence and clinical impact of SF after the Nobori BES implantation in clinical practice remain unclear. The aim of the present study

From the Department of Cardiology, Kokura Memorial Hospital, Kitakyushu, Japan (S.K., M.I., H.Y., T.D., T.H., T.M., Y.K., K.O., K.G., K.Y., M.H., Y.S., K.K., S. Shirai, K.A., K.S., M.N.); Second Department of Internal Medicine, University of Occupational and Environmental Health Japan School of Medicine, Kitakyushu, Japan (S. Sonoda).

Correspondence to: Shoichi Kuramitsu, MD, Department of Cardiology, Kokura Memorial Hospital, 3-2-1 Asano, Kokurakita-ku, Kitakyushu, 802-8555, Japan. E-mail: kuramitsu@circulation.jp

Received December 11, 2013; accepted January 30, 2014.

© 2014 The Authors. Published on behalf of the American Heart Association, Inc., by Wiley Blackwell. This is an open access article under the terms of the Creative Commons Attribution-NonCommercial License, which permits use, distribution and reproduction in any medium, provided the original work is properly cited and is not used for commercial purposes.

was to assess the incidence and clinical impact of SF after the Nobori BES implantation.

Methods

Patient Population and Procedural Protocol

From May 2011 to June 2012, 1691 consecutive patients with 2313 lesions underwent successful stent implantation, and 1270 patients with 1702 lesions were treated with only BES (Nobori) at Kokura Memorial Hospital. Of these, 1026 (80.7%) patients with 1407 lesions who underwent follow-up angiography 6 to 9 months after the initial procedure, regardless of clinical symptoms, or before 6 months for recurrent symptoms, were enrolled in this study (Figure 1). All interventions were performed using standard techniques. Predilatation, postdilatation, and use of intravascular ultrasound (IVUS) were left to the operator's discretion. After the procedure, all patients were advised to continue on aspirin (81 to 162 mg daily) for life unless there were contraindications. Either ticlopidine (200 mg daily) or clopidogrel (75 mg daily) was also prescribed for at least 1 year after stent implantation. All the study patients gave written informed consent for the procedure and the follow-up protocol, which was approved by the institutional review board of Kokura Memorial Hospital.

Quantitative Angiographic Analysis

Coronary angiography was performed after the intracoronary administration of 0.2 mg nitroglycerin. Quantitative coronary angiographic analysis was performed before and after stenting and during the follow-up angiography, using a guiding catheter to calibrate the magnification and a validated automated edge detection algorithm (CASS 5.7, Pie Medical Imaging). The analyses were performed independently by 2

experienced observers (Miho Hasegawa and Shinobu Matsumoto of the Angiographic Core Laboratory, Kokura Memorial Hospital) blinded to the clinical information. The target lesion for measurement of the minimal luminal diameter included 5-mm margins proximal and distal to the stent as well as the stent itself. ISR was defined as a percent diameter stenosis of >50% within the stent at the time of follow-up. In-segment restenosis was defined as a percent diameter stenosis of >50% either within the stented segment or within the 5 mm proximal or distal to the stent segment. The angiographic ISR patterns were classified as focal or diffuse according to Mehran's classification.¹⁴ A hinge motion lesion was defined as having $\geq 16^\circ$ difference in angle between diastole and systole before the procedure.¹⁵

Study End Point and Definitions

The study primary end point was the incidence of SF within 9 months after BES implantation. The secondary end point was the cumulative incidence of overall TLR, clinically driven TLR, and definite stent thrombosis ST within 9 months. A clinically driven TLR was defined as treatment for recurrent angina pectoris before scheduled follow-up angiography. Overall TLR was defined as clinically driven TLR and a >70% diameter stenosis on follow-up angiography in the presence of signs or symptoms of myocardial ischemia. The timing and diagnostic certainty of ST were assessed according to the Academic Research Consortium definition.¹⁶

SF was defined as complete or partial separation of stent segments observed by using plain fluoroscopy without contrast injection, intravascular ultrasound (IVUS), or optical coherence tomography (OCT) at follow-up angiography.⁶ The angiographic diagnosis of SF required an independent view and the agreement of 2 independent cardiologists (T.H. and T.M.). Angiographic SF was classified as follows: type 1 (partial separation), type 2 (complete separation without displacement), or type 3a and 3b (complete separation with displacement) (Figure 2). Diagnosis of SF by IVUS or OCT required careful review of the IVUS or OCT images and the agreement of 2 independent cardiologists (T.D. and M.H.). SF observed by

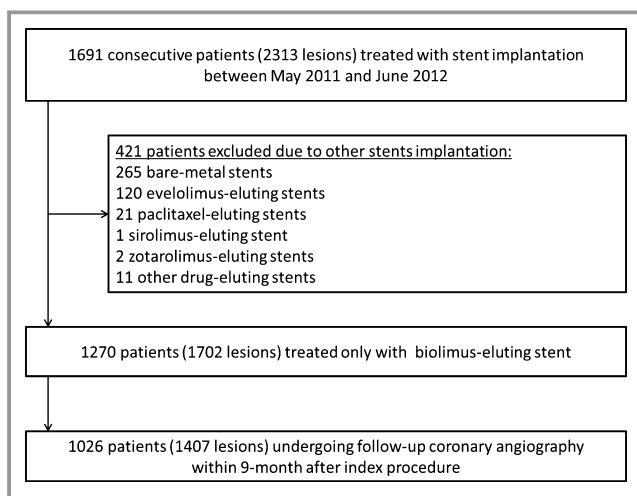


Figure 1. Study flow chart.

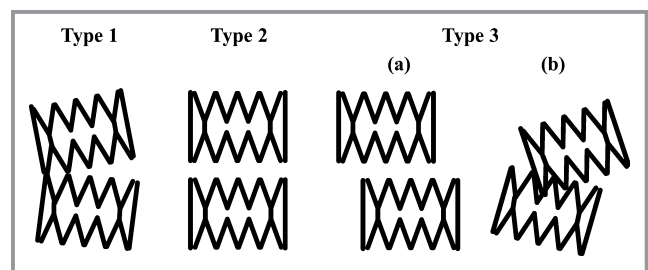


Figure 2. Angiographic classification of stent fracture. Type 1 indicates partial separation; type 2, complete separation without displacement; type 3a and 3b, complete separation with displacement.

using IVUS and OCT was classified as complete (complete separation of the stent into ≥ 2 pieces separated by image slices with no visible struts) or partial (the absence of struts over half or more of the stent circumference).

Statistical Analysis

Statistical analysis was performed using JMP version 10.0.2 and SAS version 9.1.3 (SAS Institute Inc). Data are presented as values and percentages, mean \pm SD, or median (IQR). Categorical variables were compared between groups with use of the χ^2 test or Fisher's exact test, as appropriate. Continuous variables were compared between groups using the Student's unpaired *t* test or the Mann–Whitney *U* test, based on the distribution. Multivariable logistic regression analysis was used for the lesion-based analysis of the risk factors for SF. The final model was constructed using the following 6 variables with $P < 0.05$ in the univariate analysis: calcification, tortuosity, hinge motion, overlapping stents, right coronary artery, and total stent length (per 10-mm increase). To account for the clustered nature of lesion characteristics within patients, generalized estimating equations were used for unadjusted and multivariable analyses of lesion-level data. Cumulative incidence of overall TLR, clinically driven TLR, and ST within 9 months between lesions with SF and those without SF was estimated by using the Kaplan–Meier method. Because of the small number of events in the SF and non-SF groups, statistical comparisons were not conducted for the cumulative event rates. A 2-sided probability value of < 0.05 was considered statistically significant.

Results

Coronary angiography was performed 192 days (IQR 183 to 223 days) after the index procedure. Baseline characteristics of the 1026 patients with follow-up angiography included in this study were not significantly different from those of the 176 patients without angiography except for age (70.3 ± 9.8 versus 74.1 ± 11.7 years, $P < 0.001$) and previous stroke (8.4% versus 15.4%, $P = 0.003$). At follow-up, SF after BES implantation was recognized in 58 (4.1%) of 1407 lesions and in 57 (5.5%) of 1026 patients. In the 48 (82.8%) of 58 lesions, SF was found at a single point, whereas SF occurred in ≥ 2 points per lesion in 10 (17.2%) lesions. As a result, a total of 71 fractures in 58 lesions were observed.

Clinical Characteristics

The baseline clinical characteristics of the SF and non-SF groups are shown in Table 1. There were no significant differences between the 2 groups.

Angiographic and Procedural Characteristics and Results

The angiographic and procedural characteristics of and results for both groups are shown in Table 2. Compared with the non-SF group, the SF group had considerably greater lesion complexity. While stent size was similar between the 2 groups, significant differences were seen in the total stent length, the number of stents per lesion, and the rate of stent overlap lesion (all $P < 0.001$). Preprocedure minimal lumen diameter and lesion length were significantly smaller and longer in the SF group than in the non-SF group ($P = 0.04$ and $P < 0.001$, respectively). Postprocedure minimal lumen diameter and percent diameter stenosis were significantly smaller and higher in the SF group than in the non-SF group ($P = 0.002$ and $P < 0.001$, respectively). In SF lesions with hinge motion, the point of fracture was well accorded with the point of hinge motion. At follow-up, ISR and in-segment restenosis occurred more frequently in the SF group than in the non-SF group ($P < 0.001$, respectively). In the SF group, 57.7% of SF sites were associated with ISR. The angiographic patterns of ISR were mostly focal (76.4%) in both groups. No coronary aneurysm formation was observed in the SF group.

Classification and Independent Predictors of Stent Fracture

Among 71 SFs, there were 69 (97.2%) angiographically visible SFs, in which 20 (28.2%) were type 1, 27 (38.0%) were type 2, and 22 (31.0%) was type 3. Two SFs (2.8%) were not angiographically visible and were detected only by using OCT. We defined them as angiographically “unclassified”.¹⁰ Figure 3 shows a representative case with type 3 SF. In this study, 31 (43.7%) SFs detected by using IVUS or OCT and performing a careful review of the angiogram. Of 31 SFs detected by using IVUS or OCT, 28 (90.3%) were complete and 3 (9.7%) were partial. The SFs were located in the mid-portion (67.6%), overlap portion (21.1%), proximal portion (8.4%), and distal portion (2.9%). Figure 4A and 4B show the classification of angiographic SF and the relationship between angiographic SF classification and clinically driven TLR and ST.

The predictors of SF after BES implantation on multivariate logistic regression analysis are shown in Table 3. Hinge motion (OR 8.90, 95% CI 3.84 to 20.6, $P < 0.001$), tortuosity (OR 4.16, 95% CI 1.75 to 9.88, $P = 0.001$), and overlapping stents (OR 2.41, 95% CI 0.95 to 6.10, $P = 0.06$) were identified as predictors of SF after BES implantation.

Clinical Outcomes

Overall TLR and clinically driven TLR were performed in 18 and 7 lesions with SF and 39 and 14 lesions without SF, respectively.

Table 1. Baseline Patient Characteristics

	Overall	SF	Non-SF	P Value
Patients, n	1026	57	969	
Age	70.1±9.8	72.4±8.9	70.1±9.8	0.09
Male	780 (76.0)	41 (71.9)	739 (76.2)	0.42
Hypertension	803 (78.2)	46 (80.7)	757 (78.1)	0.74
Diabetes	440 (42.8)	29 (50.8)	411 (42.4)	0.21
Dyslipidemia	746 (72.7)	39 (68.4)	707 (72.9)	0.44
Hemodialysis	75 (7.3)	5 (8.7)	70 (7.2)	0.60
Current smoking	181 (17.6)	11 (19.3)	170 (17.5)	0.72
Multivessel disease	277 (27.0)	20 (35.0)	257 (26.5)	0.16
No. of diseased vessels				0.16
1	748 (72.9)	37 (64.9)	711 (73.4)	
2	222 (21.6)	14 (24.6)	208 (21.5)	
3	56 (5.5)	6 (10.5)	50 (5.1)	
Previous MI	229 (22.3)	11 (19.3)	218 (22.5)	0.74
Previous PCI	505 (49.2)	25 (43.9)	480 (49.5)	0.41
Previous CABG	56 (5.4)	3 (5.3)	53 (5.4)	>0.99
Previous CI	83 (8.0)	8 (14.0)	75 (7.7)	0.13
Clinical status				0.34
Stable angina	905 (88.2)	53 (93.0)	852 (87.9)	
Unstable angina	29 (2.8)	0 (0.0)	29 (3.0)	
AMI	92 (9.0)	4 (7.0)	88 (9.1)	
LVEF, %	60.5 (51.1 to 66.4)	59.0 (45.8 to 65.0)	60.6 (51.6 to 66.5)	0.24
Medical treatment				
Aspirin	1026 (100.0)	57 (100.0)	969 (100.0)	—
Thienopyridine	1023 (99.7)	57 (100.0)	966 (99.6)	>0.99
Statins	780 (76.0)	40 (70.1)	740 (76.3)	0.33
ACEI	224 (21.9)	18 (31.5)	206 (21.2)	0.07
ARB	477 (46.4)	25 (43.9)	452 (46.6)	0.78
β-Blockers	452 (44.0)	27 (47.3)	425 (43.8)	0.68
OHA	324 (31.5)	21 (36.8)	303 (31.2)	0.38
Insulin	91 (8.8)	7 (12.2)	84 (8.6)	0.33

Categorical variables are expressed as n (%); continuous variable as mean±SD. SF indicates stent fracture; MI, myocardial infarction; PCI, percutaneous coronary intervention; CABG, coronary artery bypass graft surgery; CI, cerebral infarction; AMI, acute myocardial infarction; LVEF, left ventricular ejection fraction; ACEI, angiotensin-converting enzyme inhibitor; ARB, angiotensin II receptor blocker; OHA, oral hypoglycemia agent.

Cumulative incidences of overall TLR and clinically driven TLR were numerically higher in the SF group than in the non-SF group (31.0% versus 2.9% and 12.0% versus 1.0%; Figure 5 and 6, respectively). ST occurred in 1 lesion with SF and in 7 lesions without SF. Cumulative incidence of ST tended to be higher in the SF group than in the non-SF group (1.7% versus 0.5%; Figure 7). All STs were definite STs. Only late ST was observed in the SF group, whereas 5 early ST and 2 late ST were observed in the non-SF group.

Discussion

The main findings of the present study are that (1) the incidence of SF after BES implantation was 4.1% of lesions, (2) SF appeared to be associated with clinically driven TLR, and (3) lesions with hinge motion, tortuosity, or overlapping stent were identified as predictors of SF.

The incidence of SF in the clinical setting has been reported to be 0.84% to 8.4% in first-generation DES.^{6,7} Of the

Table 2. Baseline Lesion Characteristics

	Overall	SF	Non-SF	P Value
Lesion, n	1407	58	1349	
Location of target lesion				<0.001
RCA	451 (32.1)	29 (50.0)	422 (31.3)	
LAD	562 (39.9)	21 (36.2)	541 (40.1)	
LCX	297 (21.1)	7 (12.1)	337 (25.0)	
LMT	43 (3.1)	0 (0.0)	43 (3.2)	
SVG	12 (0.9)	0 (0.0)	12 (0.9)	
LITA	2 (0.2)	0 (0.0)	2 (0.2)	
Lesion type				<0.001
A	132 (9.4)	0 (0.0)	132 (9.8)	
B1	343 (24.4)	2 (3.6)	341 (25.3)	
B2	311 (22.1)	9 (15.8)	302 (22.4)	
C	620 (44.1)	47 (80.7)	573 (42.5)	
In-stent restenosis	153 (10.9)	5 (8.6)	148 (11.0)	0.83
Calcification	169 (12.0)	16 (27.6)	153 (11.3)	0.001
Tortuosity	453 (32.2)	49 (84.5)	404 (30.0)	<0.001
Hinge motion	173 (12.3)	38 (65.5)	135 (10.0)	<0.001
Bifurcation	440 (31.3)	15 (25.8)	425 (31.5)	0.39
Ostial location	133 (9.5)	7 (12.0)	126 (9.3)	0.49
Chronic total occlusion	131 (9.3)	10 (17.2)	121 (9.0)	0.059
Stent diameter, mm	2.8±0.4	2.8±0.4	2.8±0.4	0.29
Total stent length, mm	30.6±18.5	51.7±25.4	29.7±17.7	<0.001
No. of stents per lesion				<0.001
1	1000 (71.0)	18 (31.6)	982 (72.8)	
2	302 (21.5)	22 (37.8)	280 (20.8)	
≥3	105 (7.5)	18 (31.6)	87 (6.4)	
Maximal pressure, atm	12.8±4.9	13.9±5.0	12.7±4.9	0.07
Post dilatation	827 (58.9)	30 (52.7)	797 (59.1)	0.34
Stent overlap	442 (31.4)	43 (74.1)	399 (29.6)	<0.001
IVUS use	1245 (88.6)	50 (87.7)	1195 (88.7)	0.83
QCA results				
Lesion length, mm	24.1±12.3	39.9±16.8	23.4±11.7	<0.001
RVD at baseline, mm	2.63±0.41	2.57±0.38	2.63±0.41	0.32
Pre-MLD, mm	0.52±0.37	0.45±0.44	0.52±0.37	0.04
Pre-DS, %	77.4±14.9	80.2±16.6	77.3±14.8	0.14
Post-MLD, mm	2.19±0.39	2.04±0.30	2.20±0.39	0.002
Post-DS, %	16.5±6.7	20.1±5.9	16.3±6.7	<0.001
In-stent restenosis				
Focal	123 (8.7)	33 (56.9)	90 (6.7)	<0.001
Diffuse	38 (2.7)	4 (6.9)	34 (2.5)	<0.001
Overall	161 (11.4)	37 (63.8)	124 (9.2)	<0.001
In-segment restenosis	169 (12.0)	37 (63.8)	132 (9.8)	<0.001

Categorical variables are expressed as n (%); continuous variable as mean ± SD. SF indicates stent fracture; RCA, right coronary artery; LAD, left anterior descending coronary artery; LCX, left circumflex artery; LMT, left main trunk; SVG, saphenous vein graft; LITA, left internal thoracic artery; IVUS, intravascular ultrasound; QCA, quantitative coronary angiography; RVD, reference vessel diameter; MLD, minimal lumen diameter; DS, diameter stenosis.

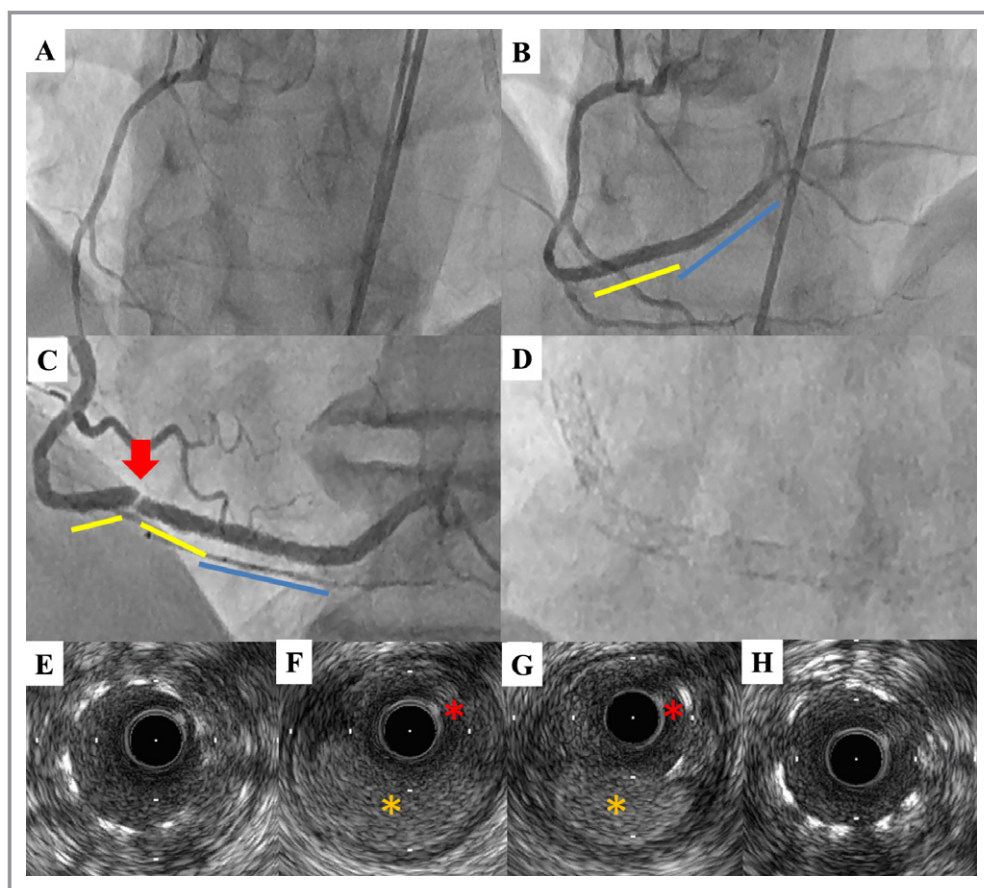


Figure 3. Representative case of stent fracture. A, Coronary angiography shows a lesion with chronic total occlusion at distal right coronary artery. B, Final results after implantation of 2 biolimus-eluting stents with overlap (2.5×24 mm [yellow line] and 2.5×28 mm [blue line]). C, At 6 months after implantation, angiography shows 99% stenosis with stent fracture (red arrow) at the mid-portion of implanted stent. D, Magnified image without contrast at follow-up. E through H, The sequence of 4 intravascular ultrasound (IVUS) image slices with 0.5-mm intervals at minimal lumen diameter from proximal (E) to distal site (H). IVUS shows the complete absence of stent strut (F) and that stent fracture is occurred at the borderline between true arterial lumen (yellow asterisk) and subintimal space (red asterisk) (F and G).

newer-generation DES, we previously reported that SF after CoCr-EES implantation was observed in 2.9% of lesions and was associated with a higher rate of major cardiac events, mainly driven by higher TLR and ST.¹⁰ The Nobori device consists of a stainless steel platform, a biodegradable polymer carrier (polylactic acid), and the antiproliferative drug Biolimus A9. The platform of Nobori is a 316L medical-grade stainless steel stent with a 2-link design to increase flexibility while maintaining satisfactory scaffolding.¹⁷ Recently, the angiographic substudy of the NOBORI Biolimus-Eluting Versus XIENCE/PROMUS Everolimus-Eluting Stent Trial (NEXT)¹² showed that the SF rate after BES implantation was 3.1% of lesions and significantly higher than that after EES implantation. However, the number of patients in this study was relatively small, and there are no data regarding the incidence of SF after BES implantation in clinical practice. In the present study, the incidence of SF after BES implantation was 4.1% of

lesions, which was higher than that of NEXT¹² and after CoCr-EES implantation in clinical practice.¹⁰ Therefore, BES might be prone to be fractured compared with CoCr-EES.

In the current study, lesions with hinge motion, tortuosity, or overlapping stents were predictors of SF after BES implantation. Hinge motion and tortuosity were reportedly common risk factors of SF between BES and CoCr-EES,¹⁰ but the former contributed more significantly to the incidence of SF in both stents. Moreover, it is intriguing that the portion and pattern of SF differed between the BES and CoCr-EES. Compared with CoCr-EES, SF after BES implantation was more likely to occur in overlapping and multiple portions and to appear as a complete fracture. The stent platform of BES differs from that of EES in terms of the number of links (2 versus 3) and metal alloy (stainless steel versus cobalt chrome). Although the design of 2 links between peaks is more flexible than the design of 3 links between peak to

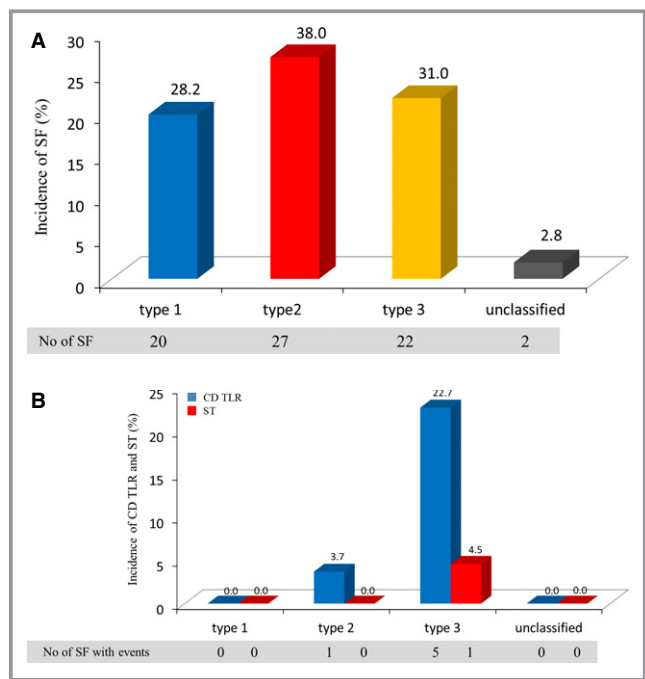


Figure 4. A, Classification of angiographic stent fracture (SF). “Unclassified” indicates angiographically nonvisible SF. B, Relationships between angiographic SF classification and CD TLR and ST. Blue box indicates clinically driven target lesion revascularization (CD TLR); red box, stent thrombosis (ST).

valley, it may be prone to complete fracture if an SF occurs. Furthermore, an overlapping stent is reportedly a risk factor for SF after SES because it increases the axial stiffness of the stented segment.^{7,18} Although it remains unclear as to why an SF in a BES is likely to occur in the overlapping portion, it may be due to the design and material of the stent platform.

An optimal stent design incorporates a balance of desirable characteristics; however, an improvement in one feature may adversely affect other attributes of the stent platform. For example, fewer connectors between hoops and thinner new

Table 3. Multivariable Logistic Regression Analysis of Stent Fracture

	OR*	95% CI	P Value
Hinge motion	8.90	3.84 to 20.6	<0.001
Tortuosity	4.16	1.75 to 9.88	0.001
Overlapping stent	2.41	0.95 to 6.10	0.06
Calcification	1.67	0.75 to 3.68	0.21
Right coronary artery	0.58	0.26 to 1.29	0.18
Total stent length (per 10-mm increase)	1.08	0.92 to 1.28	0.34

For all variables, $P < 0.05$ by univariate analysis.
*Generalized estimating equations model accounted for within-patient clustering of lesion characteristics.

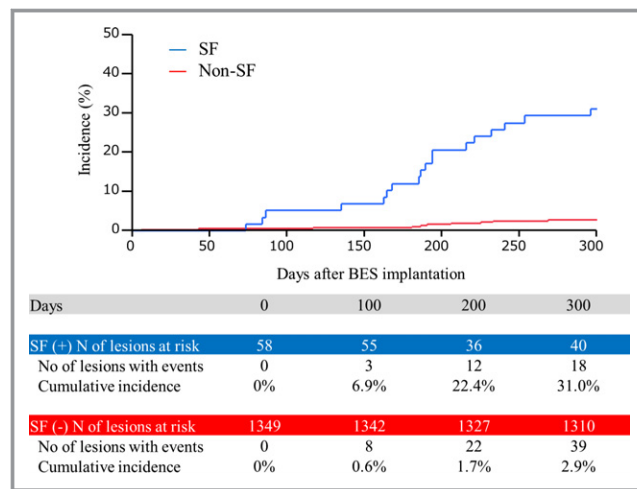


Figure 5. Cumulative incidence of overall TLR within 9 months after BES implantation. BES indicates biolimus-eluting stent; SF, stent fracture.

metal alloys such as cobalt chromium and platinum chromium lead to higher flexibility, whereas these features adversely affect stent longitudinal integrity.¹⁹ Indeed, the contributors of SF are not only flexibility but also longitudinal strength because repetitive cardiac contraction exposes the stent to compression, torsion, kinking, elongation, bending, and shear stress. These findings were supported by the presence of type 3b SF (Figure 2) in the current study. Moreover, similar SF pattern has been observed in CoCr-EES.¹⁰ Therefore, even if a newer DES with increased flexibility is developed, a few SFs may be inevitable because it is made of metal.

SF has been associated with a higher potential risk of ISR, TLR, and ST in the first-generation DES.⁵ Although current DES clinical trials have shown noninferiority among newer-

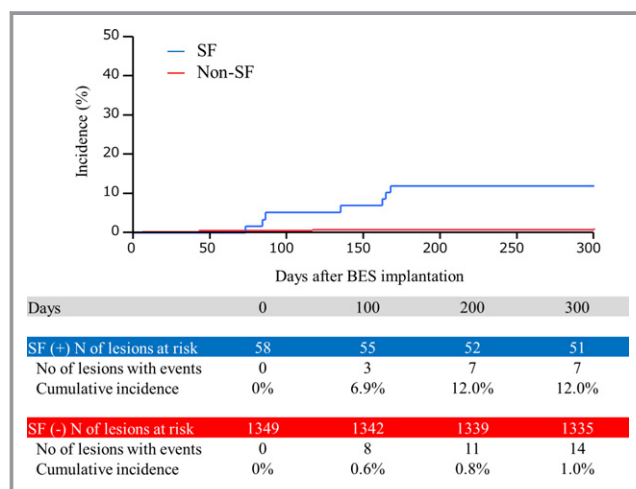


Figure 6. Cumulative incidence of clinically driven TLR within 9 months after BES implantation. BES indicates biolimus-eluting stent; SF, stent fracture.

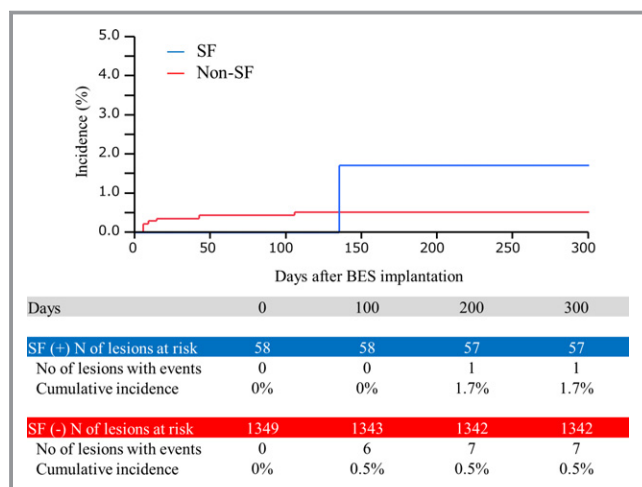


Figure 7. Cumulative incidence of stent thrombosis within 9 months after BES implantation. BES indicates biolimus-eluting stent; SF, stent fracture.

generation DES in term of clinical outcome,^{11,12,20} SF after CoCr-EES implantation was associated with MACE within 9 months, mainly driven by clinically driven TLR.¹⁰ Similarly, the present study showed a higher incidence of clinically driven TLR after BES implantation in the SF group compared with the non-SF group. These findings support that SF remains an unsolved issue even in newer-generation DES. On the other hand, there were some differences in the predictors of SF among BES and CoCr-EES. Therefore, it is important for clinicians to know the incidence, predictors, and clinical impact of SF for each newer-generation DES. Moreover, it is useful to learn the features of stent platform for appropriate use of current DES on the basis of lesion characteristics. If the target lesion is at a high risk of SF (ie, diffuse lesion with hinge motion and tortuosity), we should make efforts to not overlap stents at hinge points and to select stents with less tendency to fracture.

Study Limitations

There are several limitations in the present study. First, this study was a single-center study, and follow-up angiography was not performed in all patients. Therefore, selection bias may exist in the present study and may have biased the conclusion. Second, IVUS and OCT were not performed in all patients undergoing follow-up angiography. In addition, the detection of partial SF on angiography was limited because of its spatial resolution, regardless of high visibility on plain fluoroscopy of BES. Therefore, the present study may have underestimated the incidence of SF. Finally, the impact of SF after BES implantation on long-term clinical outcomes is not assessed in this study. Umeda et al²¹ reported that SF after SES was not significantly associated

with major adverse clinical events between 1 and 4 years after the index procedure. Further study is needed to assess whether SF after BES might influence long-term clinical outcomes.

Conclusions

SF after BES implantation occurs in 4.1% of lesions and appears to be associated with clinically driven TLR. Lesions with hinge motion, tortuosity, or overlapping stent are predictors of SF.

Acknowledgments

The authors thank Toshimitsu Hamasaki, Naoka Katsumi, Mikie Ochi, Miho Hasegawa, and Shinobu Matsumoto for assistance with this work.

Disclosures

None.

References

- Morice MC, Serruys PW, Sousa JE, Fajadet J, Ban Hayashi E, Perin M, Colombo A, Schuler G, Barragan P, Guagliumi G, Molnar F, Falotico R; RAVEL Study Group. A randomized comparison of a sirolimus-eluting stent with a standard stent for coronary revascularization. *N Engl J Med.* 2002;346:1773–1780.
- Moses JW, Leon MB, Popma JJ, Fitzgerald PJ, Holmes DR, O’Shaughnessy C, Caputo RP, Kereiakes DJ, Williams DO, Teirstein PS, Jaeger JL, Kuntz RE; SIRIUS Investigators. Sirolimus-eluting stents versus standard stents in patients with stenosis in a native coronary artery. *N Engl J Med.* 2003;49:315–323.
- McFadden EP, Stabile E, Regar E, Cheneau E, Ong AT, Kinnaird T, Suddath WO, Weissman NJ, Torguson R, Kent KM, Pichard AD, Satler LF, Waksman R, Serruys PW. Late thrombosis in drug-eluting coronary stents after discontinuation of antiplatelet therapy. *Lancet.* 2004;364:1519–1521.
- James SK, Stenestrand U, Lindbäck J, Carlsson J, Scherstén F, Nilsson T, Wallentin L, Lagerqvist B; SCAAR Study Group. Long-term safety and efficacy of drug-eluting versus bare-metal stents in Sweden. *N Engl J Med.* 2009;360:1933–1945.
- Lee SE, Jeong MH, Kim IS, Ko JS, Lee MG, Kang WY, Kim SH, Sim DS, Park KH, Yoon NS, Yoon HJ, Kim KH, Hong YJ, Park HW, Kim JH, Ahn YK, Cho JG, Park JC, Kang JC. Clinical outcome and optimal treatment for stent fracture after drug-eluting stent implantation. *J Cardiol.* 2009;53:422–428.
- Umeda H, Gochi T, Iwase M, Izawa H, Shimizu T, Ishiki R, Inagaki H, Toyama J, Yokota M, Murohara T. Frequency, predictors and outcome of stent fracture after sirolimus-eluting stent implantation. *Int J Cardiol.* 2009;133:321–326.
- Chung WS, Park CS, Seung KB, Kim PJ, Lee JM, Koo BK, Jang YS, Yang JY, Yoon JH, Kim DJ, Yoon YW, Park JS, Cho YH, Park SJ. The incidence and clinical impact of stent strut fractures developed after drug-eluting stent implantation. *Int J Cardiol.* 2008;125:325–331.
- Chakravarty T, White AJ, Buch M, Naik H, Doctor N, Schapira J, Kar S, Forrester JS, Weiss RE, Makkar R. Meta-analysis of incidence, clinical characteristics and implication of stent fracture. *Am J Cardiol.* 2010;106:1075–1080.
- Torguson R, Waksman R. Overview of the 2007 food and drug administration circulatory system devices panel meeting on the Xience V everolimus-eluting coronary stent. *Am J Cardiol.* 2008;102:1624–1630.
- Kuramitsu S, Iwabuchi M, Haraguchi T, Domei T, Nagae A, Hyodo M, Yamaji K, Soga Y, Arita T, Shirai S, Kondo K, Ando K, Sakai K, Goya M, Takabatake Y, Sonoda S, Yokoi H, Toyota F, Nosaka H, Nobuyoshi M. Incidence and clinical impact of stent fracture after everolimus-eluting stent implantation. *Circ Cardiovasc Interv.* 2012;5:663–671.
- Smits PC, Hofma S, Togni M, Vázquez N, Valdés M, Voudris V, Slagboom T, Goy JJ, Vuillomenet A, Serra A, Nouche RT, den Heijer P, van der Ent M. Abluminal

- biodegradable polymer biolimus-eluting stent versus durable polymer everolimus-eluting stent (COMPARE II): a randomised, controlled, non-inferiority trial. *Lancet*. 2013;381:651–660.
12. Natsuaki M, Kozuma K, Morimoto T, Kadota K, Muramatsu T, Nakagawa Y, Akasaka T, Igarashi K, Tanabe K, Morino Y, Ishikawa T, Nishikawa H, Awata M, Abe M, Okada H, Takatsu Y, Ogata N, Kimura K, Urasawa K, Tarutani Y, Shiode N, Kimura T; NEXT Investigators. Biodegradable polymer biolimus-eluting stent versus durable polymer everolimus-eluting stent: a randomized, controlled, noninferiority trial. *J Am Coll Cardiol*. 2013;62:181–190.
 13. Danzi GB, Chevalier B, Urban P, Fath-Ordoubadi F, Carrie D, Wiemer M, Serra A, Wijns W, Kala P, Stabile A, Ruigomez JG, Sagic D, Laanmets P, Strupp G, West N, Paunovic D; NOBORI 2 Investigators. Clinical performance of a drug-eluting stent with a biodegradable polymer in an unselected patient population: the NOBORI 2 study. *EuroIntervention*. 2012;8:109–116.
 14. Mehran R, Dangas G, Abizaid AS, Mintz GS, Lansky AJ, Satler LF, Pichard AD, Kent KM, Stone GW, Leon MB. Angiographic patterns of in-stent restenosis: classification and implications for long-term outcome. *Circulation*. 1999;100:1872–1878.
 15. Ino Y, Kubo T, Kitabata H, Shimamura K, Shiono Y, Orii M, Okochi K, Sougawa H, Tanimoto T, Komukai K, Ishibashi K, Takarada S, Nakanishi H, Tanaka A, Kimura K, Hirata K, Mizukoshi M, Imanishi T, Akasaka T. Impact of hinge motion on in-stent restenosis after sirolimus-eluting stent implantation. *Circ J*. 2011;75:1878–1884.
 16. Mauri L, Hsieh WH, Massaro JM, Ho KK, D'Agostino R, Cutlip DE. Stent thrombosis in randomized clinical trials of drug-eluting stents. *N Engl J Med*. 2007;356:1020–1029.
 17. Danzi GB, Chevalier B, Ostojic M, Hamilos M, Wijns W. Nobori™ drug eluting stent system: clinical evidence update. *Minerva Cardioangiol*. 2010;58:599–610.
 18. Lee MS, Jurewitz D, Aragon J, Forrester J, Makkar RR, Kar S. Stent fracture associated with drug-eluting stents: clinical characteristics and implications. *Catheter Cardiovasc Interv*. 2007;69:387–394.
 19. Ormiston JA, Webber B, Webster MW. Stent longitudinal integrity bench insights into a clinical problem. *JACC Cardiovasc Interv*. 2011;4:1310–1317.
 20. von Birgelen C, Sen H, Lam MK, Danse PW, Jessurun GA, Hautvast RW, van Houwelingen GK, Schramm AR, Gin RM, Louwerenburg JW, de Man FH, Stoel MG, Löwik MM, Linssen GC, Saïd SA, Nienhuis MB, Verhorst PM, Basalus MW, Doggen CJ, Tandjung K. Third-generation zotarolimus-eluting and everolimus-eluting stents in all-comer patients requiring a percutaneous coronary intervention (DUTCH PEERS): a randomised, single-blind, multicentre, non-inferiority trial. *Lancet*. 2014;383:413–423.
 21. Umeda H, Kawai T, Misumida N, Ota T, Hayashi K, Iwase M, Izawa H, Sugino S, Shimizu T, Takeichi Y, Ishiki R, Inagaki H, Ozaki Y, Murohara T. Impact of sirolimus-eluting stent fracture on 4-year clinical outcomes. *Circ Cardiovasc Interv*. 2011;4:349–354.