



Septic Arthritis of the Pubic Symphysis in Adult: A Case Report*

Artrite séptica da sínfise púbica em adultos: Relato de caso

Pedro José Labronici¹ Augusto Khede Tavares² Luiz Henrique Penteado Silva³
Robinson Esteves Santos Pires⁴ Vincenzo Giordano⁵ Fabrício Bolpato Loures⁶

¹ Orthopedics and Traumatology Service, Hospital Santa Teresa, Petrópolis, RJ, Brazil

² Orthopedics and Traumatology Service, Hospital Santa Teresa, Petrópolis, RJ, Brazil

³ Trauma Service, Hospital do Trauma e Hospital Escola São Vicente de Paulo, Passo Fundo, RS, Brazil

⁴ Universidade Federal de Minas Gerais, Belo Horizonte, MG, Brazil

⁵ Orthopedics and Traumatology Service, Hospital Municipal Miguel Couto, Rio de Janeiro, RJ, Brazil

⁶ Universidade Estadual do Rio de Janeiro, Rio de Janeiro, RJ, Brazil

Address for correspondence Pedro José Labronici, Av. Roberto Silveira, 187, apto 601, Petrópolis, RJ, 25685-040, Brazil (e-mail: plabronici@globo.com).

Rev Bras Ortop 2021;56(2):268–270.

Abstract

Septic arthritis of the pubic symphysis is a rare condition. Risk factors include trauma, low-grade infection, urological or gynecological procedures, malignant tumors of the pelvis, sports, and intravenous drug abuse. This report describes a case of septic arthritis of the pubic symphysis in a 23-year-old male patient with no history of pelvic surgery, previous infections, or intense physical activity. Arthritis was diagnosed by blood culture positive for *Enterococcus* spp. and yeasts, and the patient was treated with antibiotics. This case emphasizes the importance of complementary exams to aid the treatment of septic arthritis of the pubic symphysis and shows that an invasive procedure, such as pubic symphysis puncture biopsy, may not be required.

Keywords

- ▶ septic arthritis
- ▶ osteitis
- ▶ pubic symphysis

Resumo

A artrite séptica da sínfise púbica é uma condição rara. Os fatores de risco são trauma, infecção de baixo grau, procedimentos urológicos ou ginecológicos, tumores malignos da pelve, prática de esportes e uso de drogas intravenosas. O presente relato descreve um caso de artrite séptica da sínfise púbica em um paciente do sexo masculino, de 23 anos, sem história de cirurgias pélvicas, infecções prévias ou atividade física intensa. A artrite foi diagnosticada pela hemocultura que revelou crescimento de *Enterococcus* sp + leveduras, e o paciente foi tratado com antibioticoterapia. Este caso enfatiza a importância de exames complementares no auxílio do tratamento da artrite séptica da sínfise púbica, e demonstra que procedimentos invasivos, tais como a punção da sínfise púbica, podem não ser necessários.

Palavras-chave

- ▶ artrite séptica
- ▶ osteíte
- ▶ sínfise púbica

* Study developed at the Orthopedics and Traumatology Department, Hospital Santa Teresa, Petrópolis, RJ, Brazil.

received
May 21, 2020
accepted
September 17, 2020
published online
March 22, 2021

DOI <https://doi.org/10.1055/s-0040-1721843>.
ISSN 0102-3616.

© 2021. Sociedade Brasileira de Ortopedia e Traumatologia. All rights reserved.

This is an open access article published by Thieme under the terms of the Creative Commons Attribution-NonDerivative-NonCommercial-License, permitting copying and reproduction so long as the original work is given appropriate credit. Contents may not be used for commercial purposes, or adapted, remixed, transformed or built upon. (<https://creativecommons.org/licenses/by-nc-nd/4.0/>)

Thieme Revinter Publicações Ltda., Rua do Matoso 170, Rio de Janeiro, RJ, CEP 20270-135, Brazil

Introduction

Septic arthritis of the pubic symphysis is a rare condition, usually caused by *Staphylococcus aureus* and *Pseudomonas aeruginosa*.¹⁻⁵ Infection may result from a secondary embolization due to bacteremia or contiguous spread of a soft-tissue infection. Risk factors include trauma, low-grade infection, urological and gynecological procedures, malignant tumors of the pelvis, practice of sports, and intravenous drug abuse.⁵ Clinically, it presents as fever, abdominal, pelvic or groin pain, which increases when standing up and walking, pain at hip movement, and painful claudication.²⁻⁴ The difficulty in suspecting pubic conditions, due to their rarity and atypical presentations, can delay diagnosis and therapy.^{2,4} The present report aims to increase awareness of a rare infection focus at the pubic symphysis, assisting in its differential diagnosis from abdominal pain, thus enabling early treatment.

Case Report

A healthy, 23-year-old male patient, who worked as a teacher, was admitted to the emergency department on June 10, 2019, complaining of bilateral hip pain starting 11 days before. The pain started on the left hip, and the patient had reported fever for 8 days. He denied trauma, high-demand physical activities, and previous infections.

On physical examination, the patient was aware, oriented, with low-grade fever (38.8°C), tachycardic (108 beats per minute), and with no inflammatory signs at an ectoscopic examination of the pelvis and lower limbs; he complained of diffuse pain during bilateral palpation from the pubic symphysis to the anterolateral region of hip, which was accentuated on the left side. The patient also presented reduced muscle strength (M2) for hip flexion and leg extension, but no sensory changes or abnormalities in other muscle groups.

On June 03, 2019, a magnetic resonance image (MRI) of the patient's left hip showed signs of insertional peritendinitis of the gluteus minimus, but no changes at the pubic symphysis joint. Laboratory tests requested at admission showed 18,100 white blood cells (WBC)/mm³ with 18% of band neutrophils, an erythrocyte sedimentation rate (ESR) of 82 mm at the first hour, and a C-reactive protein (CRP) level of 162 mg/dL. On June 10, 2019, when the patient was admitted, a chest x-ray, blood cultures with four samples, a urine sedimentoscopy, and a urine culture were requested. A new MRI of the pelvis was consistent with septic arthritis of the pubic symphysis (→ **Figure 1**). Treatment was instituted on the following day with intravenous ciprofloxacin, 400 mg, every 12 hours, and vancomycin. Blood cultures were positive for *Enterococcus* spp. and yeasts. Chest x-ray and urine cultures were negative.

On June 17, 2019, the patient presented significant improvement, including limb strength recovery, pain relief, and laboratory markers reduction; as such, we decided to continue the intravenous antibiotic therapy with ciprofloxacin and vancomycin. He improved up to the total remission of complaints on July 4, 2019 (→ **Table 1**). After 4 weeks of intravenous antibiotic therapy, the patient was discharged

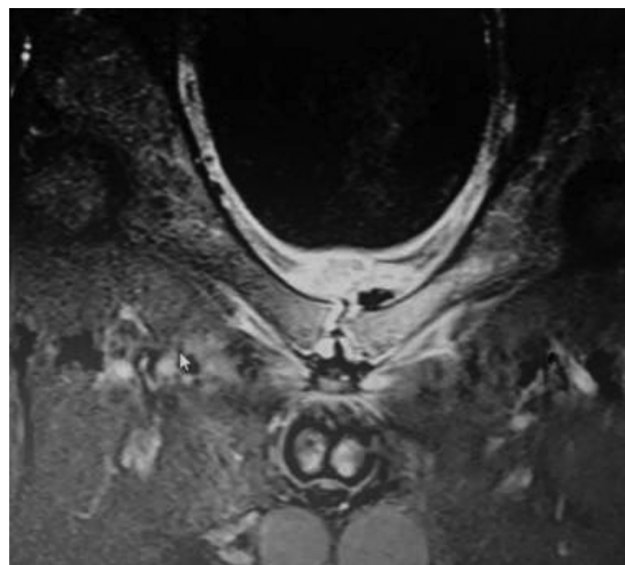


Fig. 1 Magnetic resonance imaging of the pelvis in short inversion time inversion recovery showing a fluid collection at the pubic symphysis region.

with a prescription of oral ciprofloxacin (500 mg every 12 hours) for another 60 days and outpatient follow-up.

Discussion

The case report presently discussed demonstrates the importance of complementary exams to diagnose septic arthritis of the pubic symphysis with no need for invasive procedures.

Septic arthritis of the pubic symphysis is very different from osteitis pubis. Osteitis pubis is characterized by pelvic pain, broad-based gait, and bone lesion on the pubic symphysis edges. It is a self-limiting inflammation secondary to trauma, pelvic surgery, childbirth, or stress (often in athletes). Septic arthritis of the pubic symphysis must be suspected in patients with acute onset of pelvic pain, fever, and systemic symptoms.⁴ Clinically, these symptoms include abdominal, pelvic, or inguinal pain, which increases when standing up or walking and can result in lameness. In addition, this diagnosis must be considered when testicular, perineal, or thigh pain is noted.²⁻⁴ Although septic arthritis and inflammatory arthritis of the pubic symphysis present similar clinical presentations, the former is more severe and accompanied by pain and fever.²⁻⁴

Although conventional radiography takes 2 to 4 weeks to show signs of pubic symphysis joint impairment, it can help to exclude other causes.¹ The first signs of septic arthritis with pubic osteomyelitis are an unilateral injury with bone sequestration or stress fracture and eventual bone destruction.^{1,2,4} Wilmes et al.⁵ assessed the extent of pelvic abnormalities (with joint contrast injections) and performed symphysis aspiration guided by computed tomography (CT) for material analysis. Several authors recommend joint aspiration guided by ultrasonography or CT to diagnose an infection.²⁻⁴ However, this invasive procedure may be prevented by positive blood cultures.³ Magnetic resonance imaging is the gold-standard imaging method due to its excellent sensitivity (with specificity comparable to CT). Magnetic resonance imaging sequences

Table 1 Patient evolution per laboratorial findings

	June 10	June 11	June 12	June 17	June 24	July 03	July 05
White blood cells (/mm ³)	18,100	11,900	15,450	9,010	12,260	5,380	4,690
Band neutrophils (%)	18	7	8	1	2	5	2
C-reactive protein (mg/dL)	162.8	155.1		18.4	6.5		1.9
Erythrocyte sedimentation rate (mm/1 st hour)	82	62	90	88	71		25

include fat suppression (fat sat, short inversion time inversion recovery) for improved visualization of the inflamed edges, aiding the diagnosis.¹

The literature states that biopsy and culture are required to differentiate septic and inflammatory arthritis.^{6,7} However, when blood culture is positive, antibiotic therapy can be started, and laboratory findings (complete blood count, CRP, ESR) will reveal clinical improvement. Ghislain et al.⁸ reported that no randomized, controlled studies evaluated antibiotic guidelines for the treatment of septic arthritis of the pubic symphysis when puncture biopsy is negative. In the patient presently discussed, blood cultures were positive for *Enterococcus* spp. and yeasts, and we decided for an antibiotic therapy with ciprofloxacin and vancomycin with no pubic symphysis puncture biopsy for diagnosis confirmation.

The most common infectious agent is *S. aureus*, followed by *P. aeruginosa*, *Escherichia coli*, anaerobic bacteria, and *Salmonella*, *Streptococcus* and *Brucella* species.⁸ Initial treatment with intravenous antibiotics must be followed by oral treatment for at least 4 weeks, and follow-up must continue until ESR normalization (which often takes 3 months). Pubic symphysis surgical debridement and curettage is indicated in patients with serious complications, including pelvic diastasis due to bone necrosis, bladder perforation, pelvic instability, and severe pain not responding to antibiotics.^{9,10}

Septic arthritis of the pubic symphysis is rare and, depending on the results of complementary tests, such as positive blood culture, MRI, and inflammatory markers, patients can be treated conservatively with no need for an invasive procedure.

Conflict of Interests

The authors declare no conflict of interests.

References

- Jarlaud T, Railhac JJ, Sans N, De Paulis F. Symphyse pubienne normale et pathologique: apport de l'imagerie. *J Radiol* 2001;82(3 Pt 2):425-436, quiz 437-438
- Knoeller SM, Uhl M, Herget GW. Osteitis or osteomyelitis of the pubis? A diagnostic and therapeutic challenge: report of 9 cases and review of the literature. *Acta Orthop Belg* 2006;72(05):541-548
- Charles P, Ackermann F, Brousse C, Piette AM, Blétry O, Kahn JE. [Spontaneous streptococcal arthritis of the pubic symphysis]. *Rev Med Interne* 2011;32(07):e88-e90
- Ross JJ, Hu LT. Septic arthritis of the pubic symphysis: review of 100 cases. *Medicine (Baltimore)* 2003;82(05):340-345
- Wilmes D, Omoumi P, Squifflet J, Cornu O, Rodriguez-Villalobos H, Yombi JC. Osteomyelitis pubis caused by *Kingella kingae* in an adult patient: report of the first case. *BMC Infect Dis* 2012;12:236
- Gamble JG, Simmons SC, Freedman M. The symphysis pubis. Anatomic and pathologic considerations. *Clin Orthop Relat Res* 1986;(203):261-272
- Bouza E, Winston DJ, Hewitt WL. Infectious osteitis pubis. *Urology* 1978;12(06):663-669
- Ghislain L, Heylen A, Alexis F, Tintillier M. Septic arthritis of the pubic symphysis: an atypical abdominal pain. *Acta Clin Belg* 2015;70(01):46-49
- Fricker PA, Taunton JE, Ammann W. Osteitis pubis in athletes. Infection, inflammation or injury? *Sports Med* 1991;12(04):266-279
- Grace JN, Sim FH, Shives TC, Coventry MB. Wedge resection of the symphysis pubis for the treatment of osteitis pubis. *J Bone Joint Surg Am* 1989;71(03):358-364