

Oncology

A leopard never changes its spots: Development of colonic adenocarcinoma in an Indiana Pouch

Maureen V. Hill^{a,*}, Brian T. Kadow^b, Min Huang^c, Frank H. Roland^d, Sanjay A. Reddy^a, Alexander Kutikov^a

^a Department of Surgical Oncology, Fox Chase Cancer Center, Philadelphia, PA, USA

^b Department of Urology, DuPage Medical Group, Lisle, IL, USA

^c Department of Pathology, Fox Chase Cancer Center, Philadelphia, PA, USA

^d Department of Urology, Doylestown Health, Doylestown, PA, USA



ARTICLE INFO

Keywords:

Indiana pouch
Adenocarcinoma
Urothelial carcinoma

ABSTRACT

Colonic adenocarcinoma of a urinary diversion is rare. We report a case of a 70 year-old woman who developed such a malignancy 12 years after creation of an Indiana pouch urinary diversion for treatment of urothelial carcinoma of the bladder cancer.

Introduction

While rare, development of adenocarcinoma in a gastrointestinal urinary diversion is a known long-term risk. It is not known if there are any risk factors that cause this cancer to arise, however genetic considerations cannot be ignored. Lynch Syndrome, a phenotype characterized by colon cancer, endometrial cancer and upper tract urothelial carcinoma, occurs when there is a germline mutation in a mismatch repair gene (MLH1, MSH2, MSH6, or PMS2).¹ Patients with these mutations are at high risk for development of an upper tract urothelial cancer; however development of urothelial carcinoma of the bladder has also been described.² In addition, sporadic microsatellite unstable colonic cancers have been seen arising within a urinary diversion. This case describes a potential genetically derived colonic adenocarcinoma arising within a urinary diversion.

Case presentation

A 70-year-old female with a history of a Stage II (T2bN0), high grade, urothelial carcinoma of the bladder underwent a cystectomy and Indiana Pouch urinary diversion in 2007. She had done well for many years with no evidence of recurrence, however in March 2019 she developed gross hematuria. She was treated with antibiotics with transient improvement but her symptoms recurred. A computed tomography (CT)

urogram demonstrated unobstructed upper tracts, an atrophic left kidney, and suggested a 3-cm mass within the Indiana pouch. Pouchoscopy confirmed a tumor within the diversion, and the patient was referred to our institution for consultation. A repeat pouchoscopy was performed that confirmed a large, exophytic mass in the colonic portion of the pouch. Biopsies were obtained that revealed a tubular adenoma with high grade dysplasia. Subsequent colonoscopy showed two <5mm hyperplastic polyps in the rectum and sigmoid colon. A staging CT of chest, abdomen, and pelvis was performed that confirmed the mass within the pouch and no evidence of metastatic disease (Fig. 1a and b). Pre-operative CEA was within normal limits.

Given the concern for invasive cancer, she was taken to the operating room for a pouch resection and conversion to an ileal conduit urinary diversion. Her procedure was uncomplicated, and the Indiana pouch was completely excised including the main blood supply, the ileocolic pedicle. The patient's prior ileo-transverse anastomosis was recreated, after approximately 18 cm of distal ileum was harvested for the ileal conduit. A left nephroureterectomy was performed to avoid a ureteral anastomosis for a non-functioning kidney. The right ureter was anastomosed to the ileal conduit via standard Bricker technique. Pathology revealed a grade II, 3.8 cm colonic adenocarcinoma invading through the muscularis propria and into the pericolic tissue (T3) (Fig. 2a and b, Fig. 3a and b). Twenty-four lymph nodes were identified, and all were negative for carcinoma. Mismatch repair protein immunohistochemical

Abbreviations: CT, computed tomography.

* Corresponding author. Department of Surgical Oncology, Fox Chase Cancer Center, 333 Cottman Ave, Philadelphia, PA 19111, USA.

E-mail address: Maureen.Hill@fccc.edu (M.V. Hill).

<https://doi.org/10.1016/j.eucr.2020.101396>

Received 30 July 2020; Received in revised form 26 August 2020; Accepted 29 August 2020

Available online 31 August 2020

2214-4420/© 2020 The Authors.

Published by Elsevier Inc.

This is an open access article under the CC BY-NC-ND license

(<http://creativecommons.org/licenses/by-nc-nd/4.0/>).

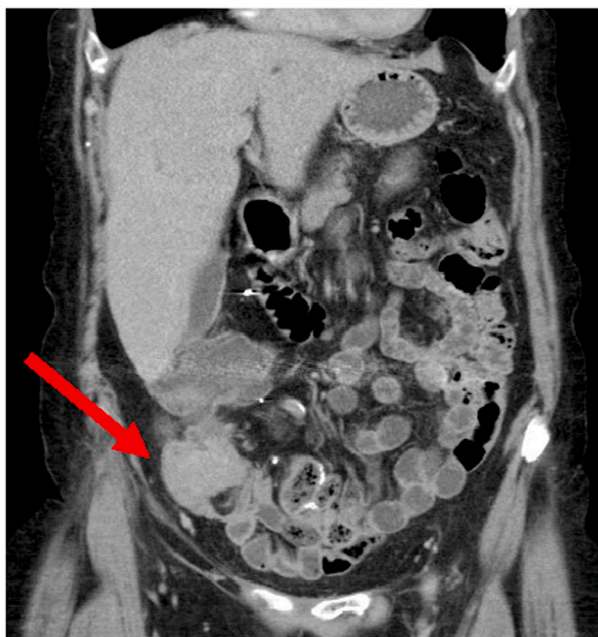
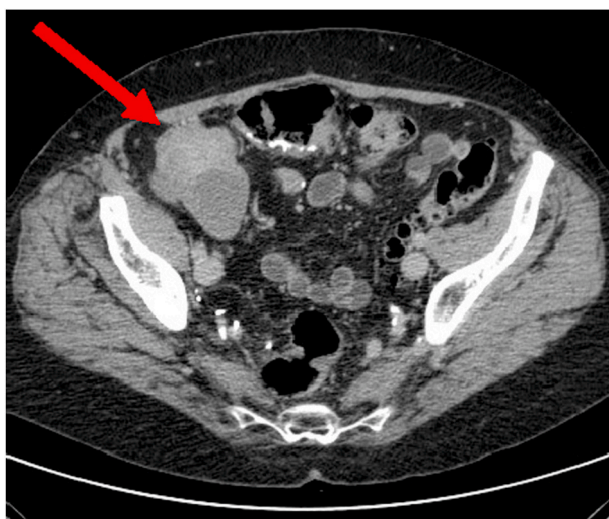


Fig. 1. (a) and (b). CT of the abdomen and pelvis revealing a mass within the Indiana pouch colonic urinary diversion (red arrows). (For interpretation of the references to colour in this figure legend, the reader is referred to the Web version of this article.)

stains revealed equivocal MLH1 expression. She was referred to genetics for consideration of germline testing for Lynch Syndrome given her equivocal expression of MLH1.

Discussion

Adenocarcinoma of the colon within a colonic urinary diversion is rare. This appears to be the 12th case reported in the literature.³⁻⁵ The patient's presenting hematuria initiated the evaluation, which was focused on ruling out recurrent urothelial carcinoma. While infrequent, primary colonic adenocarcinoma should be considered in long term bladder cancer survivors with a colonic urinary diversion. While this patient's original biopsy did not show invasive disease, suspicion for invasive disease was high based on her history, CT scan, and endoscopic findings. As such, formal excision was performed. Appropriate staging should be undertaken and every effort should be made to resect the

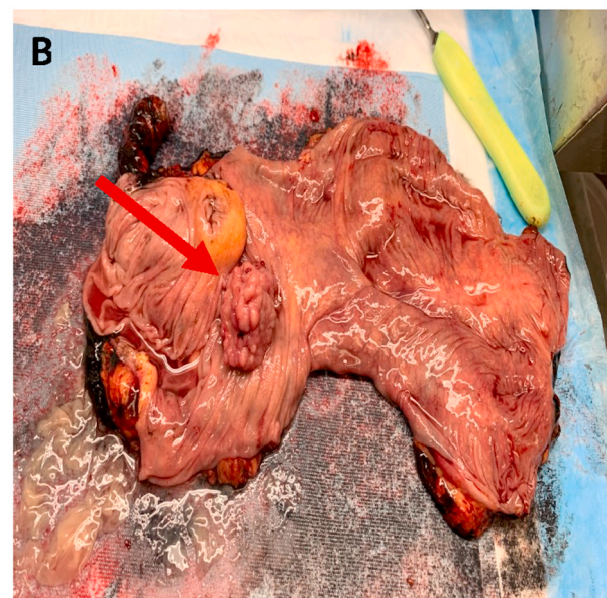
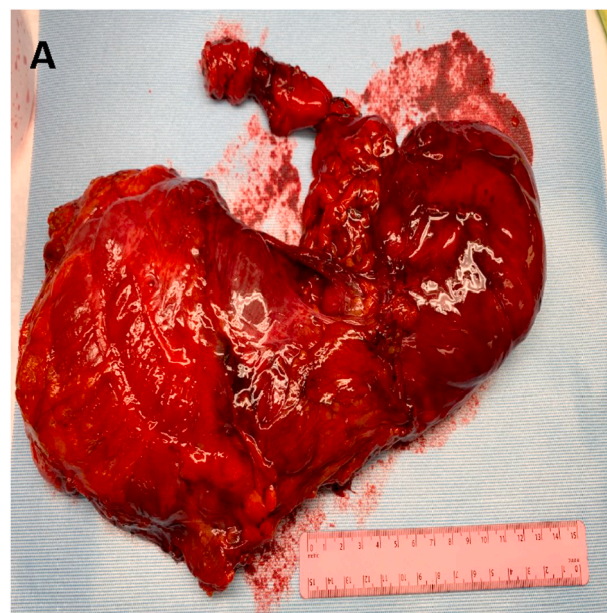


Fig. 2. (a) Gross pathology of Indiana pouch urinary diversion (b) Opened specimen reveals a 3.8 cm colonic adenocarcinoma (arrow).

colon with an adequate lymph node harvest. In this case, her pouch was created from her right and proximal transverse colon, as is typical. The tumor was located in the cecum and the ileo-colic pedicle was highly ligated, while ensuring adequate blood flow to the remainder of the transverse colon. Our lymph node harvest proved to be adequate using this technique. If the tumor was more distal in the colon, taking an additional margin would have been considered. For these complex cases, collaboration between urologic oncology and surgical oncology is imperative.

The patient's tumor was found to have equivocal expression for MLH1. Further genetic counseling and testing for germline mutations was recommended to rule out Lynch Syndrome.¹ While this would be a rare presentation, given the patient's dual malignancies such as an underlying etiology should be considered.

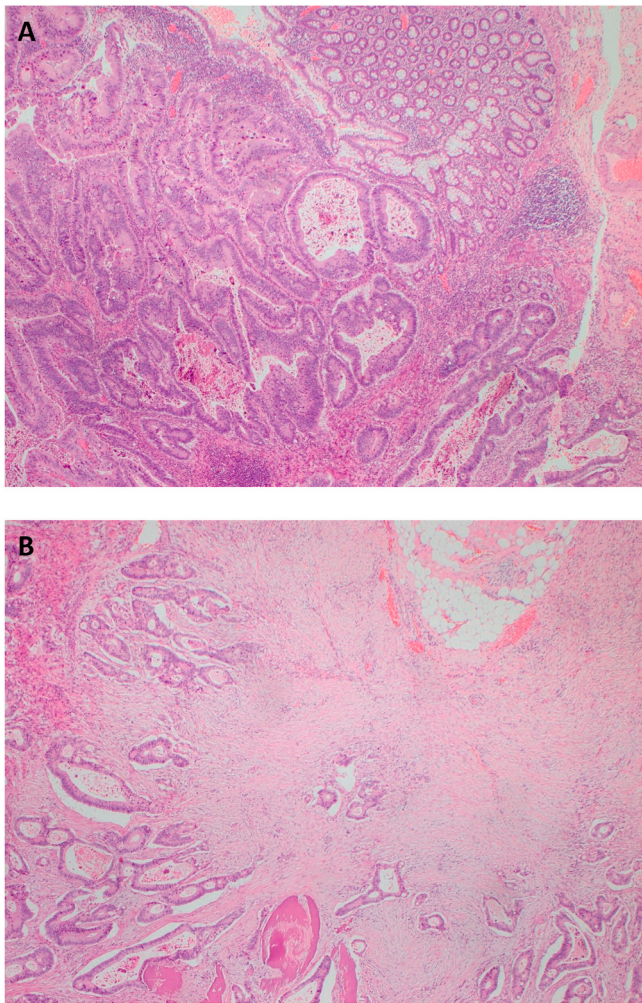


Fig. 3. (a) and (b). Invasive colonic adenocarcinoma with (a) adjacent benign colonic mucosa; (b) invading through muscularis propria.

Conclusion

Colonic adenocarcinoma of an Indiana pouch urinary diversion is

rare, but should be on the differential in patients presenting with hematuria and/or mass within the diversion. Resection is the mainstay of treatment, and it should be done in an anatomic fashion ensuring adequate lymph node harvest. Screening of the colonic pouch should be considered in long term survivors of bladder cancer and yoked to regular recommended colonoscopy screening for colon cancer. If a patient has any history or molecular profiling suggestive of a genetic disorder, genetic counseling should be considered.

Funding

This research did not receive any specific grant from funding agencies in the public, commercial, or not-for-profit sectors.

Declaration of competing interest

None.

References

1. Sinicrope FA. Lynch syndrome- associated colorectal cancer. *N Engl J Med.* 2018;379:764–773.
2. van der Post RS, Kiemeneij LA, Ligtenberg MJ, et al. Risk of urothelial bladder cancer in Lynch syndrome is increased, particular among MSH2 mutations carriers. *J Med Genet.* 2010;47(7):464–470.
3. Bell MA, Wright EJ, Fang SH, Johnson MH, Sopko NA. Management of advanced adenocarcinoma in Indiana Pouch urinary diversion. *Urology Case Reports.* 2018;17:53–55.
4. Lisle D, Cataldo P, Bibawi SE, Wood M. Colonic adenocarcinoma occurring in an Indiana pouch: report of a case and review of the literature. *Dis Colon Rectum.* 2009;43:864–867.
5. Yoshiko S, Ishikawa W, Hirai S, et al. A case of colonic adenocarcinoma incidentally occurring in an Indiana Pouch. *Hinyokika Kiyo.* 2013;59(8):531–534.