

Serial swept source optical coherence tomography of a cotton wool spot following SARS CoV2 infection

Mauli Shah, Jyotirmay Biswas¹

A 33-year-old male presented with history of blurring of vision in the left eye for two months. He was seen by the local ophthalmologist and diagnosed as nongranulomatous anterior uveitis in the left eye with normal fundus. He had history of fever 20 days back and was diagnosed positive for COVID-19 by RT-PCR. He presented with acute anterior uveitis in the left eye. Fundus examination revealed a cotton wool spot close to the fovea, which was confirmed by swept-source optical coherence tomography (SS-OCT) of the macula. The patient after two months' follow-up showed resolution of the cotton wool spot, which was confirmed by SS-OCT. Our case indicates that cotton wool spot can be an ocular manifestation of COVID-19 infection, and swept-source optical coherence tomography can precisely document the resolution of the lesion.

Key words: ACE2 receptor, CD147, cotton wool spot, SARS-CoV2

The "2019 novel coronavirus" (2019-nCoV) is an enveloped, nonsegmented positive-sense RNA virus belonging to the beta-*Coronaviridae* family.^[1] It is associated with atypical pneumonia and acute respiratory distress syndrome with notable mortality rates.^[1] Various ocular manifestations such as conjunctivitis, central retinal vein occlusion (CRVO), central retinal artery occlusion (CRAO), cotton wool spots, microhemorrhages, paracentral acute middle maculopathy (PAMM), acute macular neuroretinopathy, reactivation of uveitis, orbital cellulitis, and mucormycosis have been reported post covid infection.^[2,3] We report here a case of cotton wool spot 14 days after COVID-19 infection.

Case Report

A 33-year-old male presented to the uvea department of a tertiary eye care center of South India with redness,

photophobia, and diminution of distant and near vision in left eye since 2 months. He was seen by an ophthalmologist and diagnosed with left-eye nongranulomatous anterior uveitis. Fundus was found to be normal at that time. Right eye was normal in all aspects. He was put on topical steroids, mydriatic and cycloplegic, elsewhere. He had history of fever 20 days prior to the visit to our center and was diagnosed positive for COVID-19 by RT-PCR from nasopharyngeal and oropharyngeal swabs. He was home quarantined for 14 days. Then, he was tested negative for COVID-19. At presentation, his best-corrected visual acuity (BCVA) in both eyes was 6/6, N6. On slit-lamp examination, the right eye was quiet. There was aqueous flare 2+ and cells 2+ in the left eye. On fundus examination, there was only a single cotton wool spot seen just below optic disc inferonasal to fovea [Fig. 1a] Fundus fluorescein angiography (FFA) did not show any signs of vasculitis except the area of focal hypofluorescence corresponding to cotton wool spot [Fig. 2]. Swept-source optical coherence tomography (SS-OCT) of the left eye through the cotton wool spot showed intraretinal hyperreflective echoes causing shadowing [Fig. 1b]. Systemic workup for vasculitic and nonvasculitic causes for soft exudates, including anti-ds DNA antibody, blood pressure, complete blood count, erythrocyte sedimentation rate, serum homocysteine, random blood sugar, serum lipid profile, and HIV, was unremarkable. The patient was diagnosed with a cotton wool spot in the left eye secondary to SARS-CoV2 infection. He was put on topical steroid, cycloplegic agent, and was reviewed after a month. Left eye fundus photo and SS-OCT showed a reduction in the size of the cotton wool spot [Fig. 1c]. After 2 months of follow-up, the cotton wool spot disappeared. This was confirmed by repeat SS-OCT [Fig. 1d]. Moreover, there was complete resolution of anterior uveitis too.

Discussion

Our case showed cotton wool spot can be a manifestation of COVID-19 infection. Cotton wool spots are thought to represent axoplasmic debris at the level of retinal ganglion cell axons resulting from axoplasmic flow interruption due to vascular or mechanical causes.^[4] The exact pathophysiological mechanism of SARS-CoV2 remains unknown, but as viruses such CMV, HIV, and Dengue are known to cause retinal lesions, its potentially damaging effect on the retina has been widely suspected.

The most common mechanism until now for cellular infection by SARS-CoV-2 is the binding of the viral spike protein to the cellular angiotensin-converting enzyme 2 (ACE2), with serine protease TMPRSS2 promoting spike protein priming.^[5] Although ACE2 is expressed in the rat retina, mostly in the inner nuclear layer,^[6] a recent study reported low expression of ACE2 in human retinal cells.^[7] Notwithstanding

Access this article online	
Quick Response Code:	Website: www.ijo.in
	DOI: 10.4103/ijo.IJO_947_21

Department of Uvea, Medical Research Foundation, Sankara Nethralaya, ¹Department of Uveitis and Ocular Pathology, Sankara Nethralaya, Chennai, Tamil Nadu, India

Correspondence to: Dr. Jyotirmay Biswas, Director of Uveitis and Ocular Pathology Department, Sankara Nethralaya, 41, College Road, Nungambakkam, Chennai - 600 006, Tamil Nadu, India. E-mail: drjb@snmail.org

Received: 21-Apr-2021

Revision: 17-Aug-2021

Accepted: 30-Aug-2021

Published: 25-Sep-2021

This is an open access journal, and articles are distributed under the terms of the Creative Commons Attribution-NonCommercial-ShareAlike 4.0 License, which allows others to remix, tweak, and build upon the work non-commercially, as long as appropriate credit is given and the new creations are licensed under the identical terms.

For reprints contact: WKHLRPMedknow_reprints@wolterskluwer.com

Cite this article as: Shah M, Biswas J. Serial swept source optical coherence tomography of a cotton wool spot following SARS CoV2 infection. Indian J Ophthalmol 2021;69:2867-8.

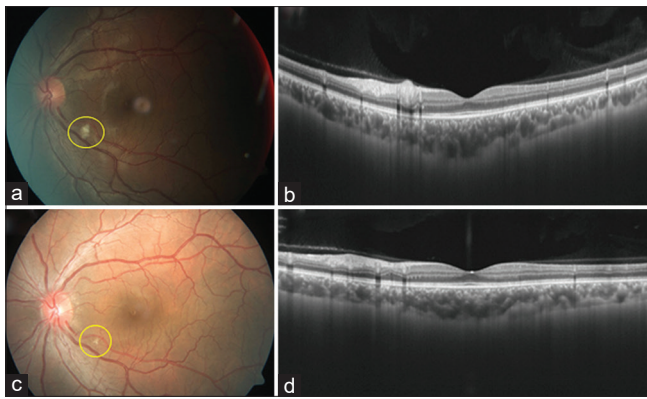


Figure 1: (a) Left-eye fundus photograph showing a single cotton wool spot. (b) Swept-source optical coherence tomography (SS-OCT) of the left eye showing intraretinal hyperreflective echoes of the cotton wool spot at the time of presentation. (c) Disappearance of the cotton wool spot on the fundus photograph. (d) Swept-source OCT showing resolution of the cotton wool spot at 2 months of follow-up

this, transmembrane glycoprotein CD147 has been described as another possible receptor for SARS-CoV-2 entry into host cells.^[8] In contrast to ACE2, CD147 has been detected at moderate-to-high levels in all cell types of the human retina.^[7] Therefore, even though ACE2/TMPRSS2 retinal expression may be low, CD147 provides a possible mechanism for SARS-CoV-2 entry into retinal cells.

Various ocular manifestations have been associated with COVID-19, the most common being conjunctivitis seen in 0.8% of patients.^[9] Marinho *et al.* described retinal findings, which include subtle cotton wool spots and microhemorrhages associated with COVID-19.^[3] Markan *et al.*^[10] reported longitudinal analysis of cotton wool spots in COVID-19 with high-resolution spectral-domain optical coherence tomography and optical coherence tomography angiography. The primary cellular receptor for the entry of SARS-CoV-2 is the angiotensin-converting enzyme 2 (ACE2), which has been detected in the aqueous humor and the retina in humans.^[11] Casagrande *et al.*^[11] evaluated retinal biopsy samples of 14 eyes of COVID-19 patients and demonstrated viral-RNA of SARS-CoV-2 in three of them. Based on current knowledge about the disease and its pathogenesis, the cotton wool spot in our case could be because of direct involvement of the retina by viral particles.

Conclusion

Our case indicates that cotton wool spot can be an ocular manifestation due to COVID-19 infection and swept-source OCT can serially evaluate its precise resolution.

Declaration of patient consent

The authors certify that they have obtained all appropriate patient consent forms. In the form, the patient(s) has/have given his/her/their consent for his/her/their images and other clinical information to be reported in the journal. The patients understand that their names and initials will not be published and due efforts will be made to conceal their identity, but anonymity cannot be guaranteed.

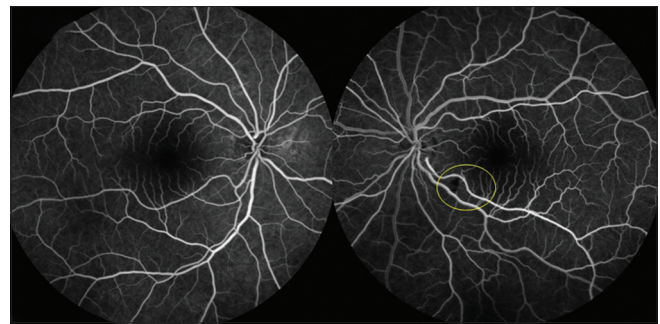


Figure 2: Arteriovenous phase of FFA showing hypofluorescent area in the left eye corresponding to the cotton wool spot

Financial support and sponsorship

Nil.

Conflicts of interest

There are no conflicts of interest.

References

- Lai CC, Shih TP, Ko WC, Tang HJ, Hsueh PR. Severe acute respiratory syndrome coronavirus 2 (SARS-CoV-2) and coronavirus disease-2019 (COVID-19): The epidemic and the challenges. *Int J Antimicrob Agents* 2020;55:105924. doi: 10.1016/j.ijantimicag. 2020.105924.
- Sen M, Honavar SG, Sharma N, Sachdev MS. COVID-19 and eye: A review of ophthalmic manifestations of COVID-19. *Indian J Ophthalmol* 2021;69:488-509.
- Marinho PM, Marcos AA, Romano AC, Nascimento H, Belfort R Jr. Retinal findings in patients with COVID-19. *Lancet* 2020;395:1610.
- McLeod D, Marshall J, Kohner EM, Bird AC. The role of axoplasmic transport in the pathogenesis of retinal cotton-wool spots. *Br J Ophthalmol* 1977;61:177-91.
- Hoffmann M, Kleine-Weber H, Schroeder S, Krüger N, Herrler T, Erichsen S, *et al.* SARS-CoV-2 cell entry depends on ACE2 and TMPRSS2 and is blocked by a clinically proven protease inhibitor. *Cell* 2020;181:271-80.
- Tikellis C, Johnston CI, Forbes JM, Burns WC, Thomas MC, Lew RA, *et al.* Identification of angiotensin converting enzyme 2 in the rodent retina. *Curr Eye Res* 2004;29:419-27.
- Hamashima K, Gautam P, Lau KA, Khiong CW, Blenkinsop TA, Li H, *et al.* Potential modes of COVID-19 transmission from human eye revealed by single-cell atlas. *BioRxiv* 2020. doi: 10.1101/2020.05.09.085613.
- Wang K, Chen W, Zhou YS, Lian JQ, Zhang Z, Du P, *et al.* SARS-CoV-2 invades host cells via a novel route: CD147-spike protein. *BioRxiv* 2020. doi: 10.1101/2020.03.14.988345.
- Guan WJ, Ni ZY, Hu Y, Liang WH, Ou CQ, He JX, *et al.* Clinical characteristics of coronavirus disease 2019 in China. *N Engl J Med* 2020;382:1708-20.
- Markan A, Bansal R, Gautam N, Ahuja C, Agarwal A, Katoch D, *et al.* Longitudinal analysis of cotton wool spots in COVID-19 with high-resolution spectral domain optical coherence tomography and optical coherence tomography angiography. *Clin Exp Ophthalmol* 2021;49:392-5.
- Casagrande M, Fitzek A, Püschel K, Aleshcheva G, Schultheiss HP, Berneking L, *et al.* Detection of SARS-CoV-2 in human retinal biopsies of deceased COVID-19 patients. *Ocul Immunol Inflamm* 2020;28:721-5.