

# Single miniplate osteosynthesis in angle fracture

Departments of Oral and Maxillofacial Surgery, C.S.M. Medical University (Erstwhile K.G. Medical College)  
\*Dentistry, Era Medical College, Lucknow, India

R. K. Singh, U. S. Pal, Amiya Agrawal<sup>1</sup>, Geeta Singh

## ABSTRACT

**Aim:** The present study was designed to study the feasibility of single miniplate osteosynthesis in the fracture of angle of mandible. **Materials and Methods:** in this study 110 patient were included and treated with single miniplate osteosynthesis at upper border along champy’s line of osteosynthesis. **Results:** All the cases were treated successfully, common complications which we have observed in this study, cosmetic disfigurement, delayed union, infection, wound dehiscence and paresthesia. **Conclusion:** Single miniplate fixation in unfavorable fracture is questionable and hence these fracture require some alternative method (locking plate, etc.) for fixation.

### Address for correspondence:

Ms. Akansha Singh,  
BDS IInd Year Student,  
Carrier Dental College,  
Lucknow, India.  
E-mail: rksingh\_9@rediffmail.com

**Key words:** Fixation, mandible fracture, angle region, single miniplate

## INTRODUCTION

Mandibular fractures make 80% of all facial trauma and in 20-30% cases the fracture occurs in the site of the angle. Certain structural and functional peculiarities-thinner compact plate, shape changes during life and frequent impacted or partially erupted teeth, bilateral muscle cover and endosseous and extra osseous blood circulation- condition the peculiarities of the treatment of fracture. Various treatment methods have been proposed for the treatment of mandibular angle fracture. The present study was aim to determine the effectiveness and the advantages of non compression miniplate osteosynthesis at upper border of mandible along champy’s lines of osteosynthesis.

other hospitals for specialized treatment between the period Jan 2008 and July 2009 at this center. Patients detailed history including age, sex, number and location of fractures, time between trauma and surgery were recorded. Ninety-eight (98) were men and 52 were women with a mean age of 29 and 26 years, respectively [Table 1]. Patients were operated under local anesthesia/general anesthesia by open reduction with single miniplate fixation with MMF. Data related to the clinical follow-up of wound, occlusion and suture removal, paresthesia and esthetics and radiological observations were recorded at regular intervals upto 3 months. Road traffic accidents (70%), assault (12%), fall (11.6%), gunshot injury (3%) and sports (0.3%) were responsible for most of the mandibular injuries. Adekeye *et al* (1980) reported 76% and Ellis *et al*,<sup>[1,2]</sup> reported only 15% with vehicular accidents. This difference in etiological factors may be explained by the environmental and social characteristics of the locality under study.

## MATERIALS AND METHODS

Present study included 150 patients of maxillofacial injuries either reported to trauma center of C.S.M. Medical University, Lucknow or were referred from

There were 92 (61%) fractures of the Mandible associated with Middle third, 36(24%) isolated mandibular fractures only and 22 (15%) isolated middle third region fractures only [Table 2]. All the 128 cases of fracture mandibles have total 175 fracture anatomical sites The incidence of mandibular fractures anatomical location wise were as condylar fractures 44 (25%), coronoid process 02 (1%) and fracture of the ramus 3 (2%), fracture of the angle 51(29%), body fractures 40 (23%) and symphysis and parasymphysis 30 (17%) [Table 3]. All the 51 (29%) patients who had participated in this

Access this article online	
<b>Quick Response Code:</b> 	<b>Website:</b> <a href="http://www.njms.in">www.njms.in</a>
	<b>DOI:</b> 10.4103/0975-5950.85853

study, of the mandibular angle fractures were treated with single noncompression miniplate at upper border along Champy's line of osteosynthesis.

## RESULTS

Out of 150 patients of pan facial trauma only 36 patients [Table 4] had isolated mandibular angle fracture, Majority of the patients referred to maxillofacial surgery OPD after neurosurgery clearance, postorthopedics treatment. Patients usually operated (under LA/GA) for angle fracture average 2-7 days postinjury. Sometime further 3-5 more days delays definitive treatment due to associated injuries. Patients were treated intraoral open reduction and 2.0 mm noncompression miniplate fixation at superior border (Champy's technique) and supplemented with MMF for 7-14 days.

## DISCUSSION

Fracture of the mandibular condyle is the commonest site for mandibular fracture, the angle fracture is the most frequent site when only one fracture is present (Ellis, Moos and El Attar,<sup>[1]</sup> Haugh *et al.*).<sup>[3]</sup> Seat belt law have resulted in a dramatic decrease in injury in general and severe injury in particular (Thomas 1990), similar trend has been reflected in the incidence of facial injury. Ewers

**Table 1: Sex distribution (n = 150)**

Sex	No. of cases	%
Male	98	65
Female	52	35

**Table 2: Incidence of fracture (n = 150)**

Type of fracture	No. of cases	%
Fracture of mandible associated with midface fracture	92	61
Fracture mandible isolated	36	24
Middle third facial fractures isolated	22	15

**Table 3: Anatomical distribution of mandibular fractures**

Anatomical location	No. of cases	%
Subcondylar	44	25
Coronoid process	2	1
Ramus	3	2
Angle region	51	29
Body region	40	23
Parasymphysis region	30	17
Alveolar type	5	3

**Table 4: Fracture distribution (n = 51)**

Location of fracture	No of cases
Isolated angle region	36
Fracture mandibular angle and other region	16

and Harle (1985) quote the first description of mandibular fracture fixation using plate and screws by Hausmann in 1886. There is still debate in the management of angle fracture about the convenience of traditional treatment with MMF versus surgical treatment.

Spiessl and Schroll,<sup>[4]</sup> described a plate-fixation system which was applied to the lower border of the mandible, the biomechanically most unfavorable site, although used dynamic compression plate and bicortical screws which resulted in rigid fixation to the fracture segments. The AO/ASIF recommends that sufficient internal fixation hardware be applied to resist the maximum forces of mastication, and to restore the compression and tension trajectories by the application of two compression plates, one along the superior and one along the inferior margin of the buccal cortex but to malunion and malocclusion. AO reconstruction plate should be used in cases of infected and comminuted fractures or bone loss and in oblique fracture also. These plates are thicker stronger and available in 6-24 holes length.<sup>[5]</sup>

In 1973, Michelet *et al.*,<sup>[6]</sup> described the treatment of mandibular fracture using small, easily bendable noncompression miniplates placed transorally and anchored with monocortical screws. These techniques contradicted the AO and Luhr's emphasis on compression and absolute rigidity. Champy later performed a series of experiments with miniplate that delineated "ideal lines of osteosynthesis" within the mandible. Plates placed along these lines were thought to provide optimal fixation and stability [Figure 1]. Ideal plate placement for angle fractures was along the superior border of the mandible above or just below the superior oblique ridge. Because these plates were small and monocortical screws, placement was possible without damaging the tooth roots [Figure 2]. Champy states that this miniplate system also gives sufficient support and stability to the bone fragments to allow immediate function Subsequent clinical studies corroborated the effectiveness of the Champy technique. Schierle *et al.*,<sup>[5]</sup> reported that two-plate fixation may not offer advantages over single-plate fixation in general. However, individual fracture constellations may benefit from variation in plate(s) localization

In the present study 8 out of 51 cases (16%) reported postoperative infection; this observation is probably due to delay in treatment as already mentioned that patients were treated as secondary referrals after postorthopedic treatment and neurosurgical clearance with a mean delay of 2-7 days [Table 5]. Another reason to this finding may also be attributed to the poor oral hygiene due to stasis of saliva owing to MMF. Other causes that may be reasoned are strong distractive forces at the mandibular angle region and concomitant fractures at other sites of mandible both leading to instability of so called

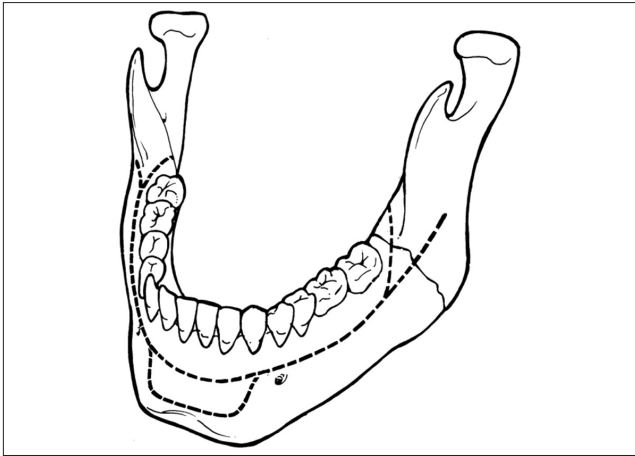


Figure 1: Champy's line of osteosynthesis

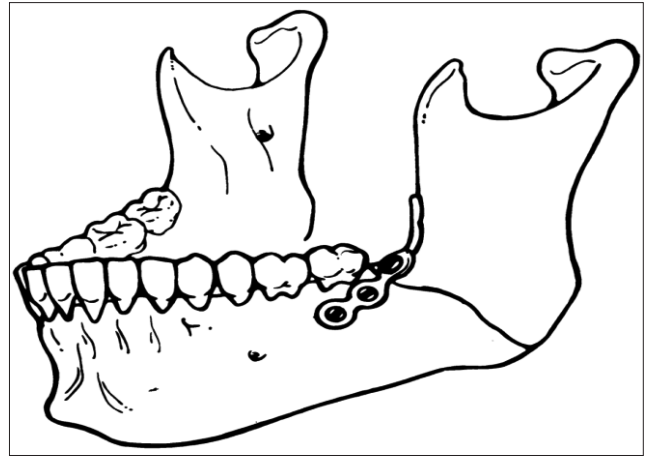


Figure 2: Champy technique-Single miniplate placement on superior border of an angle region

**Table 5: Complications associated with methods of fixation (n = 51)**

Complications	ORIF (single plate at angle region)
Infection	8
Delayed union	4
Wound dehiscence	6
Malocclusion	4
Paresthesia	5
Disfigurement (At lower border)	12

ORIF-Open reduction and internal fixation

attempted reduction and fixation of fracture fragments and presence of impacted/partially erupted tooth. Our results are in corroboration with other studies, quoted as follows Fracture of the angle are associated with the highest incidence of postsurgical infection of all mandibular fractures reported by Lizuka and Lindqvist.<sup>[7]</sup> This may be due to the biomechanics of mandibular function. It is the angle region where the horizontal and vertical rami of the mandible of the mandible joint and where the powerful elevator muscles attached to the ramus transfer their force to the body of the mandible. This creates great demands of fixation if rigidity under functional loads is to be maintained. The forces that must be countered in fracture at the mandibular angle have been derived from maximum voluntary bite force measurements, which in a healthy adult male may be in order of 50 kilo pounds (kp).

Ellis *et al.*,<sup>[8]</sup> examined various treatments modalities for angle fractures. They showed a significantly higher complication rate using compression plates on both mandibular borders intraorally in comparison to the Champy technique. Intraoral application of larger plates appear to increase complication rates. Thirteen percent rate of infection using a solitary lag screw (Ellis and Ghali)<sup>[9]</sup> and a 17% rate of infection when the fracture was treated by MMF with or without placement of a positional wire or plate. Lizuka *et al.*,<sup>[7]</sup> also noted infection

as an important complication and suggested that it can be reduced by experience of the operator. Anderson and Alpert (1992) observed that infection could be avoided by avoiding a treatment delay. The effects of a tooth in the fracture line as a cause of infection can be minimized by preoperative antibiotic therapy.

Ezsias and Sugar (1994) reported a high incidence of 18 and 25% infection with miniplate fixation at the angle. Kuriakose *et al.*,<sup>[10]</sup> reported a better treatment outcome for angle and comminuted fractures with rigid plates. Andrew JL. *et al.*,<sup>[11]</sup> published results 110 of 127 potential responses were received (87%). Among 104 surgeons who treated mandible fractures, 86 (83%) treat more than 10 mandibular fractures per year the preferred techniques for simple, non comminuted mandibular angle fractures in this group were: single miniplate on the superior border (Champy technique) with or without arch bars (44 surgeons, 51%); tension band plate on the superior border and nonlocking, bicortical screw plate on the inferior border (11 surgeons, 13%); dual miniplates (nine surgeons, 10%); a locking screw plate on the inferior border only (six surgeons, 7%), and three-dimensional plates (five surgeons, 6%). A single miniplate on the superior border of the mandible has become the preferred method of treatment among AO faculty. When using large, inferiorly based plates more surgeons are now favoring neutral rather than eccentric screw placement. Intraoperative MMF is not considered mandatory by some surgeon under certain circumstances. Barry CP *et al.*,<sup>[12]</sup> presented 50 patients of isolated angle fractures treated with superior border plating and reported 12% experienced complications requiring plate removal, 8% patients experienced superficial soft tissue infections associated with bone plate, treated with oral antibiotics, 2% experienced plated exposure and a further patient 2% presented with a fractured bone plate. All six (12%) patients were treated by bone plate removal under general

anesthesia. Permanent inferior alveolar nerve sensory deficit (<12 months) was present in 8%. Nineteen percent patients with normal postinjury/preoperative sensory function had a postoperative sensory deficit. The incidence of complications is one of the criteria of the evaluation of the efficacy of treatment. Our observations have shown the following one or other type of complications (dictated in terms of infection, delayed healing/union, wound dehiscence, malocclusion, paresthesia and disfigurement) delayed union in four out of 51 cases (8%) owing to instability of fracture fixation. Wound dehiscence was reported in six out of 51 cases (12%) that too due to infection. Malocclusion in four out of 51 cases (8%) were again attributable to instability because of strong distractive forces overcome with weak osteosynthesis fixation device. Paresthesia was reported in five out of 51 cases (9.8%) reason may again be instability and distraction at the fracture site leading to infection inflammation causing further nerve injury. As an individual complication disfigurement ranked highest with 12 out of 51 cases (23%) Possible explanation may be that when the fixation of fracture at angle region was done using single miniplate at superior border then flaring at lower border at angle region and increase in intergonial distance occurs which on subsequent healing/union results into disfigurement. Gutwald R<sup>[13]</sup> studied the comparison of the different osteosynthesis techniques showed that in the case of Miniplate fixation torsion and gapping of the bone fragments occurred following plate application and screw tightening when the plates were pressed onto the bone, so last incongruence's between bone surface and plate were transferred to the mobile bone fragments resulting in more extended gaps and torsion. This was only observed to a much lesser extent with the Mini-Locking-System due to the fixation principle avoiding pressure to the bone. During functional loading the Mini-Locking-System showed also a significant higher stability in comparison to conventional miniplates In literature regarding cases of mandibular angle fractures, the incidence of complications varies: Feller *et al*, state that healing complications occur in 2.3% of cases, according to Dhariwal *et al*,<sup>[14]</sup> such percentage is 7.3%, Lamphier *et al.* – 13.3%, Atanasov 25.2%, etc. Such huge difference between the findings presented by different authors exists because some authors attribute bleeding, hematomas, infections, neural damage and postoperative calluses to complications, while others think that complications include fracture fragments adhesion failure, damage to the lower alveolar nerve, osteomyelitis and malocclusion. Osteomyelitis ranks

among the most common and most severe complications of fracture healing. According to the findings presented by Fox and Kellman,<sup>[15]</sup> inflammatory complications in cases of mandibular angle fractures treated with two monocortical miniplates fixation amount to 2.9%, which is comparable to or better than the infection rate reported with the single miniplate fixation technique in other studies and according to Ellis<sup>[1,2,16]</sup> – to 15.8%.

## REFERENCES

1. Ellis E 3<sup>rd</sup>, Moos KF, el-Attar A. Ten years of mandibular fractures: An analysis of 2,137 cases. *Oral Surg Oral Med Oral Pathol* 1985;59:120-9.
2. Ellis E 3<sup>rd</sup>, Walker LR. Treatment of mandibular angle fractures using one noncompression miniplate. *J Oral Maxillofac Surg* 1996;54:864-71.
3. Haug RH, Prather J, Indresano AT. An epidemiological survey of facial fractures and concomitant injuries. *J Oral Maxillofac Surg* 1990;48:926-32.
4. Spiessel B. Rigid internal fixation of fractures of the lower jaw. *Reconstr Surg Traumatol* 1972;13:124-40.
5. Schierle HP, Schmelzeisen R, Rahn B, Pytlik C. One- or two-plate fixation of mandibular angle fractures? *J Craniomaxillofac Surg* 1997;25:162-8.
6. Champy M, Loddé JP, Schmitt R, Jaeger JH, Muster D. Mandibular osteosynthesis by miniature screwed plates via a buccal approach. *J Maxillofac Surg* 1978;6:14-21.
7. Lizuka T, Lindqvist C. Rigid internal fixation of fractures in the angular region of the mandible: An analysis of factors contributing to different complications. *Plast Reconstr Surg* 1993;91:265-71.
8. Ellis E 3<sup>rd</sup>. Treatment methods for fractures of the mandibular angle. *Int J Oral Maxillofac Surg* 1999;28:243-52.
9. Ellis E 3<sup>rd</sup>, Ghali GE. Lag screw fixation of the mandibular angle fracture. *J Oral Maxillofac Surg* 1991;49:234-43.
10. Kuriakose MA, Fardy M, Sirikumara M, Patton DW, Sugar AW. A comparative review of 266 mandibular fractures with internal fixation using rigid (AO/ASIF) plates or miniplates. *Br J Oral Maxillofac Surg* 1996;34:315-21.
11. Andrew JL. Gear treatment modalities for mandibular angle fractures. *J Oral Maxillofac Surg* 2005;63:655-63.
12. Barry CP, Keams GJ. Superior border plating technique in the management of isolated mandibular angle fractures: A retrospective study of 50 consecutive patients. *J Oral Maxillofac Surg* 2007;65:1544-9.
13. Gutwald R, Brian Alpert1, Schmelzeisen R. Principles and stability of Locking plates. Presented at the 67th Meeting of the Keio Medical Society in Tokyo, Jul 15, 2002.
14. Dhariwal DK, Gibbons AJ, Murphy M, Llewelyn J, Gregory MC. A two year review of the treatment and complications of mandibular angle fractures. *J R Army Med Corps* 2002;148:115-7.
15. Fox AJ, Kellman RM. Mandibular angle fractures: Two-miniplate fixation and complications. *Arch Facial Plast Surg* 2003;5:464-9.
16. Passeri LA, Ellis E 3<sup>rd</sup>, Sinn DP. Relationship of substance abuse complications with mandibular fractures. *J Oral Maxillofac Surg* 1993;51:22-5.

**How to cite this article:** Singh RK, Pal US, Agrawal A, Singh G. Single miniplate osteosynthesis in angle fracture. *Natl J Maxillofac Surg* 2011;2:47-50.

**Source of Support:** Nil. **Conflict of Interest:** None declared.