

Collision nodal metastasis of bladder cancer and melanoma: The first reported case and literature review

Francesca Sanguedolce^{a*}, Francesco Troiano^b, Giovanni Musci^a, Magda Zanelli^c, Maurizio Zizzo^{d,e}, Stefano Ascani^f, Giuseppe Carrieri^b, Luigi Cormio^b

^aDepartment of Pathology, University Hospital, Foggia, Italy; ^bDepartment of Urology and Renal Transplantation, University of Foggia, Foggia, Italy; ^cPathology Unit, Azienda Unità Sanitaria Locale-IRCCS di Reggio Emilia, Reggio Emilia, Italy; ^dSurgical Oncology Unit, Azienda Unità Sanitaria Locale-IRCCS di Reggio Emilia, Reggio Emilia, Italy; ^eClinical and Experimental Medicine, University of Modena and Reggio Emilia, Modena, Italy; ^fPathology Unit, Azienda Ospedaliera Santa Maria di Terni, University of Perugia, Terni, Italy

Abstract

Collision metastasis is a rare phenomenon of concomitant localization of 2 or more different tumors in the same lymph node. In most cases, primary malignancies are synchronous carcinomas arising in the same organ or area of the body. A 82-year-old man presented with hematuria and acute renal failure; he had undergone dermatological consultation ten months ago because of a large deep brown skin lesion in his dorso-lumbar region, which was not excised upon patient's request. He underwent radical cystectomy with extended pelvic lymphadenectomy due to nonpapillary high-grade urothelial carcinoma, with focal squamous features, infiltrating the bladder wall and prostate gland. In one left iliac lymph node, small foci of metastatic urothelial carcinoma (positive for P63 and CK34betaE12) were close to melanoma cells (positive for HMB45). The patient refused further treatment and died of metastatic disease 12 months after cystectomy. There is no specific clinical feature for nodal collision metastasis. A polymorphic histologic appearance poses the suspect, but immunohistochemical stains are needed to define the primary tumors. Collision metastases are thought to carry a poor prognosis. Their clinical relevance is linked to the fact that the patient faces 2 different metastatic tumors that may require specific multidisciplinary approach once diagnosed as metastatic. We present, to the best of our knowledge, the first case of collision nodal metastasis from bladder cancer and melanoma, and describe its clinical and histopathological characteristics to raise awareness on this rare occurrence, which portends a poorer prognosis than each single tumor.

Keywords: Bladder; Cancer; Collision tumor; Melanoma; Nodal metastasis

1. Introduction

A collision metastasis is defined as the concomitant localization of 2 or more different tumors in the same lymph node.^[1] This is a rare phenomenon, with only a few dozen cases having been reported in literature so far.^[1–21] In most cases, primary malignancies are both carcinomas arising in the same organ or area of the body, with 1 of the 2 primary tumors being often a thyroid carcinoma or adenocarcinoma of the prostate. Conversely, collision metastases from a primary bladder cancer are rare,^[1–3,9] and those involving melanoma cells are even rarer.^[10] To the best of our knowledge, herein, we describe the first case of collision nodal metastasis from bladder cancer and melanoma to a single lymph node, along with a brief literature review.

2. Case report

A 82-year-old man presented in October 2015 with hematuria and acute renal failure (serum creatinine 11.8mg/dL). His past medical history revealed only a previous coronary artery bypass graft in 2000.

Abdominal ultrasound pointed out a 4.5 cm lesion involving the bladder trigone, probably occluding both ureteral orifices given a grade II bilateral hydro-uretero-nephrosis. He was therefore scheduled for transurethral resection of the bladder tumor. A single large mass occluding both ureteral orifices was completely resected; by the end of the procedure, both ureteral orifices were widely open. Pathology revealed a high-grade muscle-invasive urothelial carcinoma. Twenty days after transurethral resection of the bladder tumor, serum creatinine had dropped down to 1.62mg/dL and he underwent staging thoraco-abdominal computed tomography, which revealed thickening of bladder wall at the level of the left ureteral trigone and multiple enlarged lymphnodes in the left iliac-obturator region, the larger measuring 14 mm in diameter (Fig. 1A). There was no evidence of distant metastases in the explored areas. Therefore, in November 2015, he underwent radical cystectomy, extended pelvic lymphadenectomy, and bilateral ureterocutaneostomy. Postoperative course was uneventful and the patient was discharged on 10th postoperative day with a serum creatinine of 1.88mg/dL.

The opened bladder contained a fungated and ulcerated mass involving the bladder trigone, not extending into the prostate, measuring 2.5 × 4 cm. Cut sections of the prostate demonstrated

*Corresponding Author: Francesca Sanguedolce, Department of Pathology, University Hospital, Viale Pinto 1, Foggia, 71121, Italy. E-mail address: fracdolce@hotmail.com (F. Sanguedolce).

Current Urology, (2022) 16, 3, 168–171

Received May 28, 2020; Accepted June 2, 2020.

<http://dx.doi.org/10.1097/CU9.0000000000000078>

Copyright © 2022 The Authors. Published by Wolters Kluwer Health, Inc. This is an open access article distributed under the terms of the Creative Commons Attribution-Non Commercial-No Derivatives License 4.0 (CCBY-NC-ND), where it is permissible to download and share the work provided it is properly cited. The work cannot be changed in any way or used commercially without permission from the journal.

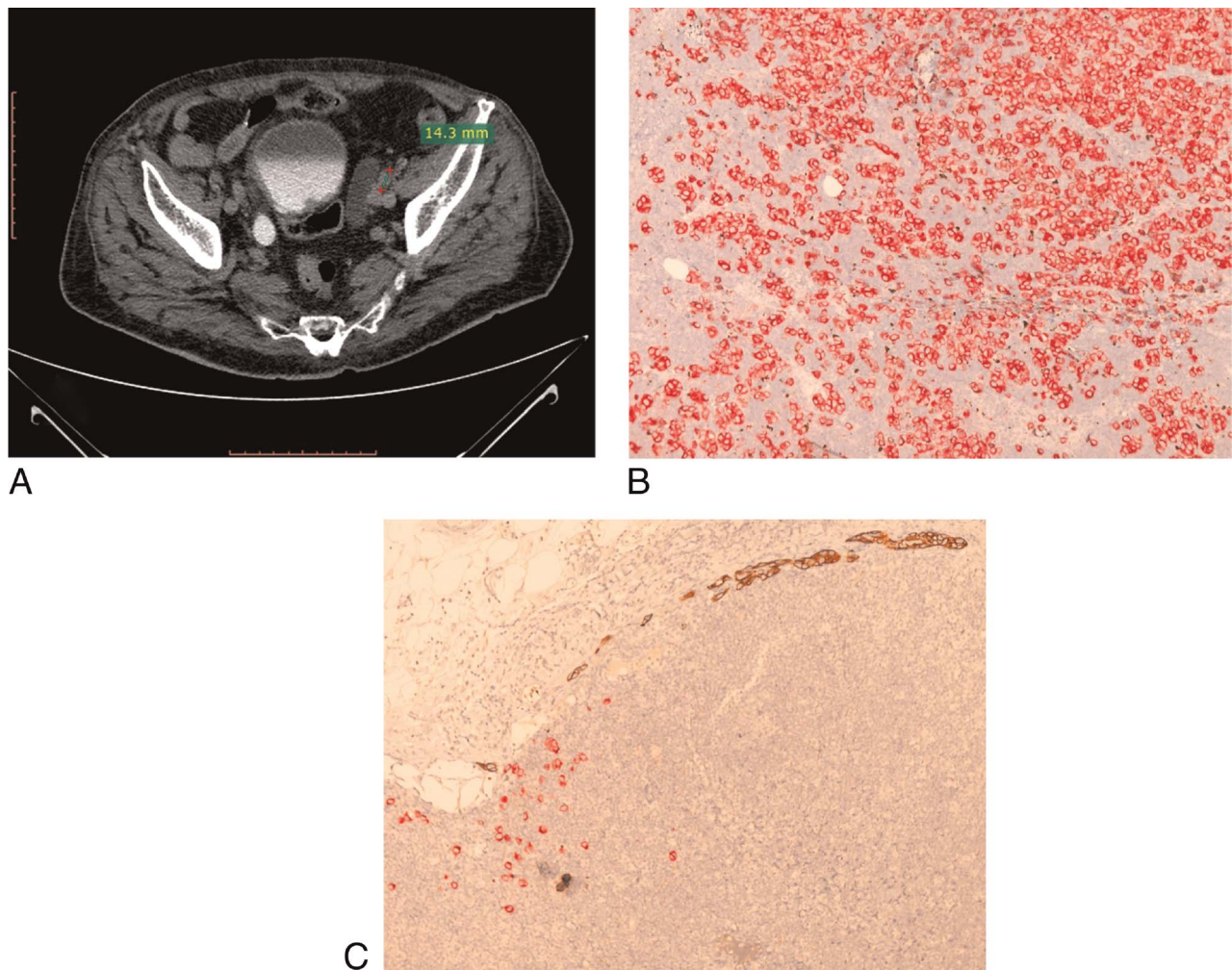


Figure 1. (A) Abdominal computed tomography scanning showing thickening of bladder wall at the level of the left ureteral trigone and multiple enlarged lymphnodes in the left iliac-obturator region, the larger measuring 14 mm in diameter. (B) Immunohistochemistry: Massive nodal metastasis from melanoma (red signal, Fast Red chromogen) ($\times 100$ magnification). (C) Immunohistochemistry: Concomitant metastasis in the same lymph node, featuring melanoma cells (red signal, Fast Red chromogen) along with bladder cancer cells (brown signal, DAB chromogen) ($\times 100$ magnification).

bilateral, symmetrical enlargement. Pathology showed a non-papillary high-grade urothelial carcinoma, with focal squamous features, infiltrating the detrusor muscle and extending into the prostate gland (pT4 according to the 2010 7th edition of the TNM staging system). Lymphovascular invasion was not identified. In one left iliac lymph node, the architecture was largely replaced with metastatic tumor composed of large sheets of pleomorphic cells with eosinophilic cytoplasm, thus suggestive of melanoma origin (Fig. 1B). The same cells were identified in another lymph node, whereby we identified also small foci of metastatic urothelial carcinoma, some of them close to the melanoma cells. Upon suspicion of a collision metastasis in the above-mentioned lymph node, immunohistochemistry was carried out. Urothelial cancer cells exhibited strong staining for P63 and CK34betaE12, while melanoma cells were positive for HMB45 (Fig. 1C). On further anamnestic investigation the patient revealed that on January 2015, he had undergone dermatological consultation because of a deep brown skin lesion in his dorso-lumbar region, approximately 8.2 cm in width, with irregular borders (Fig. 2). Though complete surgical excision was recommended, he had chosen not to undergo such procedure, claiming a slight reduction in lesion size over the following few months.

The patient refused further treatment for his 2 metastatic tumors; he died of metastatic disease 12 months after cystectomy.

3. Discussion

The collision phenomenon in a metastatic site has been described as the presence of coexistent but histologically distinct neoplasms from topographically separate primaries, in the absence of any area showing a transitional pattern that suggests a structure intermediate between the 2 tumor types.^[22] Such definition was subsequently refined by Spagnolo and Heenan,^[23] who highlighted the presence of 2 distinct, topographically separate, sites of origin for the 2 components, but allowed some transitional patterns to be seen in the area of collision. Actual criteria for collision tumors are: different cell origin and phenotype, independent topographical site of origin, lack of transitional morphological features between neoplasms,^[5,14,20] which are fulfilled in our case.

Gohji et al.^[3] stated they were able to delineate the different morphologies using hematoxylin-eosin alone; however, they could compare the histology of metastases to the primaries, as they were both known at the time of diagnosis, and the metastatic foci of the 2 primaries were clearly demarcated. Subsequent reports pointed out that the diagnosis of colliding tumor in a lymph node could be suspected on a morphologic basis in a patient known to have 2 synchronous tumors.^[1,5,8] However, as in our case, a clear diagnosis can be achieved only by proper immunohistochemical staining.^[7,10,12]

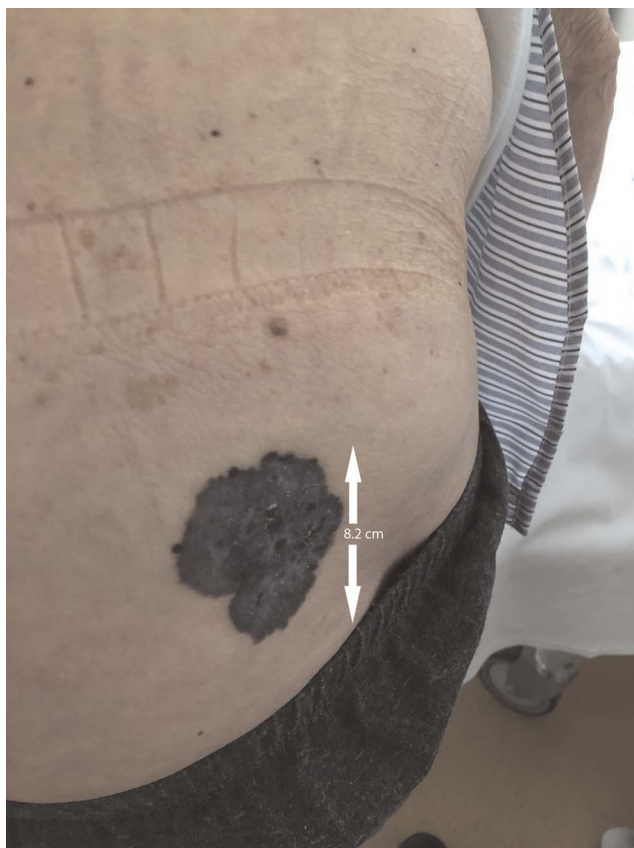

Figure 2. A deep brown skin lesion of the dorso-lumbar region, approximately 8.2 cm in width, with irregular borders, strongly suggestive for melanoma.

Possible explanations for collision metastases include: 1) involvement of carcinomas which are indolent and common (such as prostate cancer),^[5,8] their frequency and long clinical course without any overt clinical symptoms may allow time for second

malignancies to develop and metastasize to the same node; 2) an “accidental meeting” of two primary tumors^[9]; 3) a common tumorigenic stimulus triggering neoplastic transformation of both types of cells.^[4] In case of tumor-to-tumor metastasis, which is a form of collision tumor, it has been hypothesized that the presence of the first tumor alters the microenvironment, thus facilitating the development of the second adjacent tumor.^[9] This mechanism could apply to collision metastases as well. A novel interesting hypothesis involves the expression of chemokines by neoplastic cells; in their report of secondary breast carcinoma and neuroendocrine rectal carcinoma colliding in the same lymph node, Gasparinho et al.^[19] suggest that tumors featuring similar chemokines receptor profiles may migrate to specific lymph nodes or organs.

We performed a review of the 22 cases of nodal collision metastases described so far; articles reporting the concomitant presence of a metastatic tumor and lymphoproliferative disease in the same lymph node have been excluded, since this occurrence should rather be regarded as tumor-to-tumor metastasis. As shown in Table 1, most cases involve cervical or abdominal lymph nodes (9 out of 22 cases each), and at least one malignancy is a thyroid carcinoma or a prostate adenocarcinoma, respectively. According to Miyauchi et al.,^[20] a possible explanation is the slow growth and indolent clinical behavior of these 2 neoplasms, which are often diagnosed as occult or incidental/latent disease. There have been described only 4 cases of colliding secondary bladder cancer; all 4 patients underwent cystoprostatectomy for muscle-invasive bladder cancer, and in all cases one pelvic node contained neoplastic cells from both bladder and prostatic carcinoma. Interestingly, in 3 out of 4 cases, patients were unaware of the prostate cancer before surgery.

In the vast majority of cases, collision between solid tumors occurring in the same lymph node involves only epithelial tumors; one case of both metastatic melanoma and prostate adenocarcinoma detected has been reported so far.^[10] The collision metastasis was detected in an axillary sentinel lymph node biopsied for cutaneous melanoma, and the patient had a history of metastatic prostate adenocarcinoma. Conversely, in our case a clear diagnosis of melanoma was lacking before the detection of nodal metastases.

Table 1

Literature reports of collision metastases occurring in the same lymph node.

Author, year [Reference]	Age	Sex	Nodal site	Primary tumors	
Sughayer, 2009 ^[8]	63	F	Axillary	Serous papillary ovarian carcinoma	Ductal breast carcinoma
Saco, 2018 ^[10]	71	M	Axillary	Prostate adenocarcinoma	Melanoma
Pastolero, 1996 ^[4]	41	M	Cervical	Papillary thyroid carcinoma	Medullary thyroid carcinoma
Guelfucci, 2004 ^[11]	51	M	Cervical	Papillary thyroid carcinoma	Squamous tongue carcinoma
Elias da Cruz Perez, 2008 ^[12]	57	M	Cervical	Thyroid carcinoma	Squamous oral carcinoma
Lim, 2008 ^[13]	47	M	Cervical	Papillary thyroid carcinoma	Squamous tongue carcinoma
Mattioli, 2009 ^[14]	50	F	Cervical	Papillary thyroid carcinoma	Squamous cell carcinoma (unknown origin)
Sadat Alavi, 2011 ^[15]	32	M	Cervical	Papillary thyroid carcinoma	Medullary thyroid carcinoma
Zeng, 2012 ^[16]	49	F	Cervical	Papillary thyroid carcinoma	Ductal breast carcinoma
Alhanafy, 2016 ^[17]	73	F	Cervical	Papillary thyroid carcinoma	Squamous thyroid carcinoma
Xu, 2018 ^[18]	63	M	Cervical	Papillary thyroid carcinoma	Squamous tongue carcinoma
Gasparinho, 2011 ^[19]	55	F	Hilar	Neuroendocrine rectal carcinoma	Ductal breast carcinoma
Wade, 2004 ^[5] (1)	80	M	Mesenteric	Prostate adenocarcinoma	Colonic adenocarcinoma
Mourra, 2005 ^[6]	70	M	Mesorectal	Prostate adenocarcinoma	Rectal adenocarcinoma
Terada, 1993 ^[7]	83	M	Para-aortic	Prostate adenocarcinoma	Stomach adenocarcinoma
Ergen, 1995 ^[2]	67	M	Pelvic	Prostate adenocarcinoma	Urothelial bladder carcinoma
Gohji, 1997 ^[3]	78	M	Pelvic	Prostate adenocarcinoma	Squamous bladder carcinoma
Overstreet, 2001 ^[1]	67	M	Pelvic	Prostate adenocarcinoma	Urothelial bladder carcinoma
Bhavsar, 2012 ^[9]	83	M	Pelvic	Prostate adenocarcinoma	Urothelial bladder carcinoma
Wade, 2004 ^[5] (2)	61	M	Perirectal	Prostate adenocarcinoma	Colonic adenocarcinoma
Miyauchi, 2013 ^[20]	82	M	Perirectal	Prostate adenocarcinoma	Rectal adenocarcinoma
El-Gendy, 2008 ^[21]	51	F	Thoracic	Oesophageal adenocarcinoma	Ductal breast carcinoma

Independently of biological behavior and pathogenetic mechanism, collision metastases are thought to carry a poor prognosis probably due to the fact that patients face 2 different metastatic tumors.^[13] As a matter of fact, they are clinically relevant because the individual primary tumors may require different treatments once diagnosed as metastatic.

Our patient does not provide much information regarding prognosis as he refused further treatment for both malignancies.

Collision nodal metastasis is extremely rare and should be considered when a polymorphic histological appearance is presented in a patient suspected/known to have 2 or more malignant neoplasms. Proper immunohistochemical staining is of great aid to confirm the diagnosis. Though often considered to be merely an academic curiosity, collision metastases often involve urogenital cancers, therefore require expert multidisciplinary approach, as the patient actually faces 2 different metastatic tumors.

Acknowledgments

None.

Statement of ethics

According to our institutional regulations, a single case report with no patient's identifying information, neither a formal ethical approval nor the participants' consent is required. All procedures performed in study involving human participants were in accordance with the ethical standards of the institutional and national research committee and with the 1964 Helsinki declaration and its later amendments or comparable ethical standards.

Conflict of interest statement

The authors disclose no conflict of interest.

Funding source

None.

Author contributions

All authors contributed equally in this study.

References

- [1] Overstreet K, Haghghi P. Urothelial and prostate carcinoma metastasizing to the same lymph node: A case report and review of the literature. *Arch Pathol Lab Med* 2001;125(10):1354–1357.
- [2] Ergen A, Balbay MD, Irwin M, Torno R. Collision metastasis of bladder and prostate carcinoma to a single pelvic lymph node. *Int Urol Nephrol* 1995;27(6):743–745.
- [3] Gohji K, Nomi M, Kizaki T, Maruyama S, Morisue K, Fujii A. "Collision phenomenon" of prostate and bladder cancers in lymph node metastases. *Int J Urol* 1997;4(2):222–224.
- [4] Pastolero GC, Coire CI, Asa S.L. Concurrent medullary and papillary carcinomas of thyroid with lymph node metastases. A collision phenomenon. *Am J Surg Pathol* 1996;20(2):245–250.
- [5] Wade ZK, Shippey JE, Hamon GA, Smoak RL, Argani P, Allsbrook WC Jr. Collision metastasis of prostatic and colonic adenocarcinoma: Report of 2 cases. *Arch Pathol Lab Med* 2004;128(3):318–320.
- [6] Mourra N, Parc Y, McNamara D, Tiret E, Flejou JF, Parc R. Lymph node metastases of prostatic adenocarcinoma in the mesorectum in patients with adenocarcinoma or villous tumor of the rectum with collision phenomenon in a single lymph node: Report of five cases. *Dis Colon Rectum* 2005;48(2):384–389.
- [7] Terada T, Satoh Y, Aoki N, Hirayama R, Ishikawa Y, Hatakeyama S. The coexistence of cancer cells of different origin within the same lymph nodes. *Surg Radiol Anat* 1993;15(2):119–123.
- [8] Sughayer MA, Zakarneh L, Abu-Shakra R. Collision metastasis of breast and ovarian adenocarcinoma in axillary lymph nodes: A case report and review of the literature. *Pathol Oncol Res* 2009;15(3):423–427.
- [9] Bhavsar T, Liu J, Huang Y. Collision metastasis of urothelial and prostate carcinomas to the same lymph node: A case report and review of the literature. *J Med Case Rep* 2012;6:124.
- [10] Saco M, Zager J, Messina J. Metastatic melanoma and prostatic adenocarcinoma in the same sentinel lymph node. *Cutis* 2018;101(2): E1–E3.
- [11] Guelfucci B, Lussato D, Cammilleri S, Chrestian M, Zanaret M, Mundler O. Papillary thyroid and squamous cell carcinoma in the same radioguided sentinel lymph node. *Clin Nucl Med* 2004;29(4):268–269.
- [12] Elias da Cruz Perez D, Paes de Almeida O, de Abreu Alves F, Paulo Kowalski L. Metastases of well-differentiated thyroid and oral squamous cell carcinoma to the same neck lymph node. *Pathol Res Pract* 2008;204(2):143–145.
- [13] Lim YC, Kim WS, Choi EC. Collision metastasis of squamous carcinoma of the oral tongue and incidental thyroid papillary carcinoma to a single cervical lymph node. *Int J Oral Maxillofac Surg* 2008;37(5):494–496.
- [14] Mattioli F, Masoni F, Ponti G, et al. "Collision" metastasis from unknown primary squamous cell carcinoma and papillary micro-carcinoma of thyroid presenting as lateral cervical cystic mass. *Auris Nasus Larynx* 2009;36(3): 372–375.
- [15] Sadat Alavi M, Azarpira N. Medullary and papillary carcinoma of the thyroid gland occurring as a collision tumor with lymph node metastasis: A case report. *J Med Case Rep* 2011;5:590.
- [16] Zeng H, Liu C, Zeng YJ, Wang L, Chen GB, Shen XM. Collision metastasis of breast and thyroid carcinoma to a single cervical lymph node: Report of a case. *Surg Today* 2012;42(9):891–894.
- [17] Alhanafy AM, Al-Sharaky D, Abdou AG, Abdallah RA. Metastatic collision tumour (papillary thyroid carcinoma and squamous cell carcinoma) in cervical lymph nodes: An immunohistochemical analysis. *J Clin Diagn Res* 2016;10(2):ED11–ED13.
- [18] Xu YM, Gong ZJ, Wu HJ. Papillary thyroid carcinoma incidentally found in cervical lymph nodes during neck dissection for patients with tongue squamous cell carcinoma: A 3-case report and literature review. *J Oral Maxillofac Surg* 2018;76(11). 2454.e1–2454.e1e6.
- [19] Gasparinho MG, Morgado S, Fonseca R, Chaves P. Collision metastases of breast and rectal carcinoma: A possible role for chemokines receptors expression. *Pathol Oncol Res* 2012;18(3):729–732.
- [20] Miyauchi J, Asahara F, Matsui J. Collision lymph node metastasis of rectal and prostate adenocarcinomas. *Pathol Int* 2013;63(8): 425–2.
- [21] El-Gendy KA, Atkin GK, Brightwell RE, Richman P, Livingstone JI. Adjacent thoracic lymph node metastases originating from two separate primary cancers: Case report. *Int Semin Surg Oncol* 2008;5:22.
- [22] Dodge OG. Gastro-oesophageal carcinoma of mixed histological type. *J Pathol Bact* 1961;81:459–471.
- [23] Spagnolo DV, Heenan PJ. Collision carcinoma at the esophagogastric junction: Report of 2 cases. *Cancer* 1980;46(12):2702–2708.

How to cite this article: Sanguedolce F, Troiano F, Musci G, Zaneli M, Zizzo M, Ascani S, Carrieri G, Cormio L. Collision nodal metastasis of bladder cancer and melanoma: the first reported case and literature review. *Curr Urol* 2022;16(3):168–171. doi: 10.1097/CU9.0000000000000078