

[CASE REPORT]

Use of Proprotein Convertase Subtilisin/Kexin Type 9 Inhibitor to Treat Cholesterol Crystal Embolisms after Catheterization: A Report of Three Cases

Yusuke Tomoi, Yoshimitsu Soga, Kazuaki Imada, Kenji Kodama, Tomonori Katsuki, Seiichi Hiramori and Kenji Ando

Abstract:

Cholesterol crystal embolism (CCE) is a serious complication that occurs after cardiac and vascular procedures. CCE involves multiple organs, and the prognosis and renal function of patients is poor. Although the efficacy of steroid, statin, and low-density lipoprotein apheresis has been reported, no definitive treatment has been established. We herein report three consecutive cases treated with conventional steroid therapy with proprotein convertase subtilisin/kexin type 9 (PCSK9) inhibitor after catheterization. The renal function was preserved, steroid therapy was stopped, and wound healing of blue toes was achieved. PCSK9 inhibitor therapy was safe in the present patient and may be a potential treatment option for CCE.

Key words: cholesterol crystal embolism, anti-PCSK9 antibody, catheterization, renal failure

(Intern Med 61: 857-860, 2022)

(DOI: 10.2169/internalmedicine.8088-21)

Introduction

Cholesterol crystal embolism (CCE) develops when fragile, atheromatous aortic plaques rupture, releasing cholesterol crystals into the small renal arteries. CCE causes a systemic inflammatory response that leads to multi-organ dysfunction (1, 2). Indeed, CCE is recognized as a serious complication after cardiac and vascular catheterization (3). These catheterization procedures are less invasive than previous methods; thus, they have become widespread in our aging society.

Proprotein convertase subtilisin/kexin type 9 (PCSK9) inhibitor markedly reduces low-density lipoprotein (LDL) cholesterol levels, and it has been reported that PCSK9 inhibitor suppresses the incidence of future cardiovascular events (4). Although its pleiotropic role has not been fully elucidated, PCSK9 inhibitor has been shown to reduce inflammatory cytokines and promote atherosclerotic plaque regression (5).

We herein report three consecutive cases of CCE successfully treated with PCSK9 inhibitor. Of note, CCE from renal prognoses have resulted in poor life prognoses (6). Although

the efficacy of steroids, statins, iloprost, and LDL apheresis has been reported, a robust therapy for CCE has yet to be established (7-10).

Case Reports

Case 1

A 69-year-old woman had a history of hypertension, hyperlipidemia, and diabetes as well as a smoking habit. She underwent percutaneous coronary intervention for multivessel coronary disease via a radial artery approach. Ten weeks later, her renal function dropped from an estimated glomerular filtration rate (eGFR) of 65.9 mL/min/1.73 m² to 27.7 mL/min/1.73 m², as calculated by a modified version of the modification of diet in renal disease formula from the Japanese Society of Nephrology (11). Simultaneously, the patient experienced pain that revealed cyanosis of the toes and livedo reticularis in both legs (Table 1, Figure).

Laboratory data revealed eosinophilia (Table 2). As we could not deny the involvement of another renal disease, a skin biopsy was performed one week later and revealed a

Table 1. Clinical Features of and Course of Three Patients with Cholesterol Crystal Embolism.

	Case 1	Case 2	Case 3
Age (years)	70	77	70
Gender	Female	Male	Male
Risk factors	HTN, HLP, DM, smoking	HLP, DM, smoking	HTN, HLP, smoking
Cause of cholesterol crystal embolism	CAG PCI	AOG EVT	AOG EVT
Time interval* (week)	10	6	4
Symptoms			
Pain	Presence	Presence	Presence
Livedo reticularis	Presence	Presence	Presence
Acrocyanotic toes	Presence	Presence	Presence
Renal dysfunction	Presence	None	Presence
Biopsy	Skin	None	Skin
Medication			
PCSK9 inhibitor	Evolocumab 140 mg/2 weeks	Alirocumab 75 mg/2 weeks	Alirocumab 75 mg/2 weeks
Current PSL use	Stopped	Stopped	Stopped
PSL use duration (week)	52	24	51
Current PCSK9 inhibitor use	Continued	Stopped	Stopped
PCSK9 inhibitor use duration (week)	Even today	43	10
Wound healing	Complete	Complete	Complete with bilateral toe amputation
Wound healing duration (week)	48	47	51
Outcomes	Alive	Alive	Alive

AOG: aortography, CAG: coronary angiography, DM: diabetes mellitus, EVT: endovascular therapy, HLP: hyperlipidemia, HTN: hypertension, PCI: percutaneous coronary intervention, PCSK9: proprotein convertase subtilisin/kexin type 9, PSL: prednisolone

*Interval between cause of cholesterol crystal embolism and manifestation of symptoms.

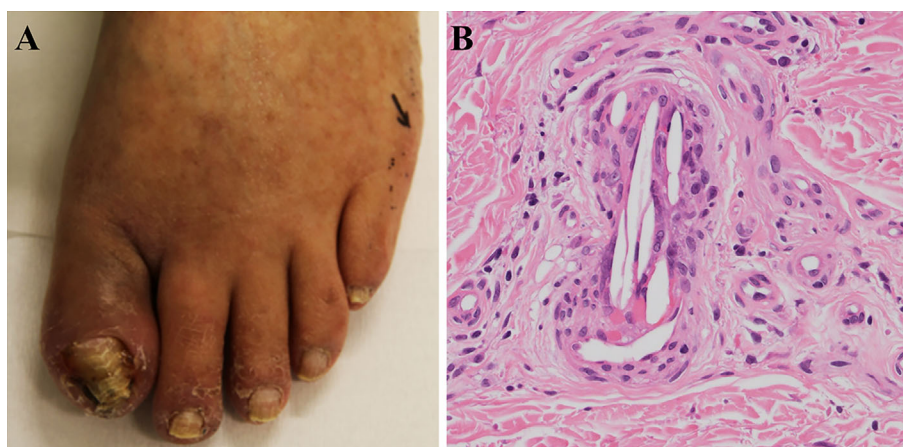


Figure. Skin lesion in cholesterol crystal embolism and cholesterol crystals in a skin biopsy specimen (Case 1). (A) The left foot was revealed to have blue toe syndrome and livedo reticularis. A skin biopsy was performed for the livedo reticularis area at Toe 5 (black arrow). (B) The skin biopsy revealed cholesterol clefts in a small artery (Hematoxylin and Eosin staining, $\times 400$).

needle-shaped cleft in the small arterial lumen consistent with CCE. After the diagnosis of CCE, oral prednisolone (20 mg/day) was administered. We gradually tapered the steroid dose, and a strong statin (Rosuvastatin) was gradually increased to the maximum dose (20 mg/day). Because the patient could not achieve optimal LDL control, we started administering a PCSK9 inhibitor (Evolocumab, 140 mg/2 weeks). After 11 weeks, both the cyanosis of the toes and the leg pain were completely resolved. Finally, although

we stopped prednisolone 52 weeks later, her renal function and leg condition were maintained.

There were no further occurrences of renal failure for the following two years (clinical findings and laboratory data are shown in Table 1, 2).

Case 2

The patient was a 78-year-old man who had a history of hyperlipidemia and diabetes as well as a heavy smoking

Table 2. Laboratory Findings of Three Patients with Cholesterol Crystal Embolism.

	Case 1	Case 2	Case 3
WBC (/μL)			
Baseline	6,500	7,400	8,400
Before PSL	7,200	7,700	6,800
PSL after 1 month	10,400	8,900	7,700
Before PCSK9 inhibitor	11,900	9,100	7,900
PCSK9 inhibitor after 1 month	6,700	11,600	7,100
PCSK9 inhibitor after 6 months	5,200	7,600	6,300
Current*	5,100	7,800	6,200
Eosinophils (/μL)			
Baseline	117	120	640
Before PSL	576	693	650
PSL after 1 month	21	50	90
Before PCSK9 inhibitor	178	190	230
PCSK9 inhibitor after 1 month	120	110	90
PCSK9 inhibitor after 6 months	166	160	270
Current*	80	140	248
eGFR (mL/min/1.73 m²)			
Baseline	71.8	71.2	34
Before PSL	29.2	71.4	31.9
PSL after 1 month	31.9	71.9	30
Before PCSK9 inhibitor	26.2	71.9	28.4
PCSK9 inhibitor after 1 month	30.3	63.1	30
PCSK9 inhibitor after 6 months	32.1	65.5	27.5
Current*	30.5	66.9	24
CRP (mg/dL)			
Baseline	0.4	0.7	0.8
Before PSL	0.4	1.1	0.9
PSL after 1 month	0	0.1	0
Before PCSK9 inhibitor	2.6	0.1	0
PCSK9 inhibitor after 1 month	0	0.1	0
PCSK9 inhibitor after 6 months	0	0.2	0.1
Current*	0	0.1	0.2
LDL cholesterol (mg/dL)			
Baseline	226	123	78
Before PSL	79	103	76
PSL after 1 month	89	69	76
Before PCSK9 inhibitor	86	69	71
PCSK9 inhibitor after 1 month	38	35	35
PCSK9 inhibitor after 6 months	35	52	66
Current*	39	154	66

CRP: C-reactive protein, eGFR: estimated glomerular filtration rate, LDL: low-density lipoprotein, PCSK9: proprotein convertase subtilisin/kexin type 9, PSL: prednisolone, WBC: white blood cell count

*Current indicates 2 years data after cholesterol crystal embolism in Case 1 and Case 2. One year data after cholesterol crystal embolism in Case 3.

habit. He had peripheral artery disease (PAD) with severe bilateral claudication (Rutherford category 3). He received endovascular therapy (EVT) for bilateral iliac artery occlusion via a femoral approach. Six weeks later, the patient experienced pain that revealed cyanosis of the toes and livedo reticularis in the left leg (Table 1).

Laboratory data revealed eosinophilia, but his renal function was not progressively deteriorating (Table 2). Although we recommended performing a skin biopsy, he refused it;

therefore, we diagnosed CCE based on his clinical course.

To treat the CCE, oral prednisolone was administered (20 mg/day). In addition, the patient had statin intolerance; thus, we started a PCSK9 inhibitor (Alirocumab, 75 mg/2 weeks) to achieve optimal LDL cholesterol control after 4 weeks. The prednisolone dose was gradually tapered so we could stop it after 24 weeks. The leg pain was completely resolved, while the cyanosis and ulceration of the toes remained slightly. At this stage, the left superficial femoral artery (SFA) was found by duplex ultrasound to have chronic total occlusion, and the skin perfusion pressure (SPP) value was <40. Therefore, we performed additional EVT for the left SFA. This procedure was performed without any complications. Finally, the cyanosis and ulcer of the toes were completely healed after 47 weeks. Because the patient did not wish to have continuous administration of PCSK9 inhibitor due to economic reasons, we stopped it.

Fortunately, his leg condition and renal function have been maintained for two years (clinical findings and laboratory data are shown in Table 1, 2).

Case 3

A 70-year-old man had a history of hypertension, hyperlipidemia, and myocardial infarction, as well as a heavy smoking habit. As he had PAD with bilateral claudication (Rutherford category 2), he received EVT for the left external iliac artery and right SFA via a left femoral approach. Four weeks later, the patient was referred to our hospital due to bilateral resting leg pain with livedo reticularis, cyanosis, and ulceration of the toes.

Laboratory data revealed eosinophilia, but his renal function had not progressively deteriorated from the baseline (eGFR=34.0 to 31.9 mL/min/1.73 m²) (Table 2). Based on these clinical findings, we diagnosed him with CCE. Oral prednisolone administration (20 mg/day) was started with a maximum dose of a strong statin (Pitavastatin, 4 mg/day), but the bilateral leg condition remained unchanged after 2 weeks. We started a PCSK9 inhibitor to achieve optimal LDL cholesterol control. Concurrently, a skin biopsy was performed, and the diagnosis of CCE was pathologically confirmed. To preserve the SPP values, we performed minor amputations of right toes 3 and 5 and left toe 3 due to gangrene.

Although we stopped the administration of the PCSK9 inhibitor due to economic reasons after 10 weeks, complete wound healing was achieved for 51 weeks. Indeed, the patient's renal function has been maintained for one year (clinical findings and laboratory data are shown in Table 1, 2).

Discussion

The mainstream treatment of CCE has been to restrict the extent of ischemic damage and prevent recurrent embolization. Various intensive treatments, such as the administration of corticosteroids, statins, iloprost, and LDL apheresis, have

been used for CCE (7-10); however, there is no definitive therapy for this condition. Thus, combination therapy is usually performed in daily clinical practice, which includes steroid therapy and LDL apheresis. Steroid therapy has a role in patients with systemic inflammation, but it is a double-edged sword. Steroids have several adverse effects, such as gastrointestinal bleeding, hyperglycemia, infections, osteoporosis, and cardiovascular events. In contrast, LDL apheresis is a relatively invasive method of achieving the required extra circulation and carries the possibility of severe side effects, such as shock or allergic reactions (12). Although the combination of steroid and statin therapy was chosen in three cases because there were no clinical trials of treatment for patients with CCE, additional PCSK9 inhibitor use is safer and less invasive than steroids and LDL apheresis.

Whether or not a PCSK9 inhibitor can achieve plaque stabilization and regression through lipid-lowering and anti-inflammatory mechanisms like a statin remains unclear; however, preclinical studies have reported that the inhibition of PCSK9 inhibitor can attenuate atherogenesis and plaque inflammation (5, 13). The plaque stabilization of PCSK9 inhibitor might result in a reduced risk for further embolization. This atheroprotection effect might be caused that PCSK9 inhibitor was effective for patients with CCE. In daily clinical practice, patients occasionally experience recurrence of CCE. In these cases, steroid administration is continued until the patients finally need permanent dialysis. Achieving the gradual reduction of the steroid dose was another key part of treatment for patients with CCE to prevent severe adverse effects. Although the PCSK9 inhibitor was not used with the objective of improving the treatment of CCE, and the start time varied throughout our cases presented here, all cases successfully achieved tapering of steroid use, maintained their renal function, and obtained toe healing without any side effects from the PCSK9 inhibitor. Combination therapy with PCSK9 inhibitor might be able to be safely performed steroid dose tapering. Intensive lipid-lowering therapy, such as with a statin or LDL-apheresis, improved blood viscosity and increased the peripheral arterial blood flow (14). Although the improvement of the blood flow by a PCSK9 inhibitor remains unclear, the use of a PCSK9 inhibitor was safe in the present cases and might thus be a useful treatment option.

In the cases presented here, steroid therapy was started first. Subsequently, PCSK9 inhibitor was added; therefore, precise assessments of PCSK9 inhibitor and anti-inflammation could not be obtained from laboratory data. However, in all cases, the C-reactive protein and eosinophil levels decreased, as did the LDL-cholesterol levels. Furthermore, these cases had a preserved eGFR, and end-stage renal disease did not progress over the next two years. Further research will be needed to determine the anti-inflammation role of PCSK9 inhibitor itself in CCE treatment.

CCE is associated with high mortality, and the renal prognosis is also poor, with approximately 40-60% of patients requiring permanent dialysis (2, 15); however, the reports describing such outcomes were not recently published. Recent guidelines recommend intensive lipid-lowering therapy for systemic atherosclerotic disease (16); therefore, the accumulation of more data is necessary in the PCSK9 inhibitor era. This is a case report of only a small number of patients. Large, prospective, randomized, and controlled studies will be necessary to confirm the efficacy of PCSK9 inhibitor for clinical and renal outcomes in patients with CCE.

The authors state that they have no Conflict of Interest (COI).

References

1. Fine MJ, Kapoor W, Falanga V. Cholesterol crystal embolization: a review of 221 cases in the English literature. *Angiology* **38**: 769-784, 1987.
2. Lye WC, Cheah JS, Sinniah R. Renal cholesterol embolic disease. Case report and review of the literature. *Am J Nephrol* **13**: 489-493, 1993.
3. Fukumoto Y, Tsutsui H, Tsuchihashi M, Masumoto A, Takeshita A. The incidence and risk factors of cholesterol embolization syndrome, a complication of cardiac catheterization: a prospective study. *J Am Coll Cardiol* **42**: 211-216, 2003.
4. Sabatine MS, Giugliano RP, Keech AC, et al. Evolocumab and clinical outcomes in patients with cardiovascular disease. *N Engl J Med* **376**: 1713-1722, 2017.
5. Karagiannis AD, Liu M, Toth PP, et al. Pleiotropic anti-atherosclerotic effects of PCSK9 inhibitors from molecular biology to clinical translation. *Curr Atheroscler Rep* **10**:20: 20, 2018.
6. Belenfant X, Meyrier A, Jacquot C. Supportive treatment improves survival in multivisceral cholesterol crystal embolism. *Am J Kidney Dis* **33**: 840-850, 1999.
7. Sanai T, Matsui R, Hirano T. LDL apheresis for cholesterol embolism following coronary artery bypass graft surgery: a case report. *Angiology* **57**: 379-382, 2006.
8. Saito T. Corticosteroid pulse therapy for the treatment of cholesterol embolic disease. *Intern Med* **42**: 1159-1160, 2003.
9. Rumpf KW, Schult S, Mueller GA. Simvastatin treatment in cholesterol emboli syndrome. *Lancet* **352**: 321-322, 1998.
10. Grenader T, Lifschitz M, Shavit L. Iloprost in embolic renal failure. *Mt Sinai J Med* **72**: 339-341, 2005.
11. Matsuo S, Imai E, Horio M, et al. Revised equations for estimated GFR from serum creatinine in Japan. *Am J Kidney Dis* **53**: 982-992, 2009.
12. Bambauer R, Schiel R, Latza R. Low-density lipoprotein apheresis: an overview. *Ther Apher Dial* **7**: 382-390, 2003.
13. Shapiro MD, Fazio S. PCSK9 and atherosclerosis-lipids and beyond. *J Atheroscler Thromb* **24**: 462-472, 2017.
14. Rubba P, Iannuzzi A, Postiglione A, et al. Hemodynamic changes in the peripheral circulation after repeat low density lipoprotein apheresis in familial hypercholesterolemia. *Circulation* **81**: 610-616, 1990.
15. Scolari F, Ravani P, Pola A, et al. Predictors of renal and patient outcomes in atheroembolic renal disease: a prospective study. *J Am Soc Nephrol* **14**: 1584-1590, 2003.
16. Kinoshita M, Yokote K, Arai H, et al; Committee for Epidemiology and Clinical Management of Atherosclerosis. Japan Atherosclerosis Society (JAS) guidelines for prevention of atherosclerotic cardiovascular diseases 2017. *J Atheroscler Thromb* **25**: 846-984, 2018.

The Internal Medicine is an Open Access journal distributed under the Creative Commons Attribution-NonCommercial-NoDerivatives 4.0 International License. To view the details of this license, please visit (<https://creativecommons.org/licenses/by-nc-nd/4.0/>).