

Thoracolumbar Fracture Dislocations Without Spinal Cord Injury: Classification and Principles of Management

Global Spine Journal
2021, Vol. 11(1) 63-70
© The Author(s) 2019
Article reuse guidelines:
sagepub.com/journals-permissions
DOI: 10.1177/2192568219890568
journals.sagepub.com/home/gsj



Rishi Mugesh Kanna, MS, MRCS, FNB¹ , Dilip Chand Raja, MS, DNB, FNB¹, Ajoy P. Shetty, MS, DNB¹, and Shanmuganathan Rajasekaran, PhD¹

Abstract

Study Design: Retrospective cohort study.

Objectives: Thoracic and lumbar fracture dislocations (TLFD) are high-velocity injuries and frequently result in gross neurological deficit. Very rarely, such patients present with intact neurology. Pathomechanics of injury, radiological assessment, surgical techniques, and principles of fixation in such challenging situations have not been described previously.

Methods: Retrospective review of 36 patients of TLFD without cord injury was performed for demographics, clinical and radiological data, and management. The injuries were classified based on the direction of translation into 4 types: coronal translation (type 1), sagittal translation (type 2), combined translation—antero (type 3a), and combined translation—retro (type 3b). The injuries were managed by meticulous unilateral exposure and temporary fixation, decompression, gradual reduction of dislocation, and long segment fixation.

Results: In 36 patients, the injuries were classified as type 1 (n = 9), type 2 (n = 10), type 3a (n = 14), and type 3b (n = 3). Imaging/intraoperative observation showed varying degrees of disintegrity of disc, facet joints, and posterior ligamentous complex in the 4 different injury types. Patients with the different injury types also needed individualistic surgical approaches to aid safe reduction of dislocation. Neurological assessment was performed using American Spinal Injury Association score (ASIA), and 16 patients had minimal neurological deficits (ASIA-D) and all were type 3 injury. The mean anteroposterior and lateral translation were corrected from 8.3 ± 3.4 to 1.7 ± 1.3 mm, and 4.7 ± 4.8 to 0.7 ± 0.8 mm respectively.

Conclusion: This is the largest case series of TLFD without cord injury. Knowledge of the different injury types and principles of safe surgical reduction of the dislocation are important for the treating surgeon to ensure successful outcomes.

Keywords

thoracolumbar fracture dislocation, type C injury, fracture reduction

Introduction

Thoracolumbar fracture dislocation (TLFD), classified as Arbeitsgemeinschaft für Osteosynthesefragen (AO) type C injuries, are serious 2-column spinal injuries resulting from high-velocity accidents.¹ There is typically complete disruption of the stabilizing ligaments, facet joint capsules, and the paraspinal musculature resulting in translation of the spinal column in one or both planes (sagittal and coronal).² The bony translation and the transfer of shearing forces lead to disruption of the spinal cord, thus resulting in complete neurological deficit in most cases.^{1,2} The management is usually straightforward, and the injuries are managed surgically with long segment posterior spinal stabilization.³ Surgical fixation

enables early rehabilitation while chances of neurological recovery remain rare.

Very rarely TLFD can present without spinal cord injury with maintained neurological function where the management presents unique difficulties to the treating surgeon.^{4,5} Since the spinal column is grossly unstable because of the 2-column

¹ Ganga Hospital, Coimbatore, Tamil Nadu, India

Corresponding Author:

Rishi Mugesh Kanna, Department of Orthopaedics and Spine Surgery, Ganga Hospital, 313, Mettupalayam Road, Coimbatore 641043, Tamil Nadu.
Email: rishiortho@gmail.com



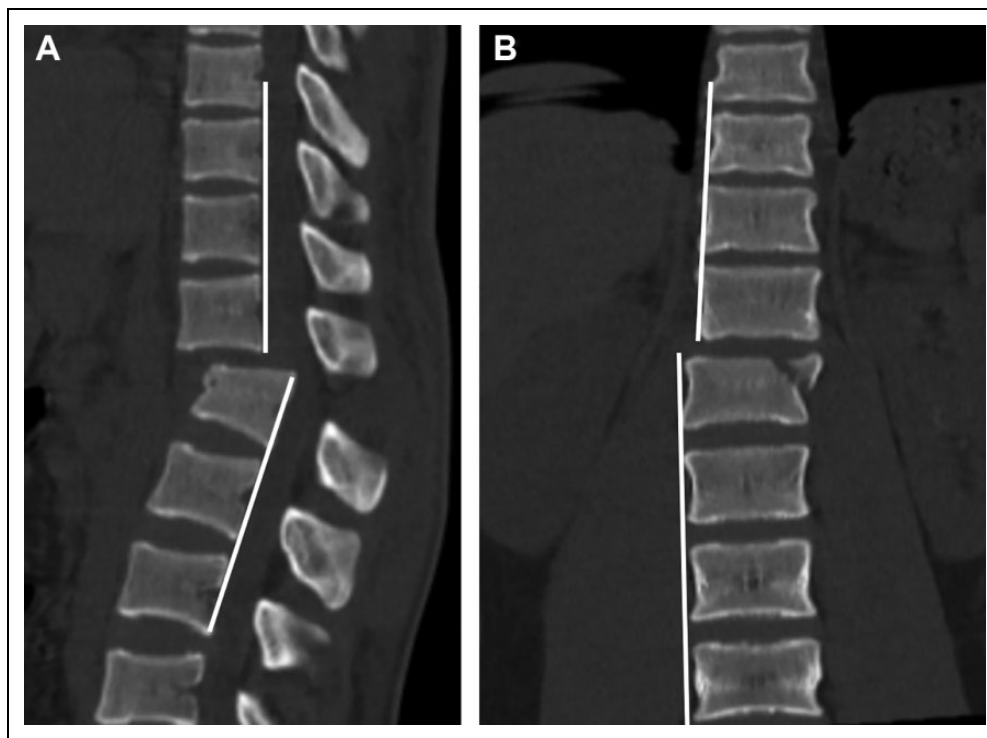


Figure 1. Technique of assessing and measuring vertebral translation in 2 planes: (a) by the presence of translation between 2 adjacent posterovertebral corners in the sagittal CT image or lateral radiograph; (b) the presence of discontinuity between 2 vertical lines drawn along the lateral margins of superior and inferior vertebra in the anteroposterior/coronal view.

disruption, there are significant risks of further instability and neurological deficit during transfer, positioning on the operating table, and surgical intervention.^{6,7} The spinal canal dimensions will be compromised by the translated spine and any untoward movements can risk the development of neurological deficit.

McAfee classified thoracolumbar injuries into wedge compression injury, stable and unstable burst fracture, chance fracture, flexion-distraction injury, and translational injury. Currently, AO classification of thoracolumbar fractures is the most reliable and widely used classification system, which is again based on the morphology of fractures (A, Compression; B, Distraction; and C, Translational) injuries and surgical decision is broadly based on this classification. The modified version of this classification system also includes neurological status and is comprehensive. However, in these standard classification systems, TLFDs are grouped as a single type (AO type C or McAfee translational injury). Radiologically, these injuries do not fall into a single pattern, with vertebral translation occurring in different planes and directions. Due to the rarity of TLFD without spinal cord injury, such cases have been previously published only as case reports, and a standard algorithm to classify the injuries and its management has not been detailed before. We present one of the largest case series of patients with TLFD without cord injury and describe the different injury mechanisms, radiological subtypes, and principles of management.

Material and Methods

We performed a retrospective review of case records of patients with TLFD treated between 2011 and 2016. Fracture dislocation of the spine was defined by the presence of discontinuity between 2 vertical lines drawn along the lateral margins of superior and inferior vertebra in the anteroposterior/coronal view and/or by the presence of translation between 2 adjacent posterovertebral corners in the lateral/sagittal view (Figure 1). American Spinal Injury Association score (ASIA) neurological grading was used: ASIA-A represents complete motor loss; ASIA-B patients have preserved sensations with complete motor loss, incomplete motor deficits with grade <3 (ASIA-C) and ≥ 3 (ASIA-D); and ASIA-E represents normal neurology. All patients with gross motor and/or sensory deficit (ASIA-A to -C) were excluded from the study. Other exclusion criteria were pathological fractures, tumors/metastatic pathological fractures, infections, and noncontiguous multi-level fractures. The remaining patients of thoracolumbar fracture dislocation with minimal or no neurological deficit (ASIA \geq D) were included in the analysis.

The records were analyzed to document the demographics, clinical and radiological data, and management. All patients had radiographs in 2 orthogonal planes, and computed tomography (CT) scan of the afflicted zone. Those with ASIA-D neurology also underwent magnetic resonance imaging (MRI) of the injured region. Based on X-ray and CT imaging, the injuries were classified into 4 types: coronal translation (type 1),

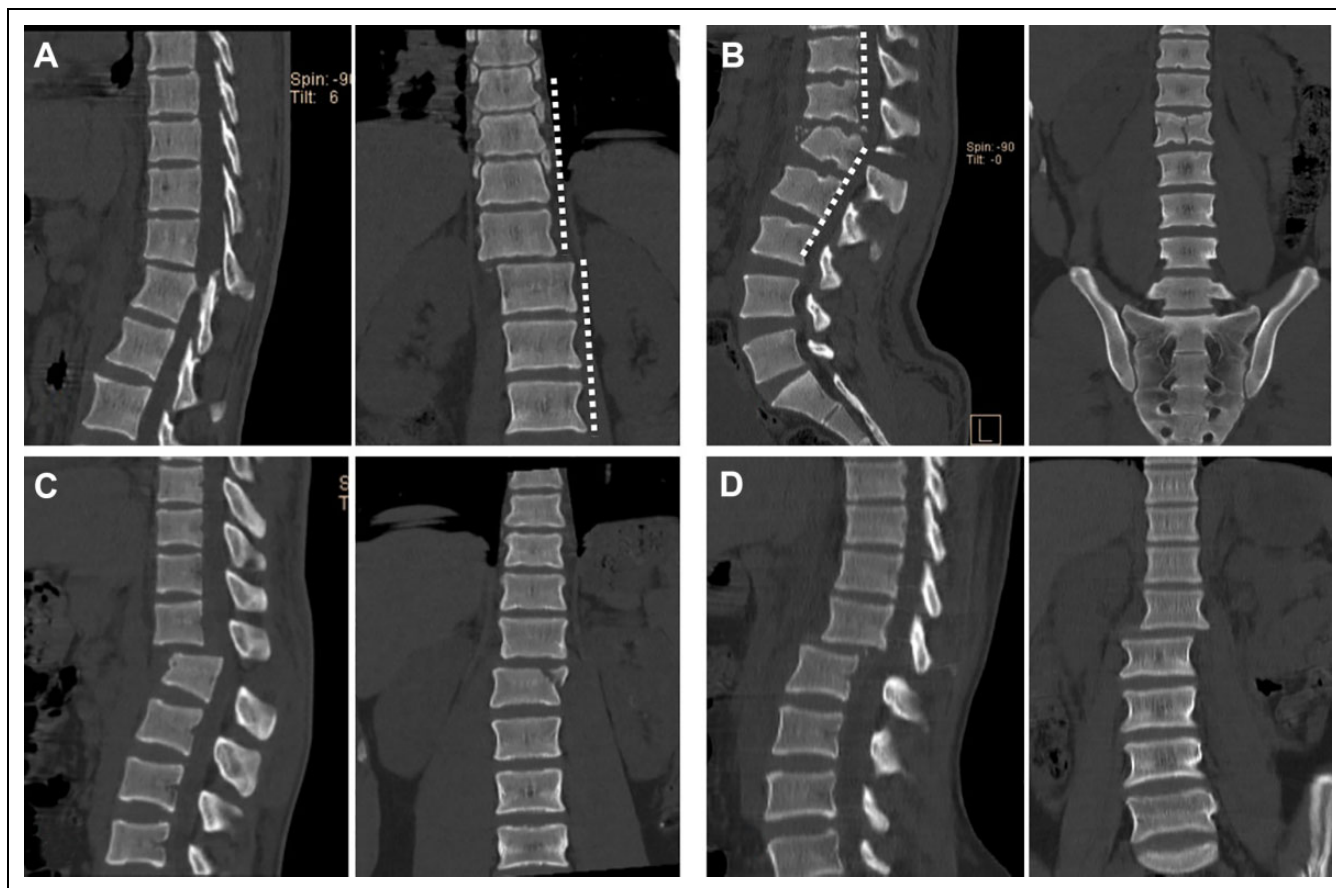


Figure 2. Classification of TLFD with intact neurology: (A) the coronal section indicates coronal translation (type 1); (B) the sagittal view indicates the presence of sagittal translation (type 2); (C, D) the coronal and sagittal CT images indicate the presence of combined translation in both the planes, anterior (type 3a) (C) and posterior (type 3b) (D).

sagittal translation (type 2), combined translation—antero (type 3a), and combined translation—retro (type 3b; Figure 2). The status of the posterior ligamentous complex structures, facet joints, and the longitudinal ligaments were documented as observed intraoperatively and in the radiological images.

Surgical Technique

The patients were operated at the earliest possible since these injuries were potentially unstable. (We have detailed the general principles of safe surgical reduction initially, and specific variations in surgical steps that needs to be exercised depending on the individual injury type are detailed in the last section.)

- All patients were managed by a posterior approach (Figure 3a-f). After endotracheal intubation, the patient was turned prone by carefully log-rolling onto padded bolsters.
- Through a posterior midline approach, the spine was exposed unilaterally first, and pedicle screws were inserted at least one level above and below the injury. The use of a high-speed burr and an electric drill was preferred to create the pedicle screw track to avoid significant motion at the injury site.
- While inserting the screws, the spinous process of vertebrae above and below the injury were gently held by a bone rongeur to avoid undue torsional stress at the site of translation.
- A temporary rod was placed to provide provisional stability to the unstable spine, and the rest of the screws were then inserted ipsilaterally. Preferably a minimum of 2 vertebral segments above and below the injury were included in the fixation zone.
- After temporary stabilization, the contralateral side was exposed and all the requisite pedicle screws were inserted.
- A laminectomy was performed at the level of translation in patients with incomplete neurological deficit.
- The screw caps of the temporary rod were released partially and an appropriately contoured rod was placed on the contralateral side in the distal segment and secured with nuts. The proximal part of the rod was then gently persuaded into the proximal screw heads, thus enabling reduction of the fracture.
- Gentle distraction or compression was performed suitably to help in complete fracture reduction. The temporary rod was replaced with a definitive contoured rod.

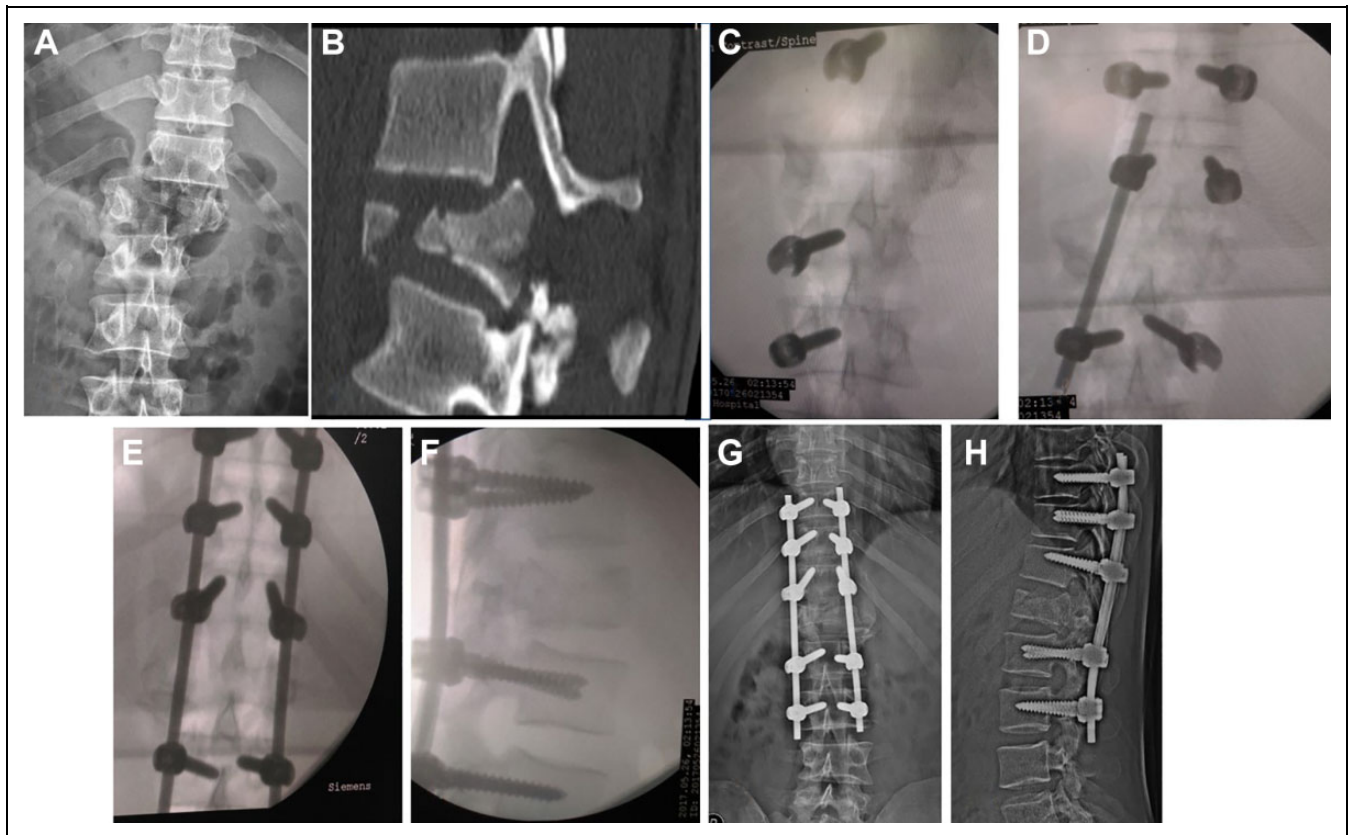


Figure 3. Safe surgical technique for reducing TLFD: (a) Anteroposterior radiograph and sagittal CT image (b) shows the presence of a type 3a translation. (c) Intraoperative AP image intensifier picture showing ipsilateral exposure of spine and placement of pedicle screws. (d) Image intensifier pictures shows the placement of a temporary rod for provisional stabilization and contralateral exposure to place pedicle screws 3 levels above and 2 levels below the injury. (e, f) Use of contoured rod on either side to reduce the dislocation. (g, h) Postoperative AP and lateral image shows good correction of the dislocation in both planes.

Depending on the type of dislocation, certain surgical steps required individualization as detailed below:

- In type 1 coronal translational injury, the cord was usually pushed toward the side of the proximal fragment. Hence, the initial exposure of the spine was performed on the contralateral side to retain spinal stability and avoid maneuvering the spine toward the side of the cord displacement.
- In patients with type 2 sagittal displacement and type 3a injuries, extreme care needs to be exercised during surgical exposure since there was usually significant disruption of the posterior ligaments and flavum, surrounding the cord posteriorly at the injury level.
- In patients with type 2 injuries, the rod is placed on the distal screws first and then gently persuaded toward the proximal screws to aid correction of the displacement.
- However, in type 3b injuries, the rod is placed into the proximal screw heads first and then gently persuaded into the distal screw heads to correct retrolisthesis.
- In patients with type 1 and 3a injuries, for reducing the dislocation, the authors prefer to gently persuade the contoured rod into both the proximal and distal screw

heads simultaneously, and then rotate the rod into the appropriate sagittal plane (as in idiopathic scoliosis).

- In patients with type 3b injuries, a facet screw was inserted across the distracted facets to retain the reduction and promote fusion (Figure 4).

Intraoperative variables, perioperative complications, fracture healing, and functional outcomes at 1 year were assessed.

Results

During the study period, 36 patients have been treated for TLFD with minimal or no neurological deficit. The mean age was 33.2 ± 13.1 years, and male-to-female ratio was 26:10. The mechanism of injuries were as follows: fall from a height ($n = 17$), road traffic accidents ($n = 16$), and industrial accident ($n = 3$). Twenty patients had associated injuries involving the chest and abdomen ($n = 8$), extremities ($n = 7$), face ($n = 3$), pelvis ($n = 2$), and others ($n = 5$). Only 2 patients had medical comorbidities. The regional distribution of injuries was as follows: thoracic (T1 to T10; $n = 10$), thoracolumbar (T11 to L1; $n = 19$), and lumbar ($n = 7$).

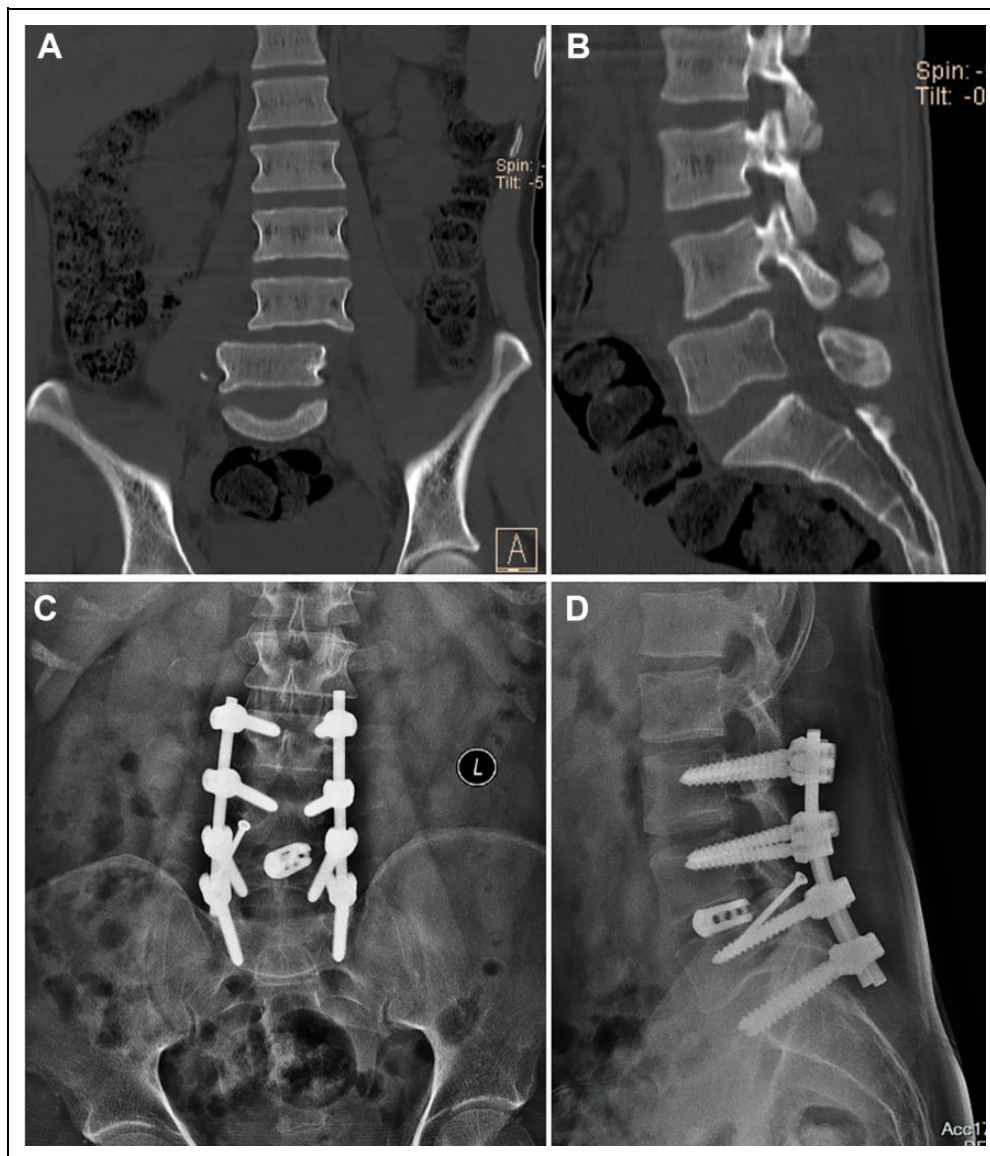


Figure 4. A 36-year-old male patient who has sustained a type 3b injury in a motor vehicle accident. (a, b) Coronal and sagittal CT images show the presence of combined lateral and sagittal translation (retrolisthesis) of vertebral column at L4-5 level. (c, d) The injury has been treated by complete reduction, posterior fixation from L3-S1, L4-5 interbody fusion and facet fixation.

Classification of Translational Injuries

Based on radiographs and CT imaging, the injuries were classified as follows: coronal translation (n = 9), sagittal translation (n = 10), combined translation—antero (n = 14) and combined translation—retro (n = 3).

Type 1 Coronal Translation. In type 1 coronal translation (n = 9), the proximal and distal segments of the injured spine were translated mediolaterally, as observed in the coronal CT images and anteroposterior radiographs. In 7 patients, the injuries occurred through the disc space and no significant vertebral fractures were present. Intraoperatively, the facet joints were documented to be subluxated, and the posterior ligamentous

complex (PLC) was intact but stretched along the side of translation.

Type 2 Sagittal Translation. In type 2 sagittal translation (n = 10), the proximal and distal segments of the injured spine were translated anteroposteriorly as observed in the lateral radiograph and sagittal CT images. Seven patients had an axial compression type fracture (AO type A2, A3, or A4) of the corresponding vertebral body, while no fractures were present in 3 patients. Perioperatively, the facets were found to be distracted but intact, and the PLC was disrupted completely.

Type 3 Combined Translation. In combined translations (n = 17), the spine was observed to be translated mediolaterally.

Additionally, the vertebral segments were translated in the sagittal plane either anteriorly (type 3a) or posteriorly (type 3b). All type 3a injuries had associated burst fractures of the vertebral body, while all type 3b injuries occurred through disc space without any vertebral fractures. The injuries appeared to be rotational around the longitudinal axis of the spine with unilateral facet disruption, and partial disruption of PLC.

The neurological ASIA grading was as follows: ASIA-E (n = 20) and ASIA-D (n = 16). While patients with uniplanar translation (type 1 and type 2) had intact neurology, 16 out of 17 patients with biplanar translation had incomplete neurological deficits. Ten patients had a traumatic dural tear and all were type 3 injuries. All the patients had similar neurological findings after the surgery and there was no case of neurological worsening. After surgery, there was improvement in neurological status in ASIA-D patients, and all achieved normal neurological status at 6 months postoperatively.

The mean blood loss was 465 ± 143 mL, and the mean surgical duration was 164 ± 56 minutes. The mean duration of stay was 9.3 ± 3.7 days. The mean time interval between injury and surgical intervention is 2.6 ± 2.6 days. The mean length of fixation was 5.1 ± 1.1 segments, and a mean 8.4 ± 1.1 pedicles were fixed. All patients had complete reduction of the dislocation, and the mean AP translation of 8.3 ± 3.4 mm was corrected to 1.7 ± 1.3 mm, while mean lateral translation of 4.7 ± 4.8 mm was corrected to 0.7 ± 0.8 mm. The mean follow-up was 14.3 months, and at the final follow-up, there were no implant failures or loss of reduction.

Discussion

TLFD are high-velocity injuries and are generally associated with a complete neurological deficit.^{1,2} Management conventionally follows the acute trauma protocol and damage control spinal stabilization to reduce the fracture, thereby enabling early spinal injury rehabilitation. However, a small subset of patients can present without spinal cord injury following a TLFD, which is considered as a rarity.^{4,5} Most of the cases described in the literature are individual case reports or a series of few cases.⁶⁻⁸ The present study is the largest case series of patients with fracture dislocation without cord injury. We have documented, classified, and described a management protocol for such patients with TLFD.

TLFD With Intact Neurology. Fracture dislocations are considered to occupy the most severe forms of injury in the thoracolumbar injury spectrum.⁹ Most patients sustain a complete neurological deficit because of the high velocity of injury transferred to the spinal cord and the translated spine obliterates the spinal canal. A complete deficit is the expected outcome such that patients with TLFD without neurological deficit are published as very rare case reports.⁶⁻¹⁰ The probable mechanism for spinal cord sparing in such injuries could be spontaneous decompression of the cord due to splaying of fracture fragments or the injury force has just fallen short of further injuring the spinal cord.¹⁰ Fractures of the pedicles and

facets at the involved vertebrae have been reported in a few case reports.¹¹⁻¹⁴ The fractured pedicles and facets dissociate the vertebral body from the posterior vertebral arch, which results in translation of the vertebral segments but the spinal cord may have enough space to avoid any injury.

Principles of Surgical Technique. The unstable nature of the injury and the precarious nature of the spinal cord mandates that an accurate and early diagnosis is critically important before any improper maneuver can be applied to patients with TLFD with intact neurological function. Any untoward movements may damage the spinal cord and cause neurological deficit.^{15,16} So, recognition of the injuries is of paramount importance and early surgical fixation is preferred to avoid further delays and transfers. We also employed a different reduction technique to ensure that the least stress occurs at the injured segment while reducing the translation. The authors insist on the following 6 critical steps to ensure safe surgical reduction of the spine:

1. Attention while log rolling the patient to prone position on the operating table
2. Unilateral exposure and temporary fixation
3. Use of high-speed burr and drill to create screw track
4. Avoid torque forces while inserting the screws
5. Perform a laminectomy before reducing the dislocation
6. Use of gentle reduction maneuvers with persuaders and rod rotation under direct visualization of the spinal cord

Furthermore, the surgical steps need individualization based on the type of dislocation.

Descriptive Classification of TLFD Without Deficits. We observed 4 different types of translational injuries of the spine. The extent of injury to the supporting ligaments and capsular structures, dural tear, subtle neurological deficit, and the steps of surgical reduction varied widely between the 4 different injury types. Hence, critical assessment of the radiographs would be crucial for the operating surgeon during surgical planning.

Conventionally translational injuries (AO type C) are not subclassified since such injuries result in complete neurological deficit and those without cord injury are very rare, precluding further subclassification. However, we noticed that TLFD without neurological deficit falls under 4 broad categories: coronal translation, sagittal translation, and combined translation either anteriorly or posteriorly. The first 2 categories were uniplanar injuries. In sagittal translation, the facet joint was intact while the PLC was disrupted, while in lateral translation, the facet joints were subluxated but the PLC was stretched and intact. Interestingly, patients with coronal translation type 1 injuries had a disruption through the disc space with intact vertebral bodies. This indicates lateral shear stress across the disc causing a lateral translation, whereas patients with sagittal translation were typical flexion distraction type injuries with disruption of the PLC. Patients with uniplanar injuries had intact neurology. The combined injuries appeared like rotational injuries of the spine around its axis such that one facet capsule was intact

while the other disrupted along with the PLC. Remarkably patients with retro-combined translation (type 3b) had intact vertebral bodies and the disruption always occurred through the disc. Biplanar injuries had varying degrees of subtle neurological deficit. Apart from being descriptive, classifying the injury also helped in devising the appropriate surgical technique of reducing the translation.

Site and Mechanism of Injury. Thoracolumbar spine was the most common location for unstable injuries of the spine. This can be attributed to the transition between the rigid thoracic spine and the flexible lumbar spine. Regarding the injury mechanism, while most case reports describe this injury following a major road traffic accident, we observed that fall from a height was the most common mechanism in our study (17/36, 47.2%). Interestingly, 3 of our patients had sustained the injury in industrial zones. Uniformly, all of them have been impounded by a heavy object falling on their back while standing. In 2 previous case reports of TLFDD without neurology, this mode of injury has been described.^{13,14}

The study has a few limitations. First, due to the rarity of the injury, the sample size is small and hence the observations are descriptive, without any statistical comparison. However, this still remains the largest series described so far. Second, the classification and management principles are enunciated based on the surgeons' experience and will need further validation for reproducibility and reliability. Third, in this series, all translational injuries were considered unstable, and addressed surgically irrespective of the amount of dislocation or kyphosis. However, it would be interesting to analyze the various difficulties experienced during surgery based on amount of translation and kyphosis. Fourth, considering the risks of neurological worsening during surgical reduction, the use of intraoperative neuromonitoring (IONM) should be considered in these patients. Ours was a retrospective analysis of patients with TLFDD and intact neurology, undergoing spine surgery from 2011 to 2016, during which we had used IONM predominantly for deformity correction and chronic myelopathy. However, this article highlights those sequential surgical steps to be taken, which could avoid potential neurological injury during surgery. IONM in such cases in current medical practice is very essential, and we recommend the usage of IONM in the future.

Conclusion

Thoracolumbar fracture dislocations are unstable injuries that ensue from high-velocity injuries. The present study describes a rare subset of such patients without gross neurological deficit. Meticulous care and vigilant attention should be exercised while transfer and surgical reduction of the injuries to avoid iatrogenic neurological deficit. The translation can happen in 1 plane or 2 planes depending on the variability in the disruption of supporting posterior ligaments and the facet joints.

Declaration of Conflicting Interests

The author(s) declared no potential conflicts of interest with respect to the research, authorship, and/or publication of this article.

Funding

The author(s) disclosed receipt of the following financial support for the research, authorship, and/or publication of this article: The study was funded by the Ganga Orthopaedic Research and Education Foundation.

ORCID iD

Rishi Mugesh Kanna, MS, MRCS, FNB  <https://orcid.org/0000-0001-5817-4909>

References

- Hutchinson MR, Dall BE. Fracture-dislocation of the thoracic and lumbar spine: advantages of halo-bifemoral traction. *J Spinal Disord.* 1993;6:482-488.
- Bohlman HH. Treatment of fractures and dislocations of the thoracic and lumbar spine. *J Bone Joint Surg Am.* 1985; 67:165-169.
- Chavda DV, Brantigan JW. Technique of reduction and internal fixation of thoracolumbar fracture-dislocation using pedicle screws and variable screw placement plates. *Orthop Rev.* 1994; (suppl):25-31.
- Akay KM, Baysefer A, Kayali H, Beduk A, Timurkaynak E. Fracture and lateral dislocation of the T12-L1 vertebrae without neurological deficit—case report. *Neurol Med Chir (Tokyo).* 2003;43:267-270.
- Phadnis AS, Tan CJ, Raman AS, Crawford R, Rai AS. Fracture and complete dislocation of the spine with a normal motor neurology. *Injury Extra.* 2006;37:479-483.
- Sasson A, Mozes G. Complete fracture-dislocation of the thoracic spine without neurologic deficit. A case report. *Spine (Phila Pa 1976).* 1987;12:67-70.
- de Lucas JC, Alvarez L, Abril JC, Calvo E. Fracture-dislocation of the thoracic spine without neurological lesion. *Injury.* 1994;25: 105-107.
- Hsieh CT, Chen GJ, Wu CC, Su YH. Complete fracture-dislocation of the thoracolumbar spine without paraplegia. *Am J Emerg Med.* 2008;26:633.e5-e7.
- Vaccaro AR, Oner C, Kepler CK, et al; AOSpine Spinal Cord Injury & Trauma Knowledge Forum. AOSpine thoracolumbar spine injury classification system: fracture description, neurological status, and key modifiers. *Spine (Phila Pa 1976).* 2013;38: 2028-2037.
- Rahimizadeh A, Asgari N, Rahimizadeh A. Complete thoracolumbar fracture-dislocation with intact neurologic function: explanation of a novel cord saving mechanism. *J Spinal Cord Med.* 2018;41:367-376.
- Harryman DT. Complete fracture-dislocation of the thoracic spine associated with spontaneous neurologic decompression. A case report. *Clin Orthop Relat Res.* 1986;(207):64-69.
- Weber SC, Sutherland GH. An unusual rotational fracture-dislocation of the thoracic spine without neurologic sequelae

- internally fixed with a combined anterior and posterior approach. *J Trauma*. 1986;26:474-479.
13. Jiang B, Zhu R, Cao Q, Pan H. Severe thoracic spinal fracture-dislocation without neurological symptoms and costal fractures: a case report and review of the literature. *J Med Case Rep*. 2014; 8:343.
 14. Zeng J, Gong Q, Liu H, Rong X, Ding C. Complete fracture-dislocation of the thoracolumbar spine without neurological deficit: a case report and review of the literature. *Medicine (Baltimore)*. 2018;97:e0050.
 15. Simpson AH, Williamson DM, Golding SJ, Houghton GR. Thoracic spine translocation without cord injury. *J Bone Joint Surg Br*. 1990;72:80-83.
 16. Uriarte E, Elguezabal B, Tovio R. Fracture-dislocation of the thoracic spine without neurologic lesion. *Clin Orthop Relat Res*. 1987;(217):261-265.