

## Management of Loose, Frequent Stools and Fecal Incontinence in a Chronic Mesenteric Ischemia Patient with Oral Serum-derived Bovine Immunoglobulin

Larry Good<sup>1</sup> and Bruce P. Burnett<sup>2</sup>

<sup>1</sup>Department of Medicine, State University of New York, SUNY, Stony Brook, NY, USA. <sup>2</sup>Entera Health, Inc., Cary, NC, USA.

### ABSTRACT

**AIM:** Chronic diarrhea with fecal incontinence (FI) is a severe, underreported, and intractable problem in many patients for which limited pharmaceutical options exist.

**METHODS:** A retrospective case history was collected after the administration of a prescription medical food composed of serum-derived bovine immunoglobulin/protein isolate (SBI) at 5 g once daily in a patient with chronic mesenteric ischemia (CMI) for chronic loose, frequent, and urgent stools. The patient was an 84-year-old white male with a 20-year history of progressively worsening chronic diarrhea with six to eight watery stools per day (Bristol Stool Form Scale, Type 7), urgency, nocturnal diarrhea, FI, and postprandial abdominal discomfort before administration of SBI.

**RESULTS:** After four weeks of SBI administration, the patient had two to three soft, semi-formed stools (Bristol Stool Form Scale, Types 4 and 5) per day with no nocturnal diarrhea, urgency, or FI, as well as full resolution of abdominal discomfort. In addition, the patient expressed an enhanced quality of life (QoL): able to travel, attend social events, and perform tasks not possible before therapy.

**CONCLUSION:** This case underscores how a safe, nutritional therapy may offer a new modality for physicians to address chronic loose, frequent stools with FI in patients with CMI in this difficult to manage gastrointestinal population.

**KEYWORDS:** serum-derived immunoglobulins, EnteraGam™, fecal incontinence

**CITATION:** Good and Burnett. Management of Loose, Frequent Stools and Fecal Incontinence in a Chronic Mesenteric Ischemia Patient with Oral Serum-derived Bovine Immunoglobulin. *Clinical Medicine Insights: Gastroenterology* 2015;8 7–11 doi:10.4137/CGast.S21307.

**RECEIVED:** October 29, 2014. **RESUBMITTED:** December 3, 2014. **ACCEPTED FOR PUBLICATION:** December 3, 2014.

**ACADEMIC EDITOR:** Melpakkam Srinivas, Editor in Chief

**TYPE:** Case Report

**FUNDING:** Authors disclose no funding sources.

**COMPETING INTERESTS:** Dr. Burnett is an employee of Entera Health, Inc. who manufactures and markets EnteraGam™ (SBI) as a prescription medical food product. Dr. Good is a speaker for Entera Health, Inc.

**COPYRIGHT:** © the authors, publisher and licensee Libertas Academica Limited. This is an open-access article distributed under the terms of the Creative Commons CC-BY-NC 3.0 License.

**CORRESPONDENCE:** [good1b@optonline.com](mailto:good1b@optonline.com)

Paper subject to independent expert blind peer review by minimum of two reviewers. All editorial decisions made by independent academic editor. Upon submission manuscript was subject to anti-plagiarism scanning. Prior to publication all authors have given signed confirmation of agreement to article publication and compliance with all applicable ethical and legal requirements, including the accuracy of author and contributor information, disclosure of competing interests and funding sources, compliance with ethical requirements relating to human and animal study participants, and compliance with any copyright requirements of third parties. This journal is a member of the Committee on Publication Ethics (COPE).

### Introduction

Fecal incontinence (FI), defined as the involuntary discharge of gas and/or fecal matter, is a severe and debilitating condition that affects over 18 million adults in the United States.<sup>1</sup> The condition is slightly more prevalent among women compared to men, and incidence increases with age and poor health status.<sup>1,2</sup> About 2–3% of all adults are affected by FI,<sup>2</sup> which increases to about 10% in elderly populations,<sup>3</sup> and is a particular problem in nursing home communities for the elderly, with rates approaching 50%.<sup>4</sup>

FI severity is determined by a combination of stool frequency, consistency, and use of protective pads.<sup>5</sup> Costs to

the patient and to the healthcare system are significant. One recent survey of self-reported patient costs showed that the average annual total cost for FI was \$4110 per person including both direct and indirect costs.<sup>6</sup> The estimated costs of FI to the healthcare system are difficult to quantify. One team of researchers found that over a five-year period, patients with FI had 55% higher total healthcare costs and 77% higher costs related to gastroenterology specialty care.<sup>7</sup> These patients also utilized significantly more healthcare costs overall because of comorbid conditions. If procedures or surgery is required to treat FI, then costs increase significantly.<sup>8</sup> In chronic care settings, substantial staff time and energy are spent maintaining



hygiene and caring for patients with FI, though there are very few studies to quantify these costs. While most studies deal with urinary incontinence, Xu and colleagues<sup>6</sup> have stated that the cost of maintaining FI patients is similar to findings in urinary incontinence. Investigators examining this issue have found that the majority of costs for incontinence management, as much as 50–75% of annual expenditures, are as a result of absorptive products, containment devices, laundry costs, and personnel costs for nurses, nursing assistants, and laundry personnel, as well as housekeeping staff.<sup>8–10</sup>

The most onerous aspect of FI is the personal costs to patients, with a deleterious impact on their quality of life (QoL). Patients consider this disorder an embarrassment and do not always make their physicians aware of their condition in an outpatient setting.<sup>11</sup> Because of this embarrassment, only approximately one-quarter of patients with FI are diagnosed.<sup>12</sup> More seriously, FI results in diminished QoL and lower mental health scores. One researcher found that 22% of patients with FI had severely degraded QoL, which was associated with worsening mental health scores.<sup>13</sup> Failure to seek treatment is common, which leads to additional diminution of QoL and mental health.

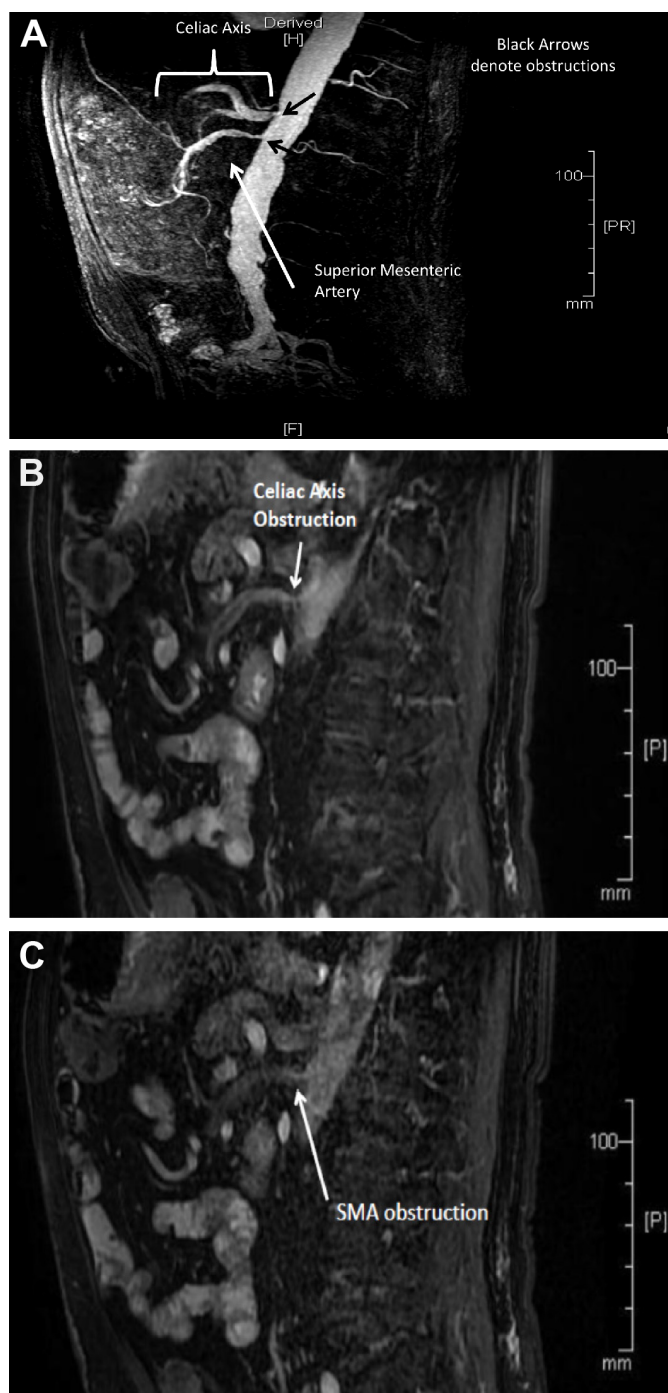
Current medical treatment for FI is limited. The primary goal of treatment is a reduction in the number of stools per day and improvement in stool consistency. Patients with low-volume stool incontinence can take bulking agents such as methylcellulose and psyllium fiber to help control liquid stools.<sup>14</sup> By also restricting fluid intake, these therapies may aid patients with soft or liquid stools but is not always wise in the elderly. Biofeedback has additionally been employed using auditory and visual cues to train patients to strengthen pelvic and rectal sphincter musculature, but its effectiveness is still unproven.<sup>15</sup> Pharmaceutical interventions including opioids such as loperamide and diphenoxylate hydrochloride/atropine, which increase gut transit time and allow for increased water absorption, are only variably effective in FI patients.<sup>16</sup>

Serum-derived bovine immunoglobulin/protein isolate (SBI) (EnteraGam<sup>TM</sup>) is a prescription medical food product indicated for the clinical dietary management of enteropathy (any intestinal disorder) in patients with chronic loose and frequent stools who have a limited or impaired capacity to ingest, digest, absorb, or metabolize certain nutrients and must be used under physician supervision. SBI is a specially formulated protein source consisting of >90% protein of which >50% is immunoglobulin G (IgG). Recent studies in humans demonstrate that SBI is safe and improves gastrointestinal symptoms (eg, chronic loose and frequent stools, abdominal discomfort, bloating, urgency) in irritable bowel syndrome with diarrhea (IBS-D)<sup>17</sup> and HIV-associated enteropathy.<sup>18</sup> Approximately 25–50% of orally administered IgG survives digestion in the stomach and small intestine. The mechanism of action of SBI is postulated to involve binding to microbial components, maintaining immune balance in the gastrointestinal tract, managing gut barrier function, and improving nutrient uptake.<sup>19</sup>

The aim of reporting this retrospective chart analysis of SBI administration for the management of chronic mesenteric ischemia (CMI)-linked chronic loose and frequent stools with FI is to provide information to the field of gastroenterology of the utility of this oral immunoglobulin preparation in this patient type.

## Methods

The choice to prescribe SBI as a nutritional agent to this CMI patient was based on peer-reviewed and published clinical studies regarding reduction in gastrointestinal symptoms including chronic loose and frequent stools.<sup>17,18</sup> This product is currently being used as standard-of-care for nutritional support in this practice for the management of chronic loose and frequent stools for a variety of intestinal disorders and such use matches the intended use for SBI (EnteraGam<sup>TM</sup>) from the company's package insert. Institutional review board approval for this retrospective case analysis is not required because this product is utilized as standard-of-care in this office for many forms of chronic loose and frequent stools as a nutritional add-on therapy. As such, this case report represents simply the patient response to normal care in a clinical setting. Patient consent was obtained to report the results of this retrospective case analysis. The patient is an 84-year-old male, 182 lbs, with a long-standing vascular disease, including CMI with a high grade obstruction of the celiac axis and superior mesenteric artery (SMA) not amenable to stenting (Fig. 1A–C). The interventional radiologist concluded that it was technically impossible to stent this patient, and comorbidities made surgery a poor option. Figure 1A shows the mesenteric circulation with obstructions in the celiac axis and SMA under contrast, while Figure 1B and C shows sagittal views of the celiac axis and SMA blockages, respectively. The inferior mesenteric artery (IMA) was not obstructed (data not shown). Comorbid conditions in this patient include long-standing atherosclerotic cardiovascular disease, coronary artery bypass grafting, coronary stents, right carotid stents, chronic atrial fibrillation, gastroesophageal reflux disease (GERD), benign prostate hyperplasia, and diarrhea with FI. For more than two decades, the patient experienced progressively worse symptoms of mesenteric ischemia, including postprandial abdominal pain with six to eight watery bowel movements daily (Bristol Stool Form Scale, Type 7), nocturnal diarrhea, and extreme urgency, as well as frequent episodes of FI. The patient had normal anal sphincter tone on digital examination, indicating sphincter continence. Therefore, changes in the intraluminal and mucosal regions might lead to resolution of diarrheal symptoms by reducing mucosal inflammation and altering intraluminal solute concentration. Workup included computerized tomographic angiography of the abdominal vessels (July 2010) and a colonoscopy (June 2010), which revealed extensive diverticulosis with findings of focal mild, acute, and chronic inflammation with denudation of surface epithelium in the sigmoid



**Figure 1.** Views of the celiac axis and SMA. (A) Impaired mesenteric circulation of patient in this case. (B) High grade obstruction of the celiac axis. (C) High grade obstruction of the SMA.

colon. Biopsies were consistent with chronic ischemic colitis. An endoscopy was also performed (June 2010). Findings from this procedure included a hiatal hernia and multiple ulcers with severe esophagitis. Biopsies showed esophageal squamous mucosa with chronic inflammation, basal cell hyperplasia, and elongation of vascular papillae, suggestive of reflux esophagitis. These findings were irrelevant to findings of ischemia and diarrhea. Laboratory evaluation showed

mild chronic anemia, iron deficiency (ferritin 10 ng/mL), and mild renal insufficiency (creatinine 1.44 mg/dL, estimated glomerular filtration rate 47 mls/minute/1.73 m<sup>2</sup>), but with normal nutritional parameters (magnesium 1.9 mg/dL, albumin 4.4 g/dL, cholesterol 150 mg/dL). Erythrocyte sedimentation rate and C-reactive protein were normal. Routine stool cultures were negative for both *Clostridium difficile* by polymerase chain reaction and fecal leukocytes, and thyroid function was normal.

Treatments for cardiovascular comorbidities currently include simvastatin, valsartan, atenolol, nifedipine, calcitriol, and aspirin. The patient also has a pacemaker. The patient is treated with a proton pump inhibitor, omeprazole (June 2010), for GERD. Attempted treatment of diarrheal symptoms included anticholinergics, loperamide, diphenoxylate/atropine, camphorated tincture of opium, and bismuth subsalicylate. The patient has not taken antibiotics for this condition. Omeprazole did not increase the intensity of the diarrhea. All treatments were unsuccessful in managing his gastrointestinal symptoms. The severity of the patient's symptoms included several weekly episodes of abdominal pain and FI, which profoundly affected his QoL. The patient also self-modified his diet to eat small frequent meals to avoid abdominal pain after consuming food. There was no weight loss or severe nutritional deficiency in this patient though there was mild chronic anemia and iron deficiency (see above). There were no findings that raised any suspicion of celiac disease or other gastrointestinal conditions. The patient was orally administered 5 g of SBI daily mixed in cereal or apple sauce over a four-week period in a gastroenterology office setting as part of standard-of-care in an attempt to manage chronic loose and frequent stools.

## Results

The patient tolerated SBI well, reporting no side effects to therapy. Within four weeks of initiating therapy with SBI, the patient stated dramatic management of his condition (Table 1). He reported a marked reduction in urgency to defecate, passing two to three soft, semi-formed stools daily (Bristol Stool Form Scale, Types 4 and 5) compared to six to eight watery stools per day (Bristol Stool Form Scale, Type 7) prior to being administered SBI. In addition, the patient also reported that nocturnal bowel movements and FI had ceased. This result may support the possibility that once this patient with normal sphincter tone was able to manage chronic loose stools, FI was markedly reduced. Postprandial responses to food intake were also altered with the patient experiencing no abdominal discomfort. His sense of well-being improved to the point that he is now able to drive for five hours for a recent vacation without incident. Finally, the patient, who is a widower, has developed a more active social life and has felt comfortable enough to start dating. The patient is currently well maintained on the same dose (5 g per day SBI) for the past seven months with no other anti-diarrheal medication,

**Table 1.** Symptoms response to therapy with serum-derived bovine immunoglobulin/protein isolate (SBI) due to chronic mesenteric ischemia (CMI).

SYMPTOM	BEFORE SBI	AFTER 4 WEEKS ON SBI
Postprandial abdominal discomfort	Moderate-severe postprandial discomfort which worsened after large meals	No abdominal discomfort
Stool frequency	6–8 watery stools per day (Bristol Stool Form Scale, Type 7)	2–3 soft, semi-formed stools per day (Bristol Stool Form Scale, Type 4–5),
Fecal incontinence	Weekly episodes of FI with urgency to defecate; nocturnal diarrhea	Marked reduction in urgency; Cessation of FI episodes and nocturnal diarrhea

with no flare in gastrointestinal symptoms, and with no side effects to this nutritional product.

## Discussion

CMI is a rare condition resulting from long-standing atherosclerotic disease of multiple mesenteric vessels.<sup>20</sup> Decreased perfusion of blood supply to the intestine in CMI leads to ischemia and inflammation. Typical symptoms of CMI are postprandial abdominal pain, weight loss, nausea, vomiting, fear of food ingestion, and diarrhea. Most treatment of CMI involves procedural or surgical intervention. Unfortunately, the patient in this retrospective analysis was not a good candidate for intervention (stenting) based on the judgment of the physician and the interventional radiologist. The patient had also failed other routine pharmaceutical interventions for diarrheal symptoms and FI. His presentation of chronic diarrhea with FI was unusual for patients with CMI, but unresponsiveness to conventional therapies led to the choice to administer a medical food known to reduce gastrointestinal symptoms as well as chronic and loose frequent stools<sup>17,18</sup> to assist in managing his condition.

There are limited dietary modifications available for CMI patients. These generally include consumption of multiple, small, low-fat meals to manage abdominal pain. Another dietary intervention, which has yet to be formally evaluated in this patient sub-set in a clinical trial, is a medical food product composed primarily of serum-derived oral bovine immunoglobulins. Medical foods have decades of use in hospital situations as enteral feedings and were considered drugs prior to the passage of an update to the Orphan Drug Act in 1988. SBI, as a specially formulated immunoglobulin-enriched product, may provide nutritive benefits by supporting normal intestinal digestion, absorption, metabolism of ordinary foodstuffs by binding microbial components. This binding may foster a stable microbiota, maintain a homeostatic immune environment in the intestine, and manage gut barrier function, which promotes increased nutrient metabolism and utilization, as well as better fluid balance.<sup>19</sup> The data herein in this patient with CMI suggests that SBI provides for a distinctive nutritional requirement unique to this patient for the management of chronic loose and frequent stools, and as a consequence, FI. SBI has been tested for safety and efficacy with regard to management of chronic loose and frequent stools in IBS-D

and HIV-associated enteropathy.<sup>17,18</sup> The primary side effects observed in clinical trials (2–5%) have included mild nausea, constipation, stomach cramps, headache, and increased urination.

Severe intractable, chronic loose stools are difficult disorders to treat successfully, especially when accompanied with FI. Wald<sup>11</sup> considers this condition so detrimental to a patient's QoL that he has stated, "Fecal incontinence is a devastating nonfatal illness, resulting in considerable embarrassment and anxiety in those who have it." The exact cause of diarrhea in mesenteric ischemia is unknown, but metabolic stress because of decreased blood circulation may induce an apoptotic response in epithelial cells as well as abnormal barrier function with decreased tight junction protein expression.<sup>21</sup> Disrupted barrier function is known to lead to translocation of microbial components, which causes immune-activation that contributes to further barrier disruption and diarrheal symptoms. SBI has been shown in animal studies to restore homeostasis to gut barrier function and maintain tight junction protein expression (for review, see Ref. 19). SBI has also been shown to statistically reduce a marker of enterocyte damage, intestinal fatty acid binding protein, and increased D-xylose uptake in HIV+ patients with associated enteropathy, suggesting improved nutritional utilization.<sup>18</sup> These activities of a serum-derived bovine oral immunoglobulin formulation may account for the positive response to therapy in this CMI patient. Regardless of how SBI managed loose frequent stools and FI, the patient's condition remains well maintained and his QoL is greatly improved. Further study is warranted into the effects of SBI on chronic loose and frequent stools in CMI and other conditions/diseases that result in diarrhea, which may contribute to FI.

## Abbreviations

CMI, chronic mesenteric ischemia; IBS-D, diarrhea-predominant irritable bowel syndrome with diarrhea; FI, fecal incontinence; IgG, immunoglobulin G; QoL, quality of life; SBI, serum-derived bovine immunoglobulin/protein isolate.

## Acknowledgements

The authors would like to acknowledge the critical reading of the manuscript and recommendations made by Victoria Jasion, Raymond Panas, Hayley Young, Bryon Petschow and Gerald Klein.





## Author Contributions

Identified and collected the retrospective case study data: LG. Analyzed the data: LG, BPB. Wrote the first draft of the manuscript: BPB, LG. Contributed to the writing of the manuscript: LG, BPB. Agree with manuscript results and conclusions: LG, BPB. Jointly developed the structure and arguments for the paper: LG, BPB. Made critical revisions and approved final version: BPB, LG. All authors reviewed and approved of the final manuscript.

## REFERENCES

1. Whitehead WE, Borrud L, Goode PS, et al; Pelvic Floor Disorders Network. Fecal incontinence in U.S. adults: epidemiology and risk factors. *Gastroenterology*. 2009;137(2):512–517.
2. Perry S, Shaw C, McGrother C, et al; Leicestershire MRC Incontinence Study Team. Prevalence of faecal incontinence in adults aged 40 years or more living in the community. *Gut*. 2002;50:480–484.
3. Crome P. Prevalence of faecal incontinence. *Age Ageing*. 2002;31:322.
4. Tobin GW, Brocklehurst JC. Faecal incontinence in residential homes for the elderly; prevalence, aetiology and management. *Age Ageing*. 1986;15:41–46.
5. Baxter NN, Rothenberger DA, Lowry AC. Measuring fecal incontinence. *Dis Colon Rectum*. 2003;46:1591–1605.
6. Xu X, Menees SB, Zochowski MK, Fenner DE. Economic cost of fecal incontinence. *Dis Colon Rectum*. 2012;55(5):586–598.
7. Dunivan GC, Heymen S, Palsos OS, et al. Fecal incontinence in primary care: prevalence, diagnosis, and healthcare utilization. *Am J Obstet Gynecol*. 2010;202(5):493.e1–e6.
8. Cummings V, Holt R, van der Sloot C, Moore K, Griffiths D. Costs and management of urinary incontinence in long-term care. *J Wound Ostomy Continence Nurs*. 1995;22(4):193–198.
9. Baker D, Bice T. The influence of urinary incontinence on publicly financed home care services to low income elderly people. *Gerontologist*. 1995;35(3):360–389.
10. Wilson L, Brown J, Shin GP, Luc KO, Subak LL. Annual costs of urinary incontinence. *Obstet Gynecol*. 2001;98:398–406.
11. Wald A. Fecal incontinence. *N Engl J Med*. 2007;356:1648–1655.
12. Whitehead WE. Diagnosing and managing fecal incontinence: if you don't ask, they won't tell. *Gastroenterology*. 2005;129:6.
13. Bartlett L, Nowak M, Ho YH. Impact of fecal incontinence on quality of life. *World J Gastroenterol*. 2009;15(26):3276–3282.
14. Bliss DZ, Jung HJ, Savik K, et al. Supplementation with dietary fiber improves fecal incontinence. *Nurs Res*. 2001;50:203–213.
15. Norton C, Cody JD. Biofeedback and/or sphincter exercises for the treatment of faecal incontinence in adults. *Cochrane Database Syst Rev*. 2012;7:CD002111.
16. Omar MI, Alexander CE. Drug treatment for faecal incontinence in adults. *Cochrane Database Syst Rev*. 2013;6:CD002116.
17. Wilson D, Evans MD, Weaver E, Shaw AL, Klein GL. Evaluation of serum-derived bovine immunoglobulin protein isolate in subjects with diarrhea-predominant irritable bowel syndrome. *Clin Med Insights Gastroenterol*. 2013;6:49–60.
18. Asmuth DM, Ma ZM, Albanese A, et al. Oral serum-derived bovine immunoglobulin improves duodenal immune reconstitution and absorption function in patients with HIV enteropathy. *AIDS*. 2013;27:2207–2217.
19. Petschow B, Burnett B, Shaw A, Weaver E, Klein G. Serum-derived bovine immunoglobulin/protein isolate: postulated mechanism of action for management of enteropathy. *Clin Exp Gastroenterol*. 2014;7:1–10.
20. Chang JB, Stein TA. Mesenteric ischemia: acute and chronic. *Ann Vas Surg*. 2003;17(3):323–328.
21. Hsiao JK, Huang CY, Lu YZ, Yang CY, Yu LC. Magnetic resonance imaging detects intestinal barrier dysfunction in a rat model of acute mesenteric ischemia/reperfusion injury. *Invest Radiol*. 2009;44(6):329–335.