

# Patent ductus venosus presenting with cholestatic jaundice in an infant with successful trans-catheter closure using a vascular plug device

Anith Chacko, Celeste Kock<sup>1</sup>, Jayneel A Joshi<sup>2</sup>, Lindi Mitchell<sup>2</sup>, Samia Ahmad

Departments of Radiology, <sup>1</sup>Paediatric Gastroenterology and <sup>2</sup>Paediatric Cardiology, Steve Biko Academic Hospital, University of Pretoria, Pretoria, South Africa

**Correspondence:** Dr. Anith Chacko, Department of Radiology, Level 5, Steve Biko Academic Hospital, Steve Biko Road, Gezina, Pretoria - 0002, South Africa. E-mail: anithchacko@gmail.com

## Abstract

Persistent ductus venosus as a cause of cholestatic jaundice is very rare. Treatment varies, but is usually reserved for infants in whom complications develop. We report a 5-week-old female infant with cholestatic jaundice caused by a patent ductus venosus and subsequent successful treatment via a transcatheter occlusion using a vascular plug device.

**Key words:** Amplatzer® vascular plug; cholestatic jaundice; patent ductus venosus; transvenous occlusion; vascular plug embolisation; vascular plug occlusion

## Introduction

Ductus venosus is a connection between the left umbilical vein and the right hepatocardiic channel (which later becomes inferior vena cava) in fetal circulation [Figure 1]. The ductus closes immediately (within hours) after birth in the vast majority of term infants and within 2 days in the majority of premature infants.<sup>[1]</sup> Persistent patent ductus venosus is very rare worldwide, with varying treatment options including surgical ligation and banding, liver transplantation, and transcatheter detachable coil closure being described. To our knowledge, of the 27 reported cases worldwide, 9 cases<sup>[2-9]</sup> have utilized transcatheter treatment and coil or vascular plug embolization, and of these, only 6 were performed in children.<sup>[2,3,6-8]</sup> The most recent report is

of closure in a 14-year-old.<sup>[9]</sup> We report on a female infant with a patent ductus venosus, which was successfully treated by transvenous occlusion with a vascular plug at the age of 5 weeks.

## Case Report

### Clinical presentation

The infant initially presented to the pediatric gastroenterology department of our institution at the age of 3 weeks as a referral from a peripheral hospital for persistent cholestatic jaundice and failure to thrive. The referral was from a peripheral hospital following phototherapy and persistent jaundice. The patient was born at the peripheral hospital following a normal vaginal delivery at 38 weeks gestation

This is an open access article distributed under the terms of the Creative Commons Attribution-NonCommercial-ShareAlike 3.0 License, which allows others to remix, tweak, and build upon the work non-commercially, as long as the author is credited and the new creations are licensed under the identical terms.

**For reprints contact:** reprints@medknow.com

**Cite this article as:** Chacko A, Kock C, Joshi JA, Mitchell L, Ahmad S. Patent ductus venosus presenting with cholestatic jaundice in an infant with successful trans-catheter closure using a vascular plug device. Indian J Radiol Imaging 2016;26:377-82.

### Access this article online

#### Quick Response Code:



**Website:**  
www.ijri.org

**DOI:**  
10.4103/0971-3026.190419

with a birth weight of 2.59 kg, good Apgar scores, and no complications.

On clinical examination, the baby had deeply jaundiced sclera and skin. The abdomen was prominent with mild ascites and a 2 cm hepatomegaly with a sharp edge and smooth surface. No splenomegaly or signs of portal hypertension were evident.

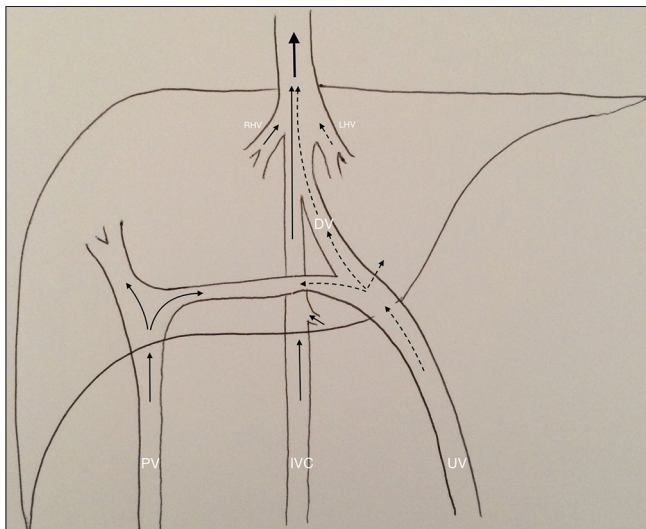
No congenital heart defects or abnormalities were present in the baby.

Liver function tests showed a conjugated (cholestatic) hyperbilirubinemia with initial total bilirubin levels of 27.4 mg/dl (468 μmol/l) and elevated liver enzymes, with a worsening trend over the course of several weeks [Table 1].

An abdominal ultrasound showed a vascular channel directly adjacent to the ligamentum teres [Figure 2]. The vascular channel was identified as a patent ductus venosus.

Inter-disciplinary meetings and discussions concurred that the infant was not fit for open surgery (surgical ligation of the ductus), and so, a minimally invasive approach was considered safest.

Thereafter, due to worsening liver function [Table 1] and development of features of hepatic encephalopathy, conventional angiography was performed for confirmation of diagnosis as well as treatment (closure) of the patent ductus venosus with the use of a detachable vascular plug device.



**Figure 1:** Sketch diagram of the normal anatomy of the hepatic circulation at birth. The dashed arrows indicate the flow of oxygenated blood from the placenta, while the solid black arrows indicate deoxygenated blood flow from the gastrointestinal tract in the portal vein and from the tributaries of the inferior vena cava. The large solid black arrow indicates combination of flow in the inferior vena cava flowing to the heart. (DV = Ductus venosus, IVC = Inferior vena cava, LHV = Left hepatic vein, PV = Portal vein, RHC = Right hepatic vein, UV = Umbilical vein)

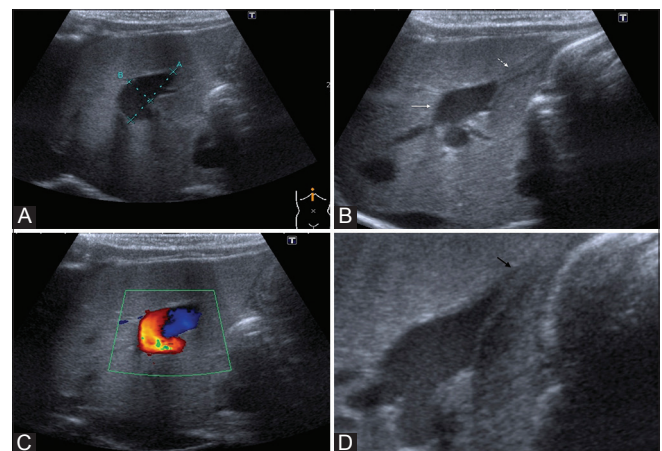
**Procedure**

The procedure was performed in the cardiac catheterization suite under general anesthesia using fluoroscopy. Dual fluoroscopic acquisition was used as it provided a more complete imaging procedure for the team. This was considered necessary as it was the team’s first such procedure and was considered safer. A combined effort by the pediatric cardiologists and interventional radiologists was required due to varying expertise between the clinicians. Access was obtained via the right jugular vein under sonar guidance (Aplio™ 300; Toshiba Medical Systems, Otawara City, Japan) with an indwelling

**Table 1: Progressive deterioration of liver function and subsequent improvement after vascular plug occlusion (\*) of the patent ductus venosus**

	Admission (age 3 weeks)	Age 4 weeks	*Age 5 weeks (procedure performed)	Age 7 weeks	Age 10 weeks
Tot br	27.4 mg/dL	27.6 mg/dL	26.2 mg/dL	8.1 mg/dL	3.7 mg/dL
Conj br	12.8 mg/dL	16.3 mg/dL	14.6 mg/dL	4.8 mg/dL	-
Albumin		28 g/L	32 g/L	31 g/L	34 g/L
ALP	390 U/l	724 U/l	473 U/l	348 U/l	-
GGT	28 U/l	24 U/l	26 U/l	45 U/l	-
AST	183 U/l	282 U/l	286 U/l	154 U/l	-
ALT	159 U/l	231 U/l	693 U/l	156 U/l	-
INR	1.4	1.38	1.35	-	-
PTT	48.25 sec	48.4 sec	41.85 sec	-	-
PT	15.3 sec	14.75 sec	14.75 sec	-	-
AFP	-	-	34 623 μg/L	-	10 958.0 μg/L

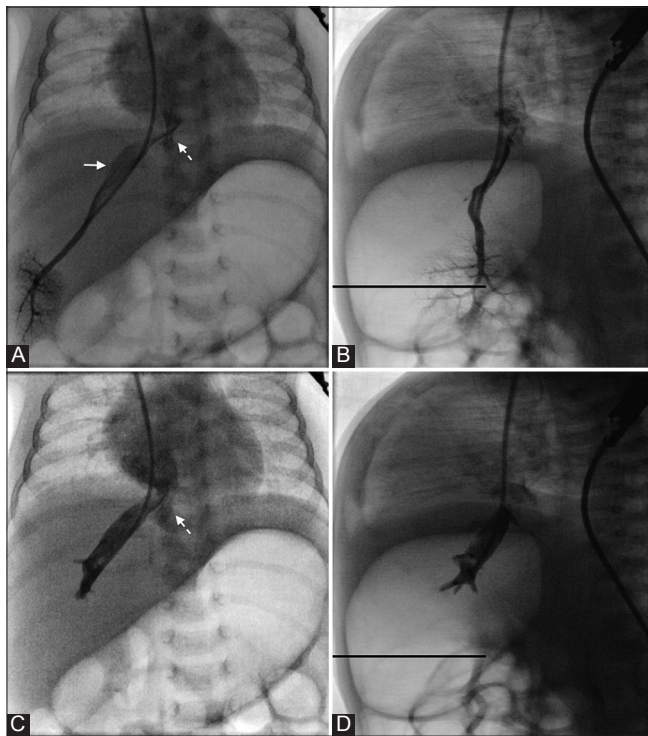
Tot br: Total bilirubin, Conj br: Conjugated bilirubin, ALP: Alkaline phosphatase, GGT: Gamma glutamyl transferase, AST: Aspartate aminotransaminase, ALT: Alanine aminotransaminase, INR: International normalized ratio, PTT: Prothrombin time, PT: Prolonged bleeding time, AFP: Alpha-fetoprotein



**Figure 2(A-D):** Sagittal ultrasound in a 5-week-old neonate with patent ductus venosus: (A) A cystic lesion is demonstrated within the right lobe of the liver (callipers) (B) The ligamentum teres (dashed white arrow) was identified in close relation to the cystic lesion (solid white arrow) (C) Color flow Doppler confirms the vascularity of the lesion (D) Zoomed image demonstrates the close relation and extension (solid black arrow) into the ligamentum teres confirming the diagnosis of a patent ductus venosus

sheath (Super Arrow-Flex<sup>®</sup> paediatric set; Teleflex Medical, Morrisville, NC, USA) placed *in situ* via the normal Seldinger technique. The right internal jugular access was deemed to provide the straightest approach to the patent ductus venosus, rather than via a femoral puncture. The guidewire used was a Terumo Small Vessel Guidewire 0.018" (Terumo Interventional Systems, Somerset, NJ, USA).

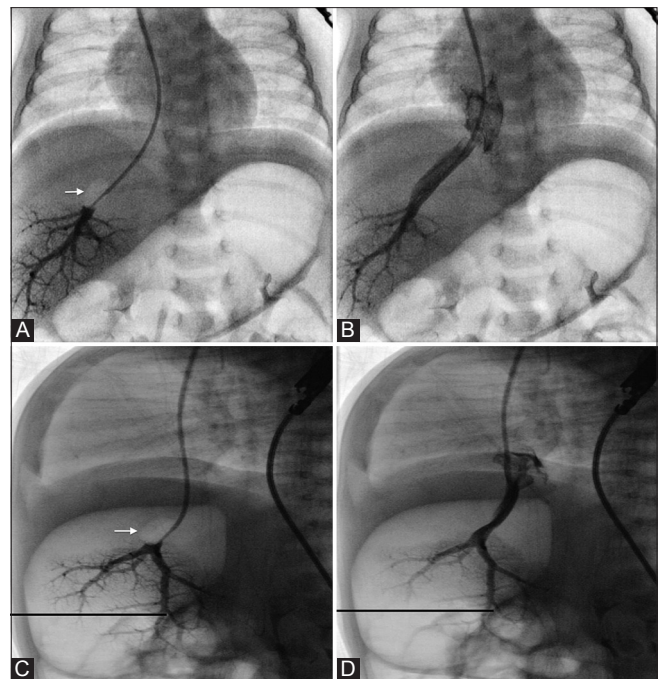
The initial angiographic run confirmed the presence of the patent ductus venosus [Figure 3], a normal inferior vena cava, as well as normal portal vein (not shown) and hepatic veins. Balloon occlusion (TransForm<sup>™</sup> Occlusion Balloon Catheter; Stryker, Kalamazoo, MI, USA) was performed to test whether closure of the patent ductus would affect portal venous pressures or hepatic venous flow to the liver parenchyma and drainage into the inferior vena cava [Figure 4]. The balloon occlusion catheter was placed into the patent ductus venosus and carefully inflated to occlude the ductus venosus. Occlusion was performed for approximately 5 s. Thereafter, a second angiographic run was performed to assess the flow within the ductus as well as within the portal and hepatic veins. The occlusion test successfully demonstrated adequate closure of the patent ductus venosus and subsequent patency and normalcy of the hepatic venous flow.



**Figure 3(A-D):** Vascular catheterization of the ductus venosus for delineation of anatomy in the frontal and lateral views. (A and B) Frontal and lateral views of the right hepatic vein and its communication with the patent ductus venosus (solid arrow) (C and D) Frontal and lateral views with the catheter tip within the distal aspect of the patent ductus. The dashed white arrow depicts the drainage of the patent ductus venosus into the right atrium via the inferior vena cava

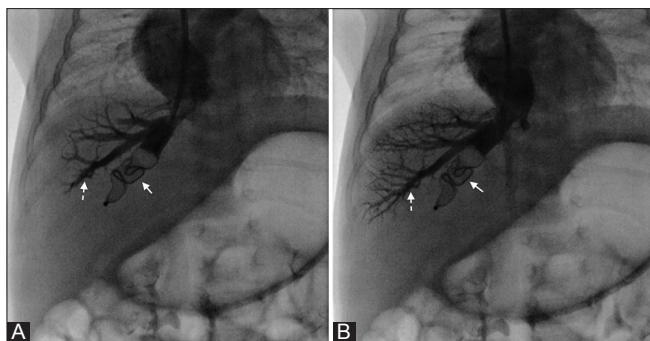
Once the vascular anatomy was defined and functional assessments were made by the occlusion test, accurate measurements were taken of the patent ductus venosus (the maximal diameter was 11.3 mm) on the angiographic run at the fluoroscopy console, and a correctly sized and appropriate vascular plug device (Amplatzer<sup>®</sup> vascular plug 2; St Jude Medical, St Paul, MN, USA) was selected for occlusion of the ductus venosus. The Amplatzer vascular plugs are made from a cylindrical nitinol wire mesh and are formed into different shapes by heat treatment. This allows for occlusion of wider vascular structures and for selection of appropriately sized and shaped devices as required in individual cases. The type chosen during the procedure was compatible for treatment of vessels with a size range of 2.0-16.9 mm.

A sleeve with a female thread on the proximal end of the device allows attachment of a delivery cable with a male screw, which then allows the device to be placed into the loader and delivery sheath. The device was successfully deployed using the proprietary Amplatzer delivery systems. Prior to detachment, angiographic runs demonstrated occlusion of the ductus venosus and patency of adjacent hepatic veins [Figures 5 and 6]. The device was successfully detached [Figure 6] and no complications were noted.



**Figure 4(A-D):** Balloon occlusion test of the patent ductus venosus. (A and B) Frontal and (C and D) lateral views showing the balloon catheterization to occlude the lumen of the patent ductus venosus. (A) and (C) demonstrate the balloon inflation (solid white arrows). The balloon was then deflated to depict flow of the ductus venosus directly into the inferior vena cava (B) and (D). No aberrant drainage/supply to or from the portal or hepatic veins was demonstrated during occlusion. Patency of the hepatic and portal veins was ensured during the balloon occlusion (not shown)





**Figure 5(A and B):** (A and B) Deployment of the vascular plug into the patent ductus venosus. Frontal views after insertion and deployment of the vascular plug (solid white arrows) into the ductus venosus, but prior to detachment. Angiography confirms patency and drainage of the right hepatic vein (dashed arrows)

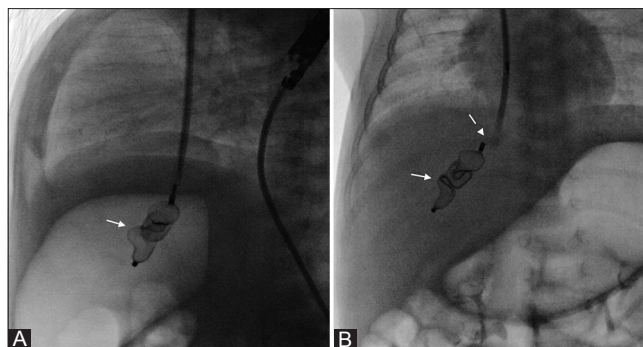
### Outcome and follow-up

The patient was admitted to intensive care following the procedure and serial liver functions showed marked improvement of the hepatic failure and decrease in hepatic enzymes [Table 1]. Monitoring over the course of a week demonstrated normalizing liver function tests and improved neurology in terms of alertness and decreased stupor due to improved hepatic encephalopathy. Follow-up ultrasound of the abdomen confirmed the persistent closure of the ductus venosus. The patient was subsequently discharged from the unit with no complications. Follow-up at 4 weeks after placement of the vascular device showed the sclera to still be slightly jaundiced, but a marked improvement was evident. On abdominal examination, a 2 cm liver was still palpable with no ascites and no splenomegaly. She had gained a total of 2.5 kg and was on par with developmental milestones. The liver enzyme profile showed marked improvement 1 week after placement of the device [Table 1 (week 7)] and continued to show improvement thereafter.

### Discussion

Ductus venosus is a direct communication between the left umbilical vein and the right hepatocardiac channel, which forms in the second month of fetal life.<sup>[10]</sup> The vessel carries nutrient-rich blood directly from the placenta to the right atrium, bypassing the sinusoidal plexus of the liver, for distribution to the systemic system in the fetus. After birth, the umbilical vein and ductus venosus close shortly after the umbilical arteries and form the ligamentum teres and ligamentum venosum.

With postpartum closure of the umbilical vein, the blood flow and blood pressure in the umbilical vein decrease abruptly, leading to functional closure of the vascular shunt. This can occur within a few minutes after birth to as late as 18 days in term infants and 37 days after birth in premature infants. Permanent closure of the ductus venosus occurs with thrombosis and final fibrotic change of the vascular shunt into the ligament venosum.<sup>[11]</sup>



**Figure 6(A and B):** (A and B) Detachment of the vascular plug for occlusion of the patent ductus venosus. The vascular plug device (solid white arrows) is *in situ* within the ductus venosus with successful detachment (dashed white arrow)

In addition to occurring in prematurity, prolonged patency of ductus venosus has been seen in congenital heart disease (atrial septal defect and tricuspid regurgitation), pulmonary hypertension, hydrops fetalis, multiple coronary fistulas, hypoplastic right hepatoportal system, tumor-like lesions of the liver, cirrhosis, and fatty infiltration of the liver.<sup>[11]</sup>

A patent ductus venosus is an intra-hepatic portocaval shunt and can be the cause of hyperammonemia and encephalopathy in affected neonates.<sup>[12]</sup> This is due to the partial or complete diversion of portal blood to the systemic circulation. One theory of the cause of the cholestatic jaundice is that the presence of the shunt would decrease the perfusion of the neonatal liver, which is a factor known to increase cholestasis in neonates.<sup>[13]</sup> Another study performed on premature and term neonates showed that a patent ductus venosus is closely related to and negatively affects crucial liver functions such as ammonia detoxification, blood coagulation, and regulation of total bile acid concentration in early neonates, and can therefore lead to complications such as cholestatic jaundice.<sup>[14]</sup>

The search for a shunt as a cause should, therefore, definitely be part of the investigation of a cause for neonatal cholestatic jaundice, but should also include investigation of other possible causes including biliary atresia (commonest cause of persistent neonatal jaundice), respiratory chain disorders, or adrenal insufficiency.<sup>[13]</sup> These causes can all easily be evaluated and differentiated using ultrasound, which is non-invasive and radiation free.

A patent ductus venosus in neonates is detectable on Doppler sonography as a vascular tubular structure in the left lobe of the liver, continuing from the umbilical vein and connecting the portal vein to the inferior vena cava. Lack of familiarity with the sonographic appearance of a patent ductus venosus may cause incorrect diagnosis of hepatic varices or other abnormal intra-hepatic vascular shunts.<sup>[11]</sup> The patent ductus venosus can also cause confusion on

gray-scale sonography, with possible mimics being abscesses or tumors.<sup>[11]</sup> The discrimination between these entities can be made using color Doppler.

Doppler sonography has shown that the waveforms of blood flow in the fetal ductus venosus correlate with the cardiac cycle having a systolic and diastolic forward component, similar to that demonstrated in the inferior vena cava. In pre-term and term infants, the ductus venosus initially exhibits similar diphasic waveforms and over time become less diphasic and more monophasic, reflecting the closure of the ductus venosus.<sup>[15]</sup>

A complete, functionally closed shunt can appear as an avascular hypoechoic area and can mimic a hepatic abscess in septic infants or as a heterogeneously hyperechoic region suggesting a liver tumor.<sup>[11]</sup> However, differentiation can be made in correlation with clinical picture and via follow-up sonography which shows a progressively hyperechogenic ductus venosus with decrease in size.

The five main complications of portosystemic shunts are neonatal cholestasis, liver tumors, hepatopulmonary syndrome, pulmonary hypertension, and portosystemic encephalopathy.<sup>[13]</sup>

Management of portosystemic shunts in the pediatric population is controversial with various treatment options such as surgical ligation and banding, liver transplantation, and transcatheter detachable coil closure being used worldwide.<sup>[13]</sup>

Recommendations from some authors<sup>[13]</sup> are to avoid early closure in neonates presenting with cholestatic jaundice, as in their experience, there is spontaneous resolution within 2–5 months. Treatment (closure) is recommended in cases with complications or to prevent complications if the shunts persisted beyond 2 years of age.<sup>[13]</sup>

Surgical management of the patent ductus venosus can present difficulties due to the occasional complex nature of the lesion and also due to lack of relevant expertise, whereas transvenous occlusion is used extensively for embolization of non-variceal portosystemic collaterals using a transjugular approach and necessary expertise can easily be transferred. The technique of transcatheter occlusion removes the need for complex surgery and can be advantageous in the infant population.<sup>[1]</sup>

Pre-procedural vascular mapping [Figure 3] of the hepatic vasculature aids accurate delivery of the device and delineation of any other aberrant vessels, as well as ensures that essential vasculature is not inadvertently occluded. Balloon occlusion of the patent ductus venosus was used in our setting [Figure 4] to test for aberrant drainage/supply to or from the portal or hepatic veins and the ductus venosus

and to ensure that there was no increase in portal pressures with closure of the ductus venosus. Our use of the vascular plug device was deemed to be advantageous in that the device is only deployed once it is actively detached. This ensures accurate placement and enables the team to check patency of associated hepatic veins prior to detachment, which can prevent potentially disastrous complications of hepatic vein thrombosis [Figures 5 and 6]. This is in contrast to conventional coil embolization techniques that could have been employed.

Hepatic failure and encephalopathy prompted intervention in our patient. The clinical recovery, normalization of liver function tests, and the persistent closure of the patent ductus venosus in our patient do indicate that this indeed was the cause for the cholestatic jaundice and that the therapy was necessary and effective.

## Conclusion

Patent ductus venosus is a rare cause of cholestatic jaundice. Sonography plays an important role in diagnosis of the condition and exclusion of other causes of cholestatic jaundice. Radiologists should be aware of the location and variable sonographic features of the ductus venosus from patency to closure in order to accurately make the diagnosis and prevent an incorrect diagnosis. Transvenous occlusion of the patent ductus venosus with a vascular plug device offers a safe and effective method of treatment in the pediatric population.

## Financial support and sponsorship

Nil.

## Conflicts of interest

There are no conflicts of interest.

## References

1. Loberant N, Herskovits M, Barak M, Ben-Elisha M, Herschkowitz S, Sela S, *et al.* Closure of the ductus venosus in premature infants: Findings on real-time gray-scale, color-flow Doppler, and duplex Doppler sonography. *AJR Am J Roentgenol* 1999;172:227-9.
2. Schwartz YM, Berkowitz D, Lorbert A. Transvenous coil embolisation of a patent ductus venosus in a 2-month-old child. *Pediatrics* 1999;103:1045-7.
3. Marx M, Huber WD, Crone J, Lammer J, Perneczky-Hintringer E, Heller S, *et al.* Interventional stent implantation in a child with patent ductus venosus and pulmonary hypertension. *Eur J Pediatr* 2001;160:501-4.
4. Shen B, Younossi ZM, Dolmatch B, Newman JS, Henderson JM, Ong JP, *et al.* Patent ductus venosus in an adult presenting as pulmonary hypertension, right-sided heart failure, and portosystemic encephalopathy. *Am J Med* 2001;110:657-60.
5. Araki T, Konishi T, Yasuda S, Osada T, Araki T. Embolization of the patent ductus venosus in an adult patient. *AJR Am J Roentgenol* 2003;180:716-8.
6. Araki T, Kamada M, Okamoto Y, Arai S, Oba O. Coil embolization

- of a patent ductus venosus in a 52-day-old girl with congenital heart disease. *Ann Thorac Surg* 2003;75:273-5.
7. Gillespie MJ, Golden A Sivaraiian VB, Rome JJ. Transcatheter closure of patent ductus venosus with the Amplatzer vascular plug in twin brothers. *Pediatr Cardiol* 2006;27:142-5.
  8. Cho YK, Chang NK, Ma JS. Successful transcatheter closure of a large patent ductus venosus with the Amplazer vascular plug II. *Pediatr Cardiol* 2009;30:540-2.
  9. Llanos D, Armijo J, Bodas A, Vaquero, E, de la Pedraja I, Arrazola J. Transjugular closure of a patent ductus venosus in a symptomatic 14-year-old boy using a vascular plug. *J Pediatr* 2014;164;426:e1-2.
  10. Sadler TW. *Langman's Medical Embryology*. 11<sup>th</sup> ed. Philadelphia: Wolters Kluwer and Lippincott, Williams and Wilkins; 2004. p. 193-8.
  11. Vade A, Lim-Dunham J, Iqbal N. Imaging of the ductus venosus in neonates. *J Ultrasound Med* 2001;20:681-7.
  12. Gitzelmann R, Arbenz UV, Willi UV. Hypergalactosaemia and portosystemic encephalopathy due to persistence of ductus venosus Arantii. *Eur J Pediatr* 1992;151:564-8.
  13. Franchi-Abella S, Branchereau S, Lambert V, Fabre M, Steimberg C, Losay J, *et al.* Complications of congenital portosystemic shunts in children: Therapeutic options and outcomes. *J Pediatr Gastroenterol Nutr* 2010;51:322-30.
  14. Murayama K, Nagasaka H, Tate K, Ohson Y, Kanazawa M, Kobayashi K, *et al.* Significant correlations between the flow volume of patent ductus venosus and early neonatal liver function: Possible involvement of patent ductus venosus in postnatal liver function. *Arch Dis Child Fetal Neonatal Ed* 2006;91:F175-9.
  15. Huisman TW, Stewart PA, Wladimiroff JW. Ductus venosus blood flow velocity waveforms in the human fetus-a Doppler study. *Ultrasound Med Biol* 1992;18:33-7.