

[CASE REPORT]

Primary Oral Mucormycosis Due to *Rhizopus microsporus* after Allogeneic Stem Cell Transplantation

Hikaru Sakamoto¹, Hidehiro Itonaga¹, Yasushi Sawayama¹, Jun Taguchi², Tomomi Saijo³, Sayaka Kuwatsuka⁴, Mikiko Hashisako⁵, Naoe Kinoshita⁵, Masao Oishi⁶, Hanako Doi⁶, Kosuke Kosai⁷, Katsutaro Nishimoto⁸, Katsumi Tanaka⁶, Katsunori Yanagihara⁷, Hiroshi Mukae³, Koichi Izumikawa^{9,10} and Yasushi Miyazaki^{1,11}

Abstract:

We herein report a rare case of oral mucormycosis following allogeneic hematopoietic stem cell transplantation. Oral mucormycosis due to *Rhizopus microsporus* manifested as localized left buccal mucositis with a 1-cm black focus before neutrophil recovery. Combination therapy with liposomal amphotericin B was initiated and surgical debridement was performed; however, the patient died due to progressive generalized mucormycosis. Considerable attention needs to be paid to the diagnosis and management of oral mucormycosis in post-transplant patients, thereby suggesting the importance of fully understanding the risk factors.

Key words: oral mucormycosis, allogeneic hematopoietic stem cell transplantation, acute myeloid leukemia

(Intern Med 57: 2567-2571, 2018)

(DOI: 10.2169/internalmedicine.0474-17)

Introduction

Mucormycosis is a rare infectious complication with an incidence of 0.6% among patients who received allogeneic hematopoietic stem cell transplantation (allo-HSCT) (1). Mucormycosis as a breakthrough infection appears to have increased among patients with hematological diseases because of the use of anti-aspergillus azoles or echinocandins as routine prophylaxis (2). Mucormycosis typically presents as an acute, aggressive, and frequently angio-invasive mold infection, and it is often a life-threatening opportunistic infection after allo-HSCT (1). The risk factors for mucormycosis include poorly controlled diabetes mellitus, iron overload, a previous history of iron-chelating therapy, the development of graft-versus-host disease, prolonged neutropenia, and sys-

temic corticosteroid administration (3-5). However, no risk-stratified therapeutic modality has yet been established. Therefore, mucormycosis needs to be diagnosed at an early stage. Based on previous findings showing the successful outcomes of complete surgical debridement together with liposomal amphotericin B (L-AMB) (4, 6, 7), an early diagnosis of oral mucormycosis appears to be advantageous for minimizing the amount of tissue that needs to be removed.

Mucormycosis manifests in 6 predominant clinical forms: rhino-cerebral, pulmonary, cutaneous, gastrointestinal, disseminated, and miscellaneous, including oral (3). Pulmonary lesions are a common manifestation in patients with hematological diseases including post-transplant patients (4); however, manifestations other than the pulmonary form are very rare. Oral mucormycosis has been reported to also develop in immunocompromized patients, such as those with poorly

¹Department of Hematology, Nagasaki University Hospital, Japan, ²Department of Hematology, Japanese Red Cross Nagasaki Genbaku Hospital, Japan, ³Department of Respiratory Medicine, Graduate School of Biomedical Sciences, Nagasaki University, Japan, ⁴Department of Dermatology, Nagasaki University Graduate School of Biomedical Sciences, Japan, ⁵Department of Pathology, Nagasaki University Hospital, Japan, ⁶Department of Plastic and Reconstructive Surgery, Graduate School of Biomedical Sciences, Nagasaki University, Japan, ⁷Department of Laboratory Medicine, Nagasaki University Hospital, Japan, ⁸Department of Dermatology, Nagasaki Ekisaikai Hospital, Japan, ⁹Department of Infectious Diseases, Nagasaki University Graduate School of Biomedical Sciences, Japan, ¹⁰Infection Control and Education Center, Nagasaki University Hospital, Japan and ¹¹Department of Hematology, Atomic Bomb Disease and Hibakusha Medicine Unit, Atomic Bomb Disease Institute, Nagasaki University, Japan

Received for publication November 9, 2017; Accepted for publication January 14, 2018

Correspondence to Dr. Hidehiro Itonaga, itonaga-ngs@umin.ac.jp

controlled diabetes mellitus, and *Rhizopus oryzae* is the most frequent pathogen. (4, 8). But it is unclear whether the clinical manifestation of oral mucormycosis differs according to the type of the pathogen. In this article, we describe a rare case of oral mucormycosis caused by *Rhizopus microsporus* in post-transplant patients.

Case Report

A 56-year-old male was diagnosed with secondary acute myeloid leukemia (AML) which had transformed from polycythemia vera in September, 2009. The laboratory findings were as follows: white blood cell count, $54.8 \times 10^9/L$ with 37% myeloblasts and 49% neutrophils; hemoglobin level, 15.0 g/dL; platelet count, $502 \times 10^9/L$. The patient had no apparent underlying complications, potential infectious diseases or any specific opportunity of environment, including his occupation, exposure to *Mucor* species (e.g., decaying vegetation and soil, barns, compost piles, plants, and smoking), and had not been administered voriconazole or iron chelators. Standard chemotherapy with cytarabine and daunorubicin did not result in hematological remission. The patient was isolated in a laminar air flow room from the initiation of induction therapy. Treatment with low-dose cytarabine was subsequently administered to debulk AML blasts before allo-HSCT. The patient's general condition was maintained without any infectious diseases or oral mucositis despite prolonged severe neutropenia. The patient did not have any donor candidates among his siblings or in the Japan Marrow Donor Program. After receiving one course of low-dose cytarabine, unrelated cord blood transplantation (total nucleated cell dose, 4.28×10^7 cells/kg; CD34-positive cell dose, 0.62×10^5 cells/kg; HLA 4/6 loci mismatched, from a male donor) was performed using myeloablative conditioning (fludarabine 120 mg/m², intravenous busulfan 12.8 mg/m², and total body irradiation 4 Gy / 2 fr.) in October 2010. Tacrolimus and oral mycophenolate mofetil were used as agents for graft-versus-host disease (GVHD) prophylaxis. Micafungin at 50 mg daily and levofloxacin at 500 mg daily were administered for anti-fungal and -bacterial prophylaxis, respectively.

On day +6 of transplantation, the patient developed fever with grade 3 oral mucositis during persistent severe neutropenia. According to the c-D-index, the scoring system to predict invasive mold infection, such as aspergillosis, based on the severity and duration of neutropenia (9), his condition was classified as high-risk (c-D-index 6,940). However, routine microbiological tests were negative: neither bacteria nor fungi were detected in the blood cultures. Furthermore, β -D glucan and galactomannan antigens were not elevated and computed tomography did not reveal any infectious lesions. Antibiotic agents were initiated for the oral infection and improved his fever and oral mucositis. On day +15, the patient re-presented with fever and localized left buccal mucositis with a 1-cm black focus in swollen cheek skin. Dermatitis progressed rapidly despite treatments with 5 different

antibiotics, and his general condition deteriorated (Fig. 1A and B). Computed tomography revealed edematous changes in the larynx and pharynx, and subcutaneous swelling from the left cheek to the neck (Fig. 1C and D). Oral mucormycosis was clinically diagnosed based on the clear boundary of necrotic tissue with an obstructed airway. A skin biopsy on day +24 showed that the necrotic surface layer was covered with non-septate hyphae with branching at wide angles (Fig. 2A-C). Fungal cultures revealed broad hyphae with very few septa that produced long sporangiospores terminating with a dark and round sporangium (Fig. 2D). A molecular analysis using a polymerase chain reaction method identified *Rhizopus microsporus* as follows; DNA was extracted from fungi cultured in Sabouraud agar using a nucleic acid extraction kit (Kyokuto Pharmaceutical Industrial, Tokyo, Japan). Next, using the extracted DNA as a template, PCR was carried out with the fungal D1/D2 region as a target using a kit [Fungal rDNA (D1/D2) PCR kit fast, Takara, Kusatsu, Japan] (http://www.clontech.com/JP/Products/PCR/Pathogen_Detection_and_Screening_Kits/Bacterial_Pathogen_Detection/rDNA_PCR_Kits?site=10025:22372:US), as previously described (10). The PCR amplification product of approximately 650 bps was purified and labeled, and the nucleotide sequence was determined by direct sequencing (Genetic Analyzer 3130, Applied Biosystems, Tokyo, Japan). Based on the obtained nucleotide sequence, the homology of the nucleotide sequence was analyzed using a database (BLAST), and the one having the highest homology was used to identify the fungal species.

The administration of 5 mg/kg/day L-AMB was initiated and surgical debridement was performed on day +24, as described previously (4, 6, 7). However, debridement could not be completed due to the presence of a large necrotic lesion involving the floor of the mouth, tongue, and mandibula. The patient was treated with L-AMB for 7 days, but died on day +31 after allo-HSCT (Fig. 3).

Discussion

Oral mucormycosis in this patient occurred before neutrophil engraftment after transplantation, rapidly progressed despite combination therapy with the administration of L-AMB and surgical debridement, and resulted in a fatal outcome. Mucormycosis mostly involves pulmonary or rhinocerebral lesions at the late phase after allo-HSCT (3-5), while oral mucormycosis is more likely to occur before neutrophil recovery (11-14). The clinical course of this case indicated the important risk factors for oral mucormycosis after allo-HSCT.

This case had sustained neutropenia, even before undergoing allo-HSCT, which may have been related to refractory AML itself and chemotherapy until shortly before HSCT. The prolonged neutropenic period before and after HSCT (high c-D-index on day +6 of allo-HSCT) may have had an unfavorable influence on mucormycosis. Although the D-index and c-D-index were originally established to estimate

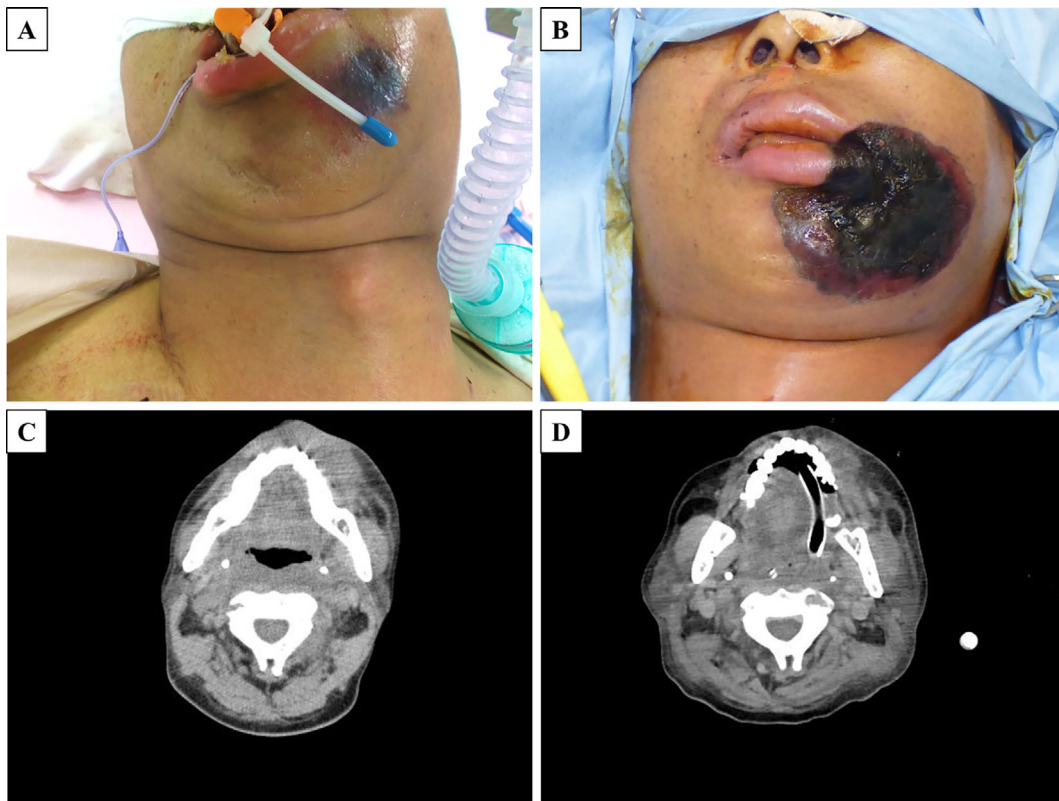


Figure 1. Skin appearance and computed tomography findings of oral mucormycosis. A black necrotic area progressively enlarged on day+15 (A) and day+24 (B) after transplantation. Computed tomography showed swelling of the oral mucosa and lower jaw skin that rapidly progressed on day+18 (C) and day+20 (D).

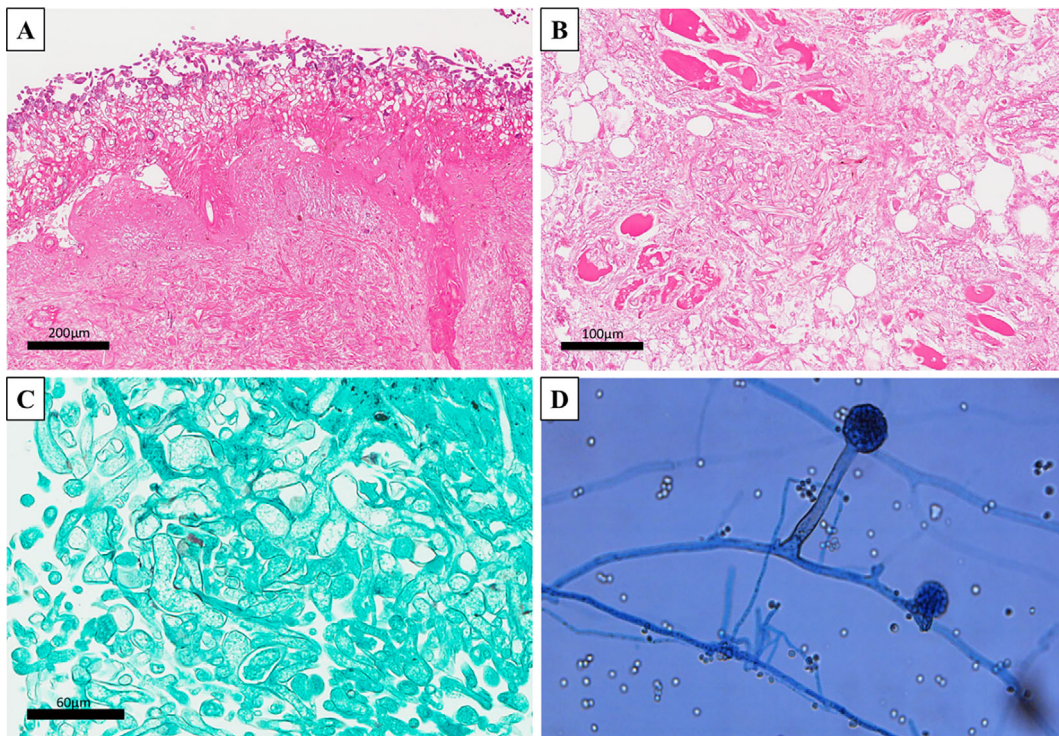


Figure 2. Pathological findings and a tissue culture of oral mucormycosis. A skin biopsy specimen was completely necrotic, with a surface that was covered by non-septate hyphae with branching at wide angles [Hematoxylin and Eosin (H&E) staining, 100 \times] (A). Hyphae infiltrated the vessels and surrounding subcutaneous tissue (H&E staining, 200 \times) (B). Grocott's methenamine silver stain revealed the presence of fungal hyphae (400 \times) (C). A skin culture grew *Mucor* spp. (D).

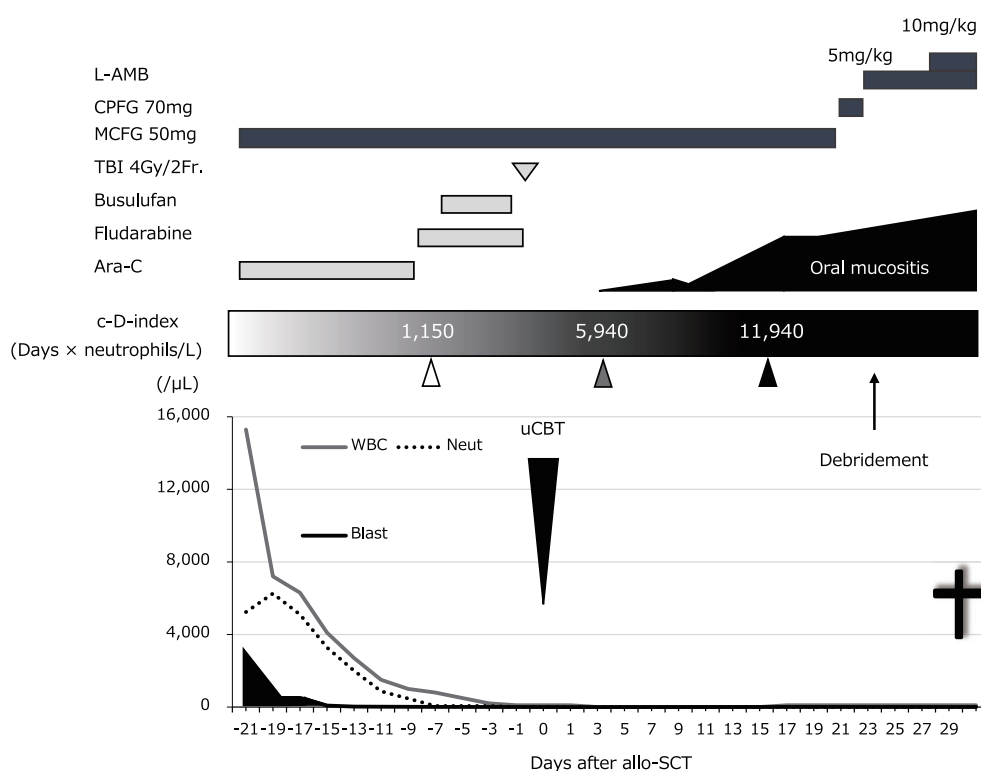


Figure 3. The clinical course from the initiation of low-dose Ara-C to post-transplantation. The intensity and duration of neutropenia persisted before and after allo-HSCT, and the c-D-index exceeded 5,800 (i.e., the cut-off point of the c-D-index to estimate the risk of mold infection, mainly aspergillosis) on day+4 after allo-HSCT. Fever with oral mucositis developed on day+6, and a black necrotic area due to mucormycosis was identified on day+15. L-AMB: liposomal amphotericin B, CPFG: caspofungin, MCFG: micafungin, TBI: total body irradiation, Ara-C: cytosine arabinose, uCBT: unrelated cord blood transplantation, WBC: white blood cell, allo-HSCT: allogeneic stem cell transplantation, c-D-index: cumulative D-index

the risk of mold infection, mainly aspergillosis, these indexes might be also useful for predicting the risk of mucormycosis, which was calculated including the neutropenic period before and after transplantation. Considering the serious clinical course of mucormycosis, it is necessary to establish either a scoring system for its prediction or a risk assessment system using a large cohort of patients under severe immune suppression, such as those with prolonged neutropenia, and those after transplantation.

Oral mucositis in the present case may have been closely related to the development of oral mucormycosis. Mucosal toxicity appeared to have been enhanced by cytotoxic chemotherapy before the conditioning regimen, and conditioning with radiation severely aggravated it, thus increasing the risk of invasive oral infection.

Furthermore, the prolonged use of Micafungin from before transplantation also promoted the development of oral mucormycosis through selective pressure on molds (15, 16). Based on the efficacy of L-AMB for patients with febrile neutropenia (17), its administration represents an important therapeutic option as an initial empirical therapy when patients have a condition similar to that observed in the present case. Because there is a report demonstrating that *Rhizopus microsporus* was less sensitive to posaconazole than

other *Mucor* species *in vitro* (18), the use of L-AMB as an initial empirical therapy should thus be considered for patients suspected of having oral mucormycosis.

The early application of combination therapy with complete surgical debridement and L-AMB administration has been reported to be successful in some cases with oral mucormycosis (12, 13). Surgical debridement was performed and the administration of L-AMB was also initiated for the present case, but these treatments failed to successfully treat the disease. Due to the limitations associated with the diagnostic modality used to detect mucormycosis at an early phase, the development of novel methods is required for severely neutropenic patients. Recent studies reported that a quantitative polymerase chain reaction (PCR) for the detection of circulating DNA using serum samples is effective for diagnosing mucormycosis at an early stage (19, 20), and a novel antigen specific to *Rhizopus* species was identified using an animal model (21). A preemptive strategy for mucormycosis using L-AMB guided by a PCR method and antigen detection to identify invasive aspergillosis using the galactomannan test may thus be warranted in the future (22, 23).

In conclusion, considerable attention needs to be paid to the diagnosis and management of oral mucormycosis in

post-transplant patients with the following risk factors: (i) persistent neutropenia before and after transplantation, (ii) the potential risk of oral mucositis by cytotoxic treatments before the initiation of a conditioning regimen, and (iii) the use of azole or echinocandin as prophylaxis. In the present practice, performing combination therapy with complete surgical debridement and the administration of L-AMB should be applied as early as possible when mucositis with a small necrotic area develops in patients with such risk factors.

Author's disclosure of potential Conflicts of Interest (COI).

Kosuke Kosai: Honoraria, Sumitomo Dainippon Pharma and MSD; Research funding, MSD. Katsunori Yanagihara: Honoraria, Sumitomo Dainippon Pharma, Astellas Pharma and MSD; Research funding, Sumitomo Dainippon Pharma, Astellas Pharma and MSD. Hiroshi Mukae: Honoraria, Sumitomo Dainippon Pharma, Astellas Pharma and MSD; Fees for promotional materials, Sumitomo Dainippon Pharma, Astellas Pharma and MSD. Koichi Izumikawa: Honoraria, Sumitomo Dainippon Pharma, Astellas Pharma and MSD; Research funding, Sumitomo Dainippon Pharma, Astellas Pharma and MSD.

References

- Riches ML, Trifilio S, Chen M, et al. Risk factors and impact of non-Aspergillus mold infections following allogeneic HCT: a CIBMTR infection and immune reconstitution analysis. *Bone Marrow Transplant* **51**: 277-282, 2016.
- Kume H, Yamazaki T, Togano T, et al. Epidemiology of visceral mycoses in autopsy cases in Japan: comparison of the data from 1989, 1993, 1997, 2001, 2005 and 2007 in annual of pathological autopsy cases in Japan. *Med Mycol J* **52**: 117-127, 2011.
- Petrikkos G, Skiada A, Lortholary O, Roilides E, Walsh TJ, Kontoyiannis DP. Epidemiology and clinical manifestations of mucormycosis. *Clin Infect Dis* **54**(Suppl 1): S23-34, 2012.
- Roden MM, Zaoutis TE, Buchanan WL, et al. Epidemiology and outcome of zygomycosis: a review of 929 reported cases. *Clin Infect Dis* **41**: 634-653, 2005.
- Leithauser M, Kahl C, Aepinus C, Prall F, Maruschke M, Junghans C. Invasive zygomycosis in patients with graft-versus-host disease after allogeneic stem cell transplantation. *Transpl Infect Dis* **12**: 251-257, 2010.
- Tissot F, Agrawal S, Pagano L, Petrikkos G, Groll AH, Herbrecht R. ECIL-6 guidelines for the treatment of invasive candidiasis, aspergillosis and mucormycosis in leukemia and hematopoietic stem cell transplant patients. *Haematologica* **102**: 433-444, 2017.
- Kontoyiannis DP, Lewis RE. How I treat mucormycosis. *Blood* **118**: 1216-1224, 2011.
- Deepa A, Nair BJ, Sivakumar T, Joseph AP. Uncommon opportunistic fungal infections of oral cavity: A review. *J Oral Maxillofac Pathol* **18**: 235-243, 2014.
- Portugal RD, Garnica M, Nucci M. Index to predict invasive mold infection in high-risk neutropenic patients based on the area over the neutrophil curve. *J Clin Oncol* **27**: 3849-3454, 2009.
- Yamada A, Hashikura Y, Takeda N, et al. A case of Kerion Celsi caused by *Trichophyton tonsurans* identified using nucleotide sequence analysis. *Jpn J Med Technol* **63**: 216-220, 2014 (in Japanese, Abstract in English).
- Metzen D, Böhm H, Zimmermann M, Reuther T, Kübler AC, Müller-Richter UD. Mucormycosis of the head and neck. *J Craniomaxillofac Surg* **40**: 321-327, 2012.
- McDermott NE, Barrett J, Hipp J, et al. Successful treatment of periodontal mucormycosis: report of a case and literature review. *Oral Surg Oral Med Oral Pathol Oral Radiol Endod* **109**: e64-e69, 2010.
- Epstein JB, Kupferman SB, Zabner R, Rejali A, Hopp ML, Tzachanis D. Early diagnosis and successful management of oral mucormycosis in a hematopoietic stem cell transplant recipient: case report and literature review. *Early Support Care Cancer* **24**: 3343-3346, 2016.
- Al Akhrass F, Debiene L, Abdallah L, et al. Palatal mucormycosis in patients with hematologic malignancy and stem cell transplantation. *Med Mycol* **49**: 400-405, 2011.
- Trifilio S, Singhal S, Williams S, Frankfurt O, Gordon L, Mehta J. Breakthrough fungal infections after allogeneic hematopoietic stem cell transplantation in patients on prophylactic voriconazole. *Bone Marrow Transplant* **40**: 451-456, 2007.
- Marty FM, Cosimi LA, Baden LR. Breakthrough zygomycosis after voriconazole treatment in recipients of hematopoietic stem-cell transplants. *N Engl J Med* **350**: 950-952, 2004.
- Walsh TJ, Finberg RW, Arndt C, Hiemenz J, Schwartz C, Holcenberg JS. Liposomal amphotericin B for empirical therapy in patients with persistent fever and neutropenia. National Institute of Allergy and Infectious Diseases Mycoses Study Group. *N Engl J Med* **340**: 764-771, 1999.
- Dannaoui E, Meis JF, Loebenberg D, Verweij PE. Activity of posaconazole in treatment of experimental disseminated zygomycosis. *Antimicrob Agents Chemother* **47**: 3647-3650, 2003.
- Millon L, Larosa F, Lepiller Q, Legrand F, Rocchi S, Grenouillet F. Quantitative polymerase chain reaction detection of circulating DNA in serum for early diagnosis of mucormycosis in immunocompromised patients. *Clin Infect Dis* **56**: e95-e101, 2013.
- Millon L, Herbrecht R, Grenouillet F, et al; French Mycosis Study Group. Early diagnosis and monitoring of mucormycosis by detection of circulating DNA in serum: retrospective analysis of 44 cases collected through the French Surveillance Network of Invasive Fungal Infections (RESSIF). *Clin Microbiol Infect* **22**: 810.e1-810.e8, 2016.
- Sato K, Oinuma KI, Niki M, Yamagoe S, Takeya H. Identification of a novel rhizopus-specific antigen by screening with a signal sequence trap and evaluation as a possible diagnostic marker of mucormycosis. *Med Mycol* **55**: 713-719, 2017.
- Cordonnier C, Pautas C, Maury S, Vekhoff A, Farhat H, Schwarzniger M. Empirical versus preemptive antifungal therapy for high-risk, febrile, neutropenic patients: a randomized, controlled trial. *Clin Infect Dis* **48**: 1042-1051, 2009.
- Herbrecht R, Patterson TF, Slavin MA, Marchetti O, Maertens J, Pappas PG. Application of the 2008 definitions for invasive fungal diseases to the trial comparing voriconazole versus amphotericin B for therapy of invasive aspergillosis: a collaborative study of the Mycoses Study Group (MSG 05) and the European Organization for Research and Treatment of Cancer Infectious Diseases Group. *Clin Infect Dis* **60**: 713-720, 2015.

The Internal Medicine is an Open Access article distributed under the Creative Commons Attribution-NonCommercial-NoDerivatives 4.0 International License. To view the details of this license, please visit (<https://creativecommons.org/licenses/by-nc-nd/4.0/>).