




Arab Journal of Urology
(Official Journal of the Arab Association of Urology)

www.sciencedirect.com



PEDIATRIC UROLOGY
ORIGINAL ARTICLE

Grafted tubularised incised-plate urethroplasty: An objective assessment of outcome with lessons learnt from surgical experience with 263 cases



Vipul Gupta *, Sunil Kumar Yadav, Talal Alanzi, Islam Amer, Mohmmad Salah, Mamdouh Ahmed

Department of Pediatric Surgery and Urology, Ibn Sina Hospital, Kuwait City, Kuwait

Received 28 June 2016, Received in revised form 9 September 2016, Accepted 19 September 2016

Available online 27 October 2016

KEYWORDS

Inlay graft;
Urethroplasty;
Primary hypospadias

ABBREVIATIONS

HOSE, Hypospadias Objective Scoring Evaluation;
(G-)TIP, (grafted) tubularised incised-plate urethroplasty;
MIUP, midline incision of the urethral plate;

Abstract Objective: Snodgrass urethroplasty remains the preferred technique in primary distal hypospadias but development of meatal stenosis often limits distal extension of the midline incision of the urethral plate (MIUP), which remains a limiting factor in reconstructing an apical neomeatus (NM). We here-in assess the cosmetic and functional outcome with distal extension of the MIUP in grafted tubularised incised-plate urethroplasty (G-TIP) repair.

Patients and methods: This prospective study included the surgical experience of 263 cases of primary hypospadias operated upon between 2012 and 2015. The G-TIP technique included standard steps of Snodgrass urethroplasty, including degloving and harvesting of glans wings, followed by MIUP that was extended distally beyond the margins of the urethral plate (UP) into the glans. The incised bed was grafted with a free preputial skin graft and fixed to the bed with polydioxanone 7-0 suture. The UP was tubularised and the suture line reinforced with a Dartos flap. The urethral catheter was removed at 7–10 days after the repair and the outcome was assessed at follow-up using the Hypospadias Objective Scoring Evaluation (HOSE) system.

* Corresponding author. Fax: +965 24839564.

E-mail address: drvipul7577@gmail.com (V. Gupta).

Peer review under responsibility of Arab Association of Urology.



Production and hosting by Elsevier

NM, neomeatus;
UCF, urethrocutaneous fistula;
UP, urethral plate

Results: An apical NM was achieved in 96% of the patients with a 3.7% incidence of urethrocutaneous fistula. The presence of suture tracks and graft at the margins of the NM were seen in the initial 4% and 5% of cases, respectively. Acceptable cosmetic results, with objective HOSE scores of > 14, were achieved in 96% of cases.

Conclusion: The G-TIP repair is a straightforward and feasible technique facilitating reconstruction of an apical NM, with an optimum outcome based on HOSE scoring. However, multicentre data are needed for undertaking comparative analysis and to assess the universal applicability of this technique in primary hypospadias.

© 2016 Production and hosting by Elsevier B.V. on behalf of Arab Association of Urology. This is an open access article under the CC BY-NC-ND license (<http://creativecommons.org/licenses/by-nc-nd/4.0/>).

Introduction

Tubularised incised-plate urethroplasty (TIP) repair is the universally accepted reconstructive procedure in primary distal and even proximal hypospadias, with excellent cosmetic and functional outcomes in most cases. The deep midline incision of the urethral plate (MIUP) remains a key to its success but still its distal extension into the glans is not universally recommended owing to the chance of meatal stenosis. This often remains a limiting factor for reconstructing the neomeatus (NM) at the tip of the glans. Thus, grafting of the incised urethral plate (UP) has been used with the aim of reducing the complications associated with distal extension of the MIUP and in cases with a narrow urethral plate. But to date, there has been a paucity of published surgical experiences with large series of cases highlighting graft-specific complications along with outcomes.

In the present study, we assess the cosmetic and functional outcome with distal extension of the MIUP in grafted TIP (G-TIP) repair. The critical steps potentially resulting in complications are analysed to highlight the simplicity and feasibility of G-TIP repair in achieving a more anatomical NM and reducing complications, e.g. meatal stenosis, which are reported with Snodgrass urethroplasty.

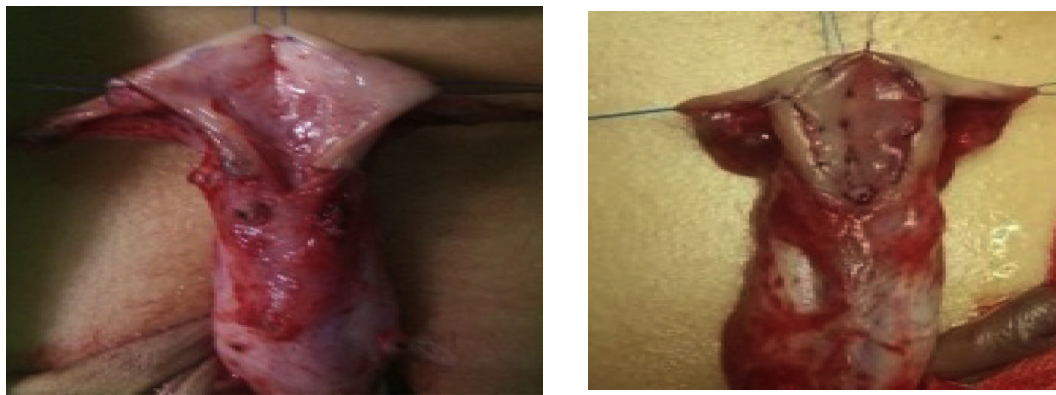
Patients and methods

The prospective case series included evaluation of surgical experience with G-TIP as the only procedure performed between 2012 and 2015 in 263 patients with primary hypospadias. The G-TIP technique included penile skin degloving with circumferential incision extending in a U-shaped fashion around the hypospadias meatus. The glans wings are mobilised and the MIUP, starting from level of the hypospadias meatus and extending distally beyond the margins of the UP into glans for 3–4 mm, was performed thus relaxing the UP (Fig. 1a). The incised bed was grafted with a preputial skin-free graft (Fig. 1b). The UP was tubularised with 7-0 polydioxanone suture and reinforced with

either a single or double layered dartos flap. The urethral stent was removed on seventh postoperative day in cases of distal and tenth postoperative day in cases of proximal hypospadias due to the long grafted bed. The objective outcome was assessed at a minimal follow-up of 3 months by an independent urologist for meatal location, shape, penile angulation, urethrocutaneous fistula (UCF), and urinary steam. There was moderate penile angulation (10–30°) in six patients with mid-penile and proximal hypospadias. The outcome was assessed using the ‘Hypospadias Objective Scoring Evaluationb’ (HOSE) system.

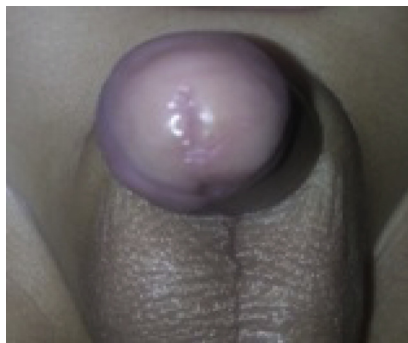
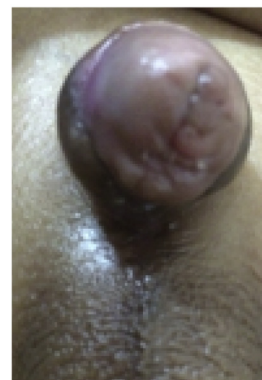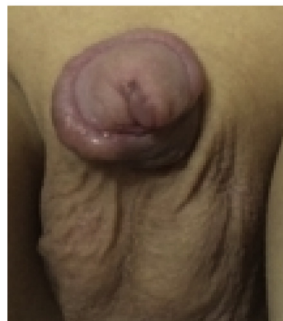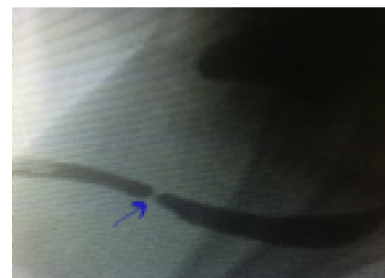Results

The native meatus was coronal in 81 (30.7%), subcoronal in 113 (43%), distal penile in 40 (17%), mid-penile in 23 (8.7%), and proximal penile in six (2.2%) patients. Amongst 88 (33%) patients with penile chordee, 34 required modified Nesbit plication. The median (range) age of repair was 15 (11–72) months. Over a median (range) follow-up of 17 (6–22) months a slit-like apical meatus was achieved in 252 (96%) patients (Fig. 2a). The presence of suture tracks and graft at the margins of the slit-like meatus occurred in the initial 12 (4%) and 17 (5%) cases, respectively, which was subsequently avoided by quilting an adequate small graft with subcuticular sutures taking the inner margins of the glans and UP. Among 10 (3.7%) patients with UCF, two had spontaneous closure, six underwent successful fistula closure in the presence of a wide apical NM, and two required a staged repair. The urine steam was single and straight in 252 (96%) of the patients and one had a very thin steam of urine 6 weeks postoperatively. Retrograde urethrography which was performed only in this case, showed localised urethral stricture (Fig. 2d). Cystoscopy revealed stricture at the site of the urethrocutaneous anastomosis, probably resulting from extension of the MIUP and grafting into normal urethra. Endoscopic internal urethrotomy was successful without recurrence on follow-up at 8 months. There was moderate penile angulation (10–30°) in seven patients that had



(a) Incised Urethral Plate

(b) Inlay Preputial Graft

Figure 1 (a) Incised UP and (b) Inlay preputial graft.**a; Vertical Slit Like Meatus****b: Suture tracks at Neomeatus****c : Bulky Graft at Margins of Neomeatus****d: RGU showing Anastamotic Stricture****Figure 2** (a) Vertical slit-like meatus, (b) Suture tracks at NM, (c) Bulky graft at margins of NM, and (d) Retrograde urethrography showing anastamotic stricture.

mid-penile and proximal hypospadias. Acceptable cosmetic results with an objective HOSE score of >14 was achieved in 96% of the patients.

Discussion

Hypospadias is one of the most common paediatric urology disorders, with a reported incidence of 1 in

300 new-born males. Among the different reconstructive techniques, the TIP repair proposed by Snodgrass in 1994 is most preferred owing to its simplicity and good cosmetic and functional outcomes [1–5]. Among the reported complications meatal stenosis, UCF, and urethral stricture have been reported in literature with an incidence varying from 2% to 26% as per surgeon expertise, shallow MIUP, small glans volume, and an

incision extending beyond the distal limits of the UP that often heals by fibrosis [1,2,5–8]. However, if the incision does not reach far enough the cosmetic result will be suboptimal, contributing to a meatus that is not slit-like [1,9,10]. To optimise the outcome in such cases and among surgeons in the early learning curve many modifications to the original procedure have been proposed. TIP modification in the form of grafting of the UP was proposed by Kolon and Gonzales [2] in 2000. Grafting allows immediate coverage of the incised UP with epithelium and minimises the effects of a narrow UP and low glans volume, thus facilitating tubularisation and medial rotation of the glans for reconstruction of a slit-like NM with a conical glans [1,2]. Similarly, Jayanthi [11] proposed extension of the midline incision distally into the tip of glans and found that it facilitates reconstruction of an anatomical apical NM without any increase incidence of meatal stenosis, which is often not recommended in the original TIP repair. In the present study, we combined the proposed modification of Jayanthi [11] and Kolon and Gonzales [2] in cases of primary hypospadias and assessed the outcome based on complications and HOSE objective scoring, which to best of our knowledge has not been reported in literature to date.

TIP repair has been based on the theory that a deep MIUP facilitates its widening and hence allows a tension-free tubularisation [1,3,4,12]. The incised bed of the UP heals by granulation and subsequent fibrous, which has been proposed to be a contributing factor for the development of urethral strictures in cases reported occasionally in the literature [1,13,14]. Similarly development of meatal stenosis has been attributed to distal extension of the MIUP into the glans, which often prevents reconstruction of a NM at the tip [1,3,4,13,14]. Grafting allows immediate coverage with epithelium and minimises the fibrotic reaction in the incised UP bed [1,2,15,16]. Leslie et al. [13] analysed the histological and functional characteristics of the inlay preputial graft in an experimental rabbit model and reported that the preputial graft kept its original histological characteristics, with good graft take and integration, thus postulating its application in human.

Kolon and Gonzales [2] first proposed grafting of the incised UP bed with the aim of promoting healing by epithelisation, and from their experience with 32 cases they observed that grafting prevents development of meatal stenosis, neourethral stricture, UCF and urethral diverticulum, especially in the presence of a narrow UP. Similarly, Gundeti et al. [17] reported that G-TIP urethroplasty reduces complication rates, especially in patients with narrow UPs. Shimotakahara et al. [8] reported the first prospective comparative analysis between TIP and G-TIP urethroplasty in 50 patients and reported a low complication rate in patients undergoing G-TIP urethroplasty and hence strongly recom-

mended it as the procedure of choice in primary hypospadias. Subsequently, Mouravas et al. [1] in 2014 reported a comparative analysis of TIP and G-TIP in 47 patients and reported that G-TIP results in lower fistula and urethral stricture rates, thus recommending it as the procedure of choice in patients undergoing primary hypospadias surgery. In a series of 102 patients operated on with G-TIP, no patient had meatal stenosis but fistula occurred in 10 patients (9.8%) [18]. In a retrospective study of a single surgeon's experience with TIP and G-TIP, the patients with G-TIP were found to have significantly lower rates of fistula and stenosis [8]. In the present study, the UP was grafted with free preputial graft along with extension of the midline incision distally into the tip of the glans. The apical NM at the tip of glans was reconstructed successfully in 96% of patients. The incidence of UCF, irrespective of glans size and degree of hypospadias, in the present series was 3.7%, which is comparable to the published fistula rates reported with G-TIP and TIP repair [1–3,5–9]. Meatal stenosis, even in the presence of a distal extension of the MIUP, and urethral stricture were not observed in the present series. Thus the present and reported experiences with grafting of the incised UP suggest that grafting prevents fibrosis of the incised distal glans and UP by immediately providing an epithelial surface thereby reducing the chances of development of urethral stricture and meatal stenosis. However, in the present study there was no analysis of the pathological stages of graft take. Graft uptake is associated with the development of hypergranulation and possible vertical graft contracture, which may have been contributory factors for the development of residual chordee in seven patients with mid-penile hypospadias with long inlay grafts in the present study.

Hypospadias repair should be evaluated both in terms of cosmetic and functional outcomes [19,20]. Holland et al. [19] proposed an objective assessment scoring system (HOSE) designed to reflect the traditional weighting given to a satisfactory functional outcome, e.g. a single urinary stream, straight erection, and absence of a fistula, together with the current emphasis on a repair that is also aesthetic, positioning a vertically orientated meatus near the tip of the glans. As the score can be measured by clinical observation it is simple to use, with good agreement between parents and medically trained assessors. A total HOSE score of 14 has been recommended as an acceptable outcome in the present era of hypospadias repair [19,20]. Al-Adl et al. [20] objectively assessed the functional and cosmetic outcomes in 43 patients undergoing TIP with distal extension of the MIUP without grafting and achieved a HOSE score of ≥ 14 in 98% of the patients. In the present study, a functional and cosmetic outcome based on meatal shape, location, penile angulation, UCF and urine steam as per the HOSE score showed that a score

Table 1 Objective outcome as per HOSE system (with permission Prof. A.J. Holland).

Objective outcome		HOSE score	Number of patients
Meatal shape	Slit-like	2	252
	Circular	1	11
Meatal location	Apical	4	252
	Proximal glanular	3	7
	Coronal	2	3
Penile angulation	Distal penile	1	1
	Straight	4	246
	Mild < 10°	3	10
	Moderate 10–45°	2	6
Urinary stream	Severe > 45°	1	1
	Single good calibre	2	252
	Single poor calibre	1	1
Fistula	No fistula	4	253
	Single coronal	3	5
	Single proximal	2	4
	Multiple or dehiscence	1	2

of ≥ 14 was achieved in 96% of patients, thus suggesting that G-TIP is associated with a good overall objective outcome. An appraisal of the surgical technique from the surgeon's experience during the learning curve resulted in a few modifications to the grafting technique. In the present series, it was observed in the initial 12 cases that subcuticular suturing of the graft with the inner margin of the glans prevented development of suture tracts at follow-up (Fig. 2b). Similarly as observed in 17 patients in the present series, a large and bulky graft results in a visible graft through the NM (Fig. 2c); thus, adequate thinning and re-sizing of the graft is recommended with the aim of optimising the cosmesis of the NM. Although circumferential anastomotic stricture occurred in one case where the graft was sutured to the incised UP proximally in the native urethra, so to avoid this we recommend the grafting of the urethral bed at the level of the native meatus only. Endoscopic incision should be considered as the initial treatment of choice in such cases thus avoiding morbidity resulting from re-do urethroplasty. The present study has several limitations. There is no comparative analysis either prospective or retrospective with TIP repair. Moreover, the glans size and the width of the UP, which are limiting factors for the success of TIP urethroplasty, has been taken into consideration only objectively without mathematical calculation of the critical size of the UP and glans width. Thus, a statistical comparison with TIP urethroplasty appears warranted to ascertain whether grafting in TIP repair actually prevents development of urethral stricture and UCF, especially in the presence of limiting factors like a narrow UP and small glans volume. The pathological aspect of graft healing, along with the long-term complications result-

ing from UP grafting, need to be assessed especially in terms of longitudinal graft contracture and histological changes resulting from exposure of grafted skin to urine. Still the present study can be considered clinically significant as a single-surgeon experience with a large number of cases, long-term follow up, critical appraisal of the surgical technique, and assessment of outcome in terms of the HOSE system by another surgeon thus nullifying the observer bias. A non-comparative objective and functional outcome assessment in the present study in terms of an absence of development of meatal stenosis, urethral stricture, a low rate of UCF and reconstruction of an anatomical NM at the glans tip justifies considering grafting of the incised UP with distal extension of the midline incision in cases of primary hypospadias (see Table 1).

Conclusion

The extended distal incision and grafting of the UP in TIP repair is a technically straightforward and feasible technique, which can be considered with the aim of reconstructing an apical NM along with reducing the incidence of UCF and meatal stenosis. We further conclude that grafting of the incised UP proximally into the normal urethra should be avoided to prevent development of anastomotic stricture and similarly subcuticular suturing of the graft with the inner margin of the incised glans is recommended to prevent suture tracks and visible graft at the margins of the NM. Thus, G-TIP urethroplasty should be considered in patients undergoing TIP repair with the aim of facilitating the availability of multicentre data, so that with comparative analysis the universal applicability and efficacy of this technique in primary hypospadias can be assessed.

Conflicts of interest

None.

Source of funding

None.

References

- [1] Mouravas V, Filippopoulos A, Sfoungaris D. Urethral plate grafting improves the results of tubularized incised plate urethroplasty in primary hypospadias. *J Pediatr Urol* 2014;**10**:463–8.
- [2] Kolon TF, Gonzales Jr ET. The dorsal inlay graft for hypospadias repair. *J Urol* 2000;**163**:1941–3.
- [3] Snodgrass WT. Tubularized, incised plate urethroplasty for distal hypospadias. *J Urol* 1994;**151**:464–5.
- [4] Snodgrass WT. Tubularized incised plate (TIP) hypospadias repair. *Urol Clin North Am* 2002;**29**:285–90.
- [5] Nerli RB, Guntaka AK, Patil RA, Patne PB. Dorsal inlay inner preputial graft for primary hypospadias repair. *Afr J Paediatr Surg* 2014;**11**:105–8.

- [6] Ye WJ, Ping P, Liu YD, Li Z, Huang YR. Single stage dorsal inlay buccal graft with tubularised incised urethral plate technique for hypospadias reoperations. *Asian J Androl* 2008;**10**:682–6.
- [7] Braga LH, Lorenzo AJ, Salle JL. Tubularized incised plate urethroplasty for distal hypospadias: a literature review. *Indian J Urol* 2008;**24**:219–25.
- [8] Shimotakahara A, Nakazawa N, Wada A, Nagata S, Koga H, Takahashi T, et al. Tubularized incised plate urethroplasty with dorsal inlay graft prevents meatal, neourethral stenosis: a single surgeon's experience. *J Pediatr Surg* 2011;**46**:2370–2.
- [9] Erlich RM. Tubularized-incised urethral plate urethroplasty: is regular dilatation necessary for success? *BJU Int* 2000;**86**:145.
- [10] Singh RB, Pavithran NM. Lessons learnt from Snodgrass tip urethroplasty: a study of 75 cases. *Pediatr Surg Int* 2004;**20**:204–6.
- [11] Jayanthi VR. The modified Snodgrass hypospadias repair: reducing the risk of fistula and meatal stenosis. *J Urol* 2003;**170**:1603–5.
- [12] Snodgrass WT, Bush N, Cost N. Tubularized incised plate hypospadias repair for distal hypospadias. *J Pediatr Urol* 2010;**6**:408–13.
- [13] Leslie B, Jesus LE, El-Hout Y, Moore K, Farhat WA, Bägli DJ, et al. Comparative histological and functional controlled analysis of tubularized incised plate urethroplasty with and without dorsal inlay graft: a preliminary experimental study in rabbits. *J Urol* 2011;**186**(Suppl.):1631–7.
- [14] Schwentner C, Seibold J, Colleselli D, Alloussi SH, Schilling D, Stenzl A, et al. Single-stage dorsal inlay full-thickness genital skin grafts for hypospadias reoperations: extended follow up. *J Pediatr Urol* 2011;**7**:65–71.
- [15] Hoebeke P, Oosterlinck W. Principles of wound healing as applied to urethra surgery. *Ann Urol (Paris)* 1993;**27**:209e12 [in French].
- [16] Ferro F, Vallasciani S, Borsellino A, Atzori P. Snodgrass urethroplasty: grafting the incised plate –10 years later. *J Urol* 2009;**182**(Suppl.):1730–4.
- [17] Gundeti M, Queteishat A, Desai D, Cuckow P. Use of an inner preputial free graft to extend the indications of Snodgrass hypospadias repair (Snodgraft). *J Pediatr Urol* 2005;**1**:395–6.
- [18] Silay MS, Sirin H, Tepeler A, Karatag T, Armagan A, Horasanli K, et al. “Snodgraft” technique for the treatment of primary distal hypospadias: pushing the envelope. *J Urol* 2012 Sep;**188**:938–42.
- [19] Holland AJ, Smith GH, Ross FI, Cass DT. HOSE: an objective scoring system for evaluating the results of hypospadias surgery. *BJU Int* 2001;**88**:255–8.
- [20] Al-Adl AM, El-Karamany TM, Bassiouny AS. Distal extension of the midline urethral-plate incision in the Snodgrass hypospadias repair: an objective assessment of the functional and cosmetic outcomes. *Arab J Urol* 2014;**12**:116–26.